

Utilization of Diagnostic Imaging in Dental and Maxillofacial Trauma in Selected Kenyan Hospitals

Eunice N. Kihara¹, Tom J. Ochola¹, Evelyn G. Wagaiyu², Mark L. Chindia¹

¹Department of Oral & Maxillofacial Surgery, University of Nairobi, Nairobi, Kenya

²Department of Periodontology/Community and Preventive Dentistry, University of Nairobi, Nairobi, Kenya

Email: ekihara@uonbi.ac.ke

How to cite this paper: Kihara, E.N., Ochola, T.J., Wagaiyu, E.G. and Chindia, M.L. (2020) Utilization of Diagnostic Imaging in Dental and Maxillofacial Trauma in Selected Kenyan Hospitals. *Open Journal of Stomatology*, 10, 61-73.

<https://doi.org/10.4236/ojst.2020.105008>

Received: March 19, 2020

Accepted: April 26, 2020

Published: April 29, 2020

Copyright © 2020 by author(s) and Scientific Research Publishing Inc.

This work is licensed under the Creative Commons Attribution International License (CC BY 4.0).

<http://creativecommons.org/licenses/by/4.0/>



Open Access

Abstract

Background: Globally, much has changed in the imaging modalities available to investigate maxillofacial trauma. Nevertheless, the regional practice patterns are highly influenced by availability, affordability and accessibility of imaging services as well as competence in interpreting radiological images and the practice of defensive medicine. The aim was to assess the use of maxillofacial trauma imaging modalities as well as to document patterns of skeletal injuries at selected government-sponsored health facilities in Kenya. **Material and Methods:** A cross sectional study, done in three health facilities. **Results:** There were 137 (81.5%) males and 31 (18.5%) females with a mean of 27.73 ± 9.86 years. Commonest aetiology of trauma was interpersonal violence (80, 47.62%) and road traffic crashes (63, 37.50%). The total number of radiological examinations was 250 with a mean of 1.49 ± 0.99 examinations per patient. Plain film radiographs were more (210, 84%) than computed tomographic scans (39, 15.6%). Dental panoramic technique was the most (104, 61.9%) popular. Most participants experienced isolated fractures to the mandible (99, 58.9%) and midface (28, 16.7%). **Conclusion:** Dental panoramic radiography remained the imaging of choice for mandibular fractures which had the commonest occurrence. There is a shift from the traditional conventional skull radiography to computed tomography in the diagnosis of midfacial fractures. Judicious utilization and prompt provision of affordable services in dental panoramic and computed tomographic scanning at the study centers and other upcoming health facilities are paramount in ensuring timely diagnosis and management of maxillofacial injuries in Kenya.

Keywords

Maxillofacial Radiology, Facial Trauma, Imaging

1. Introduction

The role of imaging in maxillofacial injury is to determine the location of the anatomic structures of both hard and soft tissue in various spatial planes. Moreover, it plays a part in categorization of fractures, planning of definitive treatment, intraoperative and postoperative assessment of surgical outcome and subsequent healing [1] [2] [3] [4]. A lot has changed in the imaging modalities and techniques available to achieve this goal.

Some of these forms of imaging include plain film radiography of the skull and other maxillofacial projections, Computed Tomographic scanning (CT scan), Cone Beam Computed Tomography (CBCT), Magnetic Resonance Imaging (MRI) and ultrasound (US). Plain films and CT are the modalities that are mostly used in evaluating maxillofacial trauma. However, plain film radiography is limited in the assessment of dental and maxillofacial injury. The drawbacks include anatomic superimposition of facial structures necessitating the use of several projections, the effect of soft tissue edema on the quality of the image and inability to image soft tissues. Additionally, there is a higher chance of technical errors that are related to patient positioning, film processing and geometric distortion [5] [6] [7]. Hence, CT was introduced in the late 1970s and 1980s which enabled visualization of both hard and soft tissues in multiple planes [8] [9] [10]. Nevertheless, the cost of CT machine installation and imaging services is definitely higher as compared to two dimensional imaging. This led to the invention of CBCT which led to reduction of time for volumetric data acquisition, lower radiation dose than conventional CT and lower cost of installation. However, CBCT is best suited for the investigation of hard tissue [11] [12].

The MRI also plays a role in investigating cranial nerves, soft tissue involvement *i.e.* articular disk and assessing hematomas [3]. Additionally, it supplements CT in the assessment of orbital injuries such as tracing the optic nerve, assessing associated brain trauma and postoperative assessment of secondary repair of orbital defects [11] [13] [14]. Ultrasound has been suggested as a complementary diagnostic procedure to augment CT in the assessment of patients with midfacial fractures [15] [16] [17]. Maxillofacial trauma has a high incidence of occurrence and requires accurate and prompt diagnosis and management. Diagnostic imaging is paramount; however, the current utilization in Kenya has not been documented hence the need for the study. The aim of the study was to assess the use of conventional radiography, computed tomography and other imaging modalities in the diagnosis of maxillofacial trauma at selected Health facilities in Kenya.

2. Materials and Method

The research work was a cross-sectional study which was conducted at three public health facilities which had varied access to head and neck imaging modalities. The modalities included plain film radiography (skull, panoramic and intraoral radiography), ultrasound and advanced imaging modalities (CBCT, CT

and MRI).

The study included only in- and outpatients who had experienced oral and maxillofacial injuries and were treated at the maxillofacial wards and clinics at the study centers. Patients who did not consent to participate in the study were excluded. The patients were selected through the non-probability convenience sampling method which included patients who visited the study centers and consented to participate in the study. Hence, every patient who presented with maxillofacial injury at the study centers was invited to participate in the study. Data was collected by the first author assisted by a research assistant; it was obtained from patient interviews as well as from their clinical notes and diagnostic images. The request for the imaging at the study centers had been done by the attending clinicians who were dentists and or senior maxillofacial registrars and maxillofacial surgeons. The same team interpreted the images. However, the CT scans were additionally interpreted by general radiologists. Radiographs and CT scans were viewed on light box viewers. Findings from the radiographs were recorded on the data collection forms. The information obtained was analysed using statistical packages for social sciences (SPSS) 20.0 (SPSS Inc. Chicago, Illinois, USA).

The proposal was approved by the Ethics and Research Committee under approval number, P345/06/2012. Written consent was obtained from the patients, parent or guardian and all the information was kept confidential.

3. Results

The results of this study include the demographic data of the participants, the aetiology of maxillofacial trauma, the radiographic investigations that were performed and the pattern of maxillofacial fractures.

3.1. Demographic Data

There were 168 participants, 137 (81.5%) were males while 31 (18.5%) were females. The age ranged between 2.5 - 60 years with a mean of 27.73 ± 9.86 years. The mean age for females (22.85 ± 10.55) was significantly lower (independent samples t-test, $p = 0.002$) than for the males (28.86 ± 9.38). The age group 21 - 30 comprised the majority (73, 43%) of patients involved in maxillofacial trauma (**Table 1**).

3.2. Aetiology of Maxillofacial Trauma

The cause of trauma was mainly through interpersonal violence (IPV) (80, 47.62%) and road traffic crashes (RTC) (63, 37.50%). Minor causes included falls and sports injuries (22, 13.1%) while three (1.8%) others included a case of a donkey bite, accident at a stone quarry and one child experienced intraoral injury to the buccal tissues by napier grass (**Table 2**). Majority of people aged 21 years and above experienced trauma through RTC and IPV while falls and sports injury involved the younger individuals aged below 20 years. Aetiology of injury

Table 1. Gender distribution according to age groups.

AGE GROUP	Gender distribution		
	Females	Males	Total (%)
0 - 10	3	6	9 (5.4)
11 - 20	11	14	25 (14.9)
21 - 30	11	62	73 (43.5)
31 - 40	5	40	45 (26.8)
41 - 50	1	9	10 (6.0)
51 - 60	0	3	3 (1.8)
Unknown age	0	3	3 (1.8)
Total	31	137	168 (100)

Table 2. Aetiology of maxillofacial trauma.

Aetiology	Number of patients	%
Interpersonal violence	80	47.62
Road traffic crashes	63	37.50
Falls	15	8.93
Sports	7	4.17
Others	3	1.80
Total	168	100

was found to be dependent on age. Chi-square test was significant and a relationship was found between age group and cause of injury, $\chi^2 (4, n = 162) = 25.649, P = 0.001$.

3.3. Radiographic Investigations

Majority (161, 94.4%) of the patients seen at the study centers underwent radiographic investigations either as additional or preliminary imaging. A third (57, 33.9%) of the patients had already received initial management in minor health facilities before referral to the study centers. Most (44, 77.19%) of the referred patients had various radiographic investigations done before referral.

All the images whether digital or analogue were printed on radiographic films and were mainly (126, 75%) kept by the patients while the hospital archived a few of them. Almost all (164, 97.6%) the patients undertook the requested images while only 4 (2.4%) did not. Only one participant declined extra imaging after having taken (postero-anterior) PA and lateral skull radiographs, while three others could not afford.

The total number of radiological examinations was 250 with a mean of 1.49 ± 0.99 examinations per patient. The examinations ranged from 0 to a maximum of 5 per patient. Majority had one examination (111, 66.1%), followed by two (23, 13.7%), three (18, 10.7%), four (6, 3.6%), five (3, 1.8%) while 7 (4.2%) had no form of imaging. Plain radiographs were the commonest form of imaging (210, 84%) followed by computed tomographic scans. There was only one ultrasound investigation which was utilized in a child who had soft tissue trauma of

the buccal tissues by a foreign body in form of napier grass. Dental pantomogram was done by most patients while other skull projections were minimally done. Intraoral examinations were done for 21 (12.5%) patients only, they included intraoral periapicals 10 (6%), upper standard occlusal 9 (5.4%) and lower standard occlusal were the least 2 (1.2%) (**Table 3**).

3.4. Maxillofacial Fractures

There were 154 (91.7%) patients who sustained various forms of maxillofacial skeletal injuries. Most (99, 58.9%) participants experienced isolated fractures to the mandible followed by midface (28, 16.7%). Some patients had a combination of mandibular fractures with either midface (24, 14.3%) or upper face fractures (2, 1.2%). The most fractured bone in the midface was the maxilla (46, 56%) followed by the zygomatic bone (18, 22%), orbit (12, 15%), naso-orbito-ethmoidal complex (16, 20%). There were 45 (26.8%) patients who experienced dentoalveolar fractures to the lower (24, 14.3%) and upper (20, 11.9%) teeth while only one (0.6%) had fractured teeth in both jaws.

Majority of patients who had sustained mandibular fractures were due to IPV while RTC mainly resulted in midface fractures. Most of the patients who experienced falls and sport injuries had sustained mandibular fractures. Fracture site was found to be dependent on cause of injury. Chi-square test was significant and a relationship was found between fracture site and cause of injury, $X^2(4, n = 168) = 17.930, P = 0.001$.

Majority of patients who were diagnosed with mandibular (88, 88.89%) and mid/upper face (32, 58.18%) injuries had been investigated through plain film radiography and CT scans respectively.

Among the 99 patients who had isolated mandibular fractures, majority (82, 82.83%) had been imaged through dental panoramic imaging (**Figure 1**) while 6 (6.06%) had CT scans, 15 (15.15%) had both PA and lateral skull views, 6 (6.06%) PA mandible and 8 (8.08%) had lateral oblique views of the mandible. Among the 55 patients who had mid- and upper face fractures with or without lower face injuries were assessed largely through CT scans (32, 58.18%) (**Figure 2**) while the rest had plain film radiography.

Thirty nine patients had CT scans which were mostly used to investigate patients who had experienced trauma due to RTC (30, 76.92%), while the minority were due to IPV (6, 15.38%), falls, sports and others (3, 7.69%). Chi-square test was significant and a relationship was found between imaging modality and cause of injury, $X^2(8, n = 168) = 37.382, P = 0.000$. Streak artifact and beam hardening caused by a metallic object has been demonstrated in **Figure 3** which shows the image of an IPV victim who experienced knife stab injuries.

The analysis of the fractures of the mandible revealed the body of the mandible as the commonest (55, 35%) fracture site followed by angle (34, 21%), parasymphysis (32, 20%), condyle (21, 13%), symphysis (13, 8%) and ramus (6, 4%) while the coronoid process was the least fractured site (2, 1%). Majority of patients had one fracture site (61, 58.7%) while the rest had 2 or more. The com-

most combination of fractures involved the body and other parts of the mandible.

Table 3. Imaging techniques utilized to investigate maxillofacial trauma.

Imaging modality	Technique	No. of images (%)	
3-Dimensional imaging	Computed tomography	39 (15.6)	
	Dental panoramic view	104 (41.6)	
	Skull views	Postero-anterior	28 (11.2)
		Lateral	28 (11.2)
	2-Dimensional imaging	Midface views	Occipital mental view 2 (0.8)
			Submental view 1 (0.4)
Temporalmandibular joint views		Reverse Townes 3 (1.2)	
Mandibular views		Lateral oblique 14 (5.6)	
		Postero-anterior 9 (3.6)	
	Intraoral images 21 (8.4)		
Ultrasound		1 (0.4)	
Total		250 (100)	

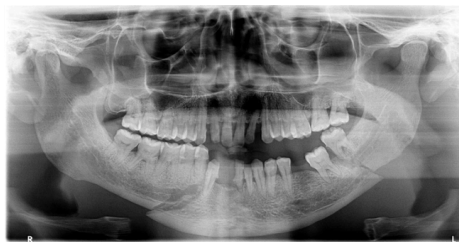

Figure 1. Dental panoramic image showing bilateral mandibular body fractures after IPV.

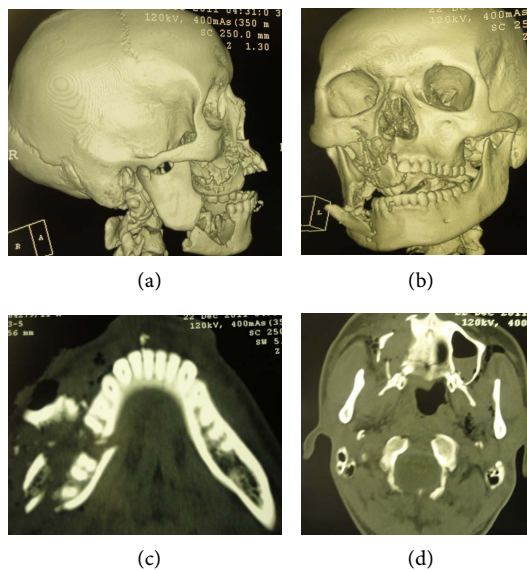


Figure 2. CT scan 3-D images ((a) & (b)) and axial views showing multiple fractures involving the mandible (c) and maxilla (d) with displaced fragments.

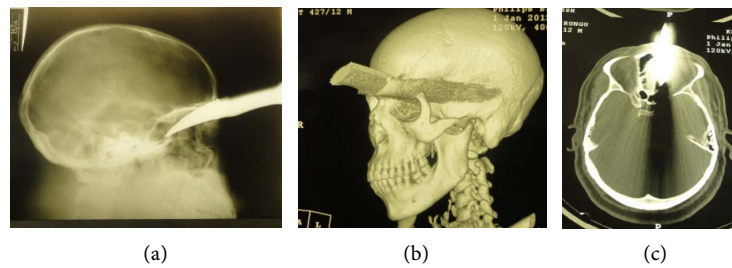


Figure 3. Lateral skull view (a) and CT scan, 3-D view (b) of an IPV patient with a knife stack on the forehead. Axial view (c) demonstrates streak artifact and beam hardening effect caused by the metallic knife.

4. Discussion

Similar to this study, maxillofacial injuries have been found to commonly involve the young adults aged 21 - 30 years old and males are more often involved as compared to females. However, the ratio of female to male varies widely ranging from 1:1 - 1:11 [18]-[25]. The variation may be due to differences in study area, population and its culture, study period, sample size and the variable under investigation. Interpersonal violence followed by road traffic crashes affected most of the patients; similar aetiological factors have been previously cited as the leading causes of traumatic injuries. Nevertheless, the cause of trauma varies with the age group, gender, ethnic culture, infrastructure, economic status and the period in the year when the data is collected [18] [21] [22] [24] [25].

It was evident that majority of the patients underwent radiological investigations before and after referral to the health facilities. Most of the radiographic investigations which were done before referral included PA and lateral skull views. This had already been noted during the routine evaluation of new trauma patients. However, it was noted that only a few patients presented with such radiographs though some of them claimed to have left some radiographs at home which were highly likely to be skull radiographs. Unfortunately, the skull views could not be adequately utilized to diagnose the maxillofacial injuries. Hence, appropriate imaging such as panoramic views and CT scan had to be done. Patients may also delay in acquiring additional images due to long queues at imaging centers or time wasted in obtaining adequate funds. Such a scenario exposes the patient to excessive ionizing radiation and increases the cost of imaging while delaying the treatment and healing period. Delay in management may lead to posttraumatic complications and prolonged suffering among other comorbidities. Delay in getting appropriate maxillofacial imaging may be caused by the fact that dental panoramic imaging services are not readily available in most health facilities as compared to general radiographic services.

It was noted that majority of the radiographs were kept by the participants; this was probably the safest way of keeping analogue images which saves the hospital the archiving space and retrieval time. It also allows the patients to carry their radiographic images along during referral to other clinicians so as to avoid repeat examinations and unnecessary exposure to ionizing radiation. However,

it limits radiology-based research since researchers do not have the luxury of accessing the images at will, a fact that prompted the current study to be done prospectively. This challenge could be overcome through a switch to digital imaging which allows more copies of the same image to be created and can be stored by both patient and the clinician.

In the three study centers, conventional radiography formed a major part of radiological diagnosis of maxillofacial fractures. They were principally utilized to investigate the mandible which was frequently fractured. Apart from panoramic imaging which is mostly used to investigate the fractures of the mandible, alternative form of imaging was utilized in one of the study centers where dental panoramic imaging was not available and one had to travel for 61 kilometers to access one. The alternative imaging included the PA and lateral oblique examinations of the mandible; The PA mandible can also be done in addition to panoramic imaging since it plays an extra role in demonstrating displacement of fractures in the posterior part of the mandible [7] [26]. Nevertheless, conventional radiographs may be limited especially in the investigation of mandibular condylar fractures particularly when a patient cannot open their mouth adequately during temporal mandibular joint radiological investigations.

Previous studies have shown that CT scanning of mandibular injuries clearly shows condylar fractures in relation to size, location and orientation of the fractured fragments [3] [27]. A meta-analysis of condylar fractures found 3-D imaging to be the main imaging modality that was utilized in all the sampled studies. It was utilised as a diagnostic tool and for computer-assisted preoperative simulation. The MRI was also used to investigate the involvement of soft tissues of the temporal mandibular joint *i.e.* the articular disc and joint capsule [2]. Selective intraoperative imaging has been found to play an important role in assessing reduced mandibular fractures as well as prompt correction of any noted anomalies [1].

The mandible has been found to be the most fractured facial bone as revealed in this and other studies [18] [19] [21] [22]. Similar to our findings, Udeabor *et al.*, (2014) reported that the commonest fractured mandibular site was the body (23.7%) then the parasymphysis 14.1% and angle 9.6% [22]. Another Indian study also found the three mandibular sites to be commonly fractured [19]. However, a study by Lone *et al.*, (2014) revealed that the parasymphyseal area (38%) was frequently fractured followed by the condyle (18%), angle (15%), symphysis (14%) and body (14%) [18]. Majority (74%) of the injuries were caused by RTC. The mechanism of mandibular trauma has been found to correlate with the fracture pattern whereby parasymphyseal fractures are associated with RTC, body fractures are likely to result from IPV and condylar fractures from falls [28].

In our study centers, CT scanning was largely limited to diagnostic evaluation of midface fractures involving the maxilla, zygomatic complex, orbital and naso-ethmoidal fractures. Similar practice has been reported in a majority of studies [1] [3] [29]. Use of conventional radiography such as occipital mental and

submental views to assess midfacial fractures was minimally utilized at the study centers. A previous audit in one of the health facilities had already shown a downward trend in utilization of skull and maxillofacial projections [30]. This is mainly due to the obvious limitations that are characteristic of two dimensional imaging as well as increased accessibility and affordability of advanced imaging modalities. CT imaging is therefore, invariable in investigating maxillofacial injuries due to its ability to demonstrate fracture sites and displaced fragments in multiple planes, 3-D images and panoramic views. Additionally, it is the gold standard for patients with multiple craniofacial and brain injuries [3] [27] [29] [31].

Cone beam CT was not utilized at the study centers. This is probably due to the fact that the only accessible machine during the period of data collection had a small field of view which could not entirely image the maxillofacial region at once [32]. Cone beam imaging has been found to provide further diagnostic information in the investigation of mandibular fractures which are not clear on conventional radiographs. It plays a role in confirming or ruling out the presence of a fracture as well as identifying new fracture sites. Additionally, it shows fracture displacement and the nature of the fractured segment (s) [27]. Kaeppler *et al.*, (2013) reported a change of treatment plan in 22 (9.5%) maxillofacial injury sites after patients underwent further investigation with CBCT. The commonest site where additional information was noted was the paramedian (parasymphyseal) area which is prone to superimposition of the cervical vertebrae in plain-film radiography. However, imaging by CBCT led to cancellation of planned surgical treatment in 6 (2.6%) sites which had shown fracture lines but there were no fractures demonstrated [27].

Cone Beam CT has also been applied in the diagnosis of orbital, midface and condylar head fractures. In particular, CBCT imaging of orbital fractures helps protect the eye lens from the effects of high radiation that is associated with conventional CT. Since the effects of metal artefacts are less pronounced in CBCT, this type of imaging can also be used to investigate gunshot wounds and other metallic foreign bodies [31] [33] [34]. Nevertheless, patients with concomitant brain injury are best investigated with CT scan which normally includes imaging of the maxillofacial skeleton [1] [3].

None of the study participants had intraoperative imaging. In previous studies this modality has been used to investigate zygomaticomaxillary fractures either by CT, CBCT, fluoroscopy or ultrasound following a reconstruction surgery. Intraoperative imaging plays a role in verifying whether a displaced fracture has been accurately repositioned before final surgical wound closure. However, the clinicians have to apply the right selection criteria since a patient may require pre-, intra- and postoperative imaging which results into increased exposure to ionizing radiation, treatment cost and operative time [4] [35]. In addition, Xing *et al.* (2015) demonstrated that CT navigation can be used in conjunction with endoscopy in removing firearm or explosive foreign bodies [36].

Ultrasound scanning was only utilized in a single patient who had sustained

injury to the buccal tissues while working in a garden. Nevertheless, some authors have suggested ultrasound as a complementary diagnostic procedure to augment CT in the assessment of patients with midfacial fractures. On the other hand, its use is limited to dislocated fractures of the orbital margin and the nasal bones. It has also been applied in investigating the zygomatic arch, anterior wall of the frontal sinus and subcondylar fractures [15] [16] [17] [32]. The study was limited to public hospitals hence the results cannot be generalized to private hospitals where there is better accessibility to imaging modalities and patients are likely to have higher social economic status as compared to patients in public hospitals.

The results of the study highlight the current utilization of various imaging techniques for management of facial fractures. Dental panoramic radiography remains the imaging of choice for mandibular fractures. Clinicians in Kenya are also moving from conventional skull radiography and have embraced computed tomography in the diagnosis of midfacial fractures. Since healthcare in Kenya has been devolved to the county level, the county government should make digital dental panoramic and computed tomographic imaging more accessible to trauma patients. In addition, a review of treatment outcome of mandibular fractures after diagnostic imaging through conventional radiography should be done in order to ratify continued use of this modality.

5. Conclusion

Males were four times more involved in maxillofacial trauma as compared to females. The age group 21 - 30 years comprised the commonest victims of trauma. The leading cause of trauma was through interpersonal violence followed closely by road traffic crashes. Conventional plain film radiography was widely utilized while advanced imaging modalities were minimally prescribed. Mandibular fractures were the majority and were investigated using panoramic radiography while midface fractures were diagnosed through CT scan. Most images were kept by the patients.

Acknowledgements

Great appreciation goes to the Director of Kenyatta National Hospital, Dean, School of Dental Sciences, University of Nairobi and Medical Superintendent of Naivasha District Hospital for granting permission to conduct the study. We thank all who participated in collecting the data. The data collection was supported by Medical Education Partnership Initiative (MEPI)/Partnership in Improved Medical Education in Kenya (PRIME-K) GRANT NO. NIH-5R24TW008889-02.

Conflicts of Interest

The authors declare no conflicts of interest regarding the publication of this paper.

References

- [1] Gelesko, S., Markiewicz, M.R. and Bell, R.B. (2013) Responsible and Prudent Imaging in the Diagnosis and Management of Facial Fractures. *Oral and Maxillofacial Surgery Clinics of North America*, **25**, 545-560. <https://doi.org/10.1016/j.coms.2013.07.001>
- [2] Boffano, P., Benech, R., Gallesio, C., Arcuri, F. and Benech, A. (2014) Current Opinions on Surgical Treatment of Fractures of the Condylar Head. *Craniofacial Trauma & Reconstruction*, **7**, 92-100. <https://doi.org/10.1055/s-0034-1371772>
- [3] Schuknecht, B. and Graetz, K. (2005) Radiologic Assessment of Maxillofacial, Mandibular, and Skull Base Trauma. *European Radiology*, **15**, 560-568. <https://doi.org/10.1007/s00330-004-2631-7>
- [4] Singh, M., Ricci, J.A. and Caterson, E.J. (2015) Use of Intraoperative Computed Tomography for Revisional Procedures in Patients with Complex Maxillofacial Trauma. *Plastic and Reconstructive Surgery-Global Open*, **3**, e463. <https://doi.org/10.1097/GOX.0000000000000455>
- [5] Bingham, C.B. (1955) The Fractured Malar. *Oral Surgery, Oral Medicine, Oral Pathology*, **8**, 13-20. [https://doi.org/10.1016/0030-4220\(55\)90125-0](https://doi.org/10.1016/0030-4220(55)90125-0)
- [6] Morris, J.H. (1948) Dental Roentnographic Technique-Interpretation Relationships. *Oral Surgery, Oral Medicine, Oral Pathology*, **1**, 58-63. [https://doi.org/10.1016/0030-4220\(48\)90005-X](https://doi.org/10.1016/0030-4220(48)90005-X)
- [7] White, S.C. and Pharoah, M.J. (2004) *Oral Radiology: Principles and Interpretation*. 5th Edition, Mosby, St Louis, 71-265.
- [8] Brant-Zawadzki, M.N., Minagi, H., Federle, M.P. and Rowe, L.D. (1982) High Resolution CT with Image Reformat Ion in Maxillofacial Pathology. *American Journal of Roentgenology*, **138**, 477-483. <https://doi.org/10.2214/ajr.138.3.477>
- [9] Kreipke, D.L., Moss, J.J., Franco, J.M., Maves, M.D. and Smith, D.J. (1984) Computed Tomography and Thin-Section Tomography in Facial Trauma. *American Journal of Roentgenology*, **142**, 1041-1045. <https://doi.org/10.2214/ajr.142.5.1041>
- [10] Weber, A. (2001) History of Head and Neck Radiology: Past, Present and Future. *Radiology*, **218**, 15-24. <https://doi.org/10.1148/radiology.218.1.r01ja2715>
- [11] Boeddinghaus, R. and Whyte, A. (2008) Current Concepts in Maxillofacial Imaging. *European Journal of Radiology*, **66**, 396-418. <https://doi.org/10.1016/j.ejrad.2007.11.019>
- [12] Scarfe, W.C. (2005) Imaging of Maxillofacial Trauma: Evolutions and Emerging Revolutions. *Oral Surgery, Oral Medicine, Oral Pathology, Oral Radiology, and Endodontology*, **100**, 75-96. <https://doi.org/10.1016/j.tripleo.2005.05.057>
- [13] Hassfeld, S., Muhling, J. and Zoller, J. (1995) Intraoperative Navigation in Oral and Maxillofacial Surgery. *International Journal of Oral and Maxillofacial Surgery*, **24**, 111-119. [https://doi.org/10.1016/S0901-5027\(05\)80871-9](https://doi.org/10.1016/S0901-5027(05)80871-9)
- [14] Laine, F.J., Conway, W.F. and Laskin, D.M. (1993) Radiology of Maxillofacial Trauma. *Current Problems in Diagnostic Radiology*, **22**, 145-188. [https://doi.org/10.1016/0363-0188\(93\)90019-P](https://doi.org/10.1016/0363-0188(93)90019-P)
- [15] Forrest, C.R., Lata, A.C., Marcuzzi, D.W. and Bailey, M.H. (1993) The Role of Orbital Ultrasound in the Diagnosis of Orbital Fractures. *Plastic and Reconstructive Surgery*, **92**, 28-34. <https://doi.org/10.1097/00006534-199307000-00004>
- [16] Friedrich, R.E., Heiland, M. and artel-Friedrich, S. (2003) Potentials of Ultrasound in the Diagnosis of Midfacial Fractures. *Clinical Oral Investigations*, **7**, 226-229. <https://doi.org/10.1007/s00784-003-0232-5>

- [17] Kleinheinz, J., Anastassov, G.E. and Joos, U. (1997) Ultrasonographic versus Conventional Diagnostic Procedures in Dislocated Subcondylar Mandibular Fractures. *Craniofacial Trauma*, **3**, 40-42.
- [18] Lone, P., Singh, A.P., Kour, I. and Kumar, M. (2014) A 2-Year Retrospective Analysis of Facial Injuries in Patients Treated at Department of Oral and Maxillofacial Surgery, IGGDC, Jammu, India. *National Journal of Maxillofacial Surgery*, **5**, 149-152. <https://doi.org/10.4103/0975-5950.154817>
- [19] Natsu, S.S., Pradhan, H., Gupta, H., Alam, S., Gupta, S., Pradhan, R., Mohammad, S., Kohli, M., Sinha, V.P., Shankar, R. and Agarwal, A. (2012) An Epidemiological Study on Pattern and Incidence of Mandibular Fractures. *Plastic Surgery International*, **2012**, Article ID: 834364. <https://doi.org/10.1155/2012/834364>
- [20] Al Ahmed, H.E., Jaber, M.A., Fanas, S.H.A. and Karas, M. (2004) The Pattern of Maxillofacial Fractures in Sharjah, United Arab Emirates: A Review of 230 Cases. *Oral Surgery, Oral Medicine, Oral Pathology, Oral Radiology, and Endodontology*, **98**, 166-170. <https://doi.org/10.1016/j.tripleo.2004.01.020>
- [21] Ascani, G., Cosimo, F., Costa, M., Mancini, P. and Caporale, C. (2014) Maxillofacial Fractures in the Province of Pescara, Italy: A Retrospective Study. *Otolaryngology*, **2014**, Article ID: 101370. <https://doi.org/10.1155/2014/101370>
- [22] Udeabor, S.E., Akinbami, B.O., Yarhere, K.S. and Obiechina, A.E. (2014) Maxillofacial Fractures: Etiology, Pattern of Presentation, and Treatment in University of Port Harcourt Teaching Hospital, Port Harcourt, Nigeria. *Journal of Dental Surgery*, **2014**, Article ID 850814. <https://doi.org/10.1155/2014/850814>
- [23] Seife, H. and Teffera, E. (2015) Epidemiology of Road Traffic Accidents: A Prospective Study at a Tertiary University Hospital in Addis Ababa Ethiopia. *East and Central African Journal of Surgery*, **20**, 3-9.
- [24] Nyameino, S., Butt, F., Guthua, S.W., Macigo, F. and Akama, M. (2018) Occurrence and Pattern of Maxillofacial Injuries Caused by Motorcycle Crashes Presenting at Two Major Referral Hospitals in Nairobi, Kenya. *Craniofacial Trauma & Reconstruction Open*, **2**, e9-e14. <https://doi.org/10.1055/s-0038-1660434>
- [25] Odhiambo, W.A., Guthua, S.W., Macigo, F.G. and Akama M.K. (2002) Maxillofacial Injuries Caused by Terrorist Bomb Attack in Nairobi, Kenya. *International Journal of Oral and Maxillofacial Surgery*, **31**, 374-377. <https://doi.org/10.1054/ijom.2001.0199>
- [26] Whaites, E. (1996) *Essentials of Dental Radiography and Radiology*. 3rd Edition, Churchill Livingstone, London.
- [27] Kaeppler, G., Cornelius, C., Ehrenfeld, M. and Mast, G. (2013) Diagnostic Efficacy of Cone-Beam Computed Tomography for Mandibular Fractures. *Oral Surgery, Oral Medicine, Oral Pathology and Oral Radiology*, **116**, 98-104. <https://doi.org/10.1016/j.o000.2013.04.004>
- [28] Barde, D., Mudhol, A. and Madan, R. (2014) Prevalence and Pattern of Mandibular Fracture in Central India. *National Journal of Maxillofacial Surgery*, **5**, 153-156. <https://doi.org/10.4103/0975-5950.154818>
- [29] Ogura, I., Sasaki, Y. and Kaneda, T. (2014) Multidetector Computed Tomography of Maxillofacial Fractures. *Japanese Dental Science Review*, **50**, 86-90. <https://doi.org/10.1016/j.jdsr.2014.05.002>
- [30] Kihara, E.N., Opondo, F., Ochola, T.J., Chindia, M.L. and Wagaiyu, E.G. (2012) 5-Year Audit of the Range and Volume of Diagnostic Radiographic Services at the University of Nairobi Dental Hospital. *Open Journal of Stomatology*, **2**, 234-236. <https://doi.org/10.4236/ojst.2012.23041>

- [31] Shah, N., Bansal, N. and Logani, A. (2014) Recent Advances in Imaging Technologies in Dentistry. *World Journal of Radiology*, **6**, 794-807. <https://doi.org/10.4329/wjr.v6.i10.794>
- [32] Kihara, E., Chindia, M., Ochola, T. and Parker, M. (2014) Clinical Significance of Pathological and Anatomical Findings in Cone Beam CT Scans of the Maxillary Sinus. *Open Journal of Stomatology*, **4**, 285-290. <https://doi.org/10.4236/ojst.2014.46040>
- [33] Macleod, L. and Heath, N. (2008) Cone-Beam Computed Tomography (CBCT) in Dental Practice. *Dental Update*, **35**, 590-598. <https://doi.org/10.12968/denu.2008.35.9.590>
- [34] Sidebottom, A.J. (2013) The TN Chawla Lecture—The Current Management of Midfacial Trauma. *Journal of Oral Biology and Craniofacial Research*, **3**, 120-122. <https://doi.org/10.1016/j.jobcr.2013.07.006>
- [35] Van Hout, W.M.M.T., Van Cann, E.M., Marvick, S.M., Frank, M.H. and Koole, R. (2014) Intraoperative Imaging for the Repair of Zygomaticomaxillary Fractures: A Comprehensive Review of the Literature. *Journal of Cranio-Maxillofacial Surgery*, **42**, 1918-1923. <https://doi.org/10.1016/j.jcms.2014.07.012>
- [36] Xing, L., Duan, Y., Zhu, F., Shen, M., Jia, T., Liu, L., Tao, J., Chen, Y., Gao, Z. and Zhang, H. (2015) Computed Tomography Navigation Combined with Endoscope Guidance for the Removal of Projectiles in the Maxillofacial Area: A Study of 24 Patients. *International Journal of Oral and Maxillofacial Surgery*, **44**, 322-328. <https://doi.org/10.1016/j.ijom.2014.12.018>