

*East African Medical Journal Vol. 83 No. 3 March 2006*

#### EMBRYONAL RHABDOMYOSARCOMA WITH UTERINE INVERSION: CASE REPORT

S.B.O. Ojwang, MD., MMed(OG), DipGyn Oncol, Department of Obstetrics and Gynaecology, College of Health Sciences, University of Nairobi. P.O. Box 19676-00200, Nairobi Kenya, F. Rana, MMed, S. Sayed, MMed, Department of Pathology, The Aga Khan Hospital, Nairobi P.O. Box 30270-00100, Nairobi, Kenya and W.K. Aruasa, MBChB, Department of Obstetrics and Gynaecology, College of Health Sciences, University of Nairobi, P.O. Box 19676-00200, Nairobi, Kenya

Request for reprints to: Prof. S.B.O. Ojwang, Department of Obstetrics and Gynaecology, College of Health Sciences, University of Nairobi. P.O. Box 19676-00200, Nairobi, Kenya

## EMBRYONAL RHABDOMYOSARCOMA WITH UTERINE INVERSION: CASE REPORT

S.B.O OJWANG, F. RANA, S. SAYED and W.K. ARUASA

### SUMMARY

**Presented here is a 16 year old nulliparous girl who had embryonal rhabdomyosarcoma causing uterine inversion. She had been referred with a one year history of continuous vaginal bleeding and vaginal swelling. Histology had shown sarcoma botyroides and had received five courses of chemotherapy at the referring hospital. At surgery she was found to have uterine inversion and extended hysterectomy was carried out to be followed by radiotherapy.**

### INTRODUCTION

Uterine sarcomas, which are sometimes composed of a great variety of mesodermally derived elements, such as bone, cartilage, fat and striated muscle are the subject of great histogenetic speculation and innumerable pathologic classification systems (1). Consequently, they are surrounded by more confusion and controversy than most gynaecologic tumours. In fact for a group of cancers that make up only 2-3% of all malignant tumours of the corpus, they have received an inordinate amount of attention and they occupy a disproportionate volume of controversial literature.

No common aetiological agent has been identified with uterine sarcomas, but in some reports prior pelvic radiation therapy has been associated with the mixed forms of uterine sarcoma in an unexpectedly high number of cases (2).

Sarcomas can occur at any age but are most prevalent after forty years of age. However embryonal rhabdomyosarcoma is seen mainly in children. Sarcomas are well known as a source of haematogenous metastases, but with the exception

of leiomyosarcomas, lymphatic permeation and contiguous spread are probably the most common methods of extension (3). Endometrial sarcomas can usually be diagnosed by endometrial biopsy or dilatation and fractional curettage, but the sarcomas derived from the myometrium (leiomyosarcomas) frequently require hysterectomy to obtain adequate tissue for analysis.

From a clinical standpoint, the uterine sarcomas can be separated into four categories: leiomyosarcomas (LMS), endometrial stromal sarcomas (ESS), malignant mixed mesodermal tumours (MMMT), and adenosarcomas (4). These categories depend upon their histogenesis with LMS thought to arise from the myometrial smooth muscle cell or a similar cell lining blood vessels within the myometrium whereas ESS and MMMT arise from undifferentiated endometrial stromal cells, which retain the potential to differentiate into malignant cell lines that histologically appear native (homologous) or foreign (heterologous) to the human uterus. Pure heterologous sarcomas such as rhabdomyosarcoma, chondrosarcoma, osteosarcoma and liposarcoma are extremely rare.

There is no universal agreement on the histologic features that determine outcome, but most authorities agree that the number of mitotic figures per high power field, vascular and lymphatic invasion, serosal extension and in some cases degree of anaplasia are helpful (5). Lack of discriminating histologic features and analytic sophistication often cause arbitrary assignment of a specific tumour to an improper category. This is regrettable, since treatment is largely predicated on correct histologic diagnosis. Historically, surgery has been the favored treatment for uterine sarcomas, but some evidence shows that a combination of radiation therapy and surgery is more beneficial for patients with endometrially derived uterine sarcomas (6). Chemotherapy has proved to be useful in treating some recurrences (7).

### CASE REPORT

A 16 year old nulliparous lady presented with a one year history of continuous per vaginal bleeding and vaginal heaviness. The per vaginal bleeding occasionally came in clots and required upto five pads to be changed in 24 hours. She also had foul smelling copious, yellowish, thick per vaginal discharge for one year. Prior to coming to us, she had presented six months earlier at the referring hospital with a swelling protruding through the vagina and histology showed sarcoma botryoides. She had been treated with five courses of cyclophosphamide 900mg, doxorubicin 90mg and vincristine 2mg at three-weekly intervals. This treatment reduced a heterogenous enhancing mass (on abdominal CT scan) from 9.0 x 9.0 x 10.5cm to 7.0 x 6.3 x 8.9cm. At this point, her guardian thought of seeking a second opinion in Nairobi.

At the time of presentation to us, she also had severe lower abdominal pain, dysuria and frequency of micturition for two months. There was no history of gross haematuria. She also had painful bowel movements with bloodstained stool for one week and mucus in stool for five months. There was no history of cough or chest pain. There was no history of X-ray exposure. She had her menarche at age 14 and prior to her current illness had moderate menstrual flow of four days every 28 to 30 days and no dysmenorrhoea. She was not sexually active.

On physical examination, at presentation, she was found to be a young girl in fair general condition

and of asthenic build, moderately pale, no lymphadenopathy and not in any obvious distress. Abdominal examination was essentially normal.

Laboratory investigations revealed Hb7.1g/dl, PCV 21.7%, MCV 84.7fL; urea, electrolytes, creatinine and liver function tests all within normal limits. An ELISA for HIV-1 and 2 test was negative. After these investigations she underwent examination under anaesthesia (EUA) which revealed a large tumour mass arising from upper vagina. Most of the vagina was not involved. There was thickening of the parametria but it seemed that the tumour did not involve the pelvic side wall. Per rectal examination revealed free, smooth rectal mucosa and a large round mass anteriorly. Biopsy of the tumour was taken and histology confirmed embryonal rhabdomyosarcoma.

Immunohistochemical staining with monoclonal antibodies using envision system showed features consistent with embryonal rhabdomyosarcoma (spindle cell type).

She was planned for laparotomy after chest and abdomino-pelvis CT scans and barium enema. CT scan of the chest was normal while abdomino-pelvis CT scan reported two channels containing faecal material. The normal channel consisted of a redundant appearing sigmoid colon which passed into a normal upper third of rectum. However, the other channel was located anteriorly and appeared related to the genital tract.

Barium enema showed unimpeded barium flow from the anal opening to the caecum. The rectum distended well with barium and showed no filling defect or mucosal lesion. The sigmoid colon showed mild narrowing of the lumen without stricture filling defects or hold up. The descending colon was poorly haustrated but otherwise of normal caliber. The transverse and ascending colon were normal. There was reflux of barium at the ileocaecal valve and the distal jejunum appeared normal.

She was transfused two pints of whole blood and thereafter underwent extended total abdominal hysterectomy. Intra-operatively, there was a large tumour occupying most of the vagina but not involving vaginal wall and the tumour had pulled the uterus with it causing uterine inversion. Fallopian tubes were filling the dimple of the inversion. The uterus, ovaries and pelvic lymph nodes were grossly normal. The ovaries were left *in situ* and elevated about one and a half inch from umbilicus in case of

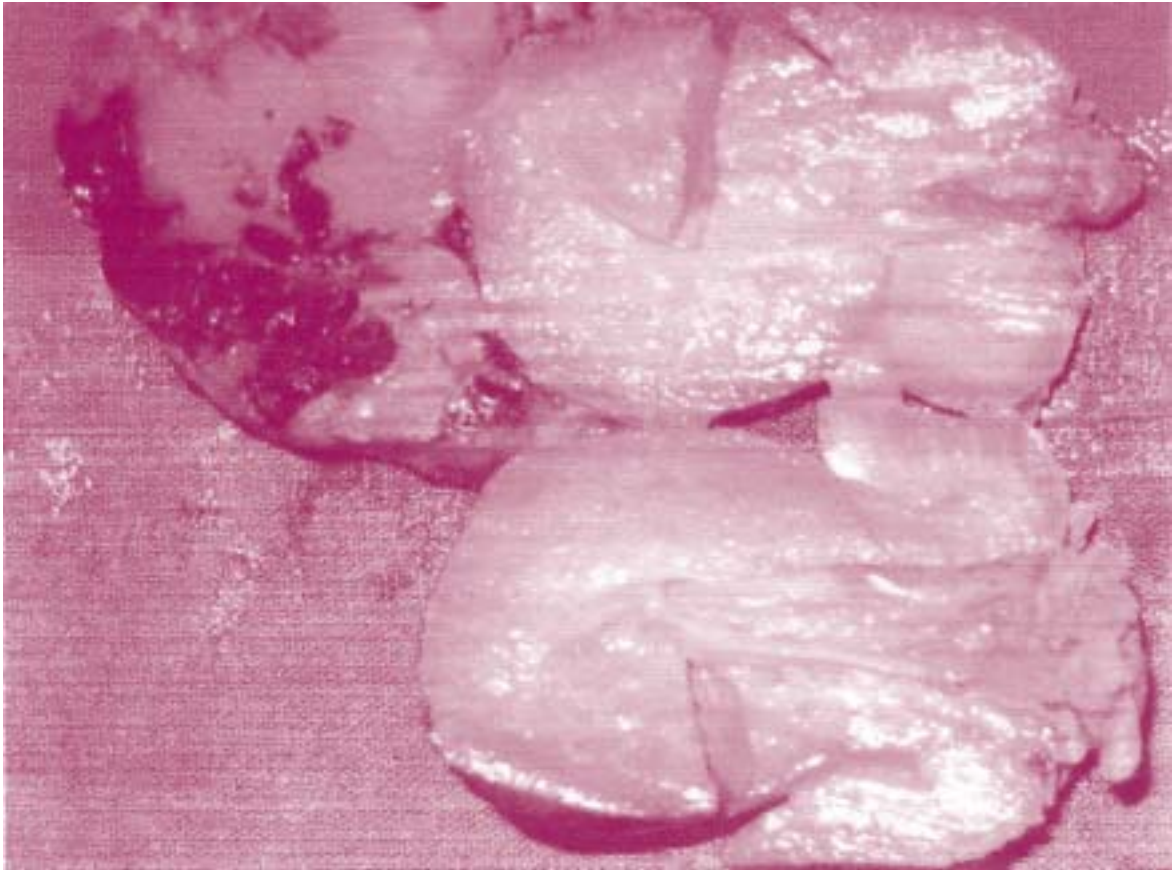
future radiotherapy. Histology confirmed embryonal rhabdomyosarcoma with vaginal cuff and endometrium tumour free (Figures 1 and 2).

The patient made an uneventful recovery, and

was discharged. Post-operative review three weeks after surgery revealed a well healed wound, normal pelvis, and haemoglobin 8.2g/dl. She was given haematinics and scheduled for radiotherapy.


**Figure 1**

*Uterus specimen of embryonal rhabdomyosarcoma*



**Figure 2**

*Photomicrograph of embryonal rhabdomyosarcoma on histology*





## DISCUSSION

Sarcomas account for only 2-3% of all female genital tract malignancies. Only 10% of these occur outside the uterus (e.g. vulva, vagina, fallopian tubes, uterine ligaments). Rhabdomyosarcomas represent a rare neoplasm of mesoderm origin, and comprises about 1% of all genital malignancies. Sarcoma botyroides (embryonal rhabdomyosarcoma of the cervix) is an embryonic variant found mostly in vagina of infants and young children under the age of 16 years (8). In this case the tumour arose from the uterine fundus causing uterine inversion. Uterine inversion is rare in children. The confusing abdominopelvic CT scan was probably because of distorted anatomy due to the inverted uterus.

The modified OBER classification classifies uterine sarcomas into pure, mixed, malignant mullerian and unclassified sarcomas (4). Rhabdomyosarcoma is a pure heterologous sarcoma.

Uterine sarcomas are staged as follows (5):

- Stage I : Sarcoma confined to the endometrium
  - Ia : The length of the uterine cavity is 8cm or less
  - Ib : The length of the uterine cavity is more than 8cm
- Stage II : Sarcoma involves the fundus and endocervix but not extending outside the uterus.
- Stage III : Sarcoma extending outside the uterus but confined to the pelvis.
- Stage IV : Sarcoma spread outside the pelvis or invading the bladder and rectum.

The majority of uterine sarcomas present late (8). Though survival in cases of sarcoma botyroides is thought to be better than in other types, most surgery favour radical hysterectomy and bilateral salpingo-oophorectomy followed by adjuvant chemotherapy or radiotherapy.

Our patient had stage II disease and underwent

extended hysterectomy, ovarian sparing and was recommended for radiotherapy. We left the ovaries *in situ* given the age of our patient (16 years old) and the issue of estrogen replacement therapy. Some surgeons in recent years have also advocated fertility sparing surgery or conservative surgery (9,10).

Five-year survival for rhabdomyosarcoma is very poor (11). Our case represents a case where ovarian-sparing surgery was done to avoid the issue of hormone replacement therapy. It also shows that adjuvant chemotherapy can reduce the size of sarcoma botyroides prior to surgery.

## REFERENCES

1. De Cherney A.H. and Lauren N. Sarcoma of the uterus In: Current obstetric and gynaecologic diagnosis and treatment 9th edition. *Appleton and Lange*, 2003; 946-951.
2. Perez C.A. Effects of irradiation on mixed mullerian tumors of the uterus. *Cancer*. 1979; **43**: 1274
3. Van Dinh T. and Woodruff J.D. Leiomyosarcoma of the uterus. *Amer. J. Obstet. Gynaecol.* 1982; **144**: 817.
4. Ober W.B. Uterine sarcomas: uterine sarcomas and taxonomy. *Ann. N. Acad. Sci.* 1959; **75**: 568.
5. Kahanpaa K.V. Sarcomas of the uterus; a clinicopathologic study of 119 patients. *Obstet. Gynaecol.* 1986; **67**: 417.
6. Sorbe B. Radiotherapy and/or chemotherapy as adjuvant treatment of uterine sarcomas. *Gynaecol. Oncol.* 1984; **20**: 281.
7. Thigpen J.T. Phase II trial of cisplatin as first line chemotherapy in patients with advanced or recurrent uterine sarcomas: A gynaecologic oncology group study. *J. Clin. Oncol.* 1991; **9**: 1962.
8. Lappien G. Non uterine gynaecologic sarcomas. *Arch. Gynaec. Obstet.* 1987; **24**: 25-32.
9. Behtah N. Embryonal rhabdomyosarcoma of the uterine cervix. *Gynaec. Oncol.* 2003; **91**: 452-455.
10. Vlahos. Cervical sarcoma botyroides. *J. Reprod. Med.* 1999; **44**: 306-308.
11. Major F.J. Prognostic factors in uterine sarcoma. *Cancer*. 1993; **71**: 1702-1709.