

## Astrocytosis as a biomarker for late stage human African trypanosomiasis in the vervet monkey model

Fredrick Maloba<sup>1</sup>✉, John M. Kagira<sup>1</sup>, George Gitau<sup>2</sup>, Jackson Ombui<sup>2</sup>, Jan Hau<sup>3</sup>, Maina Ngotho<sup>1</sup>

1 – Institute of Primate Research, Animal Science Department, Karen, P.O. Box 2448-00502, Nairobi, Kenya.

2 – University of Nairobi, Faculty of Veterinary Medicine, Nairobi, Kenya.

3 – University of Copenhagen and University Hospital of Copenhagen, Department of Experimental Medicine, Copenhagen, Denmark.

Correspondence: Tel. +254-0723-086812, Fax +254-0723-882546, E-mail malobafred@yahoo.com

**Abstract.** The late stage human African trypanosomiasis (HAT) is characterized by central nervous system (CNS) involvement resulting in activation of astrocytes. The aim of the current study was to determine the relationship between the occurrence of astrocytosis and other biological markers for late stage disease in the vervet monkey model of HAT. Twelve (12) vervet monkeys were infected intravenously with  $10^4$  *Trypanosoma brucei rhodesiense*, and sub-curatively treated with diminazene aceturate (5 mg/kg x 3 days, intramuscularly) starting 28 days post infection (dpi) to induce advanced late stage disease. The monkeys were further curatively treated with Melarsoprol (3.6 mg/kg x 4 days, intravenously) starting 140 dpi following the blood relapse of trypanosomes. Brain samples were collected upon euthanasia at fortnight intervals from 42 dpi and brain sections were stained for astrocytosis. During the study, data on clinical signs, haematology, cerebrospinal fluid (CSF) and immunology (IL-10, IgG, and IgM) were collected fortnightly and correlated with the level of astrocytosis. The earliest time for astrocytosis detection was 42 dpi, in areas adjacent to the choroid plexus and the size and density of the astrocytes increased with time to peak at 98 dpi. Astrocytosis was widely distributed in the brain with predominance in the white matter. The size and density of the astrocytes regressed after curative treatment at 140 dpi to almost clear at 300 days post melarsoprol treatment. Serum parasite specific IgM and IgG had high sensitivities and were associated ( $p < 0.05$ ) with time post infection. The levels of CSF IgG, CSF IgM and white cell counts highly correlated ( $p < 0.05$ ) with astrocytosis. The haematology values and clinical signs did not ( $p > 0.05$ ) have significant correlation with astrocytosis. It is concluded that increase in CSF IgG, IgM and white cell counts can be used to indicate the occurrence astrocytosis and should be tested further as markers of late stage HAT.

**Keywords:** Astrocytosis; Sleeping sickness; Staging; Central nervous system.

Received 23/02/2011. Accepted 04/05/2011.

## Introduction

Human African trypanosomiasis (HAT), also known as sleeping sickness is caused by the protozoa haemoflagellate parasite *Trypanosoma brucei gambiense* (chronic or West African form) or *Trypanosoma brucei rhodesiense* (acute or East African form). The two forms of the disease are transmitted by tsetse flies (*Glossina* spp) (WHO, 2006). The disease is fatal if left untreated. Up to 60 million people are considered at risk of infection in the 36 countries in which HAT is endemic. In the last decade, with aggressive control of the disease and its vectors by various agencies, HAT cases have been reduced dramatically to an annual prevalence of 50,000-70,000 cases/year, and incidence rates of 15,000-17,000 cases/year (WHO, 2006). Diagnosis of the disease still remains a challenge and accurate tools are required for field diagnosis of HAT (Chappuis et al., 2005). In the early stage disease, trypanosomes are found in the haemolymphatic system, and treatment is relatively safe. However, in the late stage disease, parasites penetrate the central nervous system (CNS) which can only be treated with drugs such as Melarsoprol which are quite toxic (Kennedy, 2008).

The invasion of trypanosomes into the CNS causes an inflammatory reaction which is associated with an increase in white blood cells, cytokines, antibodies and proteins in the cerebrospinal fluid (Ngotho et al., 2006; Kennedy, 2010). Most of these biomarkers are currently used to stage HAT, but have major limitations (Chapuis, et al., 2005; Kennedy, 2010). It has been suggested that pathological changes occurring beyond the blood brain barrier might be more specific in staging of HAT (Amin et al., 2010). Astrocytes, being the major glial cell type in the brain, are affected by CNS infections and this result in reactive astrocytosis which is characterized by astrocytes with large cytoplasmic mass, long and branched processes, and increased expression of intermediate filaments such as glial fibrillary acidic protein (GFAP) (Sofroniew, 2005). In HAT, activation of astrocytes signifies entry of the parasites into brain tissue (Kennedy, 2005). The association between the current markers for staging of

HAT and astrocytosis has not been well studied in human and animal models. The vervet monkey model of *rhodesiense* sleeping sickness has been reported to closely mimic the disease clinically and immunologically (Farah et al., 2005). The monkeys, unlike rodents, allow sequential collection of cerebrospinal fluid (CSF) that allows study of changes in the CNS (Schimdt and Sayer, 1982; Farah et al., 2005; Thuita et al., 2008).

The current study used the vervet monkey model of HAT to investigate the relationship between the occurrence of astrocytosis and other biological markers used in staging of HAT.

## Materials and methods

### Ethics

This work was approved by the Institutional Animal Care and Use Committee (IACUC) of the Trypanosomiasis Research Centre of Kenya Agricultural Research Institute (TRC - KARI) where the work was carried out.

### Monkeys

Thirteen vervet monkeys (*Chlorocebus aethiops*, *Cercopithecus aethiops*, African green monkeys) of both sexes, weighing between 1.95 and 3.0 kg were used in the experiment. They were trapped from the wild in an area known to be non-endemic for human trypanosomiasis. The animals underwent to a 90-day quarantine, during which they were screened for zoonotic diseases and treated for ecto- and endoparasites before being subjected to the experiment. The monkeys were fed twice daily with commercial monkey pellets (Unga Feeds Ltd, Nakuru, Kenya) and green maize, carrots, tomatoes and bananas. Water was provided *ad libitum*. They were housed in single stainless steel cages at room temperatures of 23-25°C.

### Trypanosomes

The monkeys were infected intravenously (IV) with  $10^4$  *T.b. rhodesiense* (isolate KETRI 2537) delivered in 1 ml of phosphate saline glucose (PSG). This trypanosome isolate was initially

isolated from a sleeping sickness patient in Uganda in 1972, serially passaged in monkeys before cryopreservation (Fink and Schimdt, 1980).

### *Experimental design*

Twelve monkeys were infected intravenously (IM) with approximately  $10^4$  *Trypanosoma brucei rhodesiense*. One monkey was used as un-infected control. The infected monkeys were monitored for clinical signs and parasitemia and were then sub-curatively treated with diminazine aceturate at 5 mg/kg IM for 3 days starting 28 days post infection (dpi) to induce the advanced late stage disease. Two animals were then euthanized fortnightly from 42 dpi and brain samples harvested at the level of the third ventricle and preserved in 10% formalin. Following relapse of blood parasitemia at 140 dpi, the animals were curatively treated for late stage trypanosomiasis using Melarsoprol at 3.6 mg/kg intravenously for 4 days. The animals were kept until 462 dpi (300 days post Melarsoprol treatment) when they were euthanized.

On weekly basis, the monkeys were anaesthetized using Ketamine HCl, (Rotexmedica®, Trittau, Germany) at a dosage of 10 mg/kg body weight (kg/bwt) and diazepam (Valium®, May and Baker, UK) at a dosage of 1 mg/kg bwt and clinical examination conducted. Blood was collected by femoral venipuncture and immediately analysed for hematology (Coulter Ac.T diff; Beckman coulter, Miami, FL, USA). Cerebrospinal fluid (CSF) was collected through lumbar puncture and was analyzed for white cell counts and presence of trypanosomes. Serum levels of IL-10, serum and CSF levels of parasite specific immunoglobulin M and G were undertaken as previously described (Ngotho et al., 2009). An immunohistochemical analysis was performed on the brain samples to stain for astrocytes and the pathologies were graded using a predetermined scoring system of 0-4 described by Kennedy et al. (2003). Briefly, immunohistochemistry was performed on the Wax-embedded frontal serial sections, collected from the level of the third ventricle

containing the choroid plexus, suprachiasmatic nucleus and brain stem. The sections were placed on superfrost slides (Fisher Scientific, Town, USA), deparaffinized and hydrated through xylene followed by serial rehydration in ethanol. The slides were then washed with water and phosphate buffered saline (PBS). This was followed by blocking for endogenous peroxidase activity by incubating the sections in 0.6% hydrogen peroxide. The sections were washed with PBS and incubated with diluted horse normal serum (Vector stain®, Company, USA). Excess serum was then blotted from the sections and thereafter incubated in primary antiserum diluted in PBS. The slides were then stained with primary antiserum (antibody against Glial Fibrillary Acidic Protein (GFAP), incubated with biotinylated secondary antibody solution (Vector stain®, Company, Country) and Vectastain® ABC reagent. The slides were then washed, incubated in peroxidase solution and counter stained with Mayer's haematoxylin. The slides were then dehydrated using ethanol, incubated in xylene, mounted and examined under a light microscope (Leica DM 500 with attached camera - Leica ICC 50) starting with a magnification of X10 then X25 then X40. Astrocyte cell sizes were also measured using calibrated eye piece.

### *Statistical analysis*

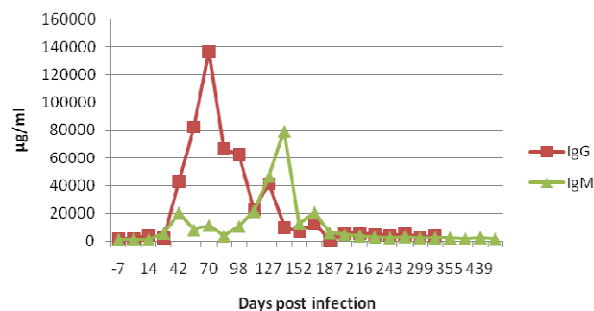
Data was entered into MsExcel® (Microsoft, USA) worksheets and was then exported into StatView® Version 5.0.1 (SAS Institute, USA) statistical package for statistical analysis. A correlation analysis was carried out to correlate astrocytosis and other diagnostic tests of HAT. Contingency tables were used to determine the sensitivity and specificity tests of individual diagnostic tests.

## **Results**

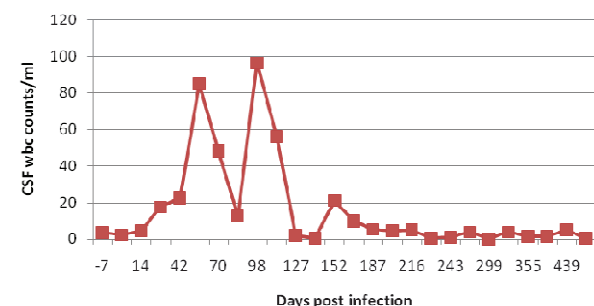
### *Bi-weekly mean values of various parameters*

The infected monkeys had clinical signs which were similar to those reported previously in the vervet monkey model (Ngotho et al., 2006), which mainly consisted of raised hair coat, eyelids oedema, splenomegally and lymphadenomegally. However, after Mel B

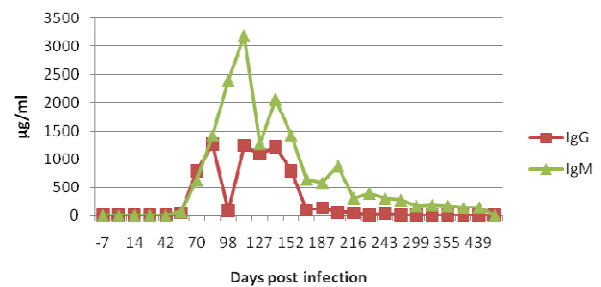
treatment, these symptoms disappeared and at the end of the study the animals were clinically normal. Packed cell volume (PCV) and white blood cells (WBC) declined following infection, but rose following diminazene and Mel B treatment. On the other hand, serum parasite specific IgM and IgG levels increased from 42 dpi and had several peaks before declining to normal values by 462 dpi (figure 1). CSF WBC counts increased in infected animals and progressed with the infection and declined after treatment with Melarsoprol at day 140 (figure 2). CSF parasite specific IgG and IgM were both detectable by 56 dpi and their levels progressively increased thereafter but declined with the Mel B treatment (figure 3). Parasite specific serum Interleukin 10 levels rose after infection and was characterized by fluctuations but declined to zero by day 98 and remained undetectable till the end of study.



**Figure 1.** IgM and IgG values in serum of monkeys infected with *T.b. rhodesiense*. The monkeys were treated with diminazene aceturate and melarsoprol at 28 and 140 days post infection



**Figure 2.** Levels of white blood cells in cerebrospinal fluid of monkeys infected with *T.b. rhodesiense*. The monkeys were treated with diminazene aceturate and melarsoprol at 28 and 140 days post infection



**Figure 3.** Levels of IgM and IgG in cerebrospinal fluid of monkeys infected with *T.b. rhodesiense*. The monkeys were treated with diminazene aceturate and melarsoprol at 28 and 140 days post infection

### Sensitivity and specificity of various diagnostic tests

The results of sensitivity and specificity of various tests against disease status are summarized in table 1. Serum IgM was the most sensitive test (75%), followed by serum IgG (55.9%) while the rest (CSF IgG, CSF IgM, CSF WBC and blood WBC) had low sensitivities of between 18.6% and 40%. CSF WBC was the most specific (91%) followed by blood WBC, CSF IgM, serum IgG and CSF IgG.

**Table 1.** Sensitivity and specificity of various screening tests in monkeys infected with *T.b. rhodesiense*

Test	Sensitivity (%)	Specificity (%)
CSF IgG	18.6	79.4
CSF IgM	21.4	85.3
CSF WBC	40	91
Serum IgM	75	22.4
Serum IgG	55.9	79.4
Blood WBC	22.1	88.2

### Immunohistochemistry

There was no detectable astrocytosis in the uninfected control animal which was euthanized at 462 dpi. The earliest detectable astrocytosis in the infected animals was on 42 dpi, when small sized astrocytes of 20 µm mean diameter, with long processes (mean length = 10 µm) were observed. Most astrocytes had two processes and were mainly located in areas adjacent to the choroids plexus. By 56 dpi the astrocytes were slightly bigger (mean = 30 µm in diameter). By 70 dpi, the astrocytes had a mean diameter of 35 µm, with at least 4 processes, at this time the astrocytes were found in most of the brain parenchyma with a

heavy intensity in the white matter. The pathology reached a peak at 98 dpi; when the astrocytes had long processes of mean length of 30-50  $\mu\text{m}$  and a large cell body of mean diameter of 50  $\mu\text{m}$  (figure 4).



**Figure 4.** Astrocytes in brain of a monkey infected with *T.b. rhodesiense* at day 98 post infection (mag x40)

One vervet monkey died suddenly at 47 days after Mel B treatment. Brain sections of this monkey showed astrocytes with prominent cytoplasm, short (2.5-5  $\mu\text{m}$  long) processes and large cell bodies of 15-20  $\mu\text{m}$ . The staining intensity was also darker than the previous time points. At 300 days post Melarsoprol treatment, the astrocytes measured 10  $\mu\text{m}$  (mean diameter) and had short processes (mean = 2.5-5  $\mu\text{m}$ ).

#### Correlation coefficient analysis

A correlation analysis was performed between astrocytosis and other diagnostic tests to see which tests correlated best with astrocytosis hence for use in predicting presence or onset of astrocytosis. The results are summarized in table 2. CSF WBC, IgG and IgM all had high correlations ( $r > 0.5$ ,  $P < 0.05$ ) with astrocytosis and a high prediction of the same ( $r^2 > 0.5$ ,  $P < 0.05$ ). Serum IgG and IgM had weak correlations with and were poor predictors of astrocytosis ( $r^2 < 0.5$ ,  $P > 0.05$ ). IL-10, PCV and WBC values from blood samples had negative correlations with astrocytosis. Clinical signs including body temperature, respiration and lymph node enlargement were correlated with astrocytosis but were all poor predictors of

astrocytosis ( $P > 0.05$ ) with pulse rate having no correlation with astrocytosis.

**Table 2.** Correlation between astrocytosis and other diagnostic tests used in a monkey model of human African trypanosomiasis

Parameter	R	r <sup>2</sup>	P-value
CSF WBC	0.886	0.785	0.0034*
CSF IgG	0.887	0.787	0.0033*
CSF IgM	0.883	0.780	0.0036*
Serum IgG	0.407	0.166	0.3643
Serum IgM	0.532	0.283	0.1743
IL-10	-0.095	0.009	0.8225
PCV	-0.110	0.012	0.7945
WBC**	-0.799	0.638	0.0566
Body Temp	0.672	0.452	0.0679
Respiratory rate	0.588	0.346	0.1254
Pulse rate	-0.055	0.003	0.8976
Lymph node	0.514	0.264	0.1924

Key: r = Correlation coefficient, r<sup>2</sup> = coefficient of determination, \* = Significant correlations, \*\* = White blood cell from hematology.

#### Discussion

The late stage HAT involves the central nervous system (CNS) and a key event is the activation of astrocytes. Activation of astrocytes has been linked to neuroinvasion of the trypanosomes into the brain tissue and astrocytes acts as mediators of inflammation process (Kennedy et al., 2003). Once activated, the astrocytes secrete molecules such as GFAP, lipocalin 2, CXCL10 and secretory leukocyte peptidase inhibitor (SPLI) (Lee et al., 2009), which has recently been shown to be sensitive and accurate markers of late stage HAT in rats (Amin et al., 2010; Hainard et al., 2009). In the current study, astrocyte activation was first detected by the start of sampling (42 dpi) and increased in distribution in the brain and size to a peak at 98 dpi. Similar observations have been made in mice infection with *T. b. brucei* (Keita et al., 1997). There was a prominence of astrocytosis in the white mater. Previous studies points to this too since trypanosomes have been shown in brain blood vessels with

extravasation being more in the white mater (Mulenga et al., 2001). The brain of the vervet which died after MelB treatment showed severe astrocytosis and it is possible that the vervet died from post-treatment reactive encephalopathy (PTRE) which occurs following Mel B treatment (Rodgers, 2009).

The current study showed that there was a strong correlation between CSF white cell counts and astrocytosis as the disease progressed. CSF white cell counts are normally used in conjunction with presence of trypanosomes in CSF to indicate late stage disease and possibility of relapse in patients who have been earlier treated (WHO, 2006; Ngoyi et al., 2009). However, mild increase in white blood cells (<20cells/ $\mu$ l) and trypanosomes in CSF does not always result in brain parenchyma involvement. Thus, there is a need to investigate on molecules produced by pathological involvement of brain parenchyma, such as astrocytosis produced lipocalin 2, SIPI and glial fibrillary acidic protein (GFAP) and CXCL10 (Amin et al., 2010; Hainard et al., 2009).

Cerebrospinal fluid parasite-specific Immunoglobulin G (CSF IgG) and IgM strongly correlated with astrocytosis and were reliable predictors of astrocytosis. The tests had a high specificity hence good for ruling out late stage disease. Indeed, detection of intrathecal immunoglobulin M (IgM) synthesis is an accurate parameter for the detection of CNS involvement in *T. brucei gambiense* HAT cases (Lejon et al., 2002; Truc et al., 2005). Generally, only a small proportion of the very large amount of IgM produced during HAT is specific anti-trypanosome antibody (Greenwood and Whittle, 1976). However, a significant proportion of trypanosome-specific antibodies detected in the CSF are of intrathecal origin (Lambert et al., 1981; Lejon et al., 2003). The irrelevance of clinical signs in staging of HAT has also been observed on other studies (Chappuis et al., 2005; Lejon et al., 2007).

## Conclusion

Astrocyte activation in the *T.b. rhodesiense* monkey model occurred by 42 dpi and it is possible that astrocytosis could have started to occur earlier. Further studies should be

conducted to determine the earliest point at which astrocytosis occurs in this disease model. Nevertheless, any detectable levels of CSF IgG and CSF IgM as well as the number of white cell counts in CSF could be used to predict occurrence of astrocytosis, and hence late stage disease.

## Acknowledgements

This work received financial support from the government of Kenya and University of Copenhagen. The technical assistance from IPR, University of Copenhagen and TRC is gratefully acknowledged.

---

## References

- Amin D.N., Ngoyi D.M., Nkhwachi G., Palomba M., Rottenberg M., Büscher P. 2010. Identification of stage biomarkers for human African trypanosomiasis. *Am. J. Trop. Med. Hyg.* 82:983-990.
- Chappuis F., Loutan L., Simmaro P., Lejon V., Büscher P. 2005. Options for field diagnosis of human African trypanosomiasis. *Clin. Microbiol. Rev.* 18:133-146.
- Farah I.O., Ngotho M., Kariuki T.M., Jeneby M., Irura L., Maina N. Hau J. 2005. Animal models for tropical parasitic infections. *Handbook of Laboratory Animal Science*, 2nd ed., Vol. III, New York: CRC Press.
- Fink E., Schimdt H. 1980. Preclinical testing of potential trypanocidal drugs in primates. Preliminary investigations of an experimental diamidine in vervets. *In: Njogu A.R., Tukei P.M., Roberts J.M.D. (Eds.), Recent developments in medical research in East Africa. Proceedings of the 1<sup>st</sup> Annual Medical Scientific Conference of Kenya Trypanosomiasis Research Institute, KEMRI, Nairobi, 173-182.*
- Greenwood B.M., Whittle H.C. 1976. Coagulation studies in Gambian trypanosomiasis. *Am. J. Trop. Med. Hyg.* 25:390-394.
- Hainard A., Tiberti N., Robin X., Lejon V., Ngoyi D.M., Matovu E. 2009. A combined CXCL10, CXCL8 and H-FABP panel for the staging of human African trypanosomiasis patients. *PLoS Negl. Trop. Dis.* 3(6):459.
- Keita M., Bouteleille B., Enanga B., Vallat J.M., Dumas M. 1997. *Trypanosoma brucei brucei*: A long-term model of human African trypanosomiasis in mice, meningoencephalitis, astrocytosis, and

- neurological disorders. *Exp. Parasitol.* 85:183-192.
- Kennedy P.G.E., Rodgers J., Bradley B., Hunt S.P., Gettinby G., Leenman S.E. 2003. Clinical and neuroinflammatory responses to meningoencephalitis in substance P receptor knockout in mice. *Brain* 126:1683-1690.
- Kennedy P.G.E. 2004. Human African Trypanosomiasis of the CNS: current issues and challenges. *J. Clin. Investig.* 113:496-504.
- Kennedy P.G.E. 2005. Sleeping Sickness – human African trypanosomiasis. *Pract. Neurol.* 5:260-267.
- Kennedy P.G. 2008. The continuing problem of human African trypanosomiasis (sleeping sickness). *Ann. Neurol.* 64:116-126.
- Kennedy P.G. 2010. Novel biomarkers for late-stage human African trypanosomiasis – the search goes on. *Am. J. Trop. Med. Hyg.* 82:981-982.
- Lambert P.H., Berney M., Kazyumba G. 1981. Immune complexes in serum and in cerebrospinal fluid in African trypanosomiasis. Correlation with polyclonal B cell activation and with intracerebral immunoglobulin synthesis. *J. Clin. Investig.* 67:77-85.
- Lee S., Park J.Y., Lee W.H., Kim H., Park H.C., Mori K. 2009. Lipocalin-2 is an autocrine mediator of reactive astrocytosis. *J. Neurosci.* 29:234-249.
- Lejon V., Legros D., Richer M., Ruiz J.A., Jamonneau V., Truc P., Doua F., Djé N., N'Siesi F.X., Bissler S., Magnus E., Wouters I., Konings J., Vervoort T., Sultan F., Büscher P. 2002. IgM quantification in the cerebrospinal fluid of sleeping sickness patients by a latex card agglutination test. *Trop. Med. Int. Health* 7:685-692.
- Lejon V., Reiber H., Legros D., Djé N., Magnus E., Wouters I., Sindic C., Büscher P. 2003. Intrathecal immune response pattern for improved diagnosis of central nervous system involvement in trypanosomiasis. *J. Infect. Dis.* 187:1475-1483.
- Lejon V., Robays J., N'Siesi F.X., Mumba D., Hoogstoel A., Bissler S., Reiber H., Boelaert M., Büscher P. 2007. Treatment failure related to intrathecal immunoglobulin M (IgM) synthesis, cerebrospinal fluid IgM and interleukin-10 in patients with haemolymphatic-stage sleeping sickness. *Clin. Vaccine Immunol.* 14(6):732-737.
- Mulenga C., Mhlanga J.D.M., Kristensson K., Robertson B. 2001. *Trypanosoma brucei brucei* crosses the blood-brain barrier while tight junction proteins are preserved in a rat chronic disease model. *Neuropathol. App. Neurobiol.* 27:77-85.
- Ngotho M., Maina N., Kagira J., Royo F., Farah I.O., Hau J. 2006. IL-10 is up regulated in early and transitional stages in vervet monkeys experimentally infected with *T.b. rhodesiense*. *Parasitol. Int.* 55:243-248.
- Ngoyi D.M., Lejon V., N'Siesi F.X., Boelaert M., Büscher P. 2009. Comparison of operational criteria for treatment outcome in gambiense human African trypanosomiasis. *Trop. Med. Int. Health* 14:438-444.
- Rodgers J. 2009. Human African trypanosomiasis, chemotherapy and CNS disease. *J. Neuroimmunol.* 7:2.
- Schmidt H., Sayer P. 1982. *Trypanosoma brucei rhodesiense* infection in vervet monkeys. II. Provocation of the encephalitic late phase by treatment of infected monkeys. *Tropenmed. Parasitol.* 33:255-259.
- Sofroniew M.V. 2005. Reactive astrocytes in neural repair and protection. *Neurosci.* 11:400-407.
- Thuita J.K., Kagira J.M., Mwangangi D., Matovu E., Turner C.M.R., Masiga D. 2008. *Trypanosoma brucei rhodesiense* transmitted by a single tsetse fly bite in vervet monkeys as a model of human African trypanosomiasis. *PLoS Negl. Trop. Dis.* 2:238.
- Truc P., Jamonneau V., Guegan J. 2005. Confirmation of the use of Latex IgM on cerebrospinal fluid for improving stage determination of human African trypanosomiasis. *Afr. J. Biotech.* 4:517-521.
- WHO. 2006. World Health Organization African Trypanosomiasis (sleeping sickness). Fact sheet No. 259; <http://www.who.int/mediacentre/factsheets/fs259/en/>. Accessed on 1<sup>st</sup> December 2010.