

Crouzon's craniofacial dysostosis in Kenya

HARJINDER S CHANA AND VOLKER KLAUSS

From the Department of Ophthalmology, University of Nairobi, Kenya

SUMMARY A 5-year-old child with Crouzon's disease presented with luxation of the eyeballs and advanced endophthalmitis as a result of which both the eyes had to be enucleated. This case led us to study the family pedigree. The factors influencing the pattern of clinical presentation, and hence the ultimate treatment of orbital disease, are discussed. The case is presented to emphasise the different concept of ophthalmology in Africa so far as the presentation and management of orbital disease are concerned. Appropriate and timely attention could have prevented the complications in our patient.

Craniofacial dysostosis was given a definitive description in 1912 by Crouzon.^{1,2} The majority of cases are hereditary as an autosomal dominant with variable expressibility.³ Isolated cases with no family history have been reported. The orbits are shallow, with a short anteroposterior length resulting in partial dislocation of a normally growing eyeball. Optic atrophy is frequent and is often attributed to intracranial hypertension, traction on the optic nerve, and transverse narrowing of the optic foramina.⁴

Case report

A 5-year-old African girl (Fig. 1) was referred to the University Teaching Hospital from an up-country health centre for assessment and management of marked proptosis, exposure keratitis with perforated corneal ulceration, and superimposed endophthalmitis of the right eye. The left eye had been enucleated six months earlier in another hospital for a similar condition. The patient was initially taken to a local traditional doctor, who treated the eye

Correspondence to Dr HS Chana, PO Box 1250, Matare, Zimbabwe.

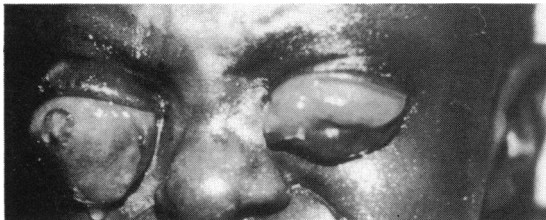

Fig. 1 The patient with right proptosis, corneal ulcer, and superimposed endophthalmitis.

condition with local herbs for four months before she first attended at our institution. Other significant findings were a high palate with deformed and crowded dental arrangement. The frog-like facies was conspicuous clinically, and the changes were confirmed by x-ray examination. There was pronounced frontal bossing, hypertelorism, and a marked hypoplasia of maxilla associated with prognathism. No syndactyly was present. No mental or neurological defects were noticed. Chromosomal studies could not be carried out owing to lack of facilities. No reconstructive surgical procedure was contemplated because of extreme destruction of the anteriorly dislocated eye with superimposed infection. The eye was enucleated.

The family's pedigree was studied (Fig. 2). The

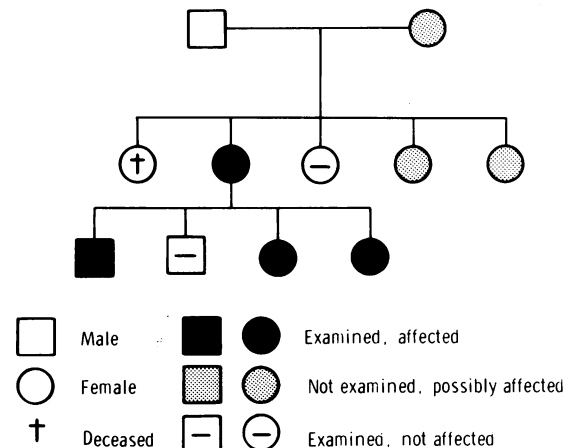


Fig. 2 The family pedigree.

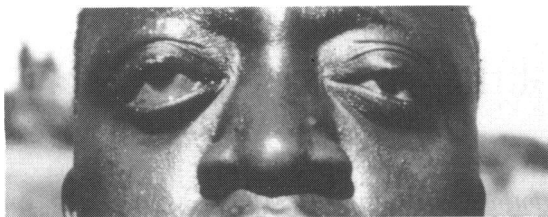

Fig. 3 The brother of the patient.

mother was asymptomatic with a corrected visual acuity of 6/18 in both eyes. She had bilateral proptosis with reduced compressibility reading 27 mm with Hertel's exophthalmometer. The lower conjunctiva showed hyperpigmentation with dilated and tortuous vessels. There was marked pallor of the temporal region of the discs, suggestive of optic atrophy. The other clinical features of Crouzon's disease were noted. The proband's brother was asymptomatic, with normal visual acuity, but had bilateral proptosis of 22 mm with moderately reduced compressibility (Fig. 3). The fundus was normal and other features of craniofacial dysostosis were seen. The younger sister of the patient also had Crouzon's disease and a right phthisical eye due to an old injury. She had a hazy keratinised cornea due to exposure keratitis in the left eye.

Discussion

The factors contributing to shallow orbits in this condition are: (1) arrested growth of the maxilla resulting in reduction of length of orbital floor; (2) a shortened anterior cranial base with depressed planum sphenoidale; (3) a forward displacement of the greater wing of the sphenoid; and (4) lateral expansion of ethmoidal cells.

The deformities of the head in all our patients were of brachycephalic type, though Blodi described various types including oxycephalic and scaphocephalic.⁵

Pneumoencephalographic assessment or CT scan are essential prior to surgical intervention. The sutures may be opened and polyethylene tubes inserted to prevent further fusion. Therapeutic orbital decompression and the use of extensive

maxillofacial osteotomies are the procedures of choice in this developmental disorder. Unfortunately our case came at a stage where even a tarsorrhaphy to save the cornea could not be carried out.

The mode of presentation and the pattern of oculo-orbital disease in Kenya differ remarkably from those in the western world owing to a multitude of factors which are summarised below. According to our experience we were not surprised that this child presented late with endophthalmitis and resultant blindness.^{6,7} Proptosis is the hallmark and the presenting sign of the orbital disease at first attendance.

The reasons for the delayed attendance are: (1) neglect and ignorance on the patient's part; (2) misdiagnosis in rural health centres leading to delayed referral; (3) lack of ophthalmologists in rural areas: in the whole country there is one Kenyan ophthalmologist to 950 000 people; (4) the role played by the witch doctors and herbalists with whom the initial treatment is sought is very significant (tribal rituals and customs are still very common in certain tribes); (5) expensive and difficult transport to the nearest hospital with ophthalmic and other medical facilities; (6) the dominant role played by the husband or father, who is the only member of the household who can give consent to surgery and who often is not easily available.

The authors are indebted to Professor Gordon Johnson, Director, Institute of Preventive Ophthalmology, University of London, for his guidance in preparation of this manuscript.

References

- 1 Crouzon O. Dysostose cranio-faciale héréditaire. *Bull Soc Med Paris* 1912; **33**: 545-55.
- 2 Crouzon O. Une nouvelle famille atteinte de dysostose cranio-faciale héréditaire. *Arch Med Enf (Paris)* 1915; **18**: 540-3.
- 3 Atkinson FRB. Hereditary cranio-facial dysostosis or Crouzon's disease. *Med Press* 1937; **195**: 118-24.
- 4 Miller M, Pruzansky S. Cranio-facial anomalies. *Principles and practice of ophthalmology*. Philadelphia: Saunders, 1980; **3**: 2367.
- 5 Blodi FC. Developmental anomalies of the skull affecting the eye. *Arch Ophthalmol* 1957; **57**: 593.
- 6 Klauss V, Chana HS. Orbitotumoren im Kenyatta National Hospital von 1978 bis 1981. *Fortschr Ophthalmol* 1982; **79**: 62-5.
- 7 Klauss V, Chana HS. Oculo-orbital tumours in Africa. *Soc Sci Med* 1983; **17**: 1743-50.

Accepted for publication 31 December 1986.