

East African Medical Journal Vol. 84 No. 12 December 2007

CHEILITIS GLANDULARIS PROGRESSING TO SQUAMOUS CELL CARCINOMA IN AN HIV-INFECTED PATIENT: CASE REPORT

F.M.A. Butt, BDS (UoN), FSRCS (Eng), MDS-OMFS (UoN), Consultant, M. L. Chindia, BDS (UoN), MSc, FFDRCSI, Associate Professor, Department of Oral & Maxillofacial Surgery, College of Health Sciences, University of Nairobi, P. O. Box 19676-00202, Nairobi, Kenya, F.S. Rana, MBChB (UoN), MMed Path (UoN), Consultant Pathologist, Aga Khan University Hospital, Nairobi, P. O. Box 30220-00110, Nairobi, Kenya and A. Ashani, BDS (UoN), Dental Surgeon, Kenyatta National Hospital, P.O. Box 20723-00202, Nairobi, Kenya

Request for reprints to: Dr. F. M. A. Butt, P.O. Box 25361-00603, Nairobi, Kenya

CHEILITIS GLANDULARIS PROGRESSING TO SQUAMOUS CELL CARCINOMA IN AN HIV-INFECTED PATIENT: CASE REPORT

F.M.A. BUTT, M. L. CHINDIA, F.S. RANA and A. ASHANI

SUMMARY

Cheilitis glandularis (CG), is a rare inflammatory minor salivary gland disease affecting the lower lip. The hallmarks of which include progressive enlargement and eversion of the lower labial mucosa resulting in the obliteration of the mucosal-vermillion interface. A case is presented of a 47-year-old HIV-infected woman who initially manifested clinical features of CG with a typical histopathology picture of a non-specific sialadenitis while a second biopsy performed six months later revealed well differentiated squamous cell carcinoma (SCC). She is symptom free one year following excision and radiotherapy treatment.

INTRODUCTION

Cheilitis glandularis (CG) is a rare disease of unknown aetiology characterised by progressive enlargement and ulceration of the lips in adults. It is a clinically distinct inflammatory condition characterised by mucopurulent exudates from ductal orifices of the labial minor salivary glands. It may be asymptomatic, or progress with a burning sensation attributed to the rawness of the vermillion border as a result of atrophy, speckled leukoplakia, erosion or frank ulceration with crusting (1).

Clinically the lesion appears as a multinodular enlargement causing eversion and induration of the lip (2). Although it commonly affects the lower lip in males, there have been occasional reports of CG affecting the upper lips and palate in young children and females (3). However, the condition occurs between the fourth and seventh decades of life and has been associated with bacterial infection. There has been a case documented with features of CG presenting in an HIV-infected patient. Although the association may have been coincidental, the

compromised immune status cannot be disregarded in the presence of malignancy (4).

We present a second case report of an HIV-infected patient who manifested clinical features of CG with the initial histopathological examination showing a non-specific sialadenitis while a second biopsy performed six months later revealed features of SCC.

CASE REPORT

A female aged 47 years old and HIV seropositive presented to the Kenyatta National Hospital (KNH), Oral and Maxillofacial clinic complaining of pain, oozing of pus and swelling of the lower lip. This had been progressive for two months (Figure 1). She had previously attended a private clinic for treatment of the same with little relief. The patient had a history of alcohol consumption (3-4 units/week) for 20 years but denied use of tobacco or any illicit drugs. She stopped alcohol consumption when she learnt about her HIV serological status and began anti-retroviral therapy.

Figure 1

Suppurative swelling with ulceration of the lower lip causing eversion

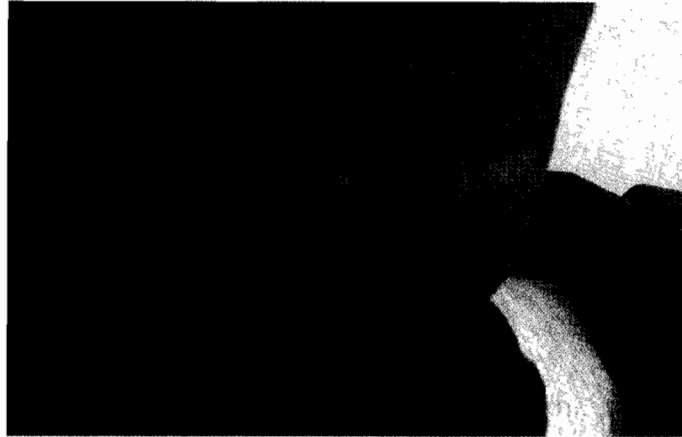

Figure 2

Initial histopathology of the lesion

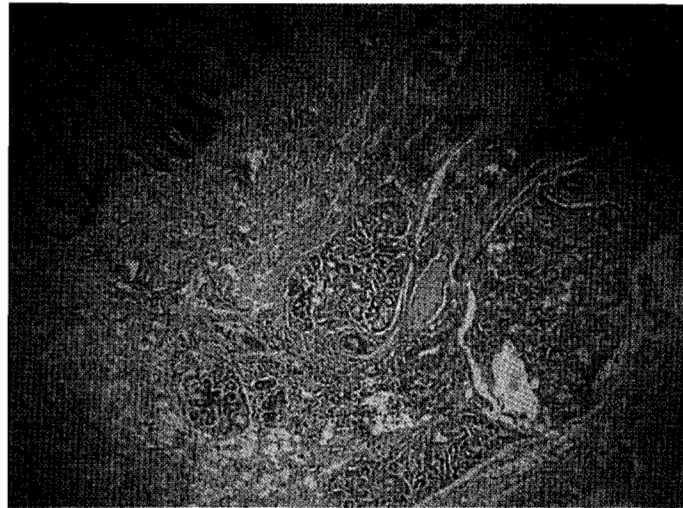
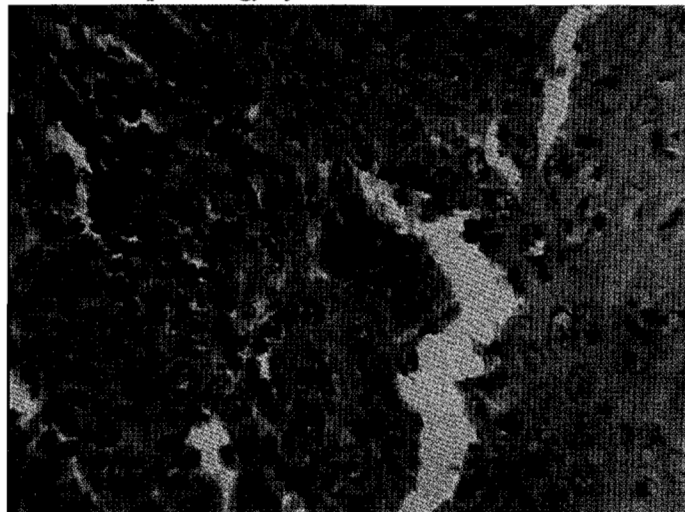

Figure 3

Histopathology of the lesion six months later



Clinical examination revealed a middle-aged woman in fair general condition. She had a right palpable submandibular lymph node which was, mobile and tender, measuring 1cm in its widest diameter. The lower lip was asymmetric with an irregular, nodular, suppurative swelling extending from the commissure to the mid-line causing eversion. Oral examination showed a fair oral hygiene with mild generalised gingivitis. The differentials included CG, actinic cheilitis, sialadenitis and bacterial cellulitis. Under local anaesthesia an excisional biopsy (vermillionectomy or cheillorrhaphy) was taken for histopathological analysis. She received a prescription of 1gm augmentin twice a day and 400 mg of metronidazole three times a day for seven days. The CD+ T-lymphocyte cell count was 98 cells/mm³. The histopathological examination revealed a "benign squamous epithelium below which there was active chronic inflammation with salivary gland tissue showing periductal inflammation consistent with features of non-specific sialadenitis" (Figure 2). A review one week after starting antibiotics showed, both the lip swelling and previously palpable submandibular lymph node had reduced in size considerably. She got lost to follow up for six months. At this time she presented with an apparent recurrence of the swelling and needed aesthetic surgery. After counseling she consented to a repeat biopsy of the lesion. Histological diagnosis reported a poorly differentiated SCC (Figure 3). Subsequently the tumour was resected, with a supra-omohyoid neck dissection and the patient sent for post-operative radiotherapy. A year later the patient remained in good condition, the CD+ T-lymphocyte cell count was at 240 cells/mm³, as she continues the anti-retroviral treatment.

DISCUSSION

Cheilitis glandularis is classified into three types on the basis of the severity of the disease: simplex, superficial suppurative and deep suppurative. The deep suppurative type also termed as cheilitis apostematosa or myxadenitis labialis has been associated with severe epithelial dysplasia and SCC (5-7). Most of the cases reported as CG in which carcinoma developed were of the deep suppurative type (8). In many cases, dysplastic (pre-malignant) surface epithelial change is evident histopathologically; and frank carcinomas have been reported in 18-35% of the cases (9). Our case fits this description. The aetiology of CG remains elusive although associations with syphilis, bacterial infections, poor oral hygiene, tobacco consumption,

sunlight exposure and immunosuppression have been suggested (1,6,5,10,11). Most of the features were documented about this case. Patients with CG of the deep suppurative type are closely monitored due to the close association of developing into a SCC, and in the background of a compromised immune system the development of a malignancy becomes several folds (12). Hence, a close follow-up is mandatory to monitor any suspicious progression into a carcinoma.

Clinically there are usually several differential diagnosis to be considered however they are eliminated by a histopathological assessment. Like in this present case the lesion, underwent a transition from the superficial to a deep suppurative type which then showed the dysplastic changes. Furthermore, it has been demonstrated that HIV infection and subsequent immunosuppression results in an increased risk of developing malignant disease (13). Perhaps, the consumption of alcohol, a known carcinogen may also have propagated and accelerated the dysplastic change into carcinoma. The treatment for the majority of such lesions is symptomatic until frank carcinoma is demonstrated.

Conclusion is not documented as an oral manifestation of HIV-infection according to the WHO classification. However, it is prudent to record such uncommon lesions that manifest in those infected as the epidemic rages on. In the background of HIV infection a diagnosis of cheilitis glandularis should be viewed with a high index of suspicion as the immunosuppression may propagate its progression into a squamous cell carcinoma as highlighted by this case report.

ACKNOWLEDGEMENTS

To the administration and Department of Dental Surgery at the Kenyatta National Hospital for permission to document this case report. We would also like to express our gratitude to the laboratory staff at the MP Shah hospital for having prepared the slides.

REFERENCES

1. Volkman, R.V. Einige fälle von cheilitis glandularis apostematosa. *Arch. Pathol. Anat.* 1870; 50:142-144.
2. Musa, N. J., Suresh, L., Hatton, M. *et al.* Multiple suppurative cystic lesions of the lips and buccal mucosa: a case of suppurative stomatitis glandularis. *Oral Surg and Oral Med. Oral Pathol. Endod.* 2005; 99:175-179.

3. Yakobi, R. and Brown, O. A. Cheilitis glandularis: a paediatric case report. *J. Am. Dent. Assoc.* 1989; **118**: 317-318.
4. Jair, C. Leao., Ferreira, A. M. C., Sarita, M., et al. Cheilitis glandularis: An unusual presentation in a patient with HIV infection. *Oral Surg. Oral Med. Oral Pathol. Endod.* 2003; **95**:142-144.
5. Weir, T. W. and Johnson, W. C. Cheilitis glandularis. *J. Oral Med.* 1971; **103**:433-437.
6. Rogers, III R. S. and Beckic, M. Diseases of the lips. *Sem. Cut. Med. and Surg.* 1997; **26**:328-336.
7. Oliver, I.D. and Pickett, A. B. Cheilitis glandularis. *Oral Surg. Oral Med. Oral Pathol.* 1980;**49**: 526-529.
8. Lederman, D. A. Suppurative stomatitis glandularis. *Oral. Surg. Oral Med. Oral Pathol.* 1994; **78**: 319-322.
9. Doku, H. C. Cheilitis glandularis. *Oral Surg. Oral Med. Oral Pathol.* 1965; **20**:563-571.
10. Everett, F.G. and Holder, D. Cheilitis glandularis apostematosa. *Oral Surg. Oral Med. Oral Pathol.* 1955; **8**:405-413.
11. Rada, D. C. Cheilitis glandularis: a disorder of ductal ectasia. *J. Dermatol. Surg. Oncol.* 1985; **11**: 372-375.
12. Stuller, C.B. Schaberg, S.J. Stokos, J, and Pierce, G.L. Cheilitis glandularis. *Oral Surg.* 1982;**53**:602-605.
13. Epstein, J. B. and Scully, C. Neoplastic diseases in head and neck of patients with AIDS. *Int. J. Oral Maxillofac. Surg.* 1992; **21**:219-226.