



CASE REPORT

Fatal Obstructive Urolithiasis in a 5 Months Old Buck: A Case Report

¹P Kimeli*, ¹AN Kipyegon and ²DN Karanja

¹Department of Clinical Studies; ²Department of Veterinary Pathology, Microbiology and Parasitology, Faculty of Veterinary Medicine, University of Nairobi, P.O. Box 29053- 00625, Kangemi, Kenya

ARTICLE INFO

Received: January 21, 2014
Revised: February 04, 2014
Accepted: February 22, 2014

Key words:

Mortality
Pet goat
Uroliths
Uroperitoneum

*Corresponding Author

P Kimeli
kimeli08@yahoo.com

ABSTRACT

A case of fatal obstructive urolithiasis was reported in a 5 months old buck of non-descript local breed kept as a pet. The affected animal was noticed to have developed an episodic abdominal distention and anorexia. The main presenting clinical signs were recumbency, tachycardia, tachypnea, hypothermia and slight congestion of conjunctival mucous membranes. The animal's condition deteriorated markedly and died despite treatment attempts to stabilize. Autopsy revealed subcuticular edema, dark red peritoneal fluid, several pea size stones in the peritoneal cavity, ruptured urinary bladder with two patches of paleness surrounded by hyperemia on its mucosa and prominent ureters. Stones were also observed at the proximal sigmoid flexure and there was hyperemia proximal to the point of obstruction.

Cite This Article as: Kimeli P, AN Kipyegon and DN Karanja, 2014. Fatal obstructive urolithiasis in a 5 months old buck: a case report. *Inter J Vet Sci*, 3(1): 40-42. www.ijvets.com

INTRODUCTION

Uroliths are concretions of solid mineral and organic compounds that cause disease through direct trauma to the urinary tract and obstruction of urinary outflow (Kalim *et al.*, 2011). They are commonly found in the urinary bladder but have also been reported to occur in the urethra at the point of the sigmoid flexure (Singh and Singh, 1990) and urethral process (Kannan and Lawrence, 2010). Urinary calculi formation is complex and multifactorial (Radostits *et al.*, 2005), resulting from a combination of physiologic, nutritional and management factors, although mainly attributed to excessive or imbalanced intake of minerals (Radostits *et al.*, 2000; Hesse *et al.*, 2009). There are different types of urine stones including struvite, calcium oxalate, calcium carbonate, calcium phosphate, silica, uric acid, cystine and tyrosine crystals (Samal *et al.*, 2011). The alkaline pH (pH>8.0) of urine favors the formation of phosphate, carbonate and struvite calculi while acidic pH (pH<7.0) predisposes to urate and silicate calculi (Pugh, 2002).

Urolithiasis is a common problem in castrated male sheep, goats and cattle (Makhdoomi and Gazi, 2013), the incidence in goats is the highest and has been reported to be about 49.3% (Amarpal *et al.*, 2004). Obstructive urolithiasis means the formation of calculi in the urinary tract with subsequent urinary blockage by uroliths (Radostits *et al.*, 2000), which is a life-threatening

condition in males. Mortality rate is very high in affected animals due to rupture of the urethra or urinary bladder (Gasthuys *et al.*, 1993).

Even though almost all the calculi are amenable to surgical intervention, in a considerable proportion of operated animals, post-surgical complications like urethral stricture (Samal *et al.*, 2011; Kinjavdekar *et al.*, 2005) may ensue making the prognosis for urolithiasis poor (Sharma, 2009). This study reports a case of fatal urinary bladder rupture due to obstructive urolithiasis in a 5 month old buck.

Case history and finding

A 5 month old buck of non-descript local breed kept as a pet was reported with a primary complaint of anorexia and abdominal distention lasting two days, then seemed to have resolved but recurred on the fourth day. The animal had been feeding on commercial concentrates, cereal grains and pasture grass consisting mainly of *Pennisetum clandestinum*. On clinical examination, there was recumbency, tachycardia, tachypnea, hypothermia and slight congestion of conjunctival mucous membranes. The buck's condition deteriorated markedly and died despite attempts to stabilize.

Autopsy revealed dark red peritoneal fluid and subcuticular edema, several pea size stones observed in the peritoneal cavity, ruptured urinary bladder with two large patches of paleness surrounded by hyperemia on its

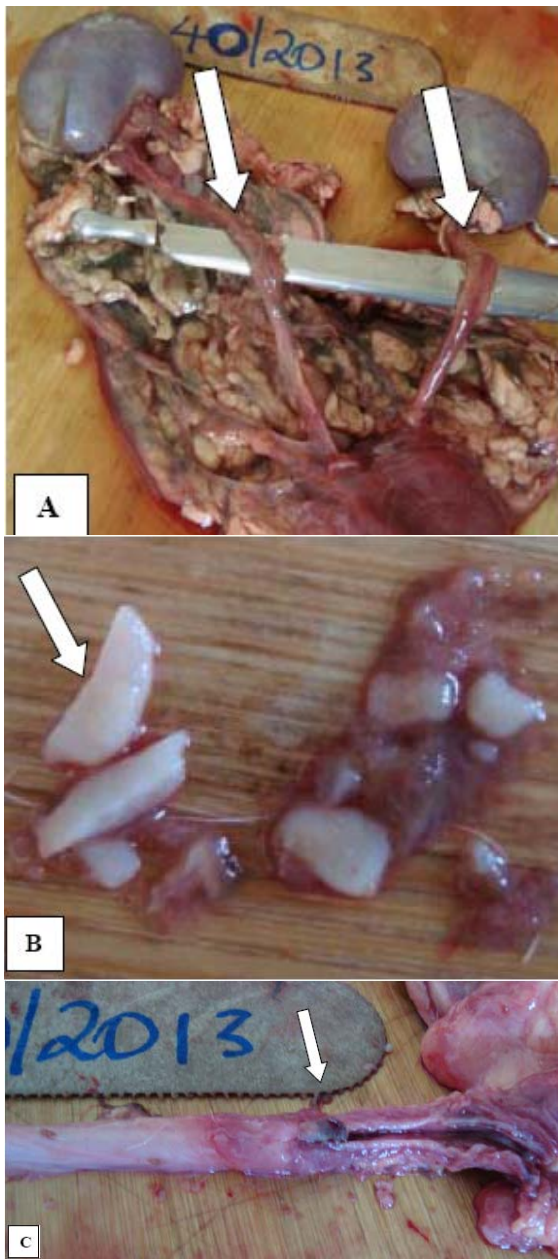


Fig. 1: Autopsy lesions observed in a case of Fatal Obstructive Urolithiasis in a 5 months old buck. **A-** prominent ureters, **B-** Stones recovered at autopsy **C-** hyperemia proximal to the point of obstruction at the proximal sigmoid flexure of the penis.

mucosa and prominent ureters. Stones were also observed at the proximal sigmoid flexure and there was hyperemia proximal to the point of obstruction.

DISCUSSION

To the researcher's knowledge, this is the first reported case of fatal obstructive urolithiasis in a 5 month old buck in Kenya. Over the years, cases of urolithiasis in small ruminants have been successfully managed surgically (Kinjavdekar *et al.*, 2005), although post-surgical complications like urethral stricture (Samal *et al.*, 2011; Kinjavdekar *et al.*, 2005) may occur.

Several risk factors predispose the formation of uroliths in ruminants, chief among which, diet plays a significant role (Jones *et al.*, 2009) with concentrates reported to be always associated with uroliths formation in ruminants (Matthews, 2009). In the present case, the pet buck was fed on cereal grains and concentrates which may have led to imbalances in the calcium: phosphorus ratio which has been implicated in uroliths formation (Bassett, 2009). It has been reported that obstructive urolithiasis is common in castrated adults (Van Metre and Divers, 2002; Samal *et al.*, 2011; Raza *et al.*, 2012) which was not the case in the current study.

Obstructive urolithiasis is easily diagnosed from the clinical signs as reviewed by Makhdoomi and Gazi (2013). The history of episodic abdominal distension reported in this case was due to rectal obstruction by the distended urinary bladder and later due to uroperitoneum; a sequel to rupture of the urinary bladder. The researchers believe that mortality was due to respiratory distress caused by fluid pressure on the diaphragm, peritonitis and toxemia due to reabsorption of urinary toxins.

The intra-cystic and intra-urethral pressure may have led to retrograde urine flow, leading to the prominence of the ureters, noted at autopsy. The overstretching of the urinary bladder caused by an increase in intra-cystic pressure may have caused pressure necrosis of the urinary bladder mucosa leading to the reported pale patches and rupture.

In conclusion, fatal obstructive urolithiasis can occur in a 5 month old intact male goat, especially those kept as pets. It is important to monitor and minimize feed that might predispose pet goats to urolithiasis. Familiarizing owners on the signs and indications of obstructive urolithiasis is also necessary to allow early reporting which in turn would improve the prognosis of treatment.

REFERENCES

- Amarpal, P Kinjavdekar, HP Aithal, AM Pawde, Tarunbir, Singh, K Pratap and T Singh, 2004. Incidence of urolithiasis: a retrospective study of five years. *Indian J Anim Sci*, 74: 175-177.
- Bassett A, 2009. Urinary Calculi in Goats, Animal Welfare Approved Technical Advice Fact Sheet No. 3.
- Gasthuys F, M Steenhaut, A De Moor and K Sercu, 1993. Surgical treatment of urethral obstruction due to urolithiasis in male cattle: a review of 85 cases. *Vet Rec*, 133: 522-526.
- Hesse AT, HG Tiselius and R Siener, 2009. Urinary Stones, Diagnosis, Treatment and Prevention of Recurrence. 3rd edn. Basel, S Karger AG ISBN 978-3-8055-9149-2.
- Jones ML, RN Streeter and CL Goad, 2009. Use of dietary cation anion difference for control of urolithiasis risk factors in goats. *Am J Vet Res*, 70: 149-155.
- Kalim MO, R Zaman and SK Tiwari, 2011. Surgical Management of Obstructive Urolithiasis in a male Cow calf. *Vet World*, 4: 213-214.
- Kannan KVA and KE Lawrence, 2010. Obstructive urolithiasis in a Saanen goat in New Zealand,

- resulting in a ruptured bladder, New Zealand Vet J, 58: 269-271.
- Kinjavdekar P, HP Amarpal, AM Aithal, K Pawde, TS Partap and K Singh, 2005. Management of urolithiasis in goats (*Capra hircus*)-A retrospective study of 25 cases. Indian J Anim Res, 39: 8-13.
- Makhdoomi DM and MA Gazi, 2013. Obstructive urolithiasis in ruminants - A Rev Vet World, 6: 233-238.
- Matthews JG, 2009. Colic, Diseases of the Goat, Wiley-Blackwell, 3: 277-89.
- Pugh DG, 2002. Sheep and Goat Medicine, 1st Ed. Elsevier Publishing Co, Philadelphia, USA.
- Radostitis OM, DC Blood, GC Gray and KW Hinchcliff, 2005. Veterinary Medicine a text book of the disease of cattle, sheep, pig, goat and horse. Bailliere Tindall, London, pp: 1877.
- Radostits OM, DC Blood, CC Gay and KW Hinchcliff, 2000. Urinary System. In: Veterinary Medicine: A textbook of the diseases of cattle, sheep, pigs, goats and horses. Bailliere Tindall, London, pp: 1877.
- Raza A, M Ghulam, M Asad, A Mansoor and I Misbah, 2012. Clinical efficacy of allopurinol and ketoprofen in the treatment of urate associated urolithiasis in bucks-case report, Inter J Mol Vet Res, 2: 22-24.
- Samal L, AK Pattanaik, C Mishra, BR Maharana, LN Sarangi and RK Baithalu, 2011. Nutritional strategies to prevent urolithiasis in animals. Vet World, 4: 142-144.
- Sharma AK, J Mohindroo and HP Aithal, 2009. Physiological, urological changes and surgical management of urethral obstruction in bovine 25 cases (2001-2006). J Am Vet Med Assoc, 234: 249-252.
- Singh J and K Singh, 1990. Obstructive Urolithiasis and Uraemia in Cattle and Buffaloes. A Review. Indian J Vet Surg, 11: 1-20.
- Van Metre DC and TJ Divers, 2002. Large Animal Internal Medicine. Mosby, St Louis, Missouri, pp: 853-860.