

## **Endovascular Overlapping Stenting for Chronic Left Common Iliac Vein Occlusion in May Turner Syndrome: A Case report:**

### **P.C. Magabe**

Lecturer, Vascular and Interventional Radiologist, University of Nairobi and Kenyatta National Hospital.

**Correspondence to:** Dr Peter Chacha Magabe, Email: cmagabe@yahoo.co.uk

*A 30 year old female was referred to the interventional radiology service with a history of persisting left lower limb swelling with an associated ulcer in the distal medial aspect of the leg. She had been evaluated at an outside medical facility and treated several times with warfarin for recurring deep vein thrombosis [DVT]. A Doppler US examination did not show any current DVT in the affected lower limb. A CT venogram showed compression of the left common iliac vein at the point where the right common iliac artery crossed it anteriorly, highly suggestive of May Turner Syndrome [MTS]. No intraluminal thrombus was demonstrated in the segment of the left common iliac vein distal to the obstruction. A conventional DSA venography confirmed total chronic occlusion of the proximal left common iliac vein by the overlying right common iliac artery with multiple pelvic venous collaterals confirming the diagnosis of MTS. The patient subsequently underwent successful endovascular stenting of the left iliac vein with two overlapping self expandable stents. The limb swelling gradually subsided and the venous ulcer healed. There has been no recurrence of the DVT in the subsequent one year follow up.*

### **Introduction**

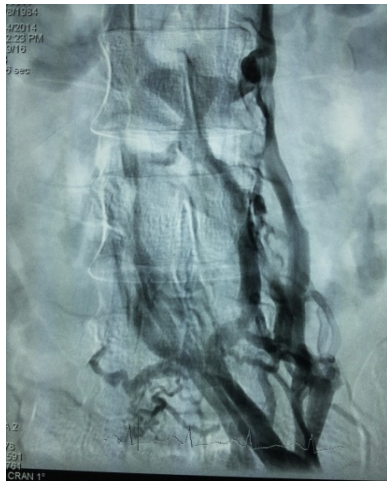May Turner Syndrome also called iliac vein compression syndrome is a rarely diagnosed condition in which patients develop iliofemoral deep venous thrombosis [DVT] due to an anatomical variant in which the right common iliac artery overlies and compresses the left common iliac vein against the lumbar spine. It is rarely considered in the differential diagnosis of DVT, particularly in patients with other risk factors. Systemic anticoagulation alone is insufficient treatment, and a more aggressive approach is necessary to prevent recurrent DVT. Endovascular stenting across the stenotic segment of the iliac vein is currently an accepted modality of treatment. A single stent across the stenotic segment of the vein is usually sufficient and widely practiced, but may be associated with early re-stenosis. Presented in this review, is a case in which a second overlapping stent was used to increase radial strength within the lumen of the vein and increase the long term patency.

### **Case Report**

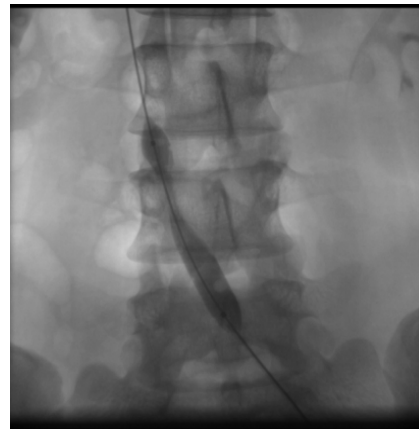A 30 year old female was referred to the interventional radiology service at Kenyatta National Hospital with a history of persisting left lower limb swelling with an associated ulcer in the distal medial leg. She had been evaluated and treated several times for recurring deep vein thrombosis [DVT] of the left lower limb at an outside medical facility with warfarin, an oral anticoagulant. There was no clinical improvement after completing systemic anticoagulation with warfarin. Swelling and pain persisted and patient could not walk unaided. A current Doppler US examination did not show any DVT in the affected lower limb. A CT venography done thereafter showed compression of the left common iliac vein at its entry into the inferior vena cava (IVC), just as the right common iliac artery crossed it, highly suggestive of May Turner Syndrome [MTS]. No intraluminal thrombus was demonstrated in the segment of the left common iliac vein distal to the obstruction.

A conventional DSA venography confirmed total chronic occlusion of the proximal left common iliac vein by the overlying right common iliac artery with multiple pelvic venous collaterals,

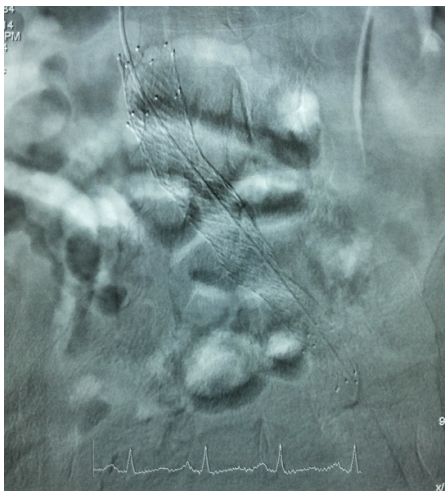
confirming the diagnosis of MTS (Figure1).The patient subsequently underwent endovascular stenting of the left common iliac vein with two overlapping self expandable stents. The vein was initially dilated with 10 by 80mm balloon (cordis, Europe) via a left common femoral vein puncture (Figure 2). This was followed by 12 by 60 mm one, and finally a 14 by 40 mm balloon. Venogram done immediately after balloon angioplasty showed good blood flow through the occluded segment .To maintain patency a 14mm by 80mm self expanding bare stent [smart stent, cordis Europe] was deployed across the original occluded segment with proximal tip at the IVC-left common iliac vein junction.



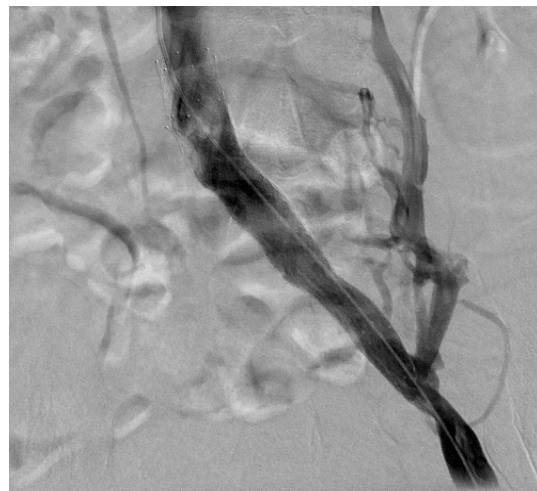
**Figure 1.** Conventional DSA angiogram through the left femoral vein shows total occlusion of the proximal left common iliac vein at L5 level. Multiple pelvic venous collaterals are seen arising from the point of occlusion.



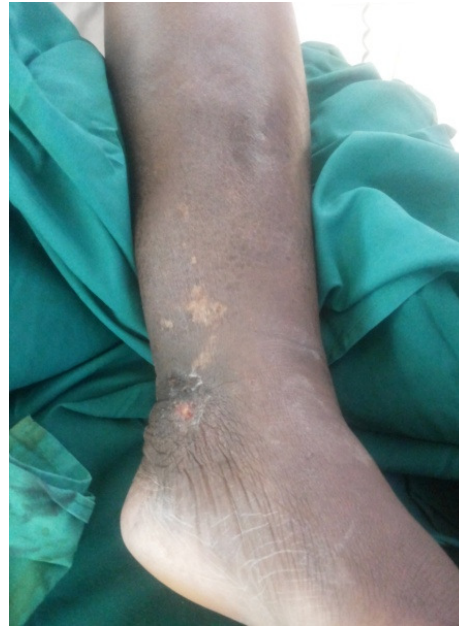**Figure 2.** Balloon dilatation of the left common iliac vein occlusion. The point of occlusion forms a waist around the balloon .This was successfully dilated using 10mm and 14 mm diameter balloons



**Figure 3.** Overlapping self expandable stents subsequently deployed across the venous occlusion. The second stent overlaps towards the distal aspect of the vein and into the left external iliac vein.



**Figure 4.** DSA venogram immediately after the venogram shows good venous inflow through the left common iliac vein.



**Figure 5.** Photograph of the medial aspect of distal left leg shows the ulcer associated with proximal left common iliac vein occlusion. The ulcer had started drying up 24 hours after the stenting

To maintain radial strength against the pulsation of the overlying right common iliac artery, a second similar self expandable stent was deployment about 2 cm below the tip of the first stent (Figure 3). A final DSA venogram (Figure 4) showed good venous inflow into the IVC with non visualization of most of the pelvic venous collaterals. A Doppler ultra sonography done 24 hours after the procedure showed a patent left common iliac vein with a normal biphasic flow pattern. The wet venous ulcer had started drying up. A subsequent follow up CT venogram at 3, 6 and 12 months showed patent left common iliac vein .The left lower limb swelling had gradually resolved and venous ulcer in the distal medial leg completely healed. There were no pain symptoms and patient had returned to normal walking and use of the left lower limb.

### Discussion

May turner syndrome results from chronic pulsatile compression of the left common iliac vein between the crossing right common iliac artery and the lower lumbar vertebral body. This induces focal intimal proliferation of the vein which forms an intimal spur. It is this spur rather than direct arterial pressure that results in impaired venous return and thrombosis. The spur also differentiates MTS related DVT from bland DVT. The left iliac vein is more predisposed to compression by the iliac artery because it has a more transverse course than the right which ascends more vertically<sup>1,2</sup>. This anatomic variant has been shown to be present in over 20% of the population mostly the young ages 25-50 years.

The condition was first described in 1957 in which 22% of 430 cadavers on autopsy had an anatomical variant in which an overriding right common iliac artery caused compression of the left common iliac vein against the lumbar spine<sup>3</sup>. More recently, a similar prevalence [22%-24%] of MTS was reported in a retrospective analysis of an asymptomatic population at CT demography<sup>4</sup>.

MTS-related DVT is however low, forming about 2% to 3% of all lower extremity DVTs .This is despite of the relatively high prevalence of MTS.

Untreated MTS may lead to recurrence of DVT like in this patient, pulmonary embolism; chronic venous stasis and iliac vein rupture. About 28% of patients with iliac vein rupture have MTS<sup>5,6</sup>. Treatment of MTS has evolved from surgical retropositioning of the overriding vessel, venovenous bypass to open repair of the affected vein<sup>7-9</sup>. The current mainstay treatment is however endovascular intervention. If concurrent DVT is present catheter-directed thrombolysis combined with percutaneous mechanical thrombectomy is done<sup>2</sup>. An inferior vena cava filter will have to be placed prior to endovascular intervention to prevent pulmonary embolism.

This is then followed by deployment of large (12-14 mm) self-expanding stents, placed across the extent of the stenosis and extending into the inferior vena cava, if possible, to prevent migration<sup>10</sup>. In this patient, a second overlapping stent was used to increase radial strength within the vein therefore reduce restenosis rate. The second stent also helps to stabilize the first proximal stent within the vein; preventing proximal migration which can be catastrophic. Stent placement has proven highly successful in MTS, with a 2-year iliac vein patency rates reported between 95% and 100%<sup>11</sup>. Following stent placement, systemic long-term anticoagulation is recommended for at least 6 months<sup>2</sup>. The patient presented here was put on long term dual anti platelet therapy (aspirin and clopidogrel) to prevent thrombosis within the stents.

### Conclusion

Endovascular overlapping venous stenting in May-Turner syndrome is technically feasible, and leads to reduction of symptoms in the majority of patients with high patency rates in the long term. This approach has been proven to be safe, efficient and alternative to surgical treatment.

### References

1. O'Sullivan GJ, Semba CP, Bittner CA, Kee ST, Razavi MK, Sze DY, Dake MD. Endovascular management of iliac vein compression [May-Thurner] syndrome. *J Vasc Interv Radiol*. 2000; 11(7):823-836.
2. Moudgill N, Hager E, Gonsalves C, Larson R, Lombardi J, DiMuzio P. May-Thurner syndrome: case report and review of the literature involving modern endovascular therapy. *Vascular*. 2009; 17(6):330-335.
3. May R, Thurner J. The cause of the predominantly sinistral occurrence of thrombosis of the pelvic veins. *Angiology*. 1957; 8(5):419-427.
4. Kibbe MR, Ujiki M, Goodwin AL, Eskandari M, Yao J, Matsumura J. Iliac vein compression in an asymptomatic patient population. *J Vasc Surg*. 2004; 39(5):937-943.
5. Kim JY, Choi D, Guk Ko Y, Park S, Jang Y, Lee do Y. Percutaneous treatment of deep vein thrombosis in May-Thurner syndrome. *Cardiovasc Intervent Radiol*. 2006; 29(4):571-575.
6. Jiang J, Ding X, Zhang G, Su Q, Wang Z, Hu S. Spontaneous retroperitoneal hematoma associated with iliac vein rupture. *J Vasc Surg*. 2010; 52(5):1278-1282.
7. Palma E, Esperon R. Vein transplants and grafts in the surgical treatment of the postphlebotic syndrome. *J Cardiovasc Surg [Torino]* 1960; 1:94-107.
8. Fazel R, Froehlich JB, Williams DM, Saint S, Nallamotheu BK. Clinical problem-solving. A sinister development-a 35-year-old woman presented to the emergency department with a 2-day history of progressive swelling and pain in her left leg, without antecedent trauma. *N Engl J Med*. 2007; 357(1):53-59.
9. Suwanabol PA, Tefera G, Schwarze ML. Syndromes associated with the deep veins: phlegmasia cerulea dolens, May-Thurner syndrome, and nutcracker syndrome. *Perspect Vasc Surg Endovasc Ther*. 2010; 22(4):223-230.



10. Calnan JS, Kountz S, Pentecost BL, Shillingford JP, Steiner RE. Venous obstruction in the aetiology of lymphoedema praecox. *Br Med J.* 1964;2(5403):221-226.
11. Hölper P, Kotelis D, Attigah N, Hyhlik-Dürr A, Böckler D. Longterm results after surgical thrombectomy and simultaneous stenting for symptomatic iliofemoral venous thrombosis. *Eur J Vasc Endovasc Surg.* 2010; 39(3):349-355.