

VARIATIONS IN BRANCHING PATTERN OF EXTERNAL CAROTID ARTERY IN A BLACK KENYAN POPULATION

Julius A. Ogeng'o, Musa K. Misiani, Poonamjeet Loyal, Kevin W. Ongeti, Jacob Gimongo, Martin I. Inyimili, Acleus K. Murunga

Corresponding Author: Musa Misiani Department of Human Anatomy, University of Nairobi P. O. Box 00100 – 30197 Nairobi, Kenya.

SUMMARY

Knowledge of variations in branching of external carotid artery is important to minimise inadvertent injury and confusion in identification during neck and craniofacial surgery and interventional neuroradiology. These variations show ethnic differences. Procedures in head and neck are increasing but data on these variations among black populations are scarce. This study therefore examined the branching pattern of external carotid artery in a black Kenyan population. Two hundred and twenty-four common carotid arteries of 112 black adult Kenyans were exposed by cadaveric dissection at Department of Human Anatomy, University of Nairobi, Kenya. The sternocleidomastoid muscle and body of mandible were removed and the external carotid artery and its branches exposed. The conventional pattern of branching was observed in only 41.1% of cases. The variant patterns observed were trifurcation (26.8%), bifurcation (17.9%) and quadrifurcation (8.9%). There were 20 (5.3%) cases of early division. Linguo-facial trunk was observed in 44.7% cases. Frequency of variant branching pattern of external carotid artery in the population studied is high. Interventional radiologists, vascular, craniofacial and neck surgeons should be aware of these. Preoperative sonographic evaluation of the carotid arterial system is recommended.

Key words: External carotid artery, Variation, Trifurcation, Quadrifurcation, African.

INTRODUCTION

Knowledge of branching pattern of external carotid artery (ECA) is essential during planning for reconstructive surgery of the neck and head (Hoffer et al., 2005; Joshi et al., 2005; Pinar and Gousar, 2006), accurate interpretation of radiological images of these areas; precise diagnosis and safe surgical approach to this region (Thwin et al., 2010; Delic et al., 2010); diagnostic imaging, vascular surgical procedures such as carotid endarterectomy or radical neck dissection, catheterization and aneurysm repair (Ozgur et al., 2008a); and interventional neuroradiology and less invasive treatment of neck masses (Satogani et al., 2009; Namatha et al., 2010). It is important to know the frequency of these, fairly common variations in order to minimize inadvertent injury (Sanjeev et al.,

2010; Panagouli et al., 2011) and difficulty in differentiating between internal and external carotid, and in identifying the branches and their origins. Site and pattern of origin of individual branches is especially important during selective intraarterial infusion of chemotherapy for treatment of head and neck tumors (Nakasato et al., 2000). Further, branches of ECA are key landmarks for adequate dissection for exposure and appropriate placement of cross clamps on the carotid arteries or catheterization (Rao and Shetty, 2011).

The patterns of branching of ECA show ethnic differences (Sanjeev et al., 2010). Accordingly, with increasing use of invasive diagnostic and interventional procedures, data on types and frequencies of vascular variations (Rao and

Received 28th May 2015. Edited 25th September 2015. Published online 27th September 2015. To cite: Ogeng'o J, Misiani MK, Loyal P, Ongeti KW, Gimongo J, Inyimili MI, Murunga AK. Variations in branching pattern of external carotid artery in a black Kenyan population. *Anatomy Journal of Africa*. 2015. Vol 4 (2): 584 – 590

Shetty, 2011) from various populations is essential. We recently reported high variability of the carotid arterial system in the Kenyan population (Anangwe et al., 2008) and highlighted variant origin of the superior thyroid artery (Ongeti and Ogeng'o 2012; Magoma et

al., 2012). Data on pattern of branching of external carotid artery (ECA), in general, among black populations, however, remains scarce. This study therefore examined the branching pattern of ECA in a black Kenyan population.

MATERIALS AND METHODS

Materials for this study were 224 ECA, from 112 (76 male, 36 female) cadavers of black adult Kenyans at Department of Human Anatomy, University of Nairobi, Kenya. The carotid arterial system was exposed by detaching and removing the sternocleidomastoid muscle. Connective tissue and fat were removed, and the mandible disarticulated. The internal jugular veins were cut and removed to clarify the dissection field. Common carotid arteries were followed to termination and the medial branch that ramified extracranially identified as the ECA. Each of its

named branches was followed towards the destination for accurate identification. Only those that could be accurately identified were included in the study. Pattern and level of branching were examined. The branches were cleaned of fat and connective tissue and representative images taken with a high resolution digital camera. The patterns of branches were recorded and frequencies calculated. The data are represented in form of a table and macrographs.

RESULTS

Two hundred and twenty-four external carotid arteries were available for examination. Five patterns of were identified. In the first, which is the typical pattern of branching of the ECA, the artery had a long stem from which the superior thyroid, lingual, facial and ascending pharyngeal arose while the ECA ended by bifurcating into the maxillary (MA) and superficial temporal (ST) arteries (Fig 1A). This was the most common pattern (92; 41.1%). In the remainder (132; 58.9%) the branching pattern was atypical. Of these, the most common branching pattern was in trifurcation (60, 26.8%), followed by bifurcation (40, 17.9%) and quadrifurcation (20, 8.9%) [Table 1].

In the 40 cases of bifurcation, after giving superior thyroid artery ECA bifurcated into a

common linguo-facial trunk and the continuation which terminate as the ST and MA (Fig 1B). In the 60 cases of trifurcation, ECA gave STA before trifurcating into a linguo-facial trunk, ascending pharyngeal artery and its continuation (Fig 1C). All the cases of trifurcation and bifurcation involved a linguo-facial trunk, giving the latter frequency of 44.7%. One case of trifurcation involved the thyrolingual trunk (Fig 1D). In the quadrifurcation, ECA gave rise to lingual, facial, ascending pharyngeal arteries then continued to terminate by bifurcation into ST and MA (Fig 1D). In 12 (5.3%) of cases of early division, the superior thyroid, lingual and facial arteries arose from the medial aspect while the ascending pharyngeal arose from the lateral side within close proximity (Fig 1E).

Table 1: Branching pattern of external carotid artery among black Kenyans

Pattern	Frequency	%
Typical pattern	92	41.1
Trifurcation	60	26.8
Bifurcation	40	17.9
Quadrifurcation	20	8.9
Early division of ECA	12	5.3
Total	224	100

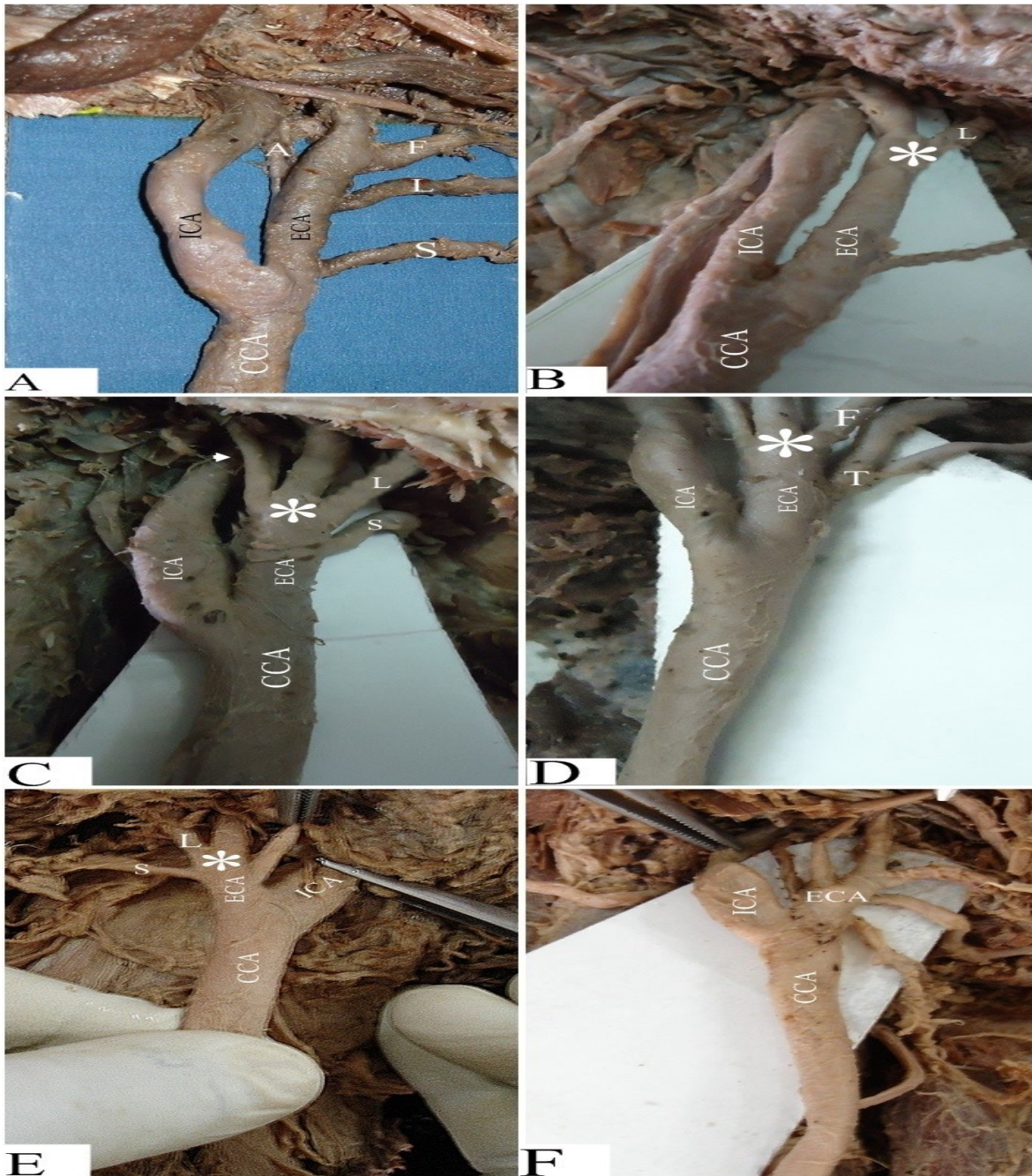


Figure 1 A - F: Photomicrographs showing the branching pattern of the external carotid artery. **A:** Conventional ECA with a long stem from which the superior thyroid artery (S), lingual (L), facial (F) and ascending pharyngeal (A) arteries arise. **B:** Bifurcation of the ECA (*) after giving the superior thyroid artery into the linguofacial trunk (L) and continuation. **C:** Trifurcation of ECA (*) after giving the superior thyroid artery (S) into linguofacial trunk (L), continuation and ascending pharyngeal (arrowhead). Note the common carotid artery (CCA) and internal carotid artery (ICA). **D:** Branching of the ECA to give a thyro-lingual trunk (T), and its subsequent termination via a trifurcation (*), among whose branches is the facial artery (F) **E:** Termination of the ECA via a quadrifurcation (*), among whose branches is the superior thyroid artery (S) and a linguo-facial trunk (L) **F:** Early division (*) of ECA. Note that the branches of the artery arise from a common short stem, resembling a pentafurcation.

DISCUSSION

The conventional branching pattern is known to be present in 76 – 90% (Shima et al., 1998; Hayshi et al., 2005; Ozgur et al., 2008a; Delic et al., 2010). Observations of the current study reveal that prevalence of this conventional pattern may be as low as 41.1%. This similar to that reported among Japanese (Yonenaga et al., 2011) but substantially lower than those reported among other populations [Table 2]. The wide differences may be due to ethnic variations, probably embedded in heredity. Normal branches of the ECA are key landmarks and their knowledge is necessary for successful surgery and to minimize postoperative complications in bloodless surgical field (Rao and Shetty, 2011). Surgeons operating in these regions should therefore beware of such variations.

Trifurcation and Quadrifurcation

Trifurcation was the most common variant occurring in 26.8% of cases. There are no other studies reporting prevalence to be compared

with since the few available cases have been documented as case reports (Kishve et al., 2011). Quadrifurcation occurred in 8.9% of cases. Variations of ECA akin to quadrifurcation have been documented. For example Thwin et al (2010) reported that after origin of STA, the ECA quadrifurcated into lingual, facial, occipital and distal part of ECA. Gluncic et al (2001) reported a quadrifurcation into STA, lingual, occipital and the distal part of ECA. It may also divide into STA, lingual, occipital and distal part of ECA (Namatha et al., 2010). Knowledge of this variation is needed for skillful, complication free surgery (Namatha et al., 2010).

Linguo – Facial Trunk

A remarkable finding of the current study is the 44.7% frequency of linguofacial trunk in trifurcation and bifurcation. This is much higher than the 10-20% literature reports from Caucasian populations (Anil, 2000; Gluncic et al., 2001; Sanjeev et al., 2010; Mata et al., 2012) [Table 2]

Table 2: Prevalence of conventional branching of external carotid in various populations

Author	Population	Method	Sample size	Prevalence (%)
Sanjeev et al., 2008	Indian	Dissection	37	56.8
Ozgur et al., 2008a	Turkish	Dissection	40	90
Delic et al., 2010	Turkish	Angiography	91	84.6
Mata et al., 2012	Brazil	Dissection	36	77.8
Yonenaga et al., 2011	Japanese	Dissection	56	41.1
Lohan et al., 2007	American	MR Angiography	46	82.6
Hayashi et al., 2005	Japanese	Dissection	98	81
Current study, 2013	Kenyan	Dissection	224	41.1

Table 3: Frequency of linguofacial trunk in various population

Author	Population	Sample size	Frequency (%)
Anangwe et al., 2008	Kenyan	80	7
Ozgur et al., 2008b	Turkish	40	7.5
Mata et al., 2012	Brazilian	36	19.4
Yonenaga et al., 2011	Japanese	56	20
Zumre et al., 2005	Turkish	40	20
Troupis et al., 2011	Greek	30	3.3
Sanjeev et al., 2010	Indian	37	18.9
Current study	Kenyan	224	44.7

Linguofacial trunks tend to arise from the EA at highly medialised positions. This places either facial or lingual artery in close proximity to the lingual fossa, making them more vulnerable to iatrogenic injury during intra-oral surgery such as tonsillectomy or repair of pseudoaneurysms to which the arteries are susceptible (Baik et al., 2011; Manzato et al., 2013). Further, they predispose to inadvertent ligation of one or the other artery during surgery or embolization or intra arterial injection of the wrong artery; or cause misinterpretation of angiograms (Nakasato et al., 2000; Bindu and Rao, 2012).

Early Division

Early division, that is when the ECA divides into its branches within the carotid triangle, occurred in 5.3% of cases. This similar to reports of Gluncic and colleagues (2001) that superior thyroid, lingual and occipital arteries branched directly from the right external carotid artery at its origin. Rao and Shetty (2011) also reported a case in which all branches arose close together from a common point just above the origin of the ECA from the common carotid artery. Such variations may cause problems in interpretation of angiograms and identification of the branches. This, has been reported to occur in 12.5% (Lucev et al., 2000). It may also predispose the maxillary artery to iatrogenic injury during

maxillofacial and parotid surgery (Shetty et al., 2015).

These variations of ECA may arise from derangements of the complex process of the development of ECA. The external carotid artery arises from the root of the 3rd aortic arch. Its branches form as annexations of arteries which develop by angiogenesis from the 1st, 2nd, 3rd, 4th and 6th aortic arches through a complex process of selective regression and persistence of various segments (Larsen, 1997; Mahendrakar, 2007). Physicians must take care and consider all possible variations of the arteries before and during surgery and in cases of ultrasonic or radiological examination (Mamatha et al., 2010). Accordingly, the higher frequency of the variations necessitates pre-operative evaluation.

The external carotid artery shows high frequency of variations comprising early bifurcation, trifurcation, quadrifurcation and short common stem. These variations may lead to inadvertent injury and cause confusion in interpretation of angiograms. Preoperative evaluation is recommended.

Acknowledgements: We acknowledge Mr. Peter Nzioka for technical support, Catherine W. Chinga and Antonina Odock – Opiko for secretarial assistance.

REFERENCES

1. Anangwe D, Saidi H, Ogeng'o J, Awori KA. 2008. Anatomical variations of the carotid arteries in adult Kenyans. *E Afr Med J*; 85: 244 – 247.
2. Anil A, Turgut HB, Peker T, Pelin C. 2000. Variations of the branches of the external carotid artery. *Gazi Med J*; 11: 81 – 83.
3. Baik FM, Chang AA, Green DA, Pakbaz RS, Bergoron CM. 2011. Post-tonsillectomy lingual artery pseudoaneurysm. *Laryngoscope*, 121: 561.
4. Bindu AH, Rao AN. 2012. Abberant patterns of branching of external carotid artery. *Int J Basic App Med Sci*; 2: 170 – 173.
5. Delic J, Savkovic A, Bajtarevic A, Isakovic E. 2010. Variations of ramification of external carotid artery – common trunks of collateral branches. *Period Biol*; 112: 117 – 119.
6. Gluncic V, Petanjek Z, Marusic A, Gluncic I. 2001. High bifurcation of common carotid artery, anomalous origin of ascending pharyngeal artery and anomalous branching pattern of external carotid artery. *Surg Radiol Anat*; 23: 123 – 125.
7. Hayashi N, Hori E, Othani Y, Kuwayama N, Eudo S. 2005. Surgical Anatomy of the cervical Artery for carotid endarterectomy. *Neurol Med Chir*; 45: 25 – 29.
8. Hoffer SO, Poschn A, Smit X. 2005. The facial artery perforator flap for reconstruction of peroral defects. *Plast Reconstr Surg*; 115: 996 – 1003.

9. Joshi A, Rajendraprased JS, Shetty K. 2005. Reconstruction of intra oral defects using facial artery musculomucosal flaps. *Br J Plast Surg*; 67: 12 – 15.
10. Kishve PS, Kishve SP, Joshi M, Aarif SMM, Kalakoti P. 2011. AN Unusual branching pattern of common and external carotid artery in a human cadaver: A case report. *Australas Med J*; 4: 180 – 182.
11. Larsen WJ. 1997. Development of cardiovascular system. *Human embryology 2nd Ed.* Churchill Livingstone New York, Edinburgh, London; 191 – 195.
12. Lohan Dg, Barkhordarain F, Saleh R, Krishnam M, Salamon N, Ruehm SG, Finn JP. 2007. MR Angiography at 3T for Assessment of the External carotid Artery System. *Am J Roentegenol*; 189: 1088 – 1094.
13. Lucev N, Bobinac D, Maric I, Doescik I. 2000. Variations in the great arteries in the carotid triangle. *Otolaryngol. Head Neck Surg*; 122: 590 – 591.
14. Magoma G, Saidi H, Kaisha WO. 2012. Origin of thyroid arteries in a Kenyan population. *Annals Afr Surg*; 9: 50 – 54.
15. Mahendrakar MA. 2007. Variation in the branching pattern of External carotid Artery: A case Report. *J Anat Soc India*; 56: 47 – 52.
16. Mamatha T, Rai R, Prabhu LV, Hadimani GA, Jiji PJ, Prameela MD. 2010. Anomalous branching pattern of the external carotid artery: a case report. *Rom J Morphol Embryol*; 51: 593 – 595.
17. Manzato L, Trivelato FP, Yugo A, Alvarenga H, renzenge MT, Ulhoa AC. 2012. Endovascular treatment of a linguofacial trunk pseudoaneurysm after tonsillectomy. *Braz J Otolaryngo*; 79: 524 -524.
18. Mata JR, Mata FR, Souza MCR, Nishijo H, Ferreira TAA. 2012. Arrangement and prevalence of branches in the external carotid artery in humans. *Ital J Anat Embryol*; 117: 65 – 74.
19. Nakasato T, Kato K, Sone M, Ehara S, Tamakawa Y, Hoshi H, Sekiyama S. 2000. Superselective continuous Arterial Infusion chemotherapy through the superficial Temporal Artery of oral cavity Tumors. *Am J Neurorad*; 21: 1917 – 1922.
20. Ongeti KW, Ogeng'o JA 2012. Variant origin of the superior thyroid artery in a Kenyan population. *Clin Anat*; 25: 198 – 202.
21. Ozgur Z, Govsa F, Ozgur T. 2008a. Anatomic evaluation of the carotid artery bifurcation in cadavers: Implications for open and endovascular therapy. *Surg Rad Anat*; 30: 475 – 480.
22. Ozgur Z, Govsa F, Ozgur T. 2008b. Assessment of origin characteristics of the front branches of external carotid artery. *J. Craniofac Surg*; 19: 1159 – 1166.
23. Panagouli E, Lolis E, Veneriatos D. 2011. A morphometric study concerning the branching points of the main arteries in humans: relationships and correlations. *An Anat*; 19: 86 – 99.
24. Pinar YA, Gousar F. 2005. Anatomy of the superficial temporal artery and its branches: Its importance for surgery. *Surg Radiol Anat*; 28: 248 – 253.
25. Rao TR, Shetty P. 2011. Unusual Branching Pattern of External Carotid artery in a cadaver. *Chang Gung Med J*; 34(6 supp): 24 – 27.
26. Sanjeev IK, Anita H, Ashwini M, Mahesh U, Rairam GB. 2010. Branching pattern of external carotid artery in human cadavers. *J Clin Diagn Res*; 4: 3128 – 3133.
27. Satogani N, Okada T, Koyama T, Kimio GK, Kamae T, Togashi K. 2009. Visualization of external carotid artery and its branches: Non-contrast enhanced MR angiography using balanced steady state free- precision sequence and a time- spatial labeling inversion pulse. *J Magn Res Reson Imaging*; 30: 678 – 683.
28. Shetty SD, Nayak SB, Kumar N, Aithal A. 2015. Low level termination of External carotid Artery and its clinical significance: A case report *Arch Clin Exp Surg*; 4: 160 - 163.
29. Shima H, VonLeudinghhausen M, Ohno K, Michi K. 1998. Anatomy of microvascular anastomosis in the neck. *Plas Reconstr Surg*; 101: 33 – 41.

30. Thwin SS, Soe MM, Myint M, Than M, Lwin S. 2010. Variations of the origin and branches of the external carotid artery in a human cadaver. *Singapore Med J*; 51: e40 – e42.
31. Troupis TG, Dimitroulis D, Paraschos A, Michalinos A, Protegerou V, Vlasis K. Troupis G, Skandalakis P. 2011. Lingual and facial arteries arising from the external carotid artery as a common trunk. *Am Surg*; 77: 151 – 154.
32. Yonenaga K, Tohnai I, Mitsudo K, Mori Y, Saijo H, Iwai T, Yonehara Y, Ota Y, Torigoe K, Takato T. 2011. Anatomical study of the external carotid artery and its branches for administration of superselective intra-arterial chemotherapy via the superficial temporal artery. *Int J clin oncol*: 16: 654 – 656.
33. Zumre O, Salbacak A, Cicekcibasi AE, Tuncer I, Seker M. 2005. Investigation of the bifurcation level of the common carotid artery and variations of the branches of the external carotid artery in human fetuses. *Ann Anat*; 187: 361 – 369.