

The Radiological Scrutiny of the Relation between Renal Vascular Dimensions and Anatomical Variation of Renal Arteries: The Must to Know before Renal Transplantation

Sungura R^{1*}, Mathenge I² and Onyambu C²

¹Department of Radiology and Imaging, Mount Meru Regional Referral Hospital, Arusha, Tanzania

²Department of Diagnostic Imaging and Radiation Medicine, University of Nairobi, Kenya

*Corresponding author: Richard Sungura, Department of Radiology and Imaging, Mount Meru Regional Referral Hospital, Arusha, Tanzania, Tel: +255784262954; E-mail: drsungura@yahoo.com

Received date: Dec 20, 2017; Accepted date: Dec 23, 2017; Published date: Dec 29, 2017

Copyright: © 2017 Sungura R, et al. This is an open-access article distributed under the terms of the Creative Commons Attribution License, which permits unrestricted use, distribution, and reproduction in any medium, provided the original author and source are credited.

Abstract

Renal transplantation is the preferred treatment of patients suffering from end stage renal disease. Because of challenges in performing surgical vascular anastomosis in variant renal anatomy, knowledge on renal vascular anatomy is very important in the pre surgical workup of potential kidney donors. These anatomical variations differ geographically and ethnically. In Kenya there has been scanty statistics on prevalence of extra-renal branching of arteries but also the clear knowledge in the understanding of the relation between renal sizes, their main arterial diameters in predicting the presence of accessory arteries without invasive diagnostic methods. This study was designed to add into the body of literature more information about the dimensions of renal vascular anatomy of adult African population in Kenya and transmit this knowledge to enrich the renal surgery practice in the region and beyond. Therefore the aim of this study was to determining the relationship between kidney size, main renal arterial caliber and how they relate in the presence or absence of accessory arteries. The study was a three-year cross-sectional descriptive study conducted at Kenyatta National Hospital from June 2008 to June 2011. A total of 204 cases including 103 (50.5%) females and 101 (49.5%) males were recruited for CTA. Most normal sized kidneys with accessory arteries had smaller main renal arterial diameters. Extra renal branching occurred in 14.7% of cases. It is concluded that the presence of accessory arteries cannot be determined by the study of kidney sizes alone. The current value of Renal CTA cannot be easily replaced by simplified noninvasive modalities for indirect and accurate study of renal vascular anatomy of potential kidney donors.

Keywords: Renal angiography; Renal artery variation; CT angiography; Renal size

Introduction

The excretory system of human body is facilitated by two retroperitoneal organs called kidneys situated in on each side of the higher lumbar vertebral column [1]. Each kidney is supplied by a single renal artery and a single renal vein, arising from the abdominal aorta and draining into the inferior vena cava, respectively. Renal arteries typically originate from the aorta at the level of second lumbar vertebra below the takeoff of the superior mesenteric artery, with the vein anterior to the artery. This blood supply has its embryological basis from the region known as rete arteriosum spanning from sixth cervical vertebra to the third lumbar vertebra. The mesonephric arteries supply the kidneys, suprarenal glands and gonads on both sides of the aorta. These arteries degenerate during development leaving one prominent renal artery [2]. Most variations originate from these embryological factors.

Anatomical variation is a common finding in renal vasculature. More than one artery supplying a kidney is the most common arterial variation, and this is seen in about 24% of cases [3]. These arteries are divided into two groups: Hilar (accessory) and polar (aberrant) arteries. The accessory arteries enter the kidney from the hilum along with the main renal artery, whereas the aberrant arteries enter the kidney directly from the capsule outside the hilum. These accessory/

aberrant renal arteries usually originate from the abdominal aorta or iliac arteries; however, they can, on rare occasion, arise from the lower thoracic aorta or from the lumbar or mesenteric arteries. Early arterial branching or prehilum branching is diagnosed when the first renal branch arises within 1.5 cm of the renal artery ostium. Early branching is seen in about 12% of the population [3].

Renal transplantation is one of the most important clinical applications of renal vascular anatomy. Renal transplantation is the treatment of choice for people who suffer from End Stage Renal Failure. This medical condition is increasingly being seen in all corners of the World including Sub Saharan Africa [4]. Repeated dialysis and renal transplantation are the only treatment options for these patients to survive [5]. Helical CT arteriography can become the primary imaging modality for preoperative assessment of potential renal donors. Nevertheless, Conventional renal angiography is still the gold standard for identification of arterial multiplicity and fibromuscular dysplasia, and should be used adjunctively if there is an ambiguity [6]. According to the applied renal vascular anatomy the first 2 cm from abdominal aorta is the most important surgically as most procedures require at least 2 cm length of the main renal artery from aorta for adequate control of anastomosis [7].

The left kidney is preferred in both Laparoscopic and Open nephrectomies due to their longer renal vein which provide more optimal vessel for venous anastomosis in the recipient. It is however known that not all potential donors have favorable anatomy conducive

for left sided laparoscopic donor nephrectomy. Complex vasculatures such as multiple renal arteries have been cited as the indication to disqualify a person for renal donation or to consider right sided donor nephrectomy. However, the right sided donor nephrectomy has technical challenges of exposing the right hilum and has shorter renal vein making anastomosis difficult [8]. Several simple ways such as sonography in attempts to predict presence of complex renal vasculature such as accessory arteries have been suggested. Correlative radiological investigations showed that diameters of main renal arteries were significantly smaller in the presence of the accessory renal artery and therefore bring to conclusion that the presence of the main renal artery with a diameter smaller than usual in a kidney with normal dimensions is indicative of the presence of an accessory renal artery [9]. In Kenya, the first renal transplant was done in 1978 at Nairobi hospital. [10]. However many patients have been sent to India for such services over many years now. Currently Renal transplantations are also done at Kenyatta National hospital, Aga Khan Hospital and possible other centers will be coming up in near future [10]. Many CT and MRI scans with high end technology are increasingly becoming available. In completing CT renal angiographic procedure, usually the scans are taken by introducing contrast material into venous bloodstream around 100 to 150 ml using Iodinated contrast by pump bolus injection [11], this defines the blood vessels being examined by making them appear bright white due to high attenuation. Scanning may include venous phase, arterial and delayed phase depending on the objective of the renal vascular study intended. CTA (computed tomography angiography) image is basically acquired through axial scans, however reformats may be needed in order to view pathology better in its long axis. These reconstructions modes include Multiplanar Reformatting (MPR), Maximum Intensity Projection (MIP), (Min IP) and Shaded Surface Display (SSD). Volume rendering techniques (VR) use a combine advantage of MIP and SSD. Volume rendering has emerged as the rendering technique of choice. These techniques permit the exploration of fine anatomical detail that would be difficult to evaluate using axial reconstructions alone [12]. It was very important for the study to be done in Kenya since the only study of renal vascular system for the local population was done through postmortem cadaveric specimens [13].

It was vital necessity therefore to do a similar study using imaging techniques to study the living cases, as the study that was done by the pathologists using cadavers did not involve measurement of renal arterial diameters neither did it involve measurement of kidney sizes. Furthermore, a number of physiological changes resulting from the effect of brain death occur in dead bodies may alter quality of structures compared to that of living donors [14]. It was presumed that if this study was to be done using CT scan, the findings could establish a roadmap for other studies possibly using modalities with non-ionizing radiation to establish an imaging protocol for investigating potential kidney donors. MRI Angiography is certainly a known efficient alternative to modalities using ionizing radiation; nevertheless it could not be afforded by most of Kenyans as a cost effective investigation of choice.

Therefore this study aimed at determining the relationship between kidney size and the presence of accessory arteries and to establish if the main renal arterial caliber is related to the presence of accessory renal arteries. Early extra renal branching prevalence was also necessary to be examined.

Materials and Methods

A cross-sectional, descriptive study was conducted at Kenyatta National Hospital, Department of radiology. Adults between the age of 18 to 75 years were included in the study. These were all cases of patients and donors who were sent to the departments of Radiology to undergo either CT Renal angiography as potential kidney donors or any other Abdominal CT angiography for other reason apart from kidney and vascular pathology between the periods of June 2008 to June 2011.

Patients were excluded when they were found to have gross renal disease. Additionally, patients with CT angiography bearing evidence of ectopic kidney and other gross renal anomalies were not recruited. People who were found to have poor functioning kidneys or incidental hydronephrosis were not part of the study. People who lived in Kenya but were not of an African race were excluded. Lastly were all cases CT angiography under the age of 18 years and above 75 years old. The sample size was obtained from the use of statistical formula by Fisher et al. [15], at the confidence interval of 95% and a margin error of 5% and prevalence of presence of accessory renal arteries at 15% [13,16]. The sample size was calculated as:

$$N = \frac{Z^2 * (p) * (1 - p)}{C^2}$$

Where p is proportion of prevalence, Z=standard normal distribution, C is the level of significance desired. When this formula applied at $c=0.05$, $z=1.96$ and $p=0.15$, $N=195$ cases. The minimum sample size was therefore supposed to be 195 angiography cases. However, 204 cases were sampled in this study. Renal and other abdominal CTA images were retrieved from the computer system and carefully examined for their renal vascular anatomy. Patient's data including numbers and type of examinations were traced from the departmental registration book. Amount of contrast that was given was also traced from procedure book usually documented by the technologist on duty. Using this basic information the images of the patients were retrieved from the computer, scrutinized for its vascular anatomy, and the results documented in the designed data forms for analysis.

Data analysis was conducted using statistical package for social scientists (SPSS) version 15. The characteristics of study participants e.g. age and sex were summarized using descriptive statistics. T-tests were used to compare renal findings between different patient groups. Data were presented in form of graphs, pie charts and tables. Radiological images are presented for selected cases.

Results

A total of 204 cases undergoing CT angiography at KNH were recruited in this study. The findings obtained from this study were henceforth categorized in accordance to the following sub-titles.

Extra renal branching

The extra renal branching was identified in 30 out of the 204 cases representing a prevalence of 14.7%. Bilateral extra renal branching was seen more commonly than unilateral branching. Among the 30 cases with extra renal branching, 23 (11.3%) cases had bilateral extra renal branching while the remaining 7 (3.43%) cases of extra renal branching occurred unilaterally. Extra renal branching occurred in 27 (13.2%) cases on the left hand side kidney and in 26 (12.7%) cases on

the right kidney. However, early extra renal branching was rare and occurred in only 5 (16.6%) out of the 30 cases. Most of the extra renal branching in both the left (24 out of 27) and right (24 out of 26) kidneys occurred more than 2 cm from the kidney.

Kidney size and presence of accessory arteries

Results of a two sample paired t-test comparison of the size of the left and right kidneys are presented in Table 1.

	Right kidney	Left kidney	Difference (95% CI)	p value
Kidney size	Average (SD)	Average (SD)		
Length (mm)	94.1 (12.3)	98.0 (13.1)	-3.9 (-5.1 to -2.7)	<0.001
Height (mm)	46.4 (8.0)	47.3 (7.0)	-0.88 (-1.8 to 0.001)	0.05
Width (mm)	48.2 (7.9)	51.4 (9.2)	-3.2 (-4.3 to -2.0)	<0.001
Volume (ml)	114.1 (39.2)	127.2 (45.1)	-13.0 (-16.7 to -9.4)	<0.001
Main arterial diameter (mm)	5.33 (1.28)	5.92 (1.28)	0.596 (0.48 to -0.71)	<0.001

Table 1: Average size of right and left kidney size with their arterial diameters.

	Odds Ratio	95% Confidence interval	P value
Regression 1			
Left accessory artery			
Length	0.98	0.93, 1.04	0.53
Height	1	0.88, 1.14	0.98
Width	1.02	0.95, 1.09	0.59
Volume	1	0.98, 1.03	0.72
Regression 2			
Right accessory artery			
Length	1.02	0.92, 1.14	0.65
Height	1.12	0.96, 1.3	0.16
Width	1.06	0.9, 1.24	0.51
Volume	0.98	0.94, 1.03	0.51

Table 2: Logistic regression analysis of kidney size and presence of an accessory renal artery.

On average, the left kidneys among the study cases were significantly larger than the right kidneys in terms of length ($p < 0.001$), height ($p = 0.05$), width ($p < 0.001$) and volume ($p < 0.001$). The length of the left kidney was greater than the right kidney in 144 (70.6%) of the cases in this study. The average difference in kidney lengths between the left and right kidney was -3.9 mm (95% CI, -5.1 to -2.7). In terms of height and width the left kidney exceeded the right kidney in 56.3%

($n = 115$) and 67.2% ($n = 137$) of cases, respectively. The average difference in kidney height was -0.88 mm (95% CI, -1.8 to 0.001) and the average difference in width was -3.2 mm (95% CI, -4.3 to -2.0).

The results of a logistic regression to predict the presence of accessory arteries based on the size of kidneys only are shown in Table 2. These findings showed that it was not possible to predict the presence of an accessory artery based on kidney size alone.

Main renal arterial diameter and presence of accessory arteries

The average arterial diameter of left renal artery was on average greater $P < 0.001$ than that of the right artery ($p < 0.001$). As shown in the bottom row of Table 1 above, the mean arterial diameter for the left side kidney among cases in the study was 5.92 mm compared to 5.33 mm recorded for the right artery diameter, difference = 0.596 (95% CI, 0.48 to -0.71). On average, the mean arterial diameter for patients with accessory arteries was less than that of patients without accessory arteries. These differences in main arterial caliber were statistically significant for the right sided kidney as presented in Figure 1 below (mean = 5.35 mm vs. 4.53 mm, $p = 0.016$). There was evidence that the diameter of the main left renal artery was less in patients presenting with left accessory arteries but this difference was marginally significant (mean = 5.96 mm vs. 5.21 mm, $p = 0.097$). Similarly, it was observed that the right diameter were significantly less for females compared to males ($p = 0.041$), but the difference in left renal artery diameters was not statistically significant in relation to gender ($p = 0.08$).

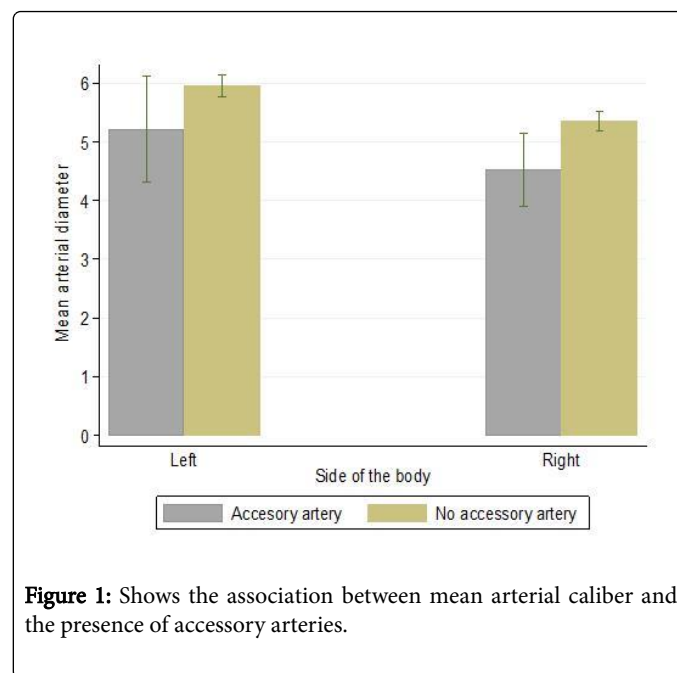


Figure 1: Shows the association between mean arterial caliber and the presence of accessory arteries.

Discussion

In this three year cross-sectional study done at Kenyatta National Hospital in Nairobi, Kenya, a total of 204 cases were recruited. The sample was composed predominantly of adults with a mean age of 47.16 years (SD ± 18.32) and range of 18 years to 75 years and the ratio of male to female participants was 1:1. These findings are of clinical significance because renal donors are commonly adults with similar

demographic characteristic to that reported in the current study. Thus the similarities reported above increases the relevance of the results from this study.

The Computerized Tomography Angiography findings from the study are discussed below under the following sub-headings: Extra renal branching, relation between Kidney size and accessory arteries and lastly relation between main arterial caliber and accessory arteries.

Extra renal arterial branching

This is arterial branching from the main renal arteries, considered to be a form of accessory arteries in the past [16], but now termed as extra renal arterial branching. In this study we found 30 cases out of 204 total cases giving a prevalence of 14.7%. An arterial branching found at a distance of less than 2 cm from the aorta was considered to be an early extra renal branching. The CTA scan showing bilateral extra renal branching is shown in the Figure 2.

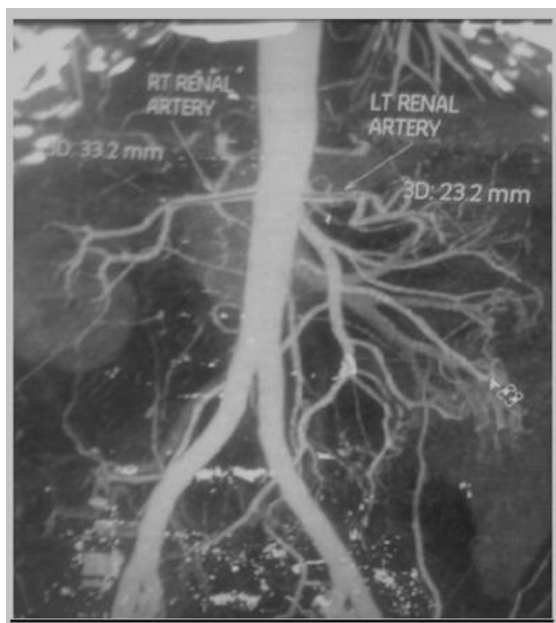


Figure 2: CTA scan showing bilateral extra renal branching. The left is at 2 cm and the right at 3 cm from abdominal aorta. Branching at 2 cm or less is considered as early extra renal branching.

Bilateral presentation of the extra renal branching was the commoner presentation. In the study by Ogeng'o et al. on Kenyan population using autopsy they observed 21.6% prevalence of extra renal branching [13]. Like in the case of accessory arteries this statistic from autopsy again is higher than that from our radiological findings. The Possible explanations include technical issues like the limitation of MDCT to depict small diameter (<3 mm) arterial branching [17]. Lack of standardized optimum protocol for running CT Angiography in view of patient BMI and pump injection rate may affect the intensity of opacification and pickup rate of small vessels. But also it is possible that the study by Ogeng'o, et al. included even the small arteries which were obliterated from the embryological development of mesonephric arteries, since it is already known in the literature that, the origin of renal arteries and its variations can be explained by the development of mesonephric arteries. These mesonephric arteries supply the kidneys,

suprarenal glands and gonads on both sides of the aorta, from sixth cervical vertebra to third lumbar vertebra, a region known as rete arteriosum urogenitale. As the development progresses these arteries degenerate, leaving one prominent mesonephric artery [2,18]. It is therefore possible that cadaveric dissection (autopsy) shows high depiction rate because it included even small primitive arteries whose lumen were obliterated by the above degenerative process and that they are not truly functional vessels. The jet flow of blood during surgical is an evidence of functional artery. Although autopsy appears to be the gold standard in this renal-arterial anatomy studying directly by dissection method, renal CT angiography is sensitive enough and the vessels missed are often smaller ones probably with no surgical significance.

The study by Shaffer et al. [19] suggests that small missed vessels during pre-operative imaging can be ligated surgically without significant ischemic injuries to the renal parenchyma.

Relation between kidney size and accessory arteries

The findings of this study show that on average the left kidney size is larger than the right one in terms of length in at least 70% of donors. The observations are shown in Figure 3-5. The variation in size could be due to developmental space occupying effect of the neighboring organs the liver and spleen during embryological ascending of kidneys [2]. The liver is larger organ than the spleen. Hence the right kidney suffers more restriction than the left. The height differences were demonstrated in 56.3% of donors and width differences in 67.2% of donors.

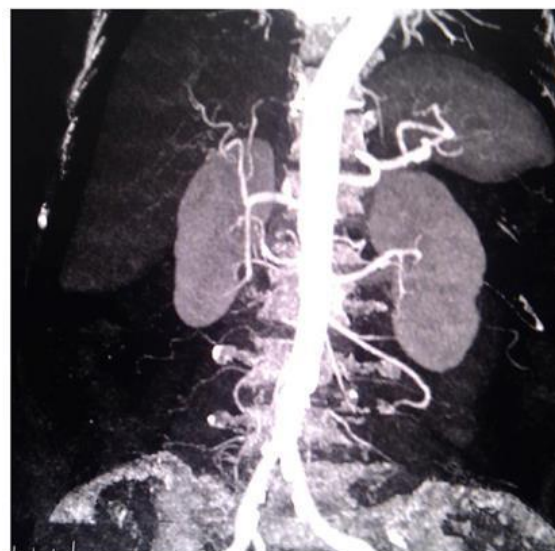

Figure 3: MIP Renal CTA- Left: Length x Height x Width (8.73 x 3.68 x 3.91 cm), main left renal artery diameter is 6.8 mm. Right: Length x height x Width (8.7 x 4.7 x 5.29 cm), main right renal artery diameter is 5.0 mm and accessory artery diameter is 2.8 mm.

The presence of accessory could not be deduced out of kidney size alone as a predictive indicator. Different kidney sizes may have different sizes of main renal artery and varied sizes of accessory arteries if present.

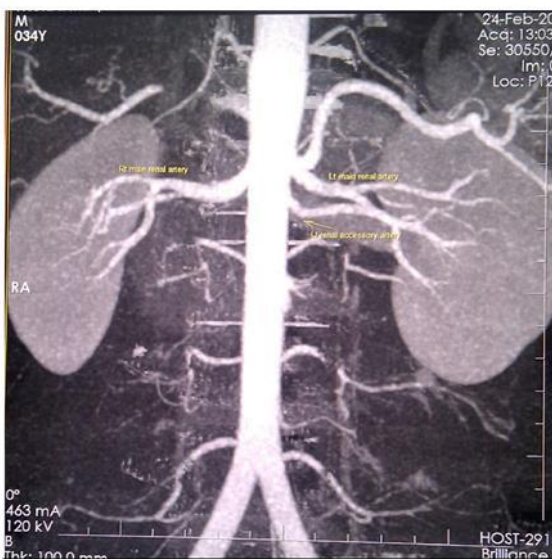


Figure 4: MIP CTA- Right: Length \times Height \times Width (9.83 \times 4.59 \times 4.38 cm) size, main right renal artery diameter is 4.8 mm. Left: Length \times Height \times Width (10.0 \times 4.48 \times 4.93 cm) size, main left renal artery diameter is 3.8 mm and accessory artery is 2.3 mm.

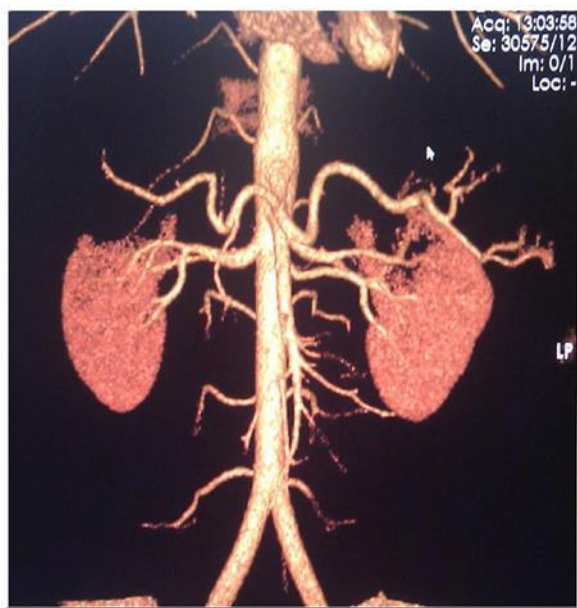


Figure 5: Volume rendering CTA image showing left accessory artery. Bone removal application was bone.

Relation between main arterial caliber and accessory arteries

The mean arterial diameter of the left main renal artery was 5.92 mm and that of the right main renal artery was 5.33 mm. So in general the left main renal arteries are relatively larger than the corresponding right arteries. The kidneys presenting with accessory arteries exhibited

smaller diameter compared to those with no accessory arteries, the observation was more evidenced in the right kidney. Almost similar observation was also noted in the study by Suat, et al. [9] suggested that higher rates of detection of accessory arteries can be obtained sonographically when both kidney size and main renal artery diameters are considered. In this study, the above observation has shown statistical significance in the right side ($p=0.016$), but it was not significant in the left side ($p=0.097$). These findings may suggest difficulty in arriving at a conclusion that presence of accessory arteries can accurately be picked from the kidney size and renal artery diameter independently. However, when the two parameters are dependently considered can give high index of suspicion about the presence of accessory arteries. The significance of this finding is to show that a radiological investigation that is able to pick renal size alone without accurately depicting caliber of the main renal artery is very inefficient in predicting presence of small accessory artery.

Study limitations

This study faced some limitations as patient's data collection and retrieval was seriously limited by the lack of long term computerized information archiving system such as PACS. The study would be more informative if prospectively done over a long period of time with all other patient information including complications related to renal surgeries. It was very difficult to achieve a representative sample size by performing this study specifically for those who came for precisely CT renal angiography for pre transplantation evaluation, therefore recruitment of other patients who were referred for other abdominal CT angiography was an alternative to study renal vascular system. This may subject the study to some degree of errors due to presence of sub clinical medical conditions that may as well affect the quality of renal imaging.

Conclusion

Based on the radiological findings of this study and the objectives that were set, the following conclusions can be reached. There is prevalence of more than 14% for extra renal arterial branching, bilateral presentation is commoner. Early extra renal branching present rarely and account for 16% of all extra renal arterial branching. There is a direct relation between the kidney size and the diameter of the corresponding main renal artery in the absence of accessory arteries.

The presence of accessory arteries cannot be determined by the study of kidney sizes alone. However, most normal sized kidneys with accessory arteries have smaller main renal arterial diameters. In this observation, the likelihood of the presence of the left renal accessory artery is high when the left kidney size is larger than the right in the setting of paradoxically smaller left main renal artery than the right. This fact cannot replace the current value of CT Renal Angiography by other simplified noninvasive imaging modalities for indirect and accurate study of renal arterial anatomy for potential kidney donors.

What is already known

Multi detector CT scan angiography is a useful tool in depicting accessory arteries for qualifying candidates for kidney donation. The presence of the main renal artery with a diameter smaller than usual in a kidney with normal dimensions is indicative of the presence of an accessory renal artery [9]. Early branching of renal arteries is 12% in a general population [3].

What is added from this research

The prevalence of extra renal branching of renal arteries in Kenya is now known to be 14.7% radiologically and early branching is 16% of the extra-renal branching. The Kenyans mean arterial diameter of the main renal artery is 5.92 mm and 5.33 mm left and right respectively. The kidneys presenting with accessory arteries exhibit smaller diameter compared to those with no accessory arteries, this observation is more significant in the right kidney. The normal size of African adult kidneys in Kenya is 114 ml (SD \pm 39.2) and 127 ml (SD \pm 45.1) right and left respectively. It is not possible to predict the presence of an accessory artery based on kidney size alone.

Recommendations

A comparative study needs to be done in this part of the world to correlate the radiological findings vs. intra operative findings of the renal vascular anatomy for kidney donors for an acceptable period of time to cover wide sample size and assess the sensitivity of radiological tools like MDCT angiography. In such a study our protocol for Renal CTA can be revised to enable higher depicting rate. This study was done using 16 Slice Helical CT Scan; a similar study can be repeated using a higher slices machine such as 128 or 320 detectors in order to find out whether different pickup rate can be demonstrated.

Competing Interests

The authors declare that they have no competing interest in whichever situation related to publication of this study. There is no fund, fee or reimbursement received from any organization that may gain or lose financially upon publication of this document. None of the authors hold stock shares in any organization that may gain or lose from this publication. No application is made or intended to be done to any patents related to the context of this manuscript. We (the authors) have no other financial or non-financial competing interest politically, intellectually or commercially.

Acknowledgement

This study was made possible by the help of the following people whom I hope can accept my humble thanks. My supervisors Dr. Onyambu and Dr. Mathenge for their valuable guidance, advise and comments on this chosen topic for my Masters of medicine dissertation. They were available any time I needed their help. Many thanks be conveyed to the administration of Kenyatta National hospital where the study was conducted, Belgian technical Corporation, Tanzania office for sponsoring my living in Kenya. Many thanks are also extended to Mr Phillip Ayieko who did most of the statistical work and finally data interpretation of this research paper.

References

1. Chaurasia BD (2004) *Human anatomy* 2: 256.

2. Bardeen CR, Evans HM, Felix W, Grosser O, Keibel F, et al. (1912) *Manual of human embryology*. Philadelphia: JB Lippincott Company: The development of the urogenital organs: pp 752-880.
3. Sheo K, Zafar N, Archana G (2010) The utility of 64 multi-detector CT angiography for evaluation of the renal vascular anatomy and possible variation. *Korean J Radiol* 11: 346-354.
4. Naicker SD (2013) End-stage renal disease in Sub-Saharan Africa. *Kid Int Sup* 3: 161-163.
5. Robert W (1997) Recent advances: General management of end stage renal disease. *BMJ* 315: 1429-1432.
6. Kumar S, Tharakan M, Chacko N, Gnanaraj L (2002) Comparison of spiral CT angiography vs digital subtraction angiography in evaluation of living kidney donors. *Ind J Uro* 19: 50-53.
7. Satomi K, Robert M, Leo PL (2008) Multi detector row CT evaluation of living renal donors prior to laparoscopic nephrectomy. *Radiographics* 24: 423-466.
8. Disick GI, Shapiro ME, Miles RA, Munver R (2009) Critical analysis of the laparoscopic donor nephrectomy in the setting of complex renal vasculature: Initial experience and intermediate outcomes. *J Endourol* 23: 451-455.
9. Aytac SK, Yigit H, Sancak T, Ozcan H (2003) Correlation between the diameter of the main renal artery and the presence of an accessory renal artery: Sonographic and angiographic evaluation. *J Ultrasound Med* 22: 433-439.
10. Otieno LS, Awori NW, Bagshawe A, Abdullah MS, Kyambi JM, et al. (1980) The first renal transplantation in Kenya. *East Afr Med J* 57: 369-373.
11. Salehipour M, Salahi H, Jalaiean H, Bahador A, Nikeghbalian S, et al. (2009) Vascular complications following 1500 consecutive living and cadaveric donor renal transplantation. *Saudi J Kidney Dis Transpl* 20: 570-572.
12. Perandini S, Faccioli N, Zaccarella A, Re T, Mucelli RP (2010) The diagnostic contribution of CT volumetric rendering techniques in routine practice. *Indian J Radiol Imaging* 20: 92-97.
13. Ogeng'o JA, Masaki CO, Sinkeet SR, Muthoka JM, Murunga AK (2010) Variant anatomy of renal arteries in a Kenyan population. *Ann Transplant* 15: 40-45.
14. Cecka JM (1994) Outcome statistics of renal transplants with an emphasis on long-term survival. *Clin Transplant* 8: 324-327.
15. Fisher SJ, Fielder DG (1998) A standard weight equation to assess the condition of North American lake herring. *J Freshwater Ecol* 13: 269-277.
16. Subhash B, Michael C, Shubam G (2007) *Vascular disease management*. J Invasive Cardiol 4.
17. Kumar NU, Murty PVLN, Kumar N, Reddy R, Ramamurthy, et al. (2004) Evaluation of renal donors with helical CT angiography- our experience. *Ind J Uro* 20: 134-137.
18. Kumar GP (2011) Bilateral superior accessory renal arteries- Its embryological basis & surgical importance- A case report. *J clin case rep* 2: 100-103.
19. Shaffer D, Sahyoun AI, Madras PN, Monaco AP (1998) Two hundred and one consecutive living-donor nephrectomies. *Arch Surg* 133: 426-443.