

**UTILITY OF IMPRINT CYTOLOGY IN RAPID INTRA-OPERATIVE DIAGNOSIS OF
HEAD AND NECK LESIONS IN PATIENTS ATTENDING SURGICAL CLINICS AT
KENYATTA NATIONAL HOSPITAL.**

**EVERLYNE KUTOLO WEBALA
REG.NO. H56/87421/2016**

Department of Human Pathology,
School of Medicine, College of Health Sciences,
University of Nairobi, P.O. Box 19676-00202, Nairobi Kenya. E-mail:
everlynekutolo@gmail.com

**SUPERVISORS:
PROF L.MUCHIRI
DR W.WAWERU DR.M.
KANINI**

**THE DISSERTATION SUBMITTED IN PARTIAL FULFILLMENT FOR THE AWARD
OF DEGREE IN MASTERS OF SCIENCE IN CLINICAL CYTOLOGY AT THE
UNIVERSITY OF NAIROBI.**

AUGUST, 2019

DECLARATION

I hereby declare that this thesis is my original work under the guidance of the supervisors listed below and has not been submitted to the University of Nairobi or any other higher learning institution.

Signature.....

Date.....

Everlyne Kutolo Webala

MSc Clinical Cytology Student, University of Nairobi **Registration**

No.H56/87421/2016.

CERTIFICATE OF SUPERVISION

We confirm that this thesis was developed by the above-named student under my guidance.

PROF. L.W. Muchiri MBChB, MMed (Path), PG-BRM, PhD, FCPATH(EGSA)

Associate Professor,
Anatomic Pathology Unit,
Department of Human Pathology,
School of Medicine,
University of Nairobi.

Signature: _____ **Date:** _____ **Dr.**

W. Waweru MBChB, MMed (Path), FCPATH(EGSA)

Senior Lecturer, Anatomic Pathology Unit,
Department of Human Pathology, School of Medicine,
University of Nairobi.

Signature: _____ **Date:** _____

DR.M. KANINI

Kenyatta National Hospital,
Consultant Oral Pathologist.

Signature: _____ **Date:** _____

DEDICATION

I dedicate this dissertation to my beloved husband Alfred Kenny Kutolo for his spiritual, social and financial support and encouragement which enabled me to succeed in my studies and also to my children Nick, Eugene, Daniel, Esther, Prisca and innocent who remained wise despite my absence at very tender age.

ACKNOWLEDGEMENT

I thank the almighty God for His strength grace and mercy that has enabled me reach this far. I wish to thank County government of Trans-Zoia Ministry of Medical Services for sponsoring me to pursue a Masters in Clinical Cytology.

I wish to extend my sincere gratitude to all those who contributed directly or in indirectly to the success of this project.

Special gratitude to my supervisors Prof. L. Muchiri, Dr W. Waweru and Dr M. Kanini for their tireless effort in guiding me through all the stages of this work.

Great appreciation to the pathology residents who assisted with touch imprint smears and all my study participants.

Sincere gratitude to all cytology staff headed by Joyce Kiremu.

Special gratitude to all staff, former and current students in the Department of Human Pathology.

My heartfelt appreciation to my fellow students and family members for encouragement and their moral support.

TABLE OF CONTENTS

DECLARATION.....	ii
CERTIFICATE OF SUPERVISION.....	iii
DEDICATION.....	iv
ACKNOWLEDGEMENT.....	v
TABLE OF CONTENTS.....	v
LIST OF FIGURES.....	viii
LIST OF TABLES.....	ix
LIST OF ABBREVIATIONS.....	xi
WORKING DEFINITIONS.....	xii
INTRAOPERATIVE CONSULTATION (IC).....	xii
ABSTRACT.....	xiii
1.0 INTRODUCTION.....	1
2.0. LITERATURE REVIEW.....	3
2.1. History of Touch Imprint Cytology.....	3
2.2. Head and Neck Lesions.....	4
2.3. Categorization of head and neck lesions.....	4
2.3.1 Congenital Cystic Lesions.....	4
2.3.2 Inflammatory and Infectious Neck Masses.....	5
2.3.3 Neoplastic Masses.....	5
2.4. Risk Factors Associated With Head and Neck Malignancies.....	5
2.5. Symptoms Associated With Head and Neck Malignancies.....	5
2.6. Treatment and Follow Up.....	6
2.7. Utility of Touch Imprint Cytology in Intraoperative Consultation.....	6
2.7.1. Establish the Nature of a Lesion.....	6
2.7.2. Establish the Presence of A Lesion.....	6
2.7.3. Confirm the Presence of a Benign Lesion.....	6
2.7.4. Confirm That Sufficient Tissue is Present for Diagnosis.....	7
2.7.5. Determine the Presence of Synchronous Lesions.....	7
2.7.6. Determine the Organ of Origin.....	7
2.7.8. Brain and Spinal Cord Lesions.....	7
2.7.9. Determine the Adequacy of Margins.....	7
2.8 Obtaining Of Fresh Tissue For Special Studies.....	7
2.8.1. Establish evidence of invasion.....	7
2.8.2. Determine the presence of infection.....	7
2.8.3. Advantages of TIC of head and neck masses.....	8
2.9.0 LIMITATIONS OF TOUCH IMPRINT CYTOLOGY.....	8
2.9.1. Risks of open (tissue/incision biopsy).....	8
2.9.2.0 Indications for head and neck lesions for biopsy.....	9
2.9.2.1. Lymph nodes.....	9
2.9.3. Differential diagnosis of head and neck masses.....	9
2.9.3.1. LYMPH NODE.....	10
2.9.4. CYSTIC LESIONS.....	11

3.2. OBJECTIVES	19
3.2.1. Broad objective	19
4.5. Selection criteria	21
4.5.1. Inclusion criteria.....	21
4.5.2. Exclusion criteria.....	21
4.6. Sample size calculation.....	21
4.7. Sampling method	22
4.8. Ethical approval and consideration	22
4.9. Data collection	23
4.9.1 Research assistants	23
4.9.2. Training of research assistants	23
4.9.3. Data collection tool	23
4.9.4. Recruitment	23
4.10. SPECIMEN COLLECTION PROCEDURE.....	24
4.11. CYTOLOGY EVALUATION.....	24
4.12. REPORTING OF CYTOLOGY RESULTS.....	24
4.12.1. Positive for Malignancy	24
4.12.2. Suspicious for malignancy	24
4.12.3. Negative for malignancy	24
4.12.4. Non-diagnostic	25
4.13. Quality control	25
4.15.0. Data analysis and management	25
5.0 RESULTS.....	26
5.2 Anatomic Site Distribution of Lesions In Relation to Gender.....	27
5.3. Satisfactory Rates of Smears.....	28
5.4. Cytomorphological Findings in Various Sites.....	28
5.4.1. Lymph Node Lesions In Relation To Gender	28
5.4.3. Thyroid Lesions.....	30
5.4.4 Oral Cavity Lesions.....	31
5.4.5. Larynx lesions	32
5.4.7. Salivary Gland Lesions	34
5.4.8 Miscellaneous.....	34
5.4.9 Cytodiagnosis of Cystic Lesions	34
5.7. Cytology Diagnosis of Benign Lesions	36
5.8. Frequency of Malignant Lesions Cytology/Histology Diagnosis.....	37
5.11. Association between age and type of lesion	40
5.16. Comparison between Cytology and Histology Diagnosis.	43
5.17. Diagnostic performance of imprint cytology of biopsies for the diagnosis of head and neck lesions	44
5.19. Inter-Rater Reliability (IRR).....	45
5.20. Cytomorphology of Imprint Cytology Findings	46
6.0 DISCUSSION.....	54

7.0 Study Limitations	61
8.0 Conclusion	62
9.0 Recommendations	62
REFERENCES	63
7.0. APPENDICES	70
Appendix I : Data Collection Sheet	70
Appendix II : Papanicolaou Staining Technique.	72
Appendix III : Modified Pap Technique	73
Appendix IV: Touch Imprint Procedure	73
Appendix V: May Grunwald- Giemsa Staining Technique.....	74

LIST OF FIGURES

Figure 1:Age distribution of head and neck lesions.....	28
Figure 2 :Anatomic site of lesions n-139.	28
Figure 3:Lymph node lesions.....	29

Figure 4:Nasal cavity lesions	30
Figure 5: Thyroid lesions	31
Figure 6 :Oral cavity lesions	32
Figure 7 :Larynx lesions	33
Figure 8: Frequency cystic lesions	35
Figure 9 :Histology /Cytodiagnosis of Cystic Lesions.	35
Figure 10: Cytology diagnosis of benign lesions.	37
Figure 11:Frequency of malignant lesions as seen in cytology/histology diagnosis	38
Figure 12 :Association between age and type of lesion	42
Figure 13:Cytomorphological features of malignant Melanoma of the Eye	47
Figure 14:Cytomorphological features of squamous cell carcinoma:.	47
Figure 15:A: Cytomorphological features of colloid goiter	48
Figure 16:B: Cytomorphological features of colloid goiter Benign colloid nodule	48
Figure 17 :Cytomorphological features of Papillary thyroid carcinoma	49
Figure 18 :Cytomorphological features of Mucocele- acinar formation.	49
Figure 19:Cytomorphological features of: A- Epithelioid sarcoma of the mandiblePlasmatoid cells.	50
Figure 20:. Cytomorphologic features of actinic cheilitis:	50
Figure 21:Cytomorphological pattern of lymphoma. Hodgkin lymphoma-51	
Figure 22:Cytomorphology of B-Large cell lymphoma-	51
Figure 23 :A Cytomorphological features of metastatic nasopharyngeal carcinoma.-	52
Figure 24:Cytomorphological features of metastatic nasopharyngeal carcinoma	52
Figure 25:Cytomorphological features of Paraganglioma (carotid body tumor).Irregular clusters of epithelioid like cells, spindling nuclei and eosinophilic finely granular cytoplasm	53
Figure 26:Cytomorphology of Pleomorphic adenoma.	53
Figure 27 :Cytomorphological features of Brain	54
Figure 28:Cytomorphology of brain abscess: Acute inflammation	54
LIST OF TABLES	
Table 1:Eye lesions diagnosis	33
Table 2: Distribution of head and neck masses as seen on histology and cytology	36

Table 3 :Correlation of imprint cytology with histology diagnosis in anatomical sites	39
Table 4: Association between age and type of lesion	40
Table 5 :Association between demographic factors and location of the lesion	41
Table 6:Association between demographic factors and type of lesion diagnosis	43
Table 7 :Comparison between cytology and histology diagnosis	44
Table 8 :Accuracy, sensitivity and specificity of TIC	45
Table 9:Inter-Rater Reliability (IRR)	46
Table 10: Comparison of sensitivity, specificity and accuracy of TIC in the diagnosis of malignancy with published studies.	57

LIST OF ABBREVIATIONS

BCC:	Basal cell carcinoma
CT:	Computer tomography scan
DPX:	Di-estrene Plasticizer Xylene
EA:	Eosin Azure
ERC:	Ethics and research committee
FISH:	Fluorescence In-situ Hybridization
FNA:	Fine needle aspirate
FNAC:	Fine needle aspiration cytology
EBV:	Epstein-Barr virus
ENT:	Ear Nose and Throat
FS:	Frozen section
GIT:	Gastrointestinal Tract
H&E:	Hematoxylin and Eosin
HIV:	Human immunodeficiency virus
HNC:	Head and neck cancer
HPV:	Human Papilloma Virus
ICC:	Immunocytochemistry
IC:	Imprint cytology
IC:	Intraoperative consultation
INCI:	Intranuclear cytoplasmic invaginations
KNH:	Kenyatta National Hospital
KS:	Kaposi Sarcoma
MEC:	Mucoepidermoid Carcinoma
MEN:	Multiple endocrine neoplasia
MGG:	May Grünwald giemsa
MRI:	Magnetic resonance imaging
N/C:	Nuclear cytoplasmic ratio
NCR:	Nairobi Cancer Registry
NPV:	Negative Predictive Value
OG:	Orange G
PAP:	Papanicolaou

PCR:	Polymerase chain reaction
PPV:	Positive Predictive Value
PI:	Principle Investigator
QA:	Quality Assurance
RS:	Reed Sternberg
SOP:	Standard Operating Procedure
SCC:	Squamous Cell Carcinoma
TAT:	Turnaround time
TI:	Touch imprint
TIC:	Touch imprint cytology
TB:	Tuberculosis
UON:	University of Nairobi
USG:	Ultrasound guided
ZN:	Ziehl Nielsen stain

WORKING DEFINITIONS

IMPRINT CYTOLOGY

This is a technique done by gently touching the surface of the Specimen soon after an excision biopsy with a clean grease free slide without disturbing the integrity of the core or resection surface. The imprint slide is air-dried or fixed immediately using 95% ethyl alcohol and stained.

SCRAPE SMEAR

This is done by using one end of a glass slide to gently scrape the surface of the lesion and make a thin-layer smear which is fixed or air dried and processed. This method generates more cellular slides, useful in evaluation of hypocellular lesions and in collecting cellular specimens for ancillary study.

INTRAOPERATIVE CONSULTATION (IC)

This is when a surgeon requests an opinion during an operation so that they can appropriately manage a patient. Surgeons particularly want to know whether a lesion is malignant or not (1, 2, 3).

It's an integral part of surgical pathology for it provides a rapid intraoperative diagnosis leading to timely and proper management of the patients (19).

MASS LESION

A mass lesion is something that takes up space, a swelling which can be an abscess, benign growth or malignant growth.

ULCER

A breach of the continuity of skin surface, epithelium or mucous membrane caused by sloughing out or disintegration of surface epithelium of inflamed necrotic tissue.

ABSTRACT

Introduction

Intraoperative consultation has offered an important service in patient management. There is need for minimal turnaround time in the laboratory assessment of surgical specimens that will aid the surgeon in formulation of immediate decisions regarding the optimal extent of surgery, diagnosis, rapid initiation of ancillary testing, therapeutic protocol and in guiding surgical management of the patient. The delay in obtaining tissue diagnosis leads to unnecessary apprehension among the patients and delay in definitive workup and treatment. Hence there is need for a rapid on-site evaluation of material obtained during the biopsy procedure.

Touch Imprint cytology (TIC) is one of the upcoming methods that can be used in the diagnosis of malignant and benign lesions in shorter period though the histopathology remains the gold standard.

Aim: The primary goal of our study was to evaluate the role and determine diagnostic accuracy of TIC in the diagnosis of various head and neck lesions and correlate the cytological diagnosis with final histopathological findings.

Materials and Method

The study was undertaken after approval by the KNH/UoN ethical research committee. A descriptive cross-sectional study was conducted on 139 patients who presented with different lesions of the head and neck at the hospital surgical clinics in the ENT, dental and main surgical theater. Intraoperatively, after obtaining the fresh biopsy specimen and prior to placing them in

fixative, imprint smears were prepared and processed. Cytological findings were then compared with final histopathological diagnosis.

Results:

With a male to female ratio of 1.2:1; 139 patients presented with different lesions of the head and neck. The cytology diagnosis analysis determined that 66 cases (47.5%) of the diagnosis were benign, 58 cases (41.7%) were malignant, 8 cases (6%) were suspicious for malignancy while 5 cases (3.6%) were non-diagnostic. The histology diagnosis analysis showed that 56.1% of the diagnosis were benign while 43.9% were malignant. overall diagnostic accuracy of TIC in diagnosing malignant lesions was 92.1% with a sensitivity and specificity of 88 and 94.9% respectively. The measure of agreement based on the Cohen's Kappa analysis showed a Coefficient (k) value of 0.838; which represented an excellent strength of agreement.

Conclusion

1. The commonest benign findings were inflammatory conditions and colloid goiter in adults and inflammatory conditions and cystic lesions in children.
2. The commonest neoplastic lesions in adults were metastatic squamous cell carcinoma, nasopharyngeal carcinoma and lymphoma and in children were 2 cases of retinoblastoma and 1 case each for lymphoma and sarcoma.
3. Intraoperative diagnosis of head and neck malignancies can readily be achieved using touch imprint cytology technique as it can easily be availed at the surgical operative site; moreover, it can offer a rapid and accurate diagnosis for further management of the patient.

Recommendations

1. Initiate the use of TIC technique in the intraoperative consultation on urgent cases to reduce diagnostic delays and improve patient management. This should be institutionalized as a standard practice without delay as the resource inputs are already available in the hospital.
2. Incorporate immunohistochemistry technique, special stains and flow cytometry during TIC analysis to improve its accuracy, sensitivity and speed since most malignant lesions were metastatic to the lymph nodes and others were inflammatory lesions caused by different infectious agents.

1.0 INTRODUCTION

Head and neck masses are a common complaint in patients and constitute a major indication for surgical consultation for definitive diagnosis (75). For early diagnosis fine needle aspiration cytology (FNA) and imaging studies are being used regularly. Final diagnosis is confirmed by histological examination. Due to many processes involved in tissue preparation and processing the biopsy results take long to be available. This leads to unnecessary apprehension among the patients and delay in definitive workup and treatment plans; hence there is need for rapid onsite evaluation of material obtained during the biopsy procedure to aid in the intraoperative decision making between benign and malignant categories. Immediate important decisions regarding the optimal extent of surgery, diagnosis, determination of therapeutic protocol and rapid initiation of ancillary testing and treatment can be made based on such practices. (18).

Differential diagnosis can be attributed to many factors including but not limited to infectious agents, inflammatory conditions and cancers. The sites affected include the oral cavity, oropharynx, hypopharynx, larynx, nasal fossa, paranasal sinuses, thyroid, salivary glands, brain, spinal cord, base of the skull, the skin and the neck.

Clinically, the patients present with a mass, abnormalities on Computer tomography and ultra sound guided scan and sometimes with signs of inflammation. Most of the conditions clinically mimic malignancy (33).

Age and the site especially the location of the mass in the cervical lymphatic nodal chain is important for the primary disease site identification as different conditions have a characteristic lymphatic spread patterns; while persistent or progressively enlarging mass is an indication for biopsy.

Touch imprint cytology is the study of the morphology of cells that exfoliate naturally and removed by artificial means. It's a very simple and cheap method and can be used for rapid onsite tissue. It has been alongside frozen section technique in the gross evaluation of the specimen for adequacy in Computer tomography scan and ultra sound guided core biopsies of masses of various organs, evaluation of sentinel nodes for metastasis and aliquoting of the specimen for special studies (e.g. molecular pathology techniques, flow cytometry) (78).

The procedure routinely used for rapid intra-operative consultation is the use of frozen sections. This involves rapid processing of fresh specimen using freezing microtome (19). The quality of the slides produced is lower due to fixation artifacts (22).

Imprint cytology has emerged as a simple and economical procedure that can be used and still give excellent results (20) (21). The disadvantages are that the depth of infiltration cannot be analyzed and the inability to provide architectural details. Imprint cytology is used in intra operative diagnosis to guide the surgeon's decision and planning (19), (50). This technique is useful in determining the parathyroid gland, assessment of the sentinel lymph nodes (5, 6), adenomatous goiter (7), in determining the surgical resection margins (16), diagnosis of benign and malignant lesions, meningiomas and glioma, basal carcinomas of the skin (8, 9, 10), ovarian cancers, alveolar soft part sarcoma, diagnosis of metastatic tumors and salivary gland tumors (11, 12, 13, 14). It's useful when processing minute specimens that cannot be histologically processed.

Loncar et al TIC observed a diagnostic accuracy, sensitivity, specificity values of 97, 96 and 100% respectively among 174 cases analyzed who presented with laryngeal and pharyngeal tumors. (17)

Hussein et al did a study where TIC was correlated with histologic diagnosis of the corresponding biopsy in 30 patients with head and neck malignancies. The concordance between TIC and paraffin sections was 90%; with a sensitivity of 88% and specificity 92% (8).

Hania et al. studied 70 cases of upper digestive and respiratory malignancies using imprint smear and found a diagnostic accuracy of 96.7% with a sensitivity and specificity of 96% and 100% (56).

Studies done using TIC intraoperatively indicate preparation turnaround time (TAT) of 3-5 minutes. This provides supportive diagnostic information when FS is equivocal or when FS evaluation cannot be done. Imprint cytology plays a significant role in quick diagnosis due to its simplicity and cost effectiveness, thus promoting it to be a better option in routine diagnostic medicine (1).

Epidemiology of head and neck cancer

The malignancies has affected more than 5.5 million people with the oral cavity 2.4 million, throat 1.7 million and larynx 1.4 million globally; thus resulting in more than half a million deaths (32). It is estimated that these cancers constitute about 5–8% of all malignancies world-wide and the trend appeared to be increasing in the third world countries (23, 24). Due to inadequate information and data from Africa the information gathered from hospital-based registries or case series as opposed to the gold standard of population-based registries is inadequate for proper quantification of correct figures (25). Different geographical zones and races exhibit variations in the incidences and occurrence of head and neck cancers. the West countries have low incidences as compared to the Asian continent and Indian subcontinent constituting about 4% of all malignancies with a 40 -50% of all malignancies in (26).

A study done by Gonzalez et al at a hospital in Spain showed a malignancy rate of 40.3%, while Tatomirovic et al at the Institute of Pathology in Serbia demonstrated a prevalence of 36.1% (72,73). A study done by Lucumay et al in Western Tanzania in paediatric patients showed inflammatory lesions (43.9%), congenital (38.5%) and neoplastic lesions (14.9%) (74, 75). A similar study done in Kenya by Ayugi et al in pediatrics showed: Inflammatory (64%), malignant neoplasm (32%) and Lymphomas (42%). The above findings showed significant differences according to country and geographical regions.

Data base of Nairobi Cancer Registry (NCR) have shown that head and neck cancers comprise over 12.8% (697) of all the 5462 cancers reported from all cancer sites with a male to female ratio of 2:1. Among the head and neck sub-sites, oral cancers are the highest at 40.6%, followed by nasopharynx and laryngeal cancers with 20.8% and 13.8 % respectively (27).

2.0. LITERATURE REVIEW

2.1. History of Touch Imprint Cytology

Dudgeon and Patrick first described the use of imprint smears of fresh tissues in the rapid microscopical diagnosis of tumor and found that compared to FS, TIC was reliable and cost effective, provided excellent cellular details (15, 37).

After the pioneering work, this technique has remained forgotten for years. Later on, the immense potential of intraoperative imprint cytodiagnosis has been recognized and has come to be utilized in various diagnostic works (19,38) especially as a tool for rapid onsite evaluation of specimens. (4).

The use of cytology smears during intraoperative consultation has often been neglected favoring use of frozen sections largely attributed to surgical pathologist's relatively higher level of confidence in frozen sections, though many studies done have demonstrated that the diagnostic efficacy of intraoperative cytology is comparable to that of frozen section (36).

A study done by Sato et al. recommended use of modified rapid Pap stain for imprint smears. They suggested that the method was as fast as the ultrafast Pap staining, without any compromise in terms of quality of staining (34).

Suen et al did a study using TIC of 64 cases of skin and soft tissues. They diagnosed 55 cases correctly. They found out that it was difficult to diagnose tumors with dense fibrous stroma as the number of neoplastic cells transferred to the slides was insufficient to enable them arrive at a correct diagnosis. They achieved an accuracy rate of 85.9 % (20).

2.2. Head and Neck Lesions

A broad range of lesions present as a head or neck mass arising from a variety of pathological processes and varying etiologies, presenting as a palpable mass, of variable size, duration, consistency and fixation or displacement to surrounding structure. However, the most ominous are malignant tumors which may be primary or metastatic, both transient and mild infections, while some life-threatening infections also present with neck lymph nodes e.g. tuberculosis, infectious mononucleosis and fungal infections.

2.3. Categorization of head and neck lesions

2.3.1 Congenital Cystic Lesions

They comprise uncommon group of lesions encountered during infancy and childhood. Thyroglossal duct cysts, branchial cleft cysts, and cystic hygromas are the mostly encountered. Thymic and cervical bronchogenic cysts are rarely encountered.

2.3.2 Inflammatory and Infectious Neck Masses

These group of lesions are acquired and include acute inflammatory abscess mostly in the cervical lymph nodes caused by Bacteria, chronic and granulomatous reactions caused by TB, actinomycosis, sarcoidosis and viral infections e.g. infectious mononucleosis.

2.3.3 Neoplastic Masses

They can be benign or malignant tumors arising primarily from thyroid, upper aerodigestive tract, salivary gland, paraganglioma, cervical soft tissues or carotid body tumors.

Metastatic tumors arise from primary sites that includes skin cancer (melanoma), adenocarcinoma from breast, GI tract, genitourinary tract, lung, unknown primary and lymphoproliferative disorders and spread through lymph reticular system to sites, often lymph nodes in the head and neck region (29).

2.4. Risk Factors Associated With Head and Neck Malignancies

Different cancers have different risk factors. Risk factor exposure influences one in the development of cancer but most of the factors do not cause cancer directly. The cancers have many of the same risk factors that include genetic factors e.g. hereditary predisposition, oncogenes derived from mutations in genes that control cell growth patterns, lack or infective tumor suppressor genes; Alcohol intake combined with cigarette smoking, Irradiation e.g. X rays and UV rays, oncogenic virus infections like EBV and HPV which are highly associated (30). Nasopharyngeal carcinoma is associated with EBV, laryngeal carcinoma is associated with HPV and HIV is linked to Kaposi's sarcoma (KS); oral and oral pharyngeal cancers have been in particular associated with use of spices, betel nuts and recurrent oral inflammations caused by chronic irritation; age, sex and immunodeficiency status of an individual and Physical and chemical agents, e.g. industrial and agricultural chemicals.

The nasal cavity and paranasal sinuses are more affected due to exposure to a variety of infections, chemical irritation and antigenic stimulation, mechanical and traumatic effects. This results in the formation of tumor-like and truly neoplastic conditions.

2.5. Symptoms Associated with Head and Neck Malignancies

They vary according to the type, location and size of the mass. Painless or painful mass, local ulceration with or without pain, referred pain to teeth or ear, dysphagia, alteration of speech and persistent hoarseness of voice; unilateral tonsillar enlargement in an adult, persistent unilateral sinusitis, persistent unilateral nose bleeding or difficulty in breathing caused by obstruction

swellings in the nasal cavity, unilateral hearing loss, cranial nerve palsies and loosening of teeth (31).

2.6. Treatment and Follow Up

Factors to consider include the exact location of the tumor, the stage of the cancer and the person's age and general health. Treatment for early operable cancers is surgery, followed by adjuvant radiotherapy, chemotherapy, targeted therapy, or a combination of treatments for persistent and recurrent tumors. Survival rates of some type of cancers have not improved despite advances in medical knowledge (28); thus, regular follow-up care is recommended after treatment. This ensures complete treatment or that a second primary (new) cancer does not develop. Medical checkup could include exams of the stoma, if one had been created, and of the mouth, neck, and throat and regular dental examination is recommended.

Other tests but are not limited to include complete physical exam, blood tests, x-rays, and computed tomography (CT), positron emission tomography (PET), or magnetic resonance imaging (MRI) scan. Thyroid and pituitary gland function should be monitored, especially if the head or neck was treated with radiation.

2.7. Utility of Touch Imprint Cytology in Intraoperative Consultation

2.7.1. Establish the Nature of a Lesion

To establish whether a lesion that needs to be resected is benign or malignant. This is very important to the operating surgeon, as this determines the type of operative procedure or further sampling that he has to make. If malignant, further determinations are required to ascertain a primary or metastatic disease.

2.7.2. Establish the Presence of a Lesion

TIC is utilized to confirm the presence of a lesion or skip lesion in surgically suspicious tissue area.

2.7.3. Confirmation of a Benign Lesion

Bony lesion that are benign can be confirmed for curettage and packing. Certain tissues cannot be studied by frozen section i.e. bone, necrotic tissue and fat. They give accurate results on touch preparations.

2.7.4. Confirmation of sufficient tissue for diagnosis

Rapid onsite evaluation using imprint smear can be utilized to ascertain sufficiency of material before the tissue is sent for histopathological diagnosis e.g. in USG or CT guided biopsies (40). Cellularity and quality of a specimen and selection of appropriate core for histology can also be achieved through this technique. Additional tissue can be requested cytology reveals a hypocellular specimen. This method can screen the entire tumor surface in conditions such as BCC of the skin as the entire tumor surface can be screened (41).

2.7.5. Determine the Presence of Synchronous Lesions

Lesion spotted unexpectedly during an operation can be ascertained using this technique.

2.7.6. Determine the Organ of Origin

Tissue such as parathyroid glands that are too small and difficult to recognize can be sampled using this technique (42, 43).

2.7.8. Brain and Spinal Cord Lesions

TIC has special role in the evaluation of these tissues because they are quite soft and various types of gliomas, meningiomas and other lesions that yield cellular smears (44, 45).

2.7.9. Determine the Adequacy of Margins

This is very important on large resections in a case of malignancy. In a complicated operating site such as in the head and neck, margin clearance of a malignant lesion is very crucial as tumor recurrence can be very aggressive and difficult to treat (41).

2.8 Obtaining of fresh tissue for Special Studies

This include flow cytometry karyotyping, electron microscopy (in 3% glutaraldehyde), FISH (unstained touch imprints, smears, and cytospin), microbiology studies-ZN and gram stain and molecular studies (in RNA preservative) (19).

2.8.1. Establish evidence of invasion

This is used in the assessment of the sentinel lymph nodes and nerves as well as ascertain metastasis at distant organs (13, 48).

2.8.2. Determine the presence of infection

The technique is used to determine the presence of tissue inflammation, granuloma and fungal infection.

2.8.3. Advantages of TIC of head and neck masses

Simple procedure

It's a simple, quick and has ability to maximize cell recovery from very small tissue pieces. It's much less time consuming, easy to adopt, reliable and does not require special instruments (39).

2.8.4. No interference with further characterization of lesion

The technique does not disrupt tissue planes which would make histological studies, tissue marker studies, immunohistochemistry and electron microscopy difficult.

2.8.5. Inexpensive and cost effective

The procedure of imprint cytology can be done even in underdeveloped infrastructure and deficient trained technician and so it's cheap.

2.8.6. Fast procedure and offers informed pre-surgical planning

A precise diagnosis is received through this technique and it provides an immediate result with minimal artifact.

2.8.7. Diagnosis of malignancy when the submitted specimen is limited in quantity

For Small fragments of tissue, that prove to be difficult for FS interpretation, sufficient cells can be obtained for imprint interpretation.

2.8.8. Diagnosis of malignancy confined to one small area of a large specimen

Inadequate sampling can be avoided as the technique can easily cover a larger portion of the specimen.

2.9.0 LIMITATIONS OF TOUCH IMPRINT CYTOLOGY

The mitotic figures in TIC smears are few or absent because they tended to rupture during imprinting nor provide architectural information and it cannot distinguish between in situ and invasive lesions, hence emphasizing the need of FS or histopathological examinations in cases where invasion is the sole criteria to define carcinoma (50).

2.9.1. Risks of open (tissue/incision biopsy)

The procedure contaminates operative field which exposes a patient to recurrence, metastasis and seeding along the biopsy tract as well as formation of scars which interferes with surgery and

cosmesis. The procedure can give rise to complications e.g. fistulae and infections, facial nerve damage, fibrosis reaction, hemorrhage and risks of surgery that include anesthesia reactions, pain bleeding and it's expensive to the client (51).

2.9.2.0 Indications for head and neck lesions for biopsy

2.9.2.1. Lymph nodes

Confirmation of reactive hyperplasia, diagnosis of a suspected infection, malignancy, to document metastasis in a patient with previously diagnosed malignancy and to verify and confirm transformation of a known lymphoma to a higher grade (52).

2.9.2.2. Salivary glands

Useful in an unexplained salivary gland enlargement. This is because it's not clinically possible to distinguish nodular inflammatory fibrosis from a neoplasm. High cervical lymph nodes from lower pole of the parotid or upper jugular lymph nodes it is hard to differentiate from the submandibular gland (5).

2.9.2.3. Congenital cervical cysts

A variety of congenital cervical cysts need to be distinguished from neoplasms with a cystic component e.g. cystic papillary carcinoma of the thyroid and cystic SCC (54).

2.9.2.3. Thyroid

A thyroid nodule that is solitary cold, multinodular or diffuse goiter is indicated for a biopsy and to investigate relatives of patients with multiple endocrine neoplasia (MEN) for the presence of medullary carcinoma, patients suspicious for follicular malignant lesions after FNA biopsy results (55).

2.9.3. Differential diagnosis of head and neck masses

The masses are evaluated by a detailed history, clinical examination and investigation like FNAC, USG, CT scan and excisional biopsy. This includes Patient's age, gender, lifestyle, socio economic status and duration, behavior of lesion, associated symptoms and presenting locations. The spectrum of diseases varies from inflammatory, congenital and developmental, and neoplastic masses.

The diseases that are spread through the lymphatics have characteristic patterns, thus the location of the mass in the cervical lymphatic nodal chain is key for the identification and diagnosis of the primary disease site. A biopsy is useful in this region as it serves as a final test for definitive diagnosis (29).

2.9.3.1. LYMPH NODE

2.9.3.1.1 Acute lymphadenitis:

This is a reactive process due to inflammation of lymph nodes caused by bacteria draining into the lymph nodes. Patients present with tender, swollen and reddened node. Cytologically there is a range of maturation of predominance of neutrophils, few mature lymphocytes and tangible body macrophages with a background of granular cellular debris.

2.9.3.1.2. Chronic lymphadenitis (reactive hyperplasia)

This is the inflammation of lymph nodes for an extended time characterized by follicular hyperplasia, paracortical hyperplasia and sinus histiocytosis with an increase in size and number of follicles, immunoblasts, histiocytes polymorphous population, small lymphocytes, plasmacytoid lymphocytes, centrocytes, centroblasts, tangible-body macrophages, dendritic lymphocytic aggregates, eosinophils, and mast cells.

2.9.3.1.3. Granulomatous lymphadenitis

Occurs in conditions caused by bacteria e.g. TB, actinomycosis, leprosy, syphilis, rhinoscleroma, brucellosis, sarcoidosis, cat scratch disease and fungal infections e.g. rhinosporidiasis, actinomycosis and histoplasmosis. The cytological hallmark for granulomatous lymphadenitis is the epithelioid histiocytes and occasional multinucleated giant cells with or without the causative agent (55).

2.9.3.1.4. Metastatic malignancy

The key to the diagnosis of a metastatic malignancy is the recognition of foreign cells in an aspirate. These cells usually form clusters and should be considered malignant until proven otherwise.

2.9.3.1.5. Squamous cell carcinoma

Larynx is mostly primary site for most metastatic squamous cell carcinomas characterized by large clusters or singly dispersed pleomorphic bizarre cell shapes, spindle and caudate cells and malignant cells. The nuclei are enlarged, irregular angular nuclear outlines, densely hyperchromatic with coarse chromatin. The cytoplasm may be non-keratinized or keratinized with a perinuclear halo with necrotic background (57).

2.9.3.1.5. Adenocarcinoma

Metastatic adenocarcinoma may be from lungs, gastrointestinal tract, breast, thyroid, pancreas or ovary. These present with medium sized to large cells with abundant delicate cytoplasm, flat sheets, acinic “ball like” pattern, rosettes, papillary architecture or singly dispersed cells with

pleomorphic cells. The nuclei exhibit anisocytosis, irregular nuclear outlines, hyperchromasia and prominent nucleoli. The cytoplasm is usually vacuolated (signet ring cells) (58).

2.9.3.1.6. Small cell carcinoma

This is a highly malignant tumor that metastases widely. Most primary head and neck small cell carcinoma arise from the esophagus (secondary small cell carcinomas would be from the lung). It presents in three architectural patterns-mosaic pattern due to nuclear moulding, chains giving an Indian file appearance and singly dispersed cells with highly malignant nuclei with scanty cytoplasm resulting in high nuclei/cytoplasmic ratio (52).

2.9.3.1.7. Lymphoma

These are malignant neoplasms of lymphoid tissue. Hodgkin's lymphoma can be reliably diagnosed cytologically by identification of Reed Sternberg (RS) cells in an inflammatory background.

2.9.3.1.8. Malignant melanomas

They arise in the skin and other extracutaneous sites e.g. the neck and eye. Cytomorphology shows various forms from round, polygonal to spindle or a mixture of all shapes ranging from epithelioid or plasmacytoid cell morphology with abundant, well-demarcated cytoplasm to eccentric nuclei and many binucleated and multinucleated cells. Brown cytoplasmic pigmentation signifying melanin can be absent or present only in occasional cells (60).

2.9.3.1.9. Nasopharyngeal carcinoma

This is a poorly differentiated squamous cell carcinoma that is commonly associated with marked lymphoid infiltration. The primary tumor is clinically occult and presents as a metastatic carcinoma to cervical lymph nodes of unknown primary. Cytology reveals undifferentiated malignant cells singly and in clusters with pleomorphic nuclei that can be elongated or spindling with prominent nucleoli. The cells have variable amount of pale, fragile cytoplasm.

2.9.4. CYSTIC LESIONS

2.9.4.1. Thyroglossal duct cyst

It's a congenital lesion that arise from the thyroglossal duct. Most cysts are located on the midline of the anterior neck and are connected to the hyoid bone. Cytology shows foamy histiocytes, anucleate squames and squamous cells (61).

2.9.4.2. Branchial Cleft Cyst

The cyst is located lateral to hyoid bone. It is a congenital malformation developed from the branchial cleft. Cytology shows anucleate squames and benign squamous cells. Lymphocytes are usually present. If the cyst is infected abundant neutrophils are noted and squamous cells with nuclear atypia may be encountered (62).

2.9.4.3. Thymic Cyst

It arises from remnants of the thymopharyngeal duct that fails to involute. It commonly occurs in the mediastinum. When it occurs in the neck it is most frequently located in the anterior cervical triangle. Cytology shows benign squamous cells and anucleate squames.

2.9.4.4. Cervical dermoid and epidermoid Cysts

These are rare lesions that occur on the neck midline, oral, orbital, or nasal area, along embryonic lines of closure. Cytology shows abundant benign squamous cells and anucleate squames.

2.9.4.5. Metastatic SCC with cystic degeneration.

Cytology shows acute inflammatory cells, necrotic debris and atypical to frankly malignant squamous cells that present as singly, in clusters and sheets of cells.

2.9.4.6. Metastatic Papillary Thyroid Carcinoma with marked cystic change

Cytology may reveal only a clear cystic fluid that shows only foamy histiocytes.

2.9.5.0. SOFT TISSUE LESIONS

2.9.5.1. Lipoma

This is soft tissue neoplasm, occurring mainly in adults between ages 40 and 60 years.

Cytology shows cluster of mature lipocytes surrounded by free fat globules.

2.9.5.2. Rhabdomyosarcoma

It arises in the nasal sinuses or throat or near the eye and spine in the neck of young children. It's highly malignant that invades contiguous structures and metastasizes by both the bloodstream and lymphatics. Cytology reveals two population of cells that exhibit small round blue cells with dark nuclei with fine chromatin and inconspicuous nucleoli with scant cytoplasm. Also present are large polygonal shaped tumor cells with abundant eosinophilic cytoplasm with diagnostic cross striations and myxoid stroma (63).

2.9.5.3. Hemangioma

This is a skin and subcutaneous tissue benign tumor, found on the head and neck producing a so-called strawberry mole or port wine stain. Cytology shows endothelial cells in small sheets or single cells, which vary from round to spindle shaped. The cells have a moderate amount of cytoplasm that ranges from pale and delicate to dense and homogeneous with regular, bland, and typically nuclei that have a longitudinal fold or groove in their nuclear membrane and presence of hemosiderin-laden macrophages (64).

2.9.5.4. Neurofibroma

The tumor affects all nerve components and can presents anywhere in the body. Numerous bland, spindly, comma, and bullet-shaped cells inside the large irregular tissue fragments are seen on cytology (65).

2.9.5.5. Angiosarcoma

Is a tumor of the blood vessels that can arise in any part of the body mostly the skin of the head and neck region. Round, oval, spindle, and epithelioid cells, single cells, pseudo acinar and rosette-like formations, papillary structures, and well-formed small which vessels may be seen on cytology (66).

2.9.5.6. Kaposi Sarcoma

Patients presents with nodular circumscribed, cutaneous and subcutaneous nodules, on the face, inside the mouth and throat, on the outside of the eye and on inner parts of the eyelids.

Cellularity is scanty cytologically with a bloody background; cohesive clusters of bland spindling cells with large, oval nuclei with smooth contours, evenly dispersed chromatin, and non-prominent nucleoli resembling granulomas with stroma. The cells have mild pleomorphism, indistinct cell borders, and prominent nuclear streak artifact. Cytoplasm is moderate and delicate and typically forms tapering tails which blend with that of the adjacent cells. Hyalines globules are occasionally present (67).

2.9.5.7. Cervical Paraganglioma

The tumor arises in the carotid body or glomus jugulare. It's composed of epithelioid cells that varies from uniform to markedly pleomorphic forming rosettes (microacinar-like structures), with round to oval to spindle nuclei with salt and paper chromatin and intranuclear cytoplasmic invaginations. The cytoplasm is abundant and eosinophilic fine granular (68).

2.9.6.0. SALIVARY GLAND

2.9.6.1. Non neoplastic salivary glands lesions

Sialadenosis as well as inflammatory lesions are the frequent encountered lesions. They can be further sub classified into acute, chronic, granulomatous sialadenitis and intraparotid lymphadenitis. Small cohesive fragments of ductal cells and a variable amount of acinar epithelium mixed with lymphocytes and plasma cells seen; or epithelioid cells with elongated or carrot-shaped nuclei and ill-defined cytoplasm admixed with lymphocytes for granulomatous type can be found.

2.9.6.2. Neoplastic salivary gland lesions

2.9.6.2.1 Pleomorphic Adenoma.

Is the benign tumor of the salivary glands. Cytology shows cellularity with a mix of thick cohesive clusters of benign glandular epithelial cells, discohesive ragged groups of plasmacytoid or spindle-shaped cells and oval, plasmacytoid myoepithelial cells with bland nuclei dispersed in mucoid or fibrillar chondromyxoid material (69).

2.9.6.2.2 Warthin's Tumor

Is a bilateral tumor of the parotid, it contains cystic degenerative changes with turbid, rust-colored fluid contents; cytology reveals numerous lymphocytes, 2- and 3-dimensional groups of oncocytes that are cohesive with abundant, granular cytoplasm and granular necrotic debris, squamous and mucinous metaplasia (70).

2.9.6.2.3 Mucoepidermoid Carcinoma (MEC)

Is a malignant tumor of parotid that is the most common and has glandular and intermediate squamous cells. Large tumor may undergo cystic degeneration forming mucous contents admixed with inflammatory cells. MEC may be classified as low or high-grade, depending on the degree of nuclear atypia of the epithelial cells, the extent of mucinous differentiation and the growth pattern. Low-grade tumors have mucus-secreting cells that have abundant, vacuolated cytoplasm and bland nuclei. High grade tumors may resemble non-keratinizing squamous cell carcinoma (71).

2.9.6.2.4 Adenoid Cystic Carcinoma

Is a malignant tumor of other salivary glands and reveals monomorphic cells that exhibit metachromatic "gum balls" with homogeneous basement membrane stroma. The cells exhibit cohesive clusters, cords, solid groups, cylinders, glands or microcystic spaces. Single cells are small and uniform with relatively bland nuclei (59).

2.9.6.2.5 Acinic cell carcinoma

This tumor has a higher incidence among children and is usually bilateral. It is composed of poorly formed, distorted serous microacini and large acinic polygonal cells with abundant delicate, foamy vacuolated cytoplasm with chronic inflammation.

2.9.6.2.6 Malignant mixed tumors.

Carcinoma ex-pleomorphic adenoma occurs in a pre-existing pleomorphic adenoma. It mostly arises in the parotid. Others are very rare and include the malignant mixed tumor (carcinosarcoma) and benign metastising mixed tumor.

2.9.7.0. THYROID LESIONS

2.9.7.1 Benign lesions

2.9.7.1.1 Acute thyroiditis

Patients with thyroiditis presents with enlarged and tender glands caused by bacteria infection e.g. Staphylococcus aureus and streptococcus species and is characterized by an abundance of neutrophils, granular cellular debris, histiocytes and granulation tissue. Follicular epithelium is scant or absent, with signs of reparative changes such as nuclear enlargement and prominent nucleoli. Colloid is absent.

2.9.7.1.2. Hashimoto Thyroiditis

Also called chronic lymphocytic thyroiditis. It's an autoimmune condition characterized with numerous benign lymphoid cells admixed with plasma cells and Hurthle cells that may have a bizarre morphology or lymphohistiocytic aggregates or follicular cells with oncocytic features (Hurthle cells) and variable nuclear atypia on microscopy.

2.9.7.1.3. Granulomatous thyroiditis (Sub-acute thyroiditis)

Is caused by chronic viral infection. Microscopy shows hypo cellular smear with clustered epithelioid cells (granuloma), scattered lymphocytes and a few multinucleated giant cells containing up to one hundred nuclei engulfing colloid.

2.9.7.1.4. Follicular lesions

These encompass goiters as well as follicular neoplasms. A goiter is an enlarged thyroid gland resulting from benign non-neoplastic hyperplasia and colloid storage. Goiters can be simple or multinodular. Follicular neoplasms comprise of follicular adenomas and follicular carcinoma.

2.9.7.1.5. Benign Colloid Nodule.

This group comprises of solitary benign colloid nodules and prominent benign colloid nodules. Cytological picture shows colloid material that is abundant and thick with cracking or bubble pattern and follicular epithelial cells in “honeycomb” arrangement.

2.9.7.2. Malignant lesions

2.9.7.2.1. Papillary thyroid carcinoma

Of all thyroid malignancies this is the most common. Radiation exposure confers a high risk. Cytology shows presence of papillary structures, Orphan-Anne eye nuclei, intranuclear cytoplasmic invaginations (INCI), grooved nuclei and psammoma bodies.

2.9.7.2.2. Medullary carcinoma

A tumor arising from the parafollicular cells or C-cells of the neuroendocrine system. Biochemistry tests of this neoplasm is a combination of elevated serum calcitonin and a thyroid nodule. Cytologically it is recognized by the presence of plasmacytoid, spindling single cells, and amyloid, nuclei with salt and paper chromatin and metachromatic neurosecretory granules.

2.9.7.2.3. Anaplastic giant and spindle cell carcinoma

This is a neoplasm that is rare, but deadly. It is composed of highly malignant pleomorphic large, spindling, elongate and bizarre shapes with dark nuclei that has coarse chromatin. Necrotic debris, tumor diathesis and abnormal mitotic figures are found in the background.

2.9.7.2.4. Hurthle cell neoplasms

Refers to lesion composed exclusively of Hurthle cells; however, it is not possible by cytology alone to distinguish a Hurthle cell adenoma from Hurthle cell carcinoma as this requires demonstration of capsular or vascular invasion on a histological specimen (49).

2.9.7.2.5. Lymphoma

Non-Hodgkin lymphoma is usually of large cell type. Reed-Steinberg cells admixed with benign lymphoid cells and eosinophils is the characteristic cells in Hodgkin's disease in the thyroid is

2.9.8.0. ORAL CAVITY

The oral cavity extends from the lips to the pharynx.

2.9.8.1. Hamartoma

This is a tumor-like malformation composed of mature normal cells in abnormal number or distribution but as a disorganized mass in normal location.

2.9.8.2. Choristoma

Is a disorganized mass consisting of normal cells in an abnormal location. Most occur on the tongue.

2.9.8.3. Papilloma

Squamous papilloma is a benign, exophytic epithelial tumor made of branching fronds of squamous epithelium with fibrovascular cores.

2.9.8.4. Verrucous carcinoma

This is a highly differentiated variant of SCC clinically shows white, warty to fungating, or exophytic lesion. Histology shows a broad base of epithelial proliferation, marked surface, keratinization and a pushing border of bulbous rete pegs with hyperkeratosis.

2.9.8.5. Mucocele

This is a mucus-filled cystic lesion associated with minor salivary glands caused by trauma. Cytology shows hypocellular specimen with mucoproteinaceous background, foamy histiocytes, giant cell, acute and chronic inflammation.

2.9.8.6. Odontogenic Cysts and Tumors

Odontogenic cysts may be inflammatory and developmental. The most common are radicular, or apical, periodontal cysts, which involve the apex of an erupted tooth, usually after infection of the dental pulp.

2.9.8.7. Ameloblastomas

They arise in the odontogenic epithelia and are the most significant odontogenic tumors clinically. Histologically are characterized by islands of odontogenic epithelium with a central stellate reticulum-like area, surrounded by basal cells with a “picket fence” appearance, due to subnuclear vacuoles (47).

2.9.9.0. Nasal cavity and paranasal sinuses

2.9.9.1. Nasal polyps

These are focal inflammatory swellings unilateral or bilateral, single or multiple. Cytological picture shows respiratory epithelium and have mucous cell within a loose mucoid stroma, infiltrated by plasma cells, lymphocytes and many eosinophils.

2.9.9.2. Wegener granulomatosis

Nasal lesions show ischemic-type necrosis, vasculitis, mixed chronic inflammation, scattered multinucleated giant cells and micro abscesses.

2.9.9.2. Nasopharyngeal carcinoma

This is an epithelial tumor in the nasal cavity. The tumor occurs in loose clusters or syncytia with crowded, overlapping nuclei. The cells are less pleomorphic than those of a keratinizing carcinoma and display with conspicuous nucleoli.

3.0. RATIONALE OF THE STUDY

Intraoperative consultation service is not available in most hospitals in resource limited countries like Kenya, as it requires specific and expensive equipment. The only available method is the use of frozen sections which is limited to a few hospitals; however, the method has limitations including interpretation difficult due to freezing artifacts, poor quality sections, bloated cell morphology and undesirable stained sections.

Clinical evaluation of solitary masses of the head and neck is tricky, pose a challenge and can be difficult because of extensive differential diagnosis in this region. Intraoperative consultation and examinations are required for immediate and important decisions regarding the optimal extent of surgery. Rapid and accurate diagnosis is of paramount importance in the outcome of medical care. To confirm malignancy in suspected cases biopsy is the preferred method of tissue diagnosis. Depending upon the resources available however, the biopsy results are available only after 3-7 days thus making it unsuitable for immediate decisions regarding the optimal extent of surgery, diagnosis, rapid initiation of ancillary testing, therapeutic protocol and in guiding surgical management of the patient. Patients apprehension is caused by delay in obtaining tissue diagnosis and thus leads to deferral to definitive workup and treatment of plan. Hence there is need for a rapid on-site evaluation of material obtained during the biopsy procedure.

Imprint cytology has a shorter turnaround time in the diagnosis of malignant and benign lesions thus can be used to overcome delays and save valuable time due to its simplicity, cost effectiveness and rapid results.

The findings from this study may be used by policy makers to formulate guidelines for better patient management.

3.1. RESEARCH QUESTION(S)

1. What is the role of imprint cytology in intraoperative diagnosis of surgically removed biopsies in patients attending surgical clinics at KNH?
2. What is the diagnostic accuracy of imprint cytology in evaluation of head and neck lesions?

3.2. OBJECTIVES

3.2.1. Broad objective

To determine the diagnostic accuracy of touch imprint cytology in the diagnosis of benign and malignant lesions of head and neck at Kenyatta National Hospital.

3.2.2. Specific objectives.

1. To describe the frequency and cytomorphologic patterns of head and neck lesions amenable to touch imprint biopsy in association to demographic factors.
2. To determine the agreement of touch imprint cytology and histology diagnosis.

4.0 MATERIALS AND METHOD

4.1 Study design

This was a descriptive cross-sectional study.

4.2. Study site

The KNH hospital ENT department, main surgical theatre and dental unit; The KNH cytology and histology laboratory were used for sample processing and examination.

4.3. Study population

All patients with head and neck masses referred for biopsy.

4.4. Accessing of study participants

Selected and trained Doctor Interns in the respective clinics identified potential patients awaiting biopsy procedure to be done. They explained to them about the nature of study

4.5. Selection criteria

4.5.1. Inclusion criteria

Patients of all ages who had mass lesions or ulceration in head and neck as clinically or radiological detected and accepted to participate in the study.

4.5.2. Exclusion criteria

Patients who did not consent or assent to participate to the study and those with a history of bleeding/coagulation disorders or any other contraindication.

4.6. Sample size calculation

The sample size was calculated using fisher's formula (77), and based on estimated percentage of correlation as seen from a similar study done by Hussein et.al in 2005 (8). The agreement between touch imprint and paraffin sections was 90%.

With p=estimated percentage of histologic concordance of 90%.

$$n = \frac{Z^2 P (1-P)}{d^2}$$

Where n= minimum

sample size

Z= statistic for level of confidence on normal distribution-critical value set at 1.96 at 95% confidence interval p=estimated percentage of histologic correlation d=level of precision=0.05

$$\frac{(1.96)^2 (0.90) (1-0.9)}{(0.05)^2} = 138.2$$

N= 139 subjects

4.7. Sampling method

Convenience sampling technique method was used. The desired sample size was achieved after patients who met the selection criteria and consented to participate in the study were recruited.

4.8. Ethical approval and consideration

The study was only undertaken after approval by the KNH/UoN ethical research committee-protocol No. P244/04/2018. Permission was sought from the manager in charge of ENT department, Oral, dental clinic and KNH cytology laboratory.

A detailed client information and consent form was administered by a doctor in order to obtain informed consent/assent from the participating patients in the clinic and the ward. Those consenting/assenting were assured of total confidentiality and voluntary nature of participation without coercion. No payment or incentives were offered to the study participants. Counselling of patients on the implication of the results were left to the clinician in-charge.

4.9. Data collection

4.9.1 Research assistants

One registrar working at the ENT Clinic theatre and one dental officer intern in the dental outpatient clinic were recruited as research assistants. Their work included preparing sample preparation area, recruiting and enrolling participants and explaining testing procedures to subjects; verify participants on inclusion/exclusion criteria and obtaining informed consent/assent from subjects, collecting and filling of clinical information data on the questionnaire and preparation of smears.

4.9.2. Training of research assistants

This was done by the principle investigator prior to the start of data collection. Content of the training included knowledge of clinical research terminologies, research protocols, research site management and professional ethics and the skills of data and specimen collection.

4.9.3. Data collection tool

A structured questionnaire was used to interview participants booked for biopsy procedure at the ENT theater and dental outpatient clinic in order to obtain both clinical and demographic data (**Appendix 3**).

4.9.4. Recruitment

Potential participants were identified by the research assistants who introduced themselves. The benefits and rationale of the study was explained to all the participants by the principal investigator. The doctor (registrar) conducted an interview to obtain both clinical and demographic data using a structured questionnaire (**Appendix 3**). The patients were requested to sign the consent form. (**Appendix 1a**).

For minors under the age of 18 years, consent was sought from the parents or guardian accompanying the patient. Assent was sought from the minors below age of 18 years. This was done by explaining what was to be done and what was expected of them in a language they understood. They were asked if they agreed to participate in the study and those that agreed signed the assent form (**Appendix 2**). The principal investigator recorded the demographic data as well as the clinical summary of the patient. The data was entered into the questionnaire (**Appendix 3**). In each case a record of complete history, clinical details along with clinical diagnosis was made.

Patients presented with different symptoms that ranged from headache, nausea, vomiting, vertigo, tinnitus and difficulty with hearing, speech, increasing growth lesion, non-healing ulcer, difficulty in swallowing, hoarseness of voice, anterior and cervical neck swelling, seizures etc.

4.10. SPECIMEN COLLECTION PROCEDURE

Fresh specimens were collected from operation theatre either on a wet gauze or in normal saline. Specimens sent in formalin were not included in the study. Gross pathological features were recorded before imprints were prepared. Specimens were trimmed in the following manner before taking imprints. The lymph nodes and encapsulated tumors were bisected with a sharp knife in one plane. Imprint was taken from different areas. Using gauze excess blood or normal saline was soaked. Then a direct imprint was prepared by pressing a clean glass slide gently on the freshly cut surface of the specimen. In this manner, imprints were obtained on four slides. For brain tumors, smears were obtained by crushing a small piece of tissue on a slide by the surface of another slide and immediately fixed in 95% ethyl alcohol for staining by modified pap technique method. Air dried smears were stained using MGG. All the smears were observed under microscope.

4.11. CYTOLOGY EVALUATION

The slides were examined for presence of cells, their patterns, morphology and background by the principle investigator and confirmed by a qualified pathologist. The findings from imprint cytology were compared and confirmed with those from histology.

Based on the Cytomorphology, lesions were classified as non-diagnostic, benign, suspicious or malignant. The diagnostic accuracy was reviewed after histopathological diagnosis was made.

4.12. REPORTING OF CYTOLOGY RESULTS

4.12.1. Positive for Malignancy

Cells seen as clustered with overlapping nuclei and prominent nucleoli, irregular nuclear outlines with marked pleomorphism, nucleoli frequently large and eccentric or for lymphoid malignancies monomorphic picture of singly dispersed lymphoid cells.

4.12.2. Suspicious for malignancy

Cells with limited degree of atypia.

4.12.3. Negative for malignancy

Normal appearing cells in shape size.

4.12.4. Non-diagnostic

Impressions with scanty cellularity and preparation artifacts e.g. obscuring blood, thick smear or technical error in obtaining desirable imprints.

4.13. Quality control

Standard operating procedures (SOP) were used and adhered to during the touch imprint preparation, processing, staining examination.

The study was conducted by trained qualified and competent personnel at KNH and UoN during specimen collection, sample processing and analysis of results. Materials and reagent used were of certified standard that included use of clean slides, current reagents and stored according to manufacturer's instructions.

All the smears were analyzed by the principal investigator (PI) and reported by two pathologists Dr. W. Waweru and Prof. L.W Muchiri. Discrepant findings were evaluated by a third pathologist Dr. Mary Kanini.

4.15.0. Data analysis and management

Analysis was carried out in consultation with a professional statistician. The data was collected, entered, cleaned and analyzed using Microsoft excel as well as STATA version 15 software.

The cases were reviewed for information on gender, age and anatomical and site location of lesion. Comparison between genders, age groups and site and anatomical location were performed. We divided the age to six categories: less than 20 years, 20-34 years, 35 to 44 years, 45-54 years, 55-64 years, 65 and above years.

The results of touch imprint staining were compared with histological findings and presented in form of tables, bar charts and pie charts. Statistical significance difference was obtained for non-neoplastic, premalignant, and malignant lesions.

For statistical purpose, lesions were grouped as malignant or benign. The analysis was done by using chi-square test for comparison between TIC and histology techniques. Diagnostic accuracy was calculated (76). Kappa agreement test was applied to find the respective agreement with final histopathology report. Value more than 0.75 was considered to give excellent significance.

5.0 RESULTS

A total of 139 patients were seen over a period of 3 months that had head and neck masses resected for pathological assessment. 78 (56%) were males and 61(44 %) female as shown in table 1.0. The age of the presentation was ranging from 1 to 85 years with a male to female ratio of 1.2:1. The mean age was 42.7 years; median age was 42 years (interquartile range: 29 - 58 years). The most cases were developed in 35-44 years and 20-34 years with 29 cases (20.9%) and 27 cases (19.4%) respectively as shown in figure 1.0. The histopathology diagnosis analysis showed that 78 cases (56.1%) of the diagnosis were benign/reactive while 61 cases (43.9%) were malignant out of which 25 cases (39.1%) showed squamous cell carcinoma of different grades. The remaining cases include nasopharyngeal carcinoma 13 cases (20.3%), lymphoma 8 cases (12.5%), sarcoma cases 3 (4.7%), meningioma 3 cases (4.7%), papillary thyroid carcinoma 2 cases (3.13%), retinoblastoma 2 cases (3.1%), glioblastoma 1 case (1.6%) each for adenoid cystic, mucoepidermoid and follicular carcinomas. malignant fibrous histiocytoma and carcinoma Ex-pleomorphic adenoma as show in figure 12.0.

The oral cavity was the most common site with 31 cases (22.3%), thyroid 21 cases (15.1%), lymph nodes 19 cases (13.7%), larynx 16 cases (11.5%), nasal cavity 15 cases (10.8%), eye 8 cases (5.8%), brain 7 cases (5%), salivary glands 7 cases (5%) and 15 cases (10.8%) from miscellaneous anatomic sites which included scalp, ear, carotid and posterior neck as shown on figure 2 .

Imprint cytology was reported in 134 instances (97.1%), 66 cases (47.5%) benign, 58 cases (41.7%) malignant and 5 cases (3.6%) nondiagnostic. Among the 58 malignant cases (41.7%), squamous cell carcinoma had 23 cases (39.7%), nasal pharyngeal carcinoma 13 cases (22.4%), lymphoma 8 cases (13.8%), sarcoma 3 cases (5.2%), meningioma 2 cases (3.4%), papillary thyroid carcinoma 2 cases (3.4%), retinoblastoma 2 cases (3.4%) and 1 case (1.7%) each for melanoma, adenoid cystic carcinoma, retinoblastoma, glioma, adenocarcinoma and mucoepidermoid carcinoma. 8 cases (6%) were suspicious for malignancy by cytology but malignant cells were found on histological evaluation thus false negatives.

5.1 Head and neck lesions distribution according to age

Lowest age was 1 year and maximum was 85 years. The intermediate age was 42 years (interquartile range: 29 - 58 years). Majority of respondents, 29 (20.9%) and 27 (19.4%) respectively, were aged 35-44 years and 20-34 years as shown in the figure 1.0 below.

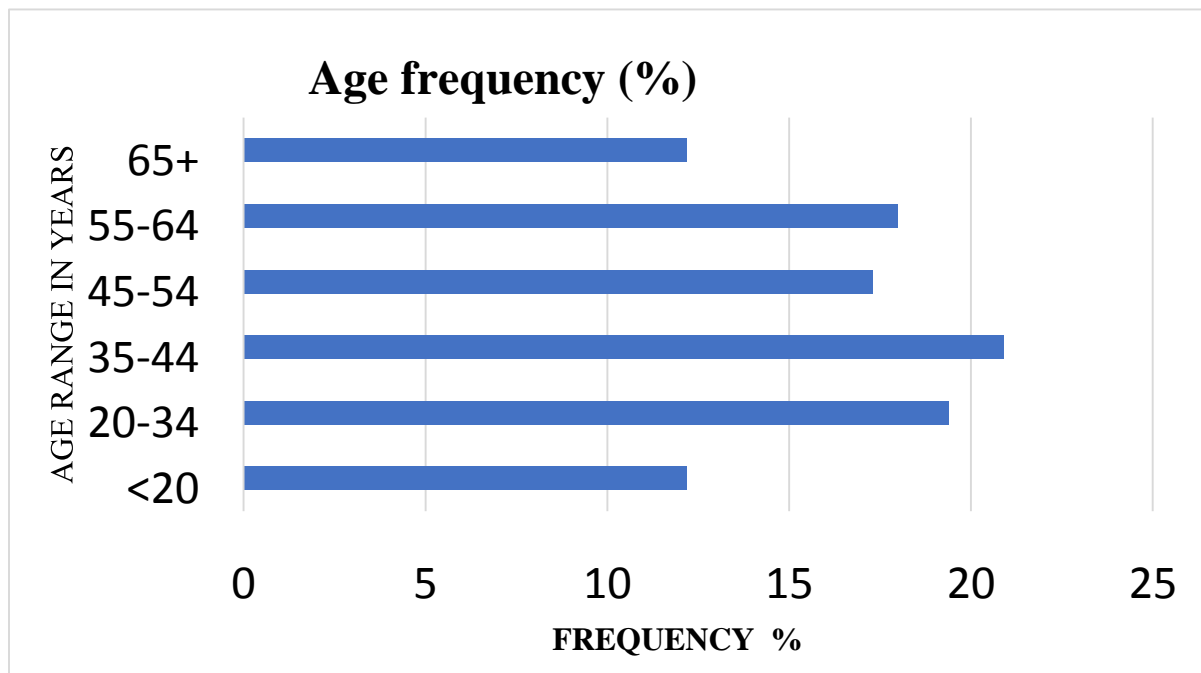


Figure 1: Age distribution of head and neck lesions

5.2 Anatomic Site Distribution of Lesions In Relation to Gender

Oral cavity had 31 cases (22.3%), thyroid 21 cases (15.1%), lymph nodes 19 cases (13.7%), larynx 16 cases (11.5%), nasal cavity 15 cases (10.8%), eye 8 cases (5.8%), brain 7 cases (5%), salivary glands 7 cases (5%) and 15 cases (10.8%) from miscellaneous anatomic sites which included scalp, ear, carotid and posterior neck are shown in the figure 2.0 below.

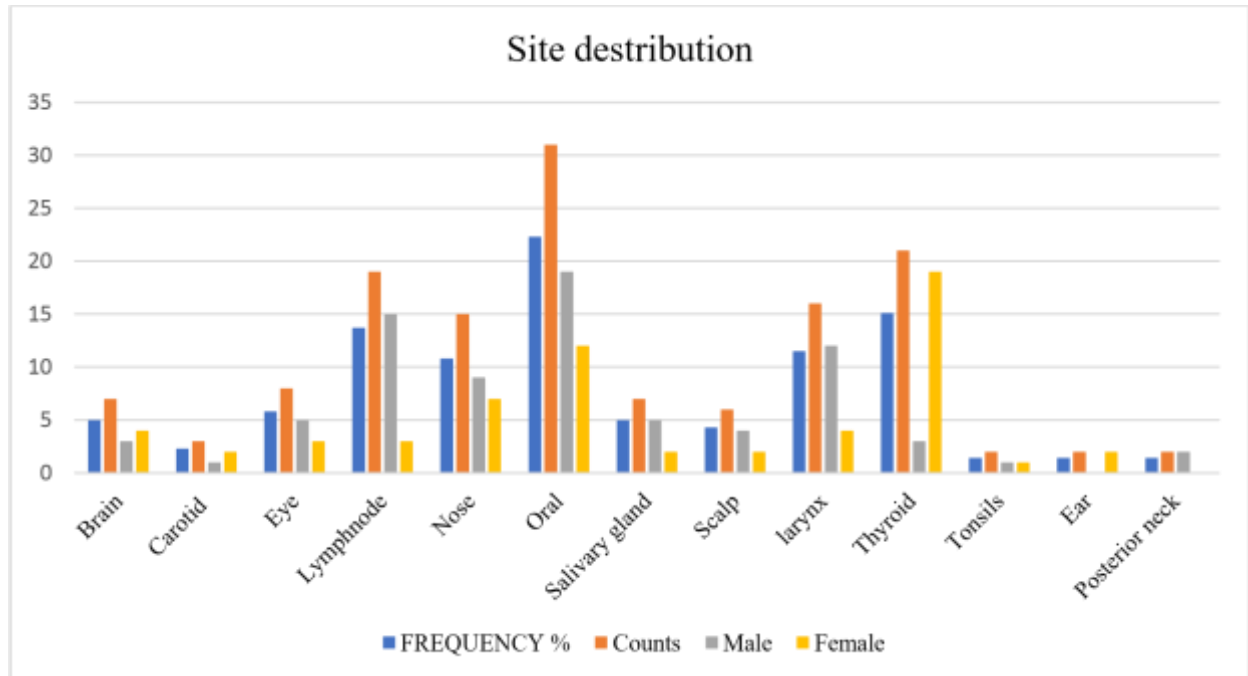


Figure 2 :Anatomic site of lesions n-139.

5.3. Satisfactory Rates of Smears

Satisfactory aspirates were obtained from 134 cases (96.4%) while unsatisfactory rates were obtained from 5 cases (3.6%). On individual lesion analysis, oral lesions had the highest unsatisfactory rate of 3 cases (60 %) while 1 case (20%) each was obtained from the scalp and ear. Among the samples 3 cases (60%) were diagnosed as hemangioma on histology and 1 case (20%) was reported as keloid on histology. The remaining 1 case (20%) was unsatisfactory due to inadequate material obtained also reported as unsatisfactory on histology.

5.4. Cytomorphological Findings in Various Sites

5.4.1. Lymph Node Lesions In Relation To Gender

Most aspirates were obtained from males 15 cases (78.9%) while only 4 cases (21.1%) were from females. Metastatic carcinoma had the majority of cases 8 cases (42.1%) due to nasopharyngeal carcinoma, lymphoma 6 cases (31.6%) cases and lymphadenitis was the common inflammation with 5 cases (26.3%). These results are shown in the figure 3.0 below.

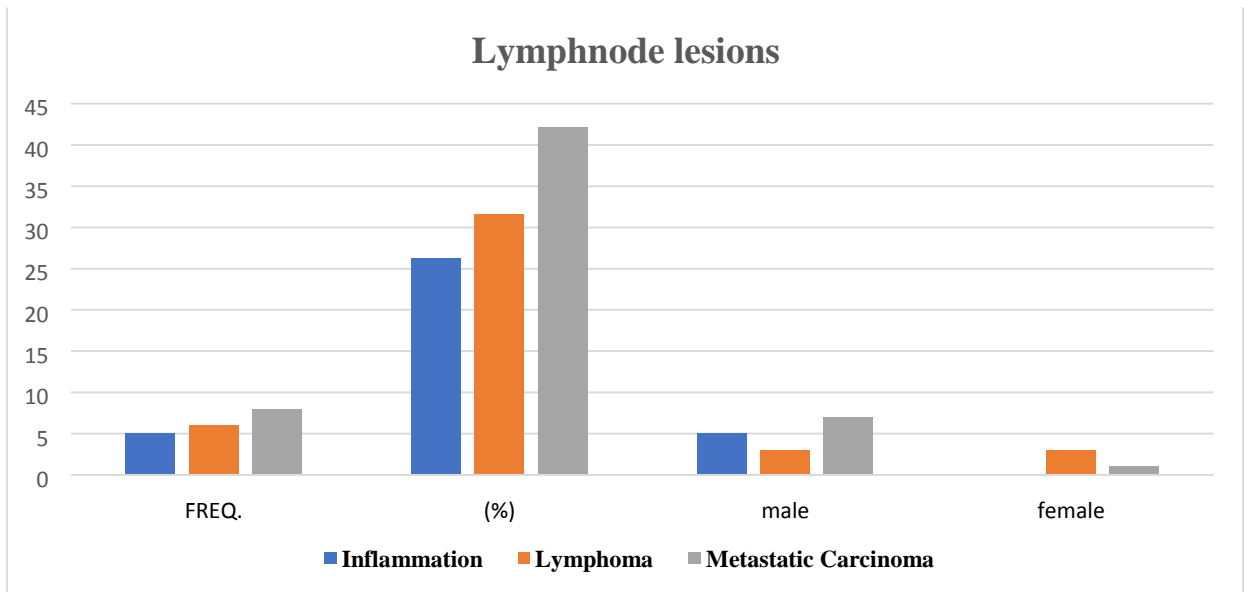


Figure 3: Lymph node lesions

5.4.2. Nasal cavity lesions

Most aspirates were obtained from males 9 cases (60%) while 6 cases (40%) from females. Imprints from nasal cavity revealed nasopharyngeal carcinoma in majority of the cases with 8 cases (53.3%), inflammation and lymphoma with 2 cases (13.3%) each, 1 case (4.4%) each for squamous cell carcinoma, fibroma and suspicious for malignancy respectively. These results are shown in the figure 4.0 below.

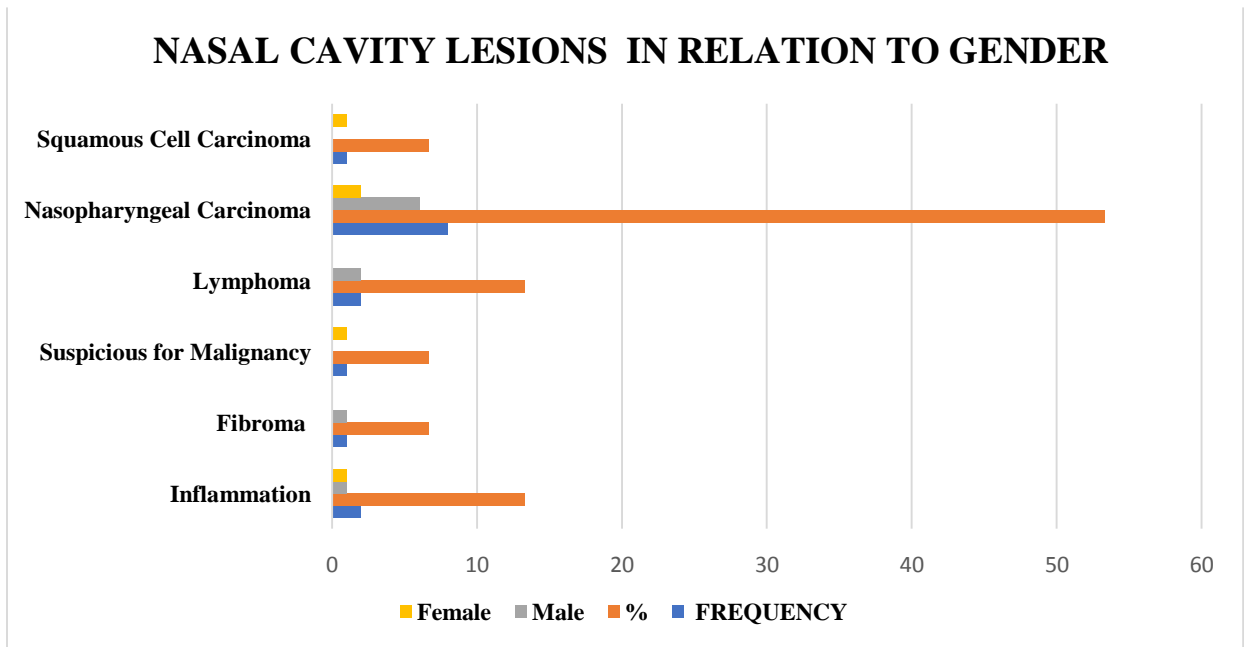


Figure 4: Nasal cavity lesions

5.4.3. Thyroid Lesions

Most thyroid aspirates were obtained from females 18 cases (85.7%) while 3 cases (14.2%) from males. Colloid goiter was the commonest diagnosis, in 12 cases (57.1%), papillary thyroid carcinoma 2 case (9.6%) while indeterminate follicular lesions reported in 3 cases (14.3%) of cases, Graves' disease 1 case (4.8%), follicular adenoma 1 case (4.8%), lymphocytic thyroiditis 2 cases (5.6%) and thyroglossal duct cyst 1 case (4.4%) as shown in figure 5 below.

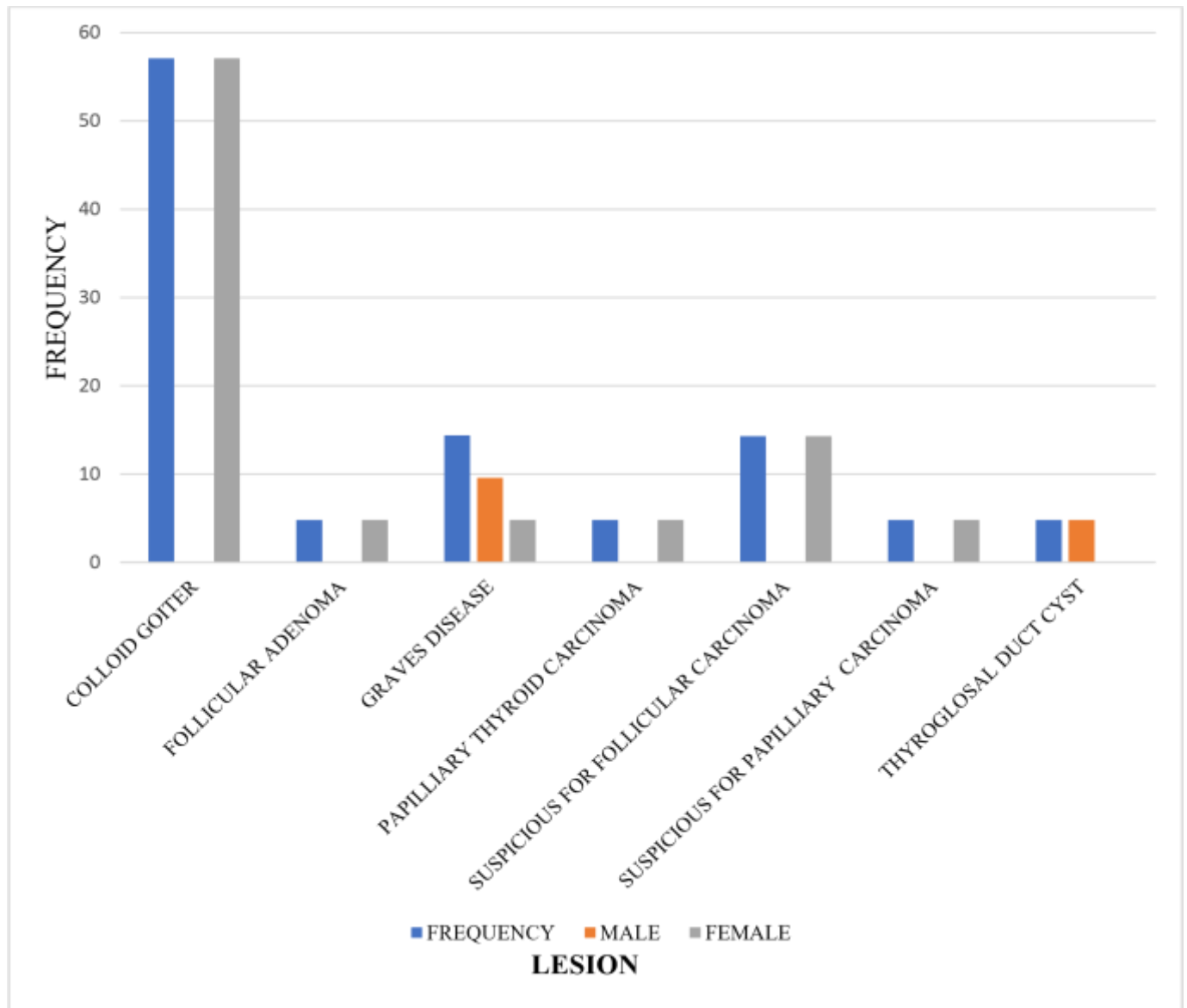


Figure 5: Thyroid lesions

5.4.4 Oral Cavity Lesions

Most aspirates were obtained from males 19 cases (61.1%) and 12 cases (38.7%) from females.

Squamous cell carcinoma was the highest malignancy in 6 cases (19.4%), mucocele 4 cases (12.9%), ameloblastoma 3 cases (9.6%), sarcoma 2 cases (6.5%), fibroma 2 cases (6.5%), actinic cheilitis 2 cases (6.5%), granuloma 1 case (3.2%), papilloma 1 case (3.2%), inflammation 1 case (3.2%), capillary hemangioma 1 case (3.2%), odontogenic cyst 1 case (3.2%), giant cell tumor 1

case (3.2%), suspicious for malignancy 1 case (3.2%) and nondiagnostic results had 3 cases (9.6%). The diagnoses are shown in the figure 6.0 below.

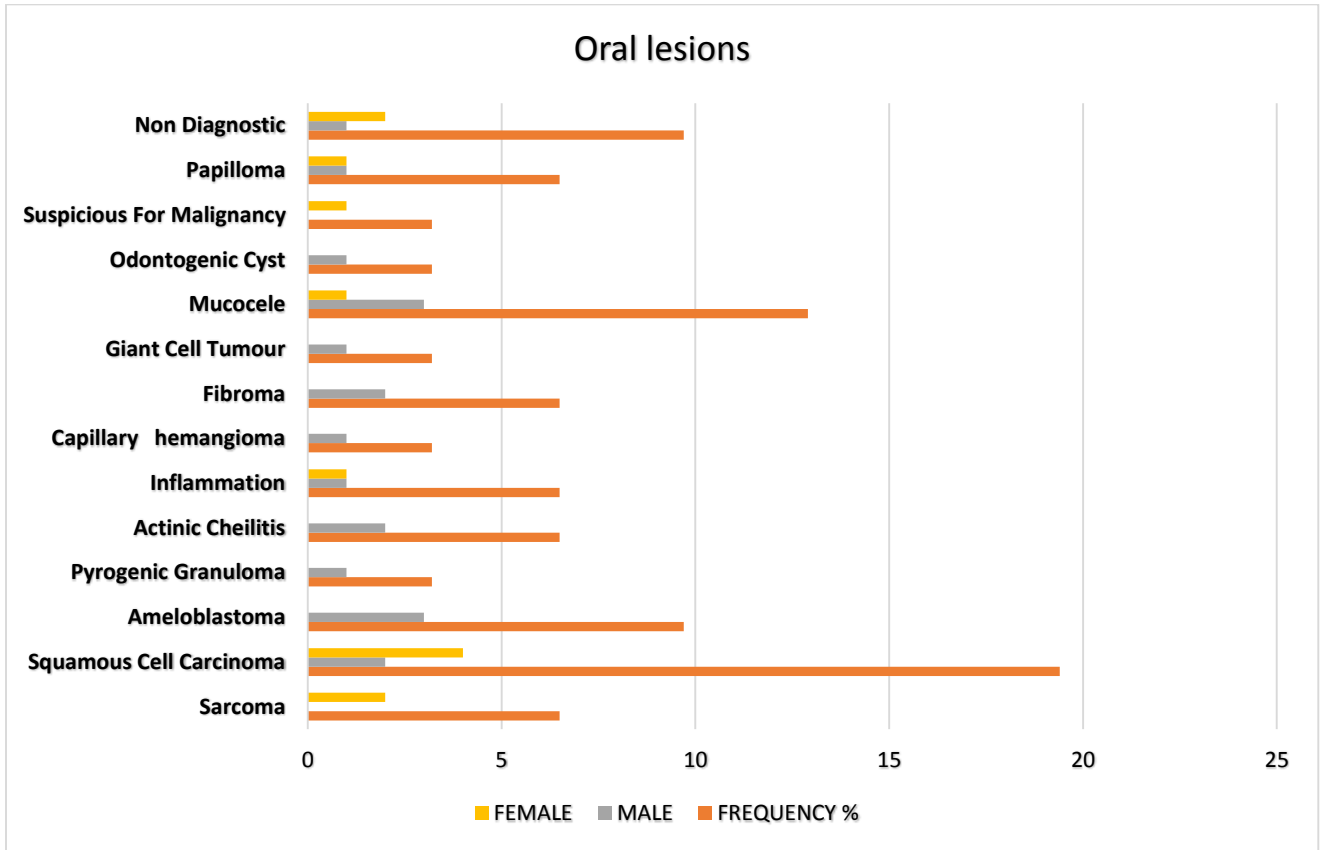


Figure 6 :Oral cavity lesions

5.4.5. Larynx lesions

Most aspirates were obtained from males 13 cases (81.3%) and 3 cases (18.7%) from females. Squamous cell carcinoma had 13 cases (81.25%); adenocarcinoma, chronic inflammation and suspicious for malignancy had 1 case (7.1%) case each. The results are shown in the figure 7.0 below.

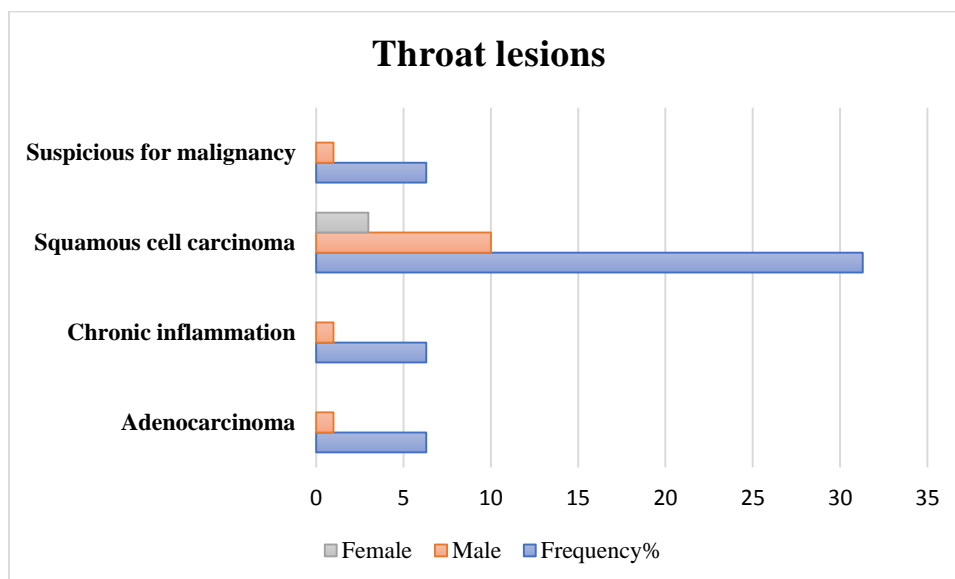


Figure 7 : Throat lesions

5.4.6. Eye lesions

Most aspirates were obtained from males 5 cases (81.3%) while 3 cases (18.7%) from females.

There were 8 cases that showed 2 cases (25%) epidermoid cyst, 2 cases (25%) papilloma, 2 cases (25%) retinoblastoma, 1 case (12.5%) each for malignant melanoma, squamous cell carcinoma as shown on the table 1 below.

Table 1:Eye lesions diagnosis

Lesion	Count	Frequency%	Male	Female
Epidermoid cyst	2	25	2	0
Retinoblastoma	2	25	1	1
Papilloma	2	25	1	1
Squamous cell carcinoma	1	12.5	0	1
Malignant melanoma	1	12.5	1	0
Total	8	100	5	3

5.4.7. Salivary Gland Lesions

A total of 7 cases were obtained. Pleomorphic adenoma 2 cases (28.6%) while adenoid cystic carcinoma, mucoepidermoid carcinoma, epidermoid cyst, inflammation had 1 case (14.3%) each. One suspicious for malignancy case (14.3%) was found which showed carcinoma Expleomorphic adenoma on histology.

5.4.8 Miscellaneous

This is a heterogeneous group of lesions from diverse anatomic sites which includes scalp, carotid, posterior neck, brain, tonsils and ear. The commonest diagnosis was inflammatory conditions in 6 cases (30%), malignant 4 cases (25%) that included 2 cases for meningioma, 1 case glioma, 1 case sarcoma; 3 cystic cases (15%) 2 cases for epidermoid cyst and 1 case cystic Hygroma; paraganglioma 3 cases (15%) and 3 cases (15%) were non diagnostic.

5.4.9 Cytodiagnosis of Cystic Lesions

A total of 13 cases were encountered both congenital and acquired cysts. The epidermoid cyst was highest with 6 cases (46.2%), mucocele 4 cases (30.8%), cystic lymphangioma, odontogenic cyst and thyroglossal duct cyst that had 1 case (7.7%) each. cytology had more lesions diagnosed as cystic as compared to histology. Cytology identified two cystic lesions as epidermoid cyst and mucocele which were reported as inflammation on histology. There was no malignancy encountered in all of the samples as shown on the figure 9.0 and figure 10 below.

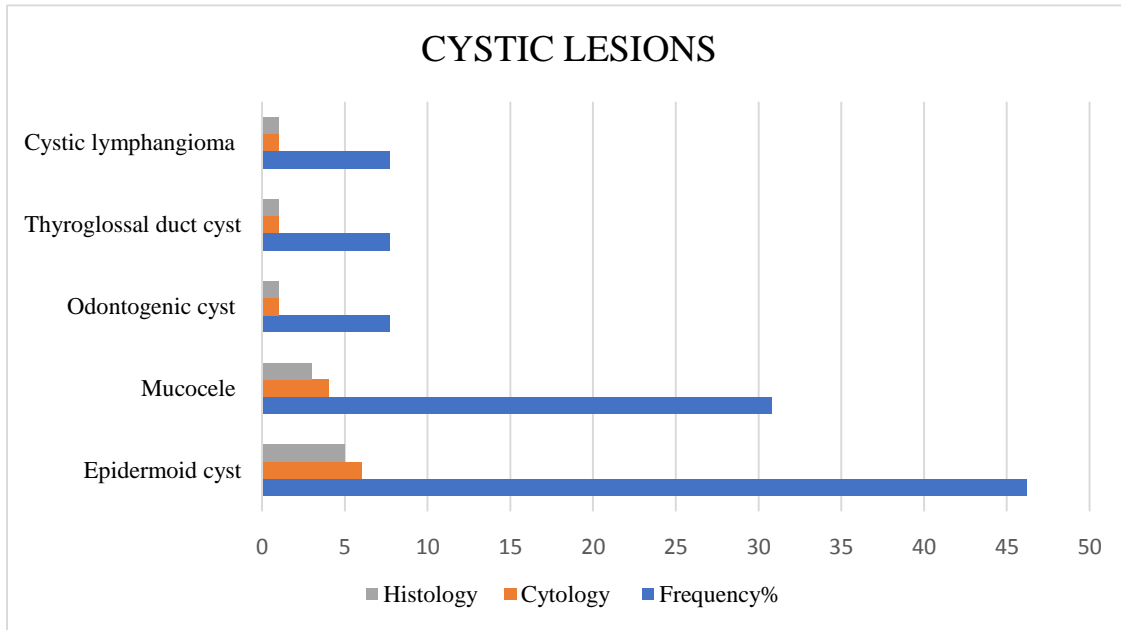


Figure 8: Frequency cystic lesions

5.5. Histology /cytodiagnosis of cystic lesions

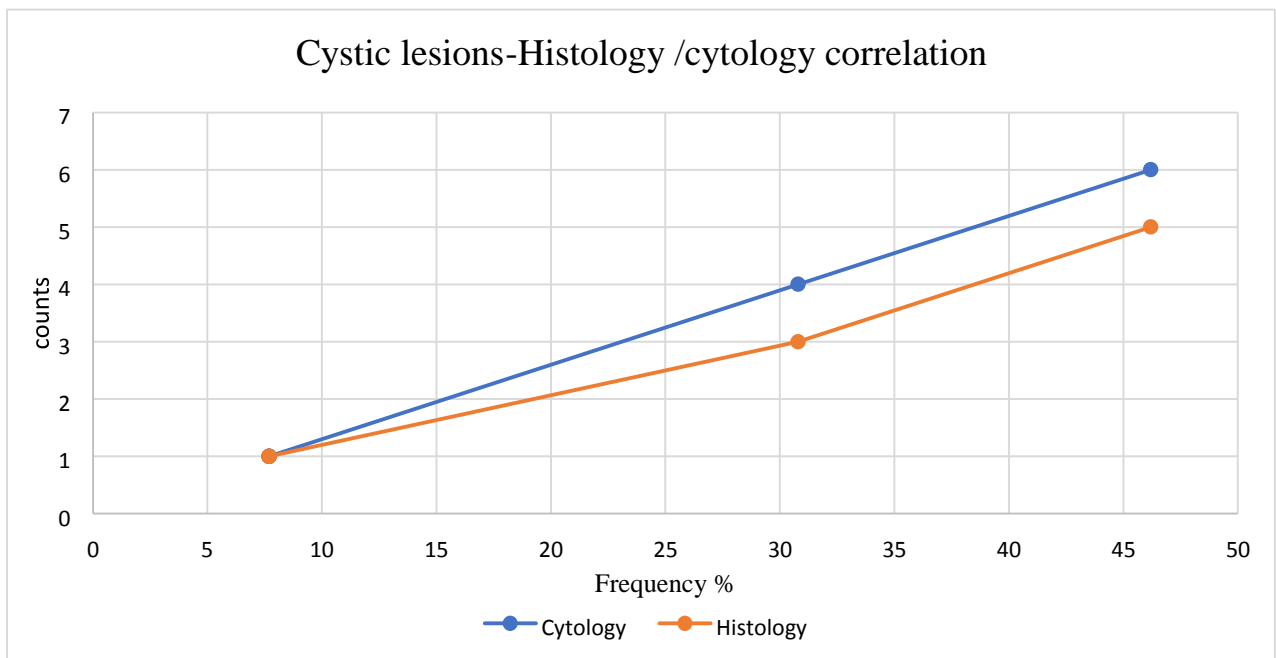


Figure 9: Histology /Cytodiagnosis of Cystic Lesions.

5.6. Head and neck lesion distribution as seen on histology and cytology.

Most lesions both benign and malignant were correctly identified on cytology. There were many cases of suspicious for malignancy on cytology which were confirmed as malignant on histology that included 2 cases of thyroid follicular carcinoma, 1 case each of fibrous histiocytoma, carcinoma Ex pleomorphic adenoma, atypical meningioma grade WHO grade 2, and squamous cell carcinoma. The remaining 3 suspicious cases included 2 cases of lesions that were reported as mild dysplasia and 1 case that was reported as compound nevi on histology. Other benign lesions were non diagnostic on cytology but confirmed on histology as diagnostic. These included cases of 1 case in a keloid and 3 cases in capillary hemangioma.

Table 2: Distribution of head and neck masses as seen on histology and cytology

Lesion	Cytology	Histology
Diagnosis	Frequency	FREQUENCY
Benign	66	76
Malignant	58	64
Suspicious for malignancy	8	0
Non diagnostic	5	2
Total	139	139

5.7. Cytology Diagnosis of Benign Lesions

Most lesions were correctly identified on imprint cytology. Inflammatory reactions were the most encountered in 18 cases (27.3%), colloid goiter 12 cases (18.2%), cystic lesions 13cases (19.7%) of which epidermoid cyst was the most encountered in 6 cases (9.1%), mucocele 4 cases (6.1%), and 1 case (1.5%) each for odontogenic cyst, thyroglossal duct cyst and cystic hygroma. Other benign lesions included papilloma 4 cases (6%), paraganglioma 3 cases (4.5%), fibroma 3 cases (4.5%), pleomorphic adenoma 2 cases (3%), ameloblastoma 3 cases (4.5%), actinic cheilitis 2 cases (3%), and 1 case (1.5%) each for capillary hemangioma, follicular adenoma, graves' disease, lymphocytic thyroiditis and pyogenic granuloma . The distributions are demonstrated on the figure 11.0 below.

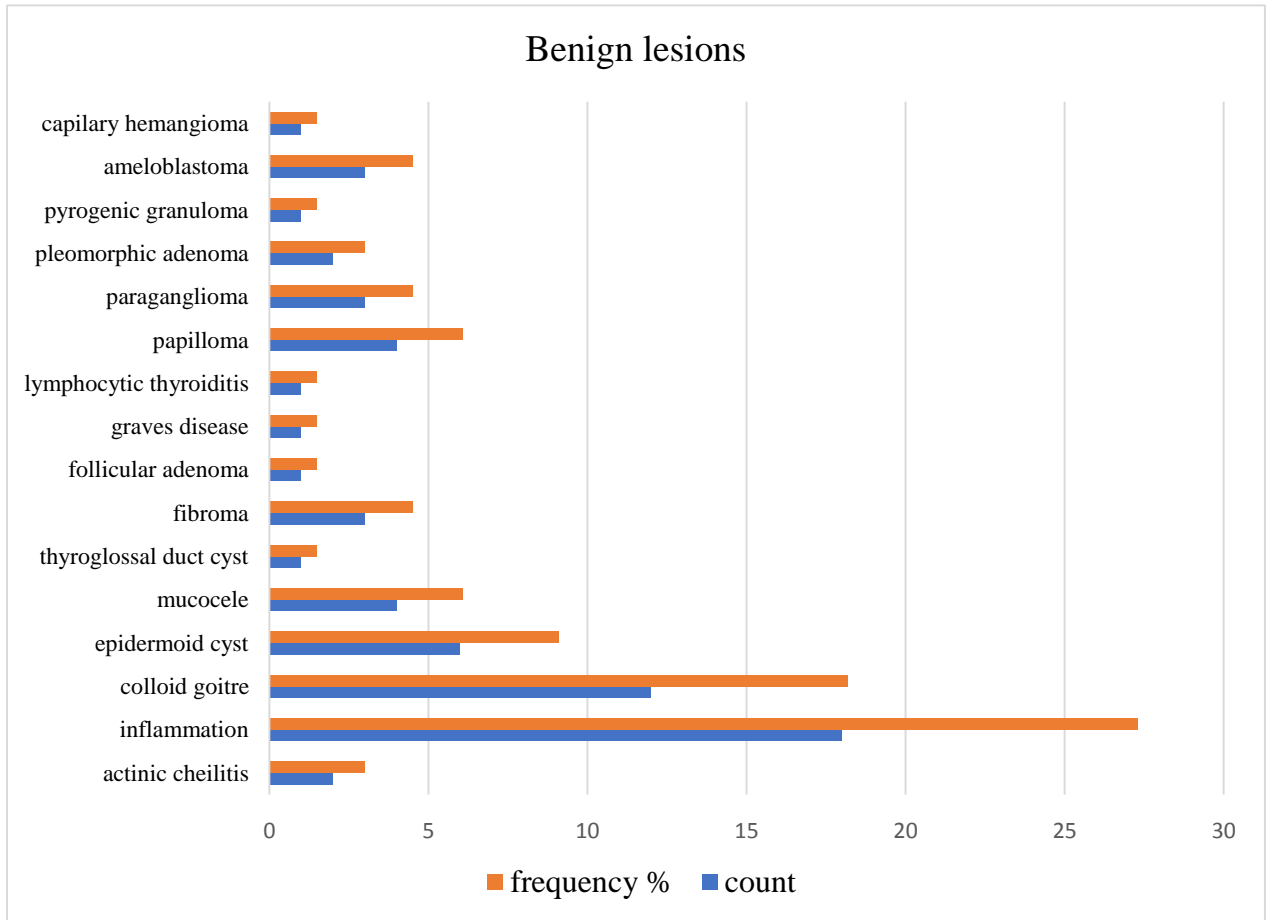


Figure 10: Cytology diagnosis of benign lesions.

5.8. Frequency of Malignant Lesions Cytology/Histology Diagnosis

Most malignancies were correctly identified on both cytology and histology. Histologically squamous cell carcinoma was the most encountered with 25 cases (39.1%); nasopharyngeal carcinoma 13 cases (20.3%), lymphoma 8 cases (12.5%), sarcoma 3 cases (4.7%), meningioma 3 cases (4.7%), papillary thyroid carcinoma 2 cases (3.13%), retinoblastoma 2 cases (3.1%), 1 case each (1.6%) for carcinoma Ex-pleomorphic adenoma, follicular carcinoma and malignant fibrous histiocytoma glioblastoma, adenoid cystic carcinoma and mucoepidermoid carcinoma.

Imprint cytology showing malignancy was found in 58 (43.2%); 56 cases (41.7%) of which were confirmed by histological examination, giving an initial 1.5% rate of inconsistent results. Two (2) specimens were reported as malignant on cytology which were found to have atypical features on histology thus were reported as negative for malignancy.

Overall, 66 cases (47.5%) specimens were negative for malignancy by imprint cytology. 8 cases (6%) were reported as suspicious for malignancy by cytology but malignant cells were found on histological evaluation thus false negatives. This is demonstrated on the figure 12.0 below.

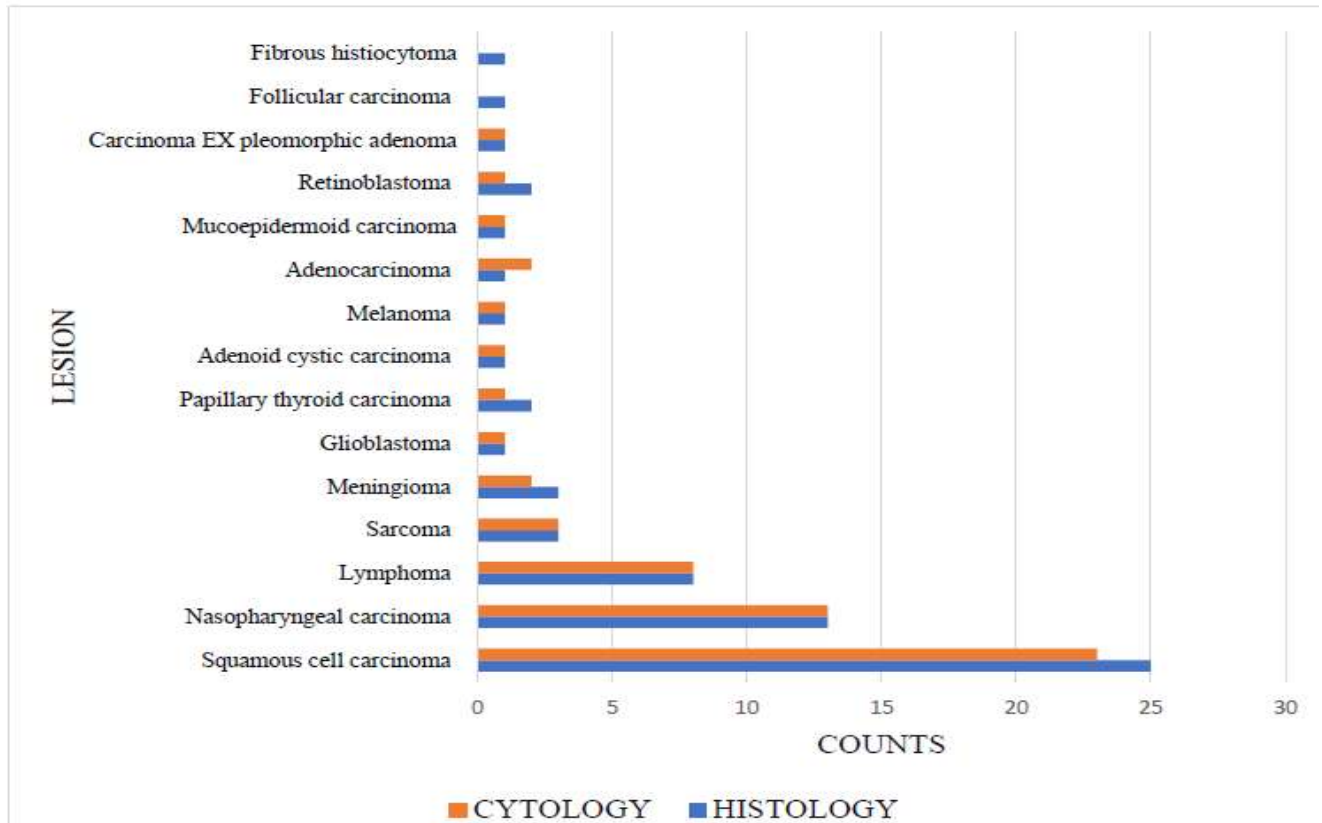


Figure 11: Frequency of malignant lesions as seen in cytology/histology diagnosis

5.9. Cyodiagnosis of malignant lesions as compared to histology diagnosis

Histologically 64 cases (46%) were malignant against 58 cases (41.7%) on cytology. Squamous cell carcinoma was the highest encountered malignancy with 25 cases (39.1%) on histology compared to 23 cases on cytology diagnosis with a 20% discounted rate. Nasopharyngeal carcinoma had 13 cases (20.3%) on both histology and cytology with 100% Concordant. Lymphoma had the highest lymphoid malignancies with 8 cases (12.5%) on both histology and cytology (100%). Meningioma 3 cases (4.7%) on histology compared to 2 cases on cytology

(66.6% concordant), sarcoma 3 cases (4.7%) on both histology and cytology (100% concordant), papillary thyroid carcinoma 3 cases (4.7%) on histology, 2 case on cytology (66.6% concordant). Retinoblastoma 2 cases (3.1%), adenocarcinoma 1 case (1.6%); adenoid cystic carcinoma 1 case (1.6%), mucoepidermoid carcinoma 1 case (1.6%) glioma 1 case (1.6%), melanoma 1 case (1.6%), carcinoma ex pleomorphic adenoma 1 case (1.6%) all had (100% concordant); while follicular carcinoma 1 case (1.6%) had 33.3% concordant rate. By imprint cytology 56 cases (40.3%) cases were correctly diagnosed as malignant.

5.10. Correlation of imprint cytology with histopathological diagnosis in anatomical sites.

Table 3: Correlation of imprint cytology with histology diagnosis in anatomical sites

Anatomical Site	Diagnosed Correctly		False Negative		Total
	NO.	%	NO.	%	
Lymph node	19	100	0	0	19
Oral	27	87.1	4	12.9	31
Nasal Cavity	11	73.3	4	26.7	15
Salivary Gland	6	87.7	1	14.3	7
Brain	5	71.4	2	28.6	7
Scalp	4	66.7	2	33.3	6
Tonsils	2	100	0	0	2
Eye	7	87.5	1	12.5	8
Thyroid	16	76.2	5	23.8	21
Ear	1	50	1	50	2
Posterior neck	3	100	0	0	3
Larynx	15	93.8	1	6.3	16
Carotid	2	100	0	0	2
Total	118		21		139

Imprint cytology correctly identified the lesions as shown in table 3.0. and figure 12.0. Of the 139 cases, 118 cases (84.9%) cases were correctly identified from different sites. 21 cases (15.1%) were not correctly identified. Results shows that there was 100% agreement of cytology and histology on lesions found in the carotid, tonsil, lymph node and in the posterior neck. There was significant deviation between cytology and histology diagnosis in the lesions found in the ear (50%), scalp (66.7%), thyroid (76.2%) brain (71.4%) and nose (73.3%).

5.11. Association between age and type of lesion

	Age group in years						Total
	< 20yrs	20-34	35-44	45-54	55-64	> 65	
Benign lesions all combined	13 (81.3%)	23 (85.2%)	18 (64.3%)	11 (52.4%)	11 (36.7%)	6 (35.3%)	82 (59.0%)
Malignant lesions							
Squamous cell carcinoma	0 (0 %)	0 (0 %)	2 (7.1%)	3 (14.3%)	11 (36.7%)	7 (41.2%)	23 (16.5%)
Nasopharyngeal carcinoma	0 (0 %)	2 (7.4%)	3 (10.7%)	3 (14.3%)	2 (6.7%)	3 (17.6%)	13 (9.4%)
Melanoma	0 (0 %)	0 (0 %)	0 (0 %)	1 (3.6%)	0 (0 %)	0 (0 %)	1 (1.4%)
Adenocarcinoma	0 (0 %)	0 (0 %)	0 (0 %)	2 (9.5%)	0 (0 %)	0 (0 %)	1 (1.4%)
Papillary thyroid carcinoma	0 (0 %)	0 (0 %)	0 (0 %)	1 (4.8%)	0 (0 %)	0 (0 %)	1 (0.7%)
Lymphoma	1 (6.3%)	2 (7.4%)	0 (0 %)	1 (4.8%)	4 (13.3%)	0 (0%)	8 (5.8%)
Retinoblastoma	1 (6.3%)	0 (0 %)	0 (0 %)	0 (0 %)	0 (0 %)	0 (0 %)	1 (0.7%)
Mucoepidermoid carcinoma	0 (0 %)	0 (0 %)	0 (0 %)	0 (0 %)	1 (3.3%)	0 (0 %)	1 (0.7%)
Sarcoma	1 (6.3%)	0 (0 %)	1 (3.6%)	0 (0 %)	0 (0 %)	0 (0 %)	2 (1.4%)
Glioma	0 (0 %)	0 (0 %)	1 (3.6%)	0 (0 %)	0 (0 %)	0 (0 %)	1 (0.7%)
Meningioma	0 (0 %)	0 (0 %)	1 (3.6%)	0 (0 %)	1 (3.3%)	0 (0 %)	2 (1.4%)
Adenoid cystic carcinoma	0 (0 %)	0 (0 %)	1 (3.6%)	0 (0 %)	0 (0 %)	0 (0 %)	1 (0.7%)
Total count	16	27	28	21	30	17	139
% within age group							

Table 4: Association between age and type of lesion

5.12. Association between demographic factors and location of the lesion

There was statistically significant association between age and location of lesion $X^2 = 14.953, p < 0.05$. The analysis also shows that there was an association between gender and location of lesion $X^2 (1) = 11.332, p < 0.05$. as demonstrated on table 5.0 below.

Table 5: Association between demographic factors and location of the lesion

Factor	Location of lesion		square	P value
	Oral Cavity	Thyroid		
<i>Age (in years)</i>				
<20 years	5(16.1%)	1(4.8%)	14.953	0.011
20-34 years	9(29%)	4(19%)		
35-44 years	5(16.1%)	7(33.3%)		
45-54 years	2(6.5%)	8(38.1%)		
55-64 years	4(12.9%)	1(4.8%)		
65+ years	6(19.4%)	0(0.0%)		
<i>Gender</i>				
Male	19(38.7%)	3(14.3%)	11.332	0.001
Female	12 (61.3%)	18(85.7%)		

5.15. Association between Age and Type of Lesion

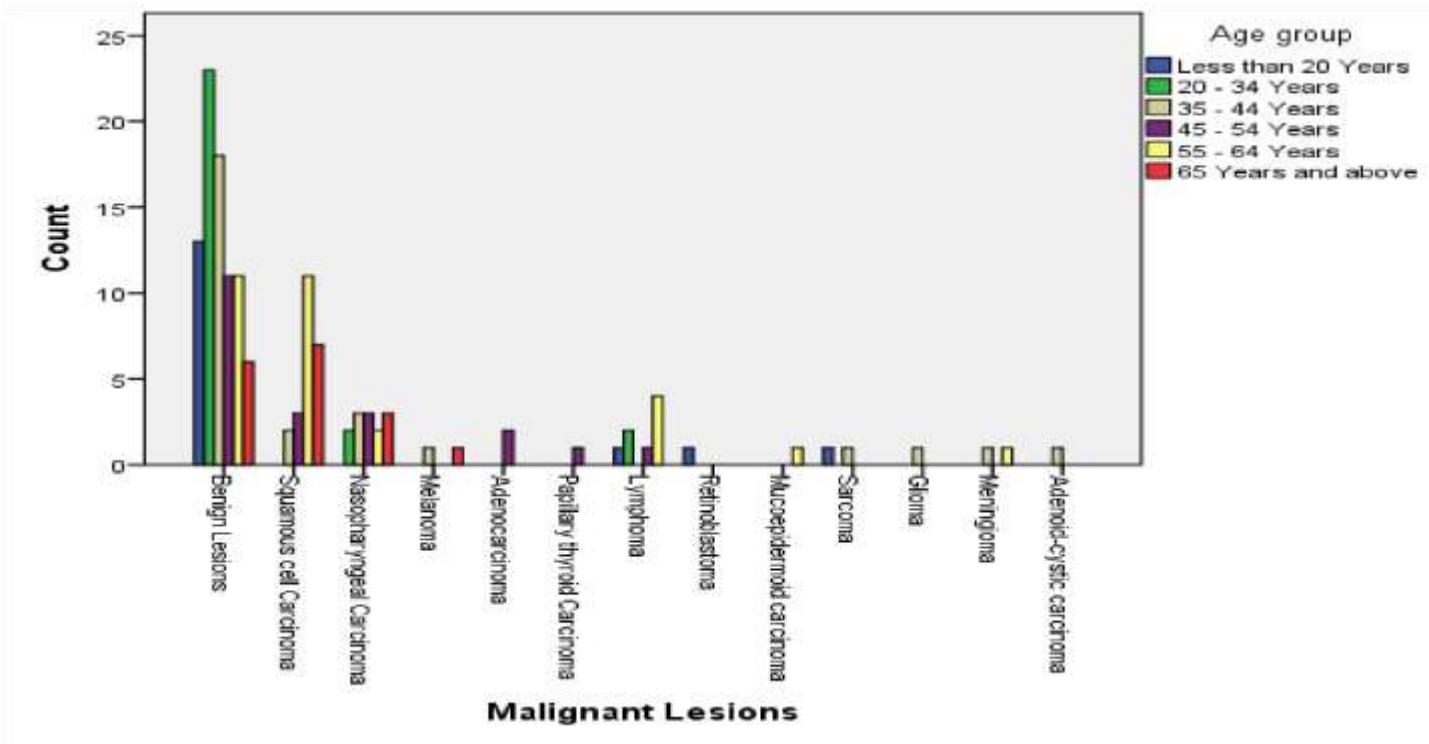


Figure 12: Association between age and type of lesion

The analysis in the table 5.0 and figure 14.0 above shows that most of these conditions are detected with increase in age. The Squamous cell Carcinoma increases among respondents with increase in age, the 35 - 44 Years age group has 8.7% compared to 65 years and above which has 30.4%. The younger age groups do not have incidences of squamous cell carcinoma. The analysis also shows that benign lesions were common in less than 20 years age group, 15.9%, 28% in 20 to 34 years age group and 22% in 35 to 44 years age group.

5.15. Association between demographic factors and type of lesion diagnosis

Factor	Imprint Cytology diagnosis			P value Chi-square
	Benign	Malignant	square	
<i>Age (in years)</i>				

<20 years	13(16%)	4(6.9%)		
20-34 years	22(27.2%)	5(8.6%)		
35-44 years	18(22.2%)	10(17.2%)	17.639	0.03
45-54 years	11(13.6%)	10(17.2%)		
55-64 years	11(13.6%)	18(31%)		
65+ years	6(19.4%)	11(19%)		
sex				
Male	42(51.9%)	36(62.1%)		
Female	39 (48.1%)	22(37.9%)	1.433	0.231

Table 6: Association between demographic factors and type of lesion diagnosis

The findings in table 7.0 shows an association between age and type of lesion $X^2(5) = 17.639, p < 0.05$. The analysis also highlights that gender there is no association between gender and type of lesion $X^2(1) = 1.433, p > 0.05$.

5.16. Comparison between Cytology and Histology Diagnosis.

Table 7: Comparison between cytology and histology diagnosis

<i>Cytology diagnosis x histology diagnosis Crosstabulation</i>					
				<i>Chi-Square</i>	<i>P- Value</i>
		<i>Benign</i>	<i>Malignant</i>		
Cytology diagnosis	Benign	Count	74	97.909	P<0.001
		% within Cytology diagnosis	91.4%		
	Malignant	Count	4		
			54		

	% within Cytology diagnosis	6.9%	93.1%		
Total	Count	78	61		
	% within Cytology diagnosis	56.1%	43.9%		

The comparison between cytology and histology as shown in table 8.0 showed that there was statistically significant association between Cytology and histology diagnosis $X^2 = 97.909$, $p < 0.05$. imprint cytology technique was able to correctly identify both benign and malignant lesions just as histology diagnosis.

5.17. Diagnostic performance of imprint cytology

Diagnostic performance of imprint cytology was compared against 139 histology reports that were available and the overall diagnostic accuracy, sensitivity and specificity determined.

Table 8: Accuracy, sensitivity and specificity of TIC Sensitivity and Specificity Analysis

		<i>Cytology diagnosis * histology diagnosis Crosstabulation</i>			
		<i>Histology diagnosis</i>			<i>Total</i>
		<i>Benign</i>	<i>Malignant</i>		
Cytology diagnosis	Benign	Count	74	7	81
		% within histology diagnosis	94.9%	11.5%	58.3%
	Malignant	Count	4	54	58
		% within histology diagnosis	5.1%	88.5%	41.7%

Total	Count	78	61	139
	% within histology diagnosis	100.0%	100.0%	100.0%

The findings from the table above shows that the possibility of finding a true positive outcome is 88.5% while that of obtaining a true negative outcome is 94.9%. The probability of obtaining a false positive is 5.1% while that of obtaining a false negative is 11.5%. The findings show that the chance of obtaining wrong malignant diagnosis at 5.1% compared to a wrong malignant diagnosis at 5.1%. The accuracy of the touch imprint cytology is 92.1%.

5.19. Inter-Rater Reliability (IRR)

Table 9: Inter-Rater Reliability (IRR)

<i>Symmetric Measures</i>					
<i>Asymptotic</i>					
		<i>Value</i>	<i>Standardized Error^a</i>	<i>Approximate T^b</i>	<i>Approximate Significance</i>
Measure of Agreement	Kappa	.838	.047	9.895	.000
N of Valid Cases		139			

a. Not assuming the null hypothesis.

b. Using the asymptotic standard error assuming the null hypothesis.

The predominant histologic type of malignancy found was squamous cell carcinoma with a sensitivity of 96.2% and specificity 100%; and a diagnostic accuracy being 96.8%.

Lymphoma had a sensitivity of 100% and specificity of 100%. This shows that cytology diagnosis is 100% accurate in comparison with the histology diagnosis.

Cohen's Kappa Coefficient was $(k) = 0.838$ with regard to the presence or absence of malignancy.

The value 0.838 represent an excellent strength of agreement where $p < 0.001$, thus the kappa coefficient is statistically significant from zero. The overall accuracy rate of imprint cytology in the diagnosis of malignant lesions was 92.1% with a sensitivity of 88.5% and specificity of 96.9% with a kappa value of 83.8%.

5.20. Cytomorphology of Imprint Cytology Findings

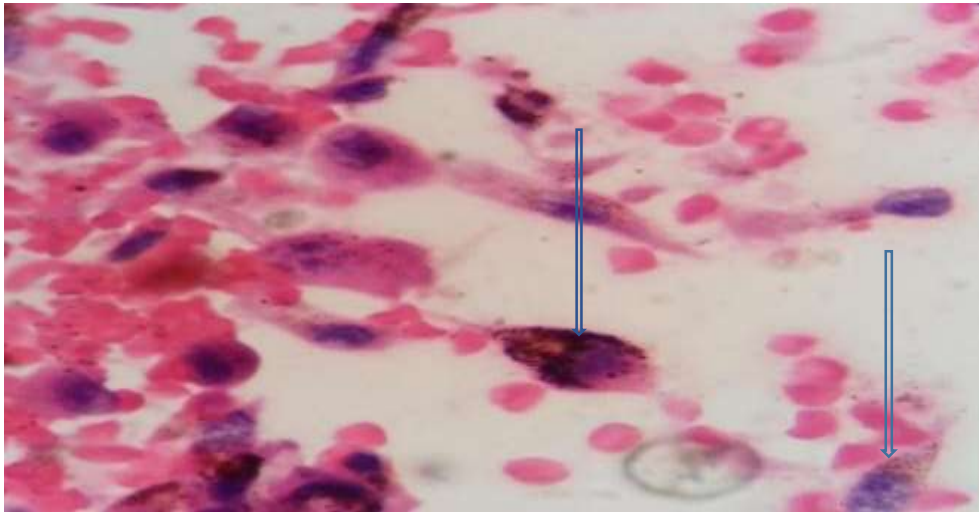


Figure 13: Cytomorphological features of malignant Melanoma of the Eye; Single spindling cells with nuclei that were oval and elongated, with prominent bipolar, slender cytoplasmic processes. Presence of intracytoplasmic melanin brown pigment granules (arrowed). (Rapid Pap X40).

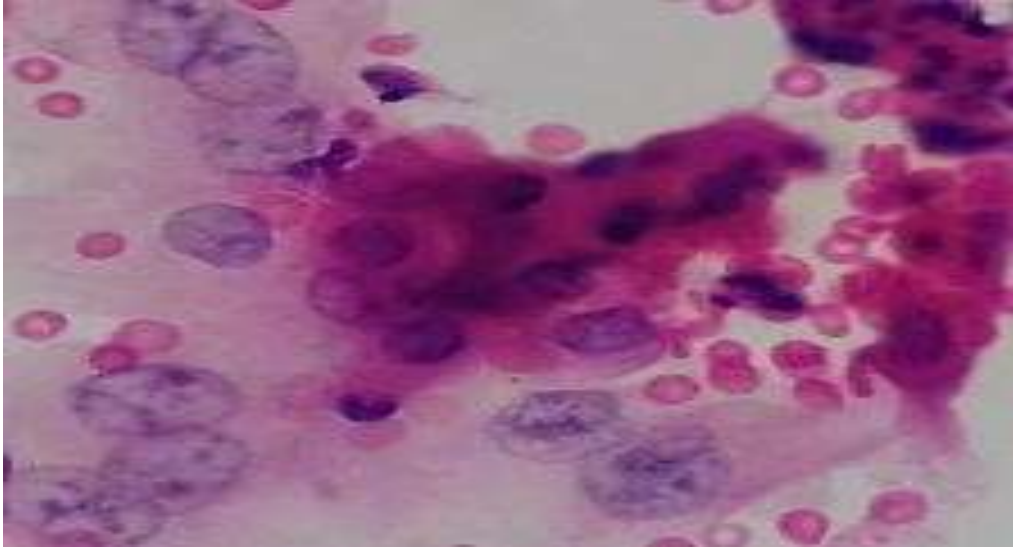


Figure 14: Cytomorphological features of squamous cell carcinoma: Loosely discohesive clusters of squamous cells with round, oval, pleomorphic nuclei and coarse chromatin and abundant cytoplasm. (Rapid Pap X40).

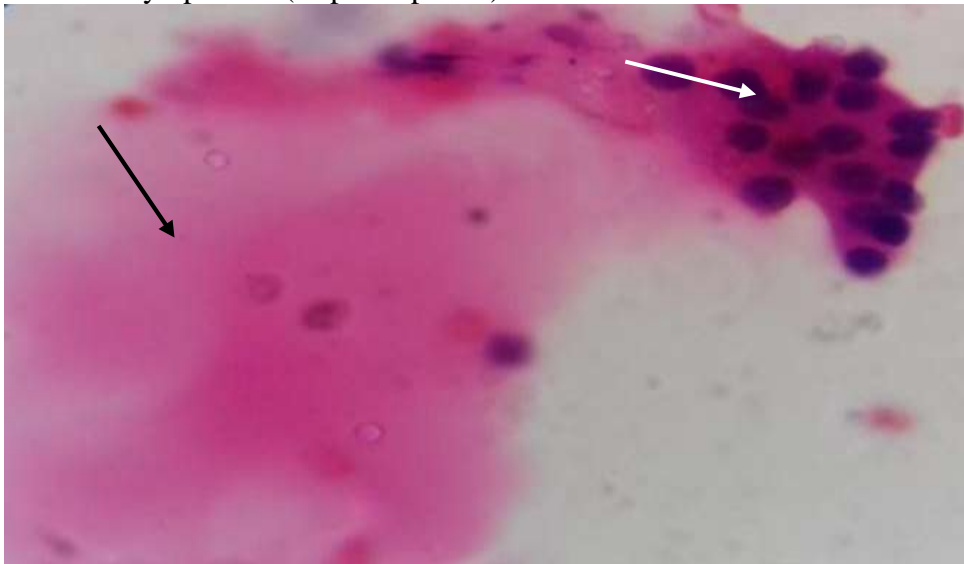


Figure 15:A: Cytomorphological features of colloid goiter: Cohesive cluster of follicular cells (white arrow) and abundant colloid (black arrow) (X40, Rapid Pap)



Figure 16:B: Cytomorphological features of colloid goiter Benign colloid nodule as demonstrated by hard colloid. (arrowed) (X40 MGG).

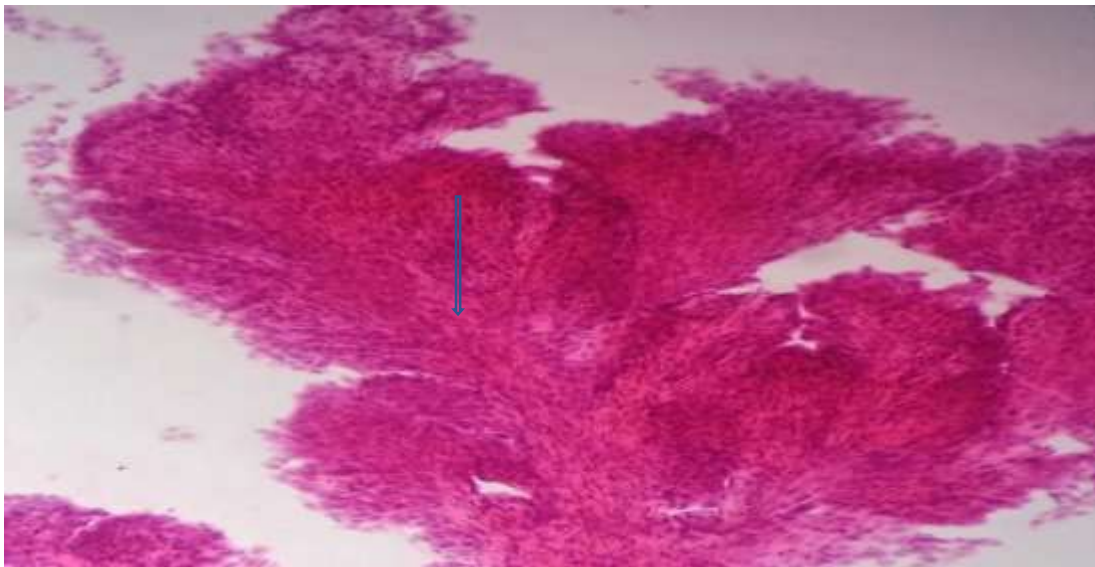


Figure 17: Cytomorphological features of Papillary thyroid carcinoma. Three-dimensional, branching papillae with fibrovascular cores. (X40, Rapid Pap

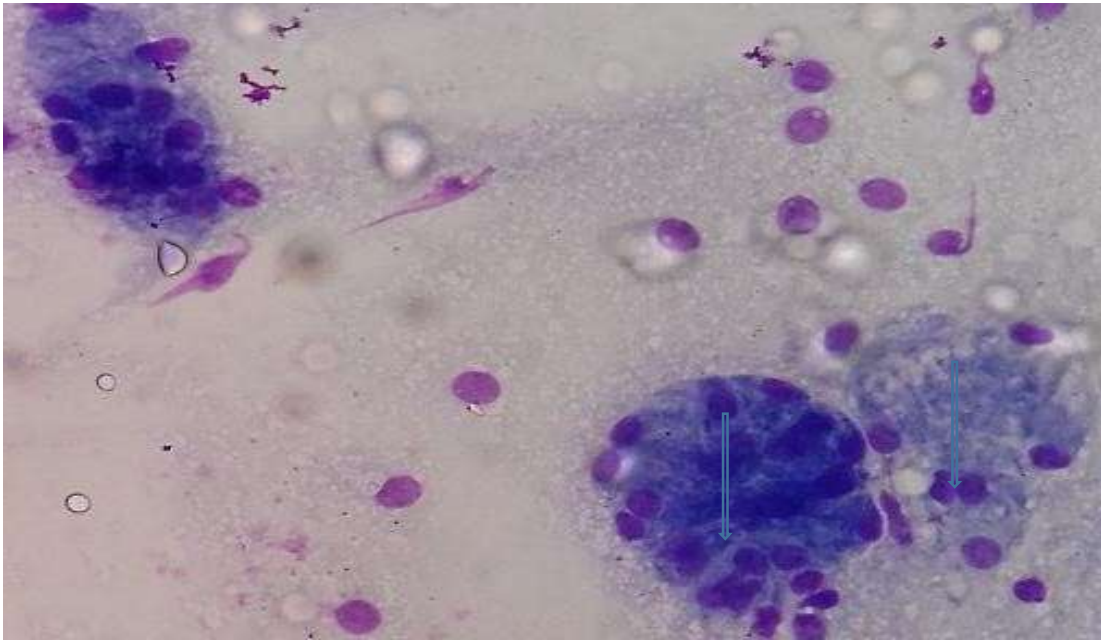


Figure 18: Cytomorphological features of Mucocele- acinar formation. The cells have clear cytoplasmic vacuolation with shrunken, pyknotic peripheral nuclei (X40 MGG);

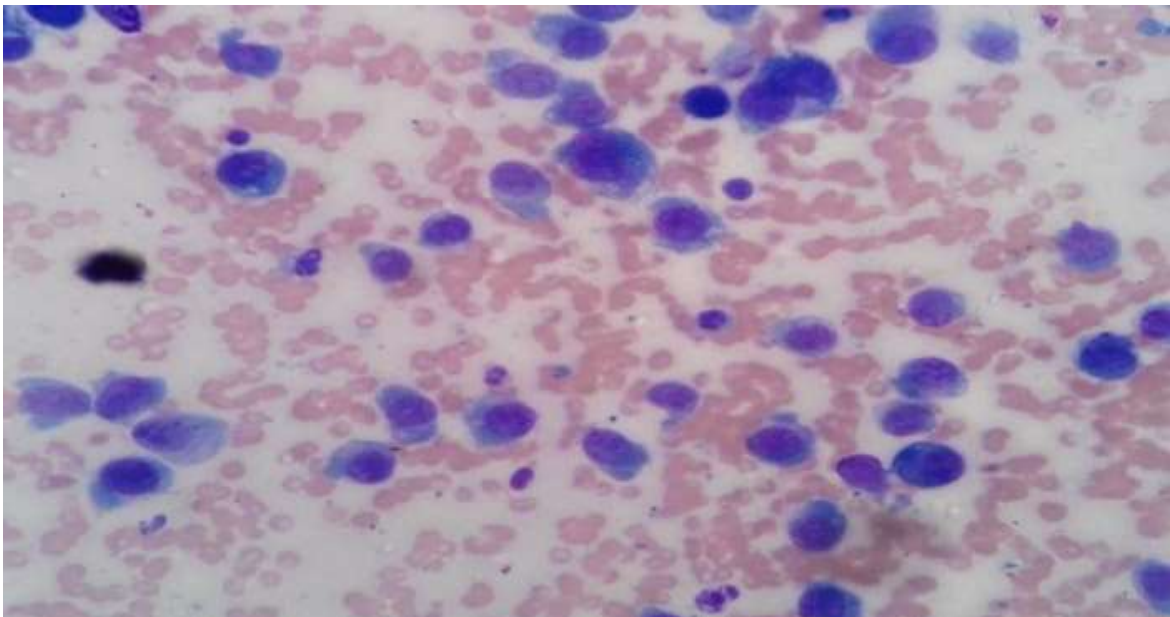


Figure 19: Cytomorphological features of Epithelioid sarcoma of the mandible. Plasmatoid cells; stingily dispersed uniformly appearing cells with abundant cytoplasm with distinct cell boarders, round to polygonal cellular contours, and eccentric nuclei, some are binucleated.

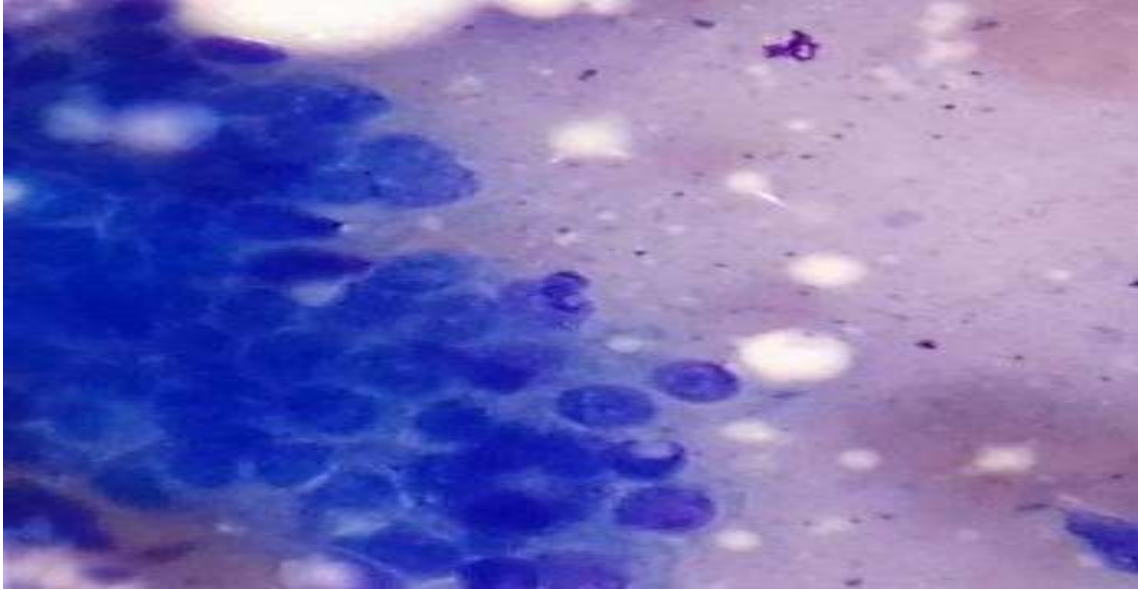


Figure 20: Cytomorphologic features of actinic cheilitis: Honey-comb pattern of benign basaloid cells with scanty cytoplasm. (X40, MGG)

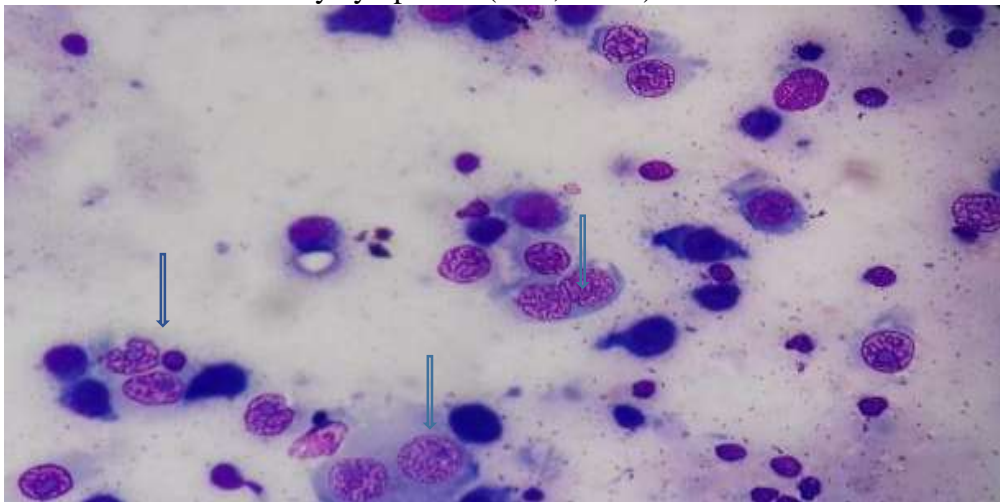


Figure 21: Cytomorphological pattern of lymphoma. Hodgkin lymphoma-Reed-Sternberg cells characterized by two large nuclei that completely resemble each other with prominent macro nucleoli with evenly dispersed chromatin and faint cytoplasm (arrowed) (X40 MGG).

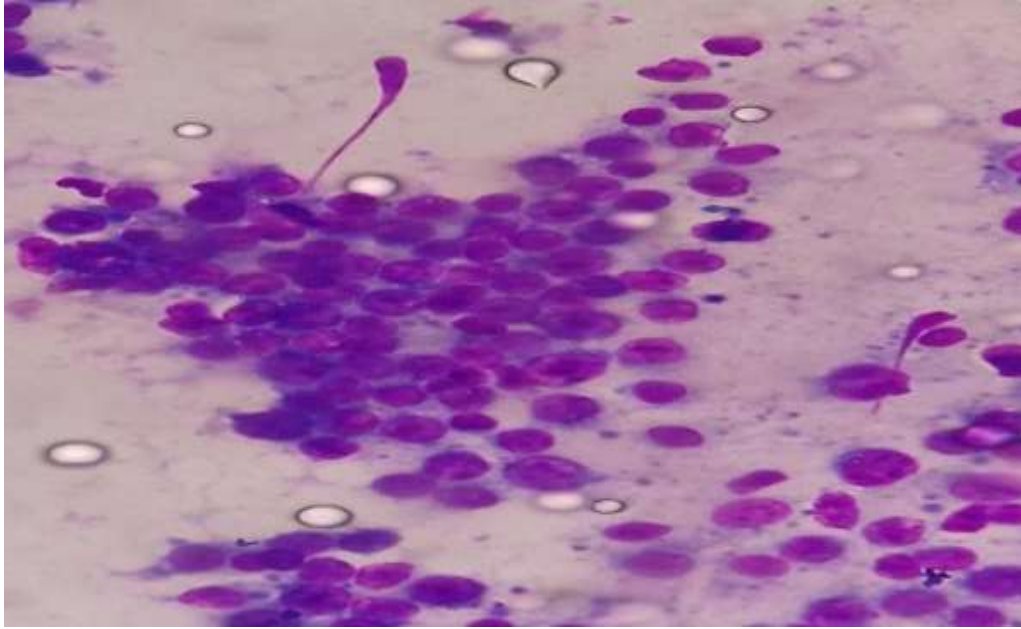


Figure 22: Cytomorphology of B-Large cell lymphoma– Monomorphic cells with solitary nuclei of uniform diameters with inconspicuous to large nucleoli. High nuclear to cytoplasmic ratio (x40 MGG).

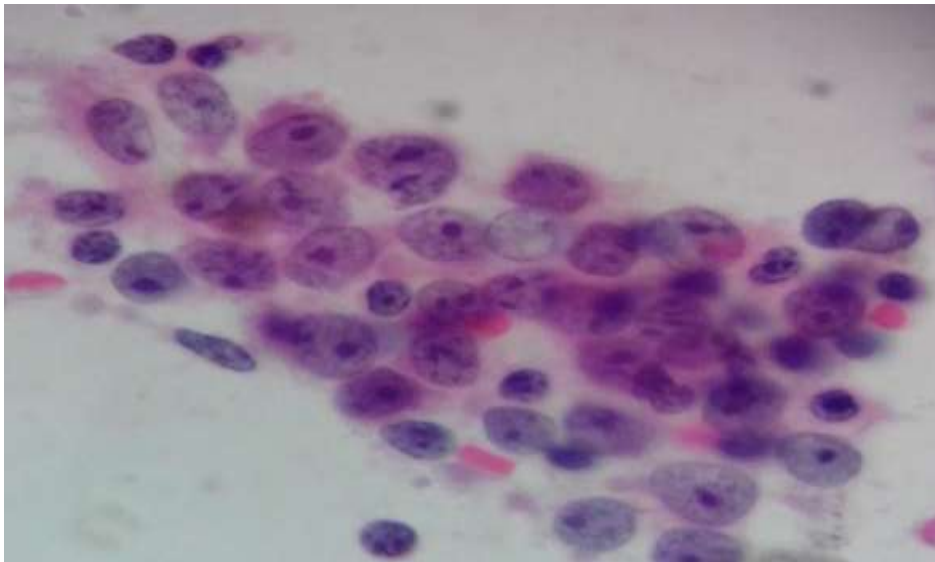


Figure 23: Cytomorphological features of metastatic nasopharyngeal carcinoma. Layers of primitive epithelial cells, with high nuclear/cytoplasmic ratio, vesicular nuclei, prominent nucleoli and delicate cytoplasm with variable degrees of keratinization (x40 rapid pap).

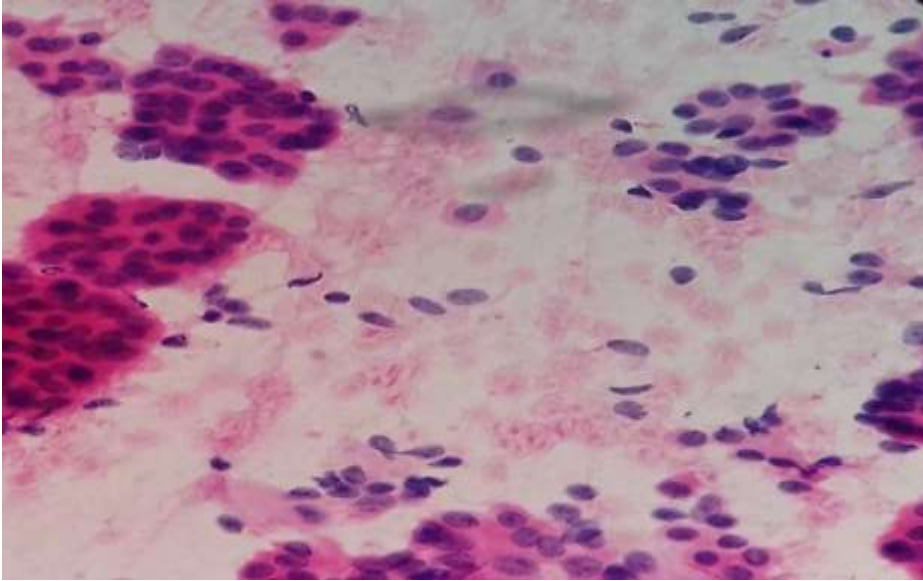


Figure 24: Cytomorphological features of metastatic nasopharyngeal carcinoma to the lymph node. Clusters or syncytia of crowded cells that overlap with large round to oval nuclei with slightly irregular membrane that have fine chromatin pattern. (x40 pap).

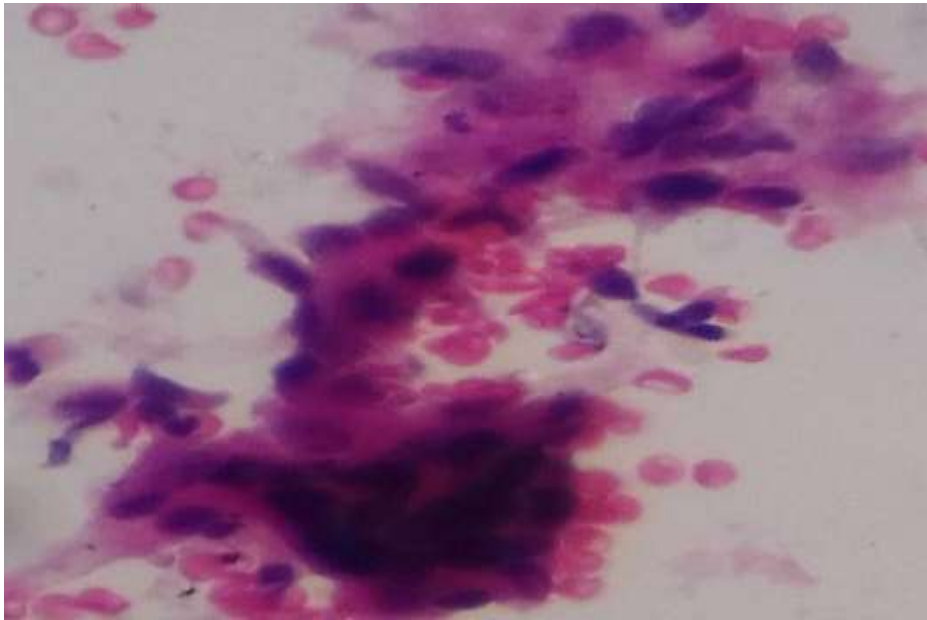


Figure 25: Cytomorphological features of Paraganglioma (carotid body tumor). Irregular clusters of epithelioid like cells, spindling nuclei and eosinophilic finely granular cytoplasm (x40 rapid pap).

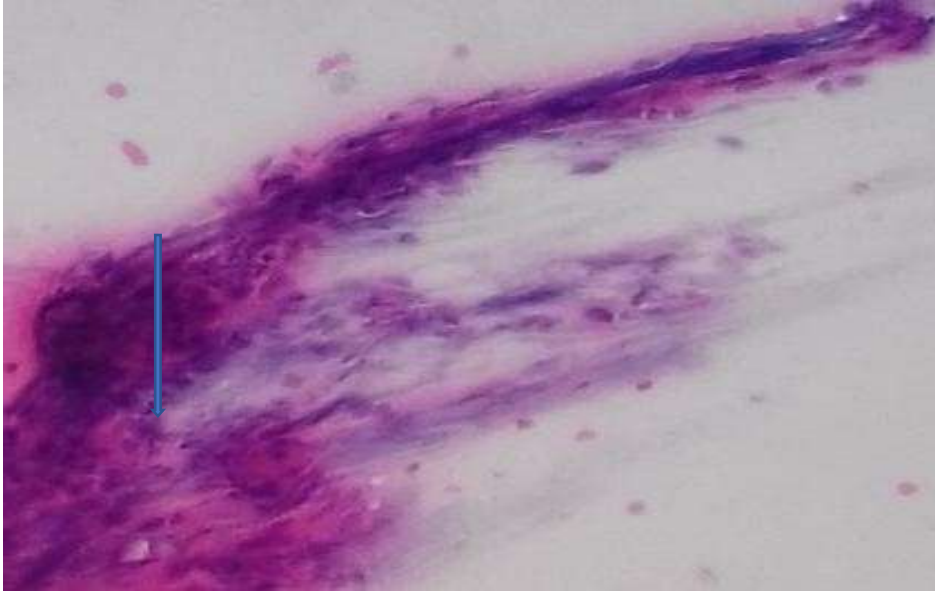


Figure 26: Cytomorphology of Pleomorphic adenoma: Chondromyxoid stroma (arrowed) (x40 Rapid pap).

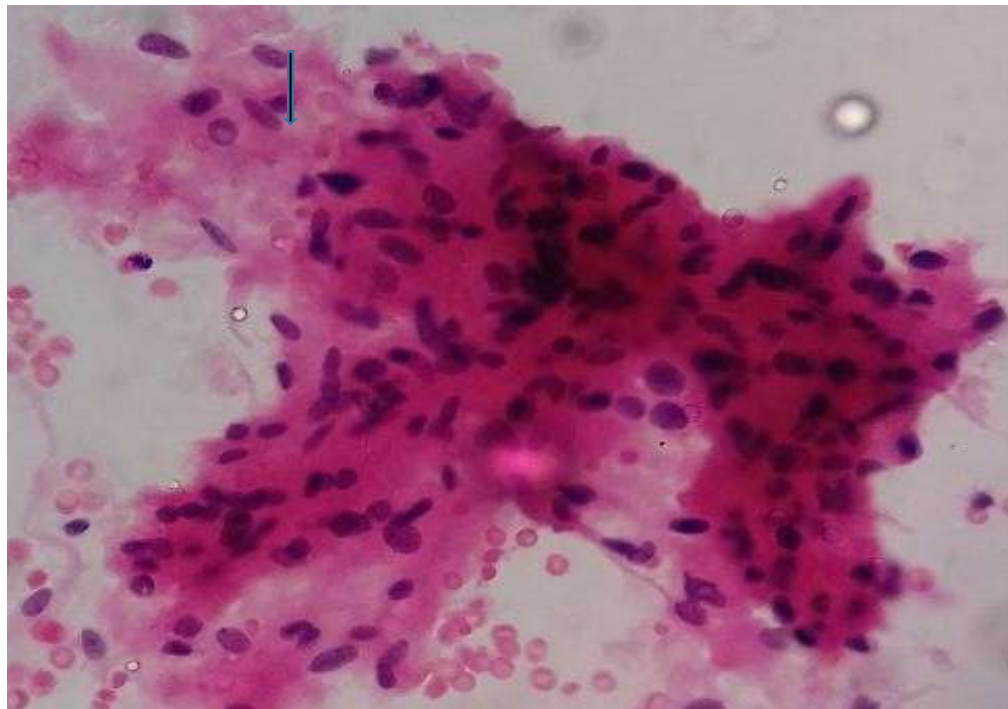


Figure 27: Cytomorphological features of Brain tissue. Meningioma-Clusters of cohesive meningeothelial cells that have a thin, defined eosinophilic cytoplasm with oval hyperchromatic

nuclei, that have chromatin that's finely granular. Intranuclear cytoplasmic inclusions are seen (arrowed) (Rapid pap).

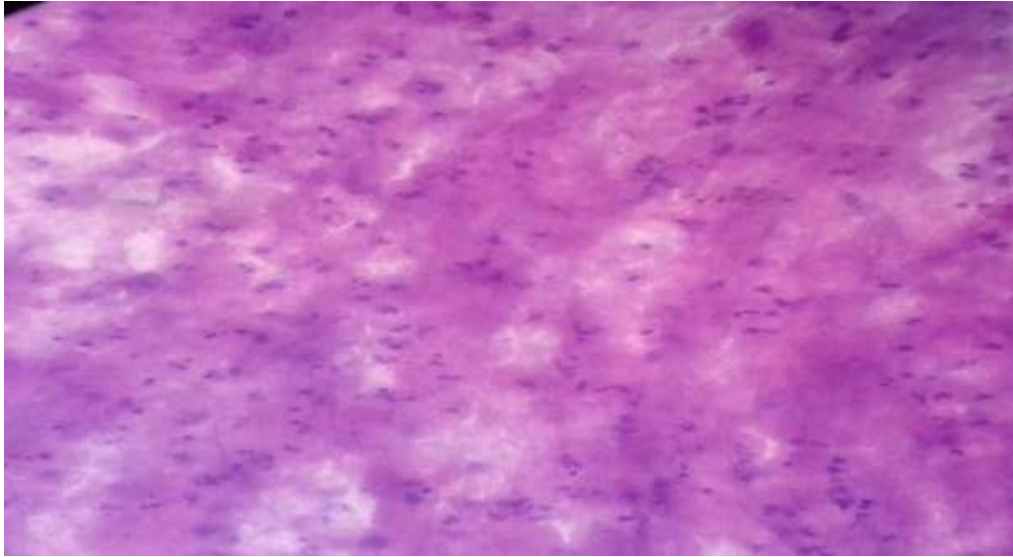


Figure 28: Cytomorphology of brain abscess: Acute inflammation; necrosis with abundant neutrophils (x40 Rapid pap).

6.0 DISCUSSION

Out of 139 participants enrolled in the study 56.1% were male while 43.9% were female; with a ratio of 1.2:1 and a mean age of 42.7. 20.9% of the respondents were in the age of age of between 35 and 44 years, 19.4% were aged between 20 and 34 years. 134 cases (97.1%), were correctly diagnosed on imprint cytology. 47.5% of the diagnosis were benign/inflammatory, 41.7% malignant, 7.2% suspicious for malignancy while 3.6% were non-diagnostic. The histology diagnosis analysis showed that 56.1% of the diagnosis were benign while 43.9% were malignant.

There was male predominance of 78 (56%) cases and 61(44 %) female cases; with a ratio of 1.2:1. Adeyami BF et al. had similar findings in a Nigerian tertiary healthcare facility with a ratio of 1.8:1 (83) for male to female. Alverenge Lde M et al. had similar findings (84). Most lesions were sampled from the oral cavity in our study; comprising of 33 cases (47.1%). Neveed et al observed that 47% of the lesions were sampled from the oral cavity (56).

The oral cavity was the most sampled site comprising of 31 cases (22.3%), thyroid 21 cases (15.1%), the lymph node 19 cases (13.7%), larynx 16 (11.5%), nasal cavity 15 cases (10.8%). Neveed et al in Pakistan found that imprint cytology was diagnostic in 97.1% cases. It was shown from their study that the oral cavity had 33 cases (47.1%) followed by the larynx with 27 cases (38.6%) (55).

Benign lesions were seen in comparatively younger age group as compared to malignant lesions in our study. Most of these conditions are detected with increase in age. Patients with neoplastic lesions (mean age 42) were older than those with non-neoplastic lesions. The increased frequency of neoplastic lesions in the older can, possibly be explained by the accumulation of somatic mutations coupled by, the decrease in immunocompetency in the adults and lifestyle changes. A P value of $p < 0.05$ ($P < 0.03$) and a $X^2 = 17.639$ obtained indicate that the mean age between the two groups were significantly different and were significant.

The higher standard deviation in non-neoplastic lesions (mainly inflammatory) shows a wider age distribution of the lesion but was predominantly in the young whereas, the lower standard deviation in neoplastic shows that they were mainly confined to older patients within a narrow age range.

The squamous cell carcinoma increased among respondents with increase in age, the 35 - 44 years age group had 8.7% compared to 65 years and above which had 30.4%. The younger age groups have a low incidence of squamous cell carcinoma with a mean age of 61.2 years. The analysis also shows that benign lesions were common in the less than 20 years age group, 15.9%, 28% in 20 to 34 years age group and 22% in 35 to 44 years age group. The mean age for malignant lesions was 47.8 years. A similar finding was found by a study conducted by Orki et al. (79) who observed that mean age for malignant lesions was 54.2 years.

The association between age and location of lesion was significant with $X^2 = 14.953$, $p < 0.05$ and Gender and location of lesion was $X^2 (1) = 11.332$, $p < 0.05$. Most of thyroid lesions were found in female patients as compared to male patients probably due to hormonal changes and malignant lesions especially those involving the oral cavity, larynx and nasal cavity were highly associated

with male gender possibly caused by lifestyle changes like alcohol consumption and cigarette smoking.

There was no association between gender and malignancy occurrence were the results showed a chi square of $X^2(1) = 1.433$ and a p value of $p > 0.05$.

The overall accuracy was 92.1% with a sensitivity of 88.5% and specificity of 94.9%. There was a good agreement (kappa value of 0.838) between imprint cytology and histology finding.

In the present study, however, we have shown that using imprint cytology as stand-alone diagnostic procedure, it is possible to achieve consistently high sensitivity (88.5%) and specificity (94.9%) for intra- operative diagnosis of head and neck lesions even in resource limited setting where frozen section facility is not available.

Our study is comparable with the studies done by different authors as listed on the table 10.0 below.

6.1. Accuracy of TIC in malignant lesions with published studies.

Investigator	Year	Accuracy	Specificity	Sensitivity
Gore, et al. (82)	20117	98.1%	100%	95.5%
Hania, et al. (56)	2016	96.7%	100%	98%
Khalid, et al. (35)	2013	94.9%	96.8%	93.2%

Bandami, et al. (81)	2010	92.63%	86.3%	96%
Present study	2019	92.1%	88.5%	94.9%

Table 10: Accuracy of TIC in malignant lesions with published studies

The sensitivity of 88.5% and specificity of 94.9% was obtained in our study; with an overall accuracy of 92.1 %. A 2.7 % rate was obtained for false positive and 11.1% for false negative. These findings are comparable to a study done by Badami, et al. (81). who found a sensitivity of 96% and specificity of 86.3% with an 92.63 % accuracy rate and 7.36 % false-negative rate.

Gore, et al. (82). found Sensitivity of 95.5% and specificity 100% and an accuracy rate of 93.3% in detecting malignancy in surgical specimens.

Another study conducted by Hussein, et al. (8) on 30 patients with head and neck mass lesions found that touch imprint smears correctly identified 90% of the cases with a sensitivity of 88% and specificity of 92%.

We found 100% sensitivity and specificity in the detection of lymphoma which shows that cytology diagnosis was 100% in comparison with the histology diagnosis; Naveed et al (56) had a similar finding with an overall diagnostic accuracy of 96.7%; a sensitivity of 96% and specificity of 100% ; with a 100% sensitivity and specificity of IC in the diagnosis of Hodgkin lymphoma. The findings from this study has shown that most cases of lymphoid and metastatic lesions to the lymph nodes for known and unknown primary cancer site, imprints from such cases if clearly positive, would be sufficient for the purpose of intraoperative diagnosis.

Most lesions were correctly identified on imprint cytology as seen on (figure 11.0). Inflammatory reactions were the most encountered in 18 cases (27.3%). The lesions were sampled from the lymph nodes 5 cases, remaining ones from brain, nasal cavity, oral cavity scalp, tonsils, and larynx. cytomorphological picture showed varying degree of inflammatory cells including neutrophils, lymphocytes, epithelioid cell, plasma cell and necrosis on the background (figure 30).

Thyroid benign lesions were correctly identified on cytology. Colloid goiter 12 cases (18.2%), follicular adenoma, graves' disease, lymphocytic thyroiditis had 1 case each. Benign colloid

goiter was demonstrated by abundant, thick colloid material with a characteristic cracking or bubble pattern. Follicular epithelial cells in “honeycomb” arrangement were also seen (figure17).

Cystic lesions comprised of 13cases (19.7%) of which were correctly identified as shown on (figure 9.0 and figure 10.0). they were sampled from the eye, neck, scalp, and the oral cavity. Epidermoid cyst was the most encountered in 6 cases (9.1%), mucocele 4 cases (6.1%), and 1 case (1.5%) each for odontogenic cyst, thyroglossal duct cyst and cystic hygroma. Cytology was able to diagnose more cysts as compared to histology. Two cysts were reported as inflammatory reaction on histology but were reported as infected epidermoid cyst on cytology. Cytology of epidermoid cyst shows abundant benign squamous cells and anucleate squames.

Other benign lesions included papilloma 4 cases (6%) which were sampled from the eye and the oral cavity. Paraganglioma 3 cases which were sampled from the carotid region of the face. Cytology was able to ick all of them. The cytomorphology showed irregular clusters of epithelioid like cells, spindling nuclei and eosinophilic finely granular cytoplasm (figure 27).

Oral cavity benign lesions included fibroma 3 cases (4.5%), ameloblastoma 3 cases (4.5%), actinic cheilitis 2 cases (3%), papilloma2 cases and 1 case (1.5%) each for capillary hemangioma, and pyogenic granuloma. All were correctly identified on cytology. Pleomorphic adenoma 2 cases (3%) and was correctly identified.

A total of 64 cases were malignant as seen on histology, 56 were correctly identified on imprint cytology as seen on (figure 12). Squamous cell carcinoma had 25 cases; 23 cases were correctly identified on imprint smears. The oral cavity, larynx and the eye were the most affected site in decreasing frequency. A sensitivity of 94.9% and specificity of 100% was found in the diagnosis of squamous cell carcinoma in this study. A similar finding was seen in a study conducted by Hania et al (56) and Nieberler M et al (46) observed sensitivity of 95.3% and specificity of 96% with a diagnostic accuracy of 95.7% among patients with oral squamous cell carcinoma. Imprint smear showed squamous cells that were loosely discohesive with nuclei that was pleomorphic and coarse chromatin and abundant cytoplasm (Figure 16).

Nasopharyngeal carcinoma was the second most encountered malignancy with a total of 13 cases on both histology and imprint cytology. 6 cases presented as metastatic to the lymph nodes and 6 case sampled from the nasal cavity. Cytomorphological features of nasopharyngeal carcinoma

shows layers of primitive epithelial cells, with high nuclear/cytoplasmic ratio, vesicular nuclei and prominent nucleoli (figure 25,26).

Lymphoma was encountered in 8 cases all of which were correctly picked by imprint cytology. 6 cases were sampled from the cervical lymph nodes and 2 cases were sampled from the nasal cavity. Imprint smears showed large monomorphic lymphoid cells, singly dispersed with increased nuclear size with irregular chromatin clumping, prominent nucleoli and scant cytoplasm as seen on figure 22.

Hodgkin lymphoma- Reed-Sternberg cells characterized by two large nuclei that completely resemble each other with prominent macro nucleoli with evenly dispersed chromatin and faint cytoplasm (figure 23,24).

Salivary gland lesions had 3 cases of malignancy that were correctly picked by imprint cytology. These included adenoid cystic carcinoma mucoepidermoid carcinoma and carcinoma EX pleomorphic adenoma. Cytology of Adenoid cystic carcinoma showed monomorphic cells that exhibit metachromatic "gum balls" with homogeneous basement membrane stroma. The cells exhibit cohesive clusters, cords, solid groups, cylinders, glands or microcystic spaces.

Thyroid malignancies were encountered in 5 cases which only two were correctly picked by imprint cytology. Two cases of papillary thyroid carcinoma were correctly identified. Suspicious for malignancy cases involved 2 samples of follicular carcinoma as seen on histology. It was not possible to ascertain the degree of capsular inversion on cytology. Cytology showed presence of papillary structures with fibrovascular cores, Orphan-Anne eye nuclei, intranuclear cytoplasmic invaginations (INCI) and grooved nuclei (figure 19).

Utility of TIC was demonstrated in the diagnosis of brain tissue malignancies e.g. Meningioma and glioblastoma and brain abscess. Cytomorphological features of Meningioma showed clusters of meningotheial cells that are cohesive with a thin, eosinophilic cytoplasm that is defined, and oval hyperchromatic nuclei that have fine granular chromatin. Intranuclear cytoplasmic inclusions are seen (figure 27,28).

Three cases of sarcoma were seen on histology which were correctly picked on cytology. The samples were obtained from the oral cavity and the scalp. Cytomorphology of sarcoma showed;

stingily dispersed uniformly appearing Plasmotoid cells with abundant cytoplasm with distinct cell borders, round to polygonal cellular contours, and eccentric nuclei, some are binucleated (figure 19).

Two cases of retinoblastoma were identified on histology of which were correctly identified on cytology; both of which were sampled from the eye.

One case of malignant melanoma was sampled from the eye which was correctly identified. The cytomorphological features showed single spindling cells with oval elongated nuclei and prominent bipolar, slender cytoplasmic processes. Presence of intracytoplasmic melanin brown pigment granules; and one case of malignant fibrous histiocytoma sampled from the nose was reported as suspicious for malignancy on cytology (figure19).

The proportion of non-diagnostic impressions in this study was 5 cases (3.6%). % of all procedures (139 cases). Among these five cases, majority were benign lesion; three were hemangioma which showed tissue surface by stratified squamous epithelium with large dilated blood sinuses with thin walls with no features of atypia on histology. On cytology only hemorrhagic background was demonstrated thus non diagnostic. One case of a keloid that showed skin tissue with increased stroma with collagen bundles arranged in haphazard fashion with glossy appearance, with no atypia noted on histology while on cytology was non diagnostic due to lack of diagnostic material because vascular and fibrotic lesions do not imprint well. The remaining were non diagnostic due to insufficient material. Gunhan et al. (80) in their study reported hemorrhagic aspirate in the cases of hemangioma and were non diagnostic. These outcomes show that malignancy is not excluded by negative results. Confirmation should be done using histology.

Eight cases were found during our study that were reported as suspicion of malignancy owing to atypical nuclear features. All cases were confirmed on histology as malignant. Among them were 2 cases of follicular thyroid carcinoma that were reported as suspicious for malignancy on cytology as it was not possible to demonstrate capsular and vascular invasion. On cytology there were nuclear feature changes with increased nuclear size, prominent nucleoli and coarse chromatin which was subtle for final diagnosis. Histology report showed malignant tumor composed predominantly of micro-follicles closely packed, with solid nests and trabecular patterns and presence of vascular invasion noted.

One case of brain meningioma was reported as suspicious for malignancy due to insufficient material and lack of clarity of cellular morphology. Similar findings were found in the study done by Suen et al (20). They found out that false negative reports may be attributed to insufficient cells and lack of clarity of cellular structures.

Squamous cell carcinoma was reported as suspicious for malignancy because of hypocellular smear with mostly benign and atypical cells. A false negative diagnosis in TIC was attributed to inadequate sampling. Multiple imprints can be made from different biopsy slides to address the problem. This will ensure that the cut surface is touched on the slides.

Comparison between imprint cytology and histology showed that 118 (84.9%) sites were correctly diagnosed by imprint. There was a lack of similarities in 21 (15.1%) cases. The analysis shows that there was 100% agreement of cytology and histology on lesions found in the carotid, tonsil, lymph node and in the face. There was significant deviation between Cytology and histology diagnosis in the lesions found in the ear (50%), scalp (66.7%), thyroid (76.2%), brain (71.4%) and Nose (73.3%). The major cause was attributed to interpretation error due to adequacy followed by nature of tissue. Similar findings were observed by Badami, et al (81) who observed that TIC was unable to differentiate between invasive carcinoma from in-situ lesions thus emphasizing the need for histology examinations for definitive diagnosis.

The usefulness of TIC was demonstrated in lymph node metastatic lesions as it gave specific diagnoses. Also, special role was in the diagnosis of brain lesions in differentiating reactive and malignant lesions as in brain abscess where the samples were liquified material; and in diagnosis of meningioma and glioma. Another special role was seen in the diagnosis of the nasal cavity and the parapharyngeal lesions in the diagnosis of malignancy especially nasopharyngeal carcinoma and lymphoma as most of the samples were very tinny, soft and delicate yet excellent diagnosis was achieved.

7.0 Study Limitations

1. The technique was not able to diagnose thyroid follicular carcinoma thus, the need for histology technique for definitive diagnosis.
2. Vascular and fibrotic lesions did not imprint well as demonstrated by inability of TIC to diagnose hemangioma and keloid thus giving a false negative result

8.0 Conclusion

1. Benign findings were inflammatory conditions and colloid goiter in adults and inflammatory conditions and cystic lesions in children.
2. Neoplastic lesions in adults were metastatic squamous cell carcinoma, nasopharyngeal carcinoma and lymphoma and in children retinoblastoma, lymphoma and sarcoma were found.
3. Intraoperative diagnosis of head and neck malignancies can readily be achieved using touch imprint cytology technique as it can easily be availed at the surgical operative site; moreover, it can offer a rapid and accurate diagnosis for further management of the patient.
4. It has been shown from this study that TIC provides information which is valuable and can play an important function in early patient's management. In most of the hospitals in developing countries like Kenya, where intraoperative diagnosis is not done, this can help improve surgical management planning.

9.0 Recommendations

1. Initiate the use of TIC in the intraoperative consultation on urgent cases to reduce diagnostic delays and improve patient management. This should be institutionalized as a standard practice without delay as the resource inputs are already available in the hospital.
2. Incorporate immunohistochemistry technique, special stains and flow cytometry during TIC analysis to improve its accuracy, sensitivity and speed since most malignant lesions were metastatic to the lymph nodes and others were inflammatory lesions caused by different infectious agents.

REFERENCES

1. Kim K, Phillips ER and Paolino M. Intraoperative Imprint Cytology: It's Significance as a Diagnostic Adjunct. *Diagnostic cytopathology*, Oct 18, 1989; Vol 6. No.5, p 304-307.
2. Manafis K: An Intraoperative Consultation. Usefulness, Reason and accuracy of the method. *Archives of Hellenic Pathology*, 1997;11:472–7.
3. Zarbo RJ, Schmidt WA, Bachner P, Howanitz PJ, Meier FA, Schiffman RB, Boone DJ, Herron RM JR: Indications and immediate patient outcomes of pathology Intraoperative consultations. *Arch Pathol LabMed* Jan 1996; 120(1) p 19-25.
4. Tribe CR. A comparison of rapid methods including imprint cytodiagnosis for the diagnosis of breast tumors. *J Clin Path.* 1973; 26:273–7.
5. Westra WH, Pritchett DD, Udelsman R. Intraoperative confirmation of parathyroid tissue during parathyroid exploration: A retrospective evaluation of the frozen section. *Am J Surg Pathol.* 1998; 22:538–44.
6. Henry-Tillman RS, Korourian S, Rubio IT, Johnson AT, Mancino AT, Massol N, et al. Intraoperative touch preparation for sentinel lymph node biopsy: a 4-year experience; *Ann Surg Oncol* 9:333-9
7. *Ann Surg Oncol.* 2002; 9:333–9. Tworek JA, Giordano TJ, Michael CW. Comparison of intraoperative cytology with frozen sections in the diagnosis of thyroid lesions. *Am J Clin Pathol.* 1998; 110:456–61.
8. Hussein MR, Rashad UM, Hassanein KA. Touch imprint cytologic preparations and the diagnosis of head and neck mass lesions. *Annals of Oncology* 2005; 16(1):171-2.
9. Monabati A, Kumar PV, Kamkarpour A. Intraoperative cytodiagnosis of metastatic brain tumors confused clinically with brain abscess. A report of three cases. *Acta Cytol.* 2000; 44:437–41.
10. Florell SR, Layfield LJ, Gerwels JW. A comparison of touch imprint cytology and Mohs frozen-section histology in the evaluation of Mohs micrographic surgical margins. *J Am Acad Dermatol.* 2001; 44:660–4.
11. Souka S, Kamel M, Rocca M, el-Assi M, Hebeishy N, Sheir SH. The combined use of cytological imprint and frozen section in the intraoperative diagnosis of ovarian tumors. *Int J Gynaecol Obstet.* 1990; 31:43–6.

12. McDonald EC, Haughton W, Lute K. Touch imprints: Their use in the frozen-section diagnosis of alveolar soft-part sarcoma. *Arch Pathol Lab Med.* 1981; 105:263–5.
13. Ghandur-Mnaymneh L, Paz J. The use of touch preparations (tissue imprints) in the rapid intraoperative diagnosis of metastatic lymph node disease in cancer staging procedures. *Cancer.* 1985; 56:339–44.
14. Ranjan A, Chandoke RK, Chauhan N, Kumari R. Oncology, study of tumors by imprint cytology. *Indian J Clin Pract.* 2013; 24:472–7.
15. Dudgeon LS and Patric VS, A new method for rapid microscopical diagnosis of tumour: With an account of 200 cases so examined University of London, *Bri J Surg.*, (1927); 15, 250–61
16. Cox CE, Ku NN, Reintgen DS, Greenberg HM, Nicosia SV and Wangenstein S., Touch preparation cytology of breast lumpectomy margins with histologic correlation, *Arch Surg.*, (1991); 126(4), 490-3.
17. Loncar B, Pajtler M, Milicic-Juhas V, Kotromanovic Z, Staklenac B, Pauzar B. Imprint cytology in laryngeal and pharyngeal tumors. *Cytopathology.* 2007; 18(1):40–3.
18. Limo AK, Gichana J, Korir A. Incidence rates of head and neck cancers in Nairobi, Kenya. *Globocan 2011 Report.*
19. M. M. Bui, P. Smith, S. V. Agresta, D. Cheong, and G. D. Letson, “Practical issues of intraoperative frozen section diagnosis of bone and soft tissue lesions,” *Cancer Control*, vol. 15, 2008; no. 1, pp. 7–12.
20. Suen KC, Wood WS, Syed AA, Quenville NF, Clement PB. Role of imprint cytology in intraoperative diagnosis: Value and limitations. *J ClinPathol.* 1978; 31:328–37.
21. Khalid A, Haque AU. Touch imprint cytology versus frozen section as intraoperative consultation diagnosis. *Int J Pathol.* 2004; 2(2):63–70
22. Thomson AM, Wallace WA. Fixation artifacts in an intra-operative frozen section: a potential cause of misinterpretation. *J Cardiothorac Surg.* 2007; 2:45.
23. Parkins D.M. PP and FJ. Estimates of the worldwide frequency of eighteen major Cancers in 1985. *Int J Cancer.* 1993; 54(4):594–606.
24. McFarlane G., Boyle P., Evstifeeva T. et al. Rising trends of oral cancer mortality among males worldwide: the return of an old public problem. *Cancer causes Control.*

- 1994; 5(3):259–65.
25. Parkin, DM, Whelan, SL, Ferlay, J, Raymond, L, Young, J. Cancer Incidence in Five Continents. Lyon: International Agency for Research on Cancer Scientific Publications, 1997:7 Google Scholar
 26. R J Sanderson. Squamous cell carcinomas of the head and neck. *BMJ*. 2002; 325(7368):822–7.
 27. Nairobi Cancer Registry Report for year 2000-2002: Kemri Report 2005.
 28. Onyango JF, Macharia IM. Delays in diagnosis, referral and management of head and neck cancer presenting at Kenyatta National Hospital, Nairobi *East Afr Med J*. 2006;83(4):85-91.
 29. McGuit WF. Neck Masses: Differential Diagnosis and Therapeutic Approach. In: Shockley WW, Pillsbury HC III, Eds. *The neck Diagnosis and Surgery*. St. Louis: Mosby Year Book, 1994: 73 – 89.
 30. Major T, Szarka K, Sziklai I, Gergely L, Czegledy J. The characteristics of human papillomavirus DNA in head and neck cancers and papillomas. *J Clin Pathol*. 2005; 58:51–5. PubMed- Cross Ref Google Scholar.
 31. National guidelines for cancer management Kenya August, 2013. Head and neck cancers. Common symptoms and signs:132.
 32. World Cancer Report 2014. World Health Organization. 2014. pp. Chapter 5.8. ISBN 9283204298.
 33. Hirachand S, Lakhey M AJ et al. Evaluation of fine needle aspiration cytology of lymph nodes in Kathmandu. *Kathmandu University Med J*. 2009; 7(26):139–42.
 34. Sato M, Taniguchi E, Kagiya T, Nunobiki O, Yang Q, Nakamura M, et al. A modified rapid Papanicolaou stain for imprint smears. *Acta Cytol*. 2004; 48:461–2.
 35. Khan et al., *Afr J Tradit Complement Altern Med*. (2015) 12(2):60-64
 36. Shidham VB, Gupta D, Galindo M, Haber M, Grotkowski C, Edmonds P, et al. I Khan et al., *Afr J Tradit Complement Altern Med*. (2015) 12(2):60-64 intraoperative scrape cytology: Comparison with frozen sections, using receiver operating characteristic (ROC) curve. *Diagn Cytopathol*. 2000; 23:134–9.

37. Elvio G Silva and B. Balfour Kraemer, Preparing and Evaluating Frozen Tissue Sections: Technique and Cytology. Intra operative Pathologic Diagnosis – Frozen Sections and other techniques, Baltimore, Williams and Wilkins, 1987; 11-15.
38. Leopold G. Koss and Myron R. Melamed, Diagnostic Cytology: Its origins and Principles. Koss' Diagnostic Cytology and its Histopathologic. Pennsylvania, Lippincott Williams and Wilkins, 2006; 14.
39. Shidham VB, Dravid NV, Grover S, Kher AV. Role of scrape cytology in rapid intraoperative diagnosis: Value and limitations. *Acta Cytol.* 1984; 28:477–82.
40. Belleannee G, Verdebout J, Feoli F, Trouette H, de Mascarel A, Verhest A. Role of cytology and frozen sections in the intraoperative examination of the thyroid: Comparison of two experiences. *Clin Exp Pathol.* 1999; 47:273–7.
41. Florell SR, Layfield LJ, Gerwels JW. A comparison of touch imprints cytology and Mohs frozen-section histology in the evaluation of Mohs micrographic surgical margins. *J Am Acad Dermatol* 2001; 44: 660–64.
42. Geelhoed GW, Silverberg SG.: Intraoperative imprints for the identification of parathyroid tissue. *Surgery* 1984 Dec; 96 (6) 1124-31.
43. Westra WH, Pritchett DD, Udelsman R. Intraoperative confirmation of parathyroid tissue during parathyroid exploration: A retrospective evaluation of the frozen section. *Am J Surg Pathol.* 1998; 22:538–44.
44. Savargaonkar P, Farmer PM: Utility of intra-operative consultations for the diagnosis of central nervous system lesions. *Ann Clin Lab Sci* 2001 AP; 31(2):133-9.
45. Monabati A, Kumar PV, Kamkarpour A: Intraoperative cytodiagnosis of metastatic brain tumors confused clinically with brain abscess. A report of three cases. *Acta Cytol* 2000 May-Jun; 44(3): 437-41.
46. Nieberler M, Häusler P, Drecoll E, Stoeckelhuber M, Deppe H, Hölzle F, et al. Evaluation of intraoperative cytological assessment of bone resection margins in patients with oral squamous cell carcinoma. *Cancer Cytopathol.* 2014;122(9):646–656.
47. Kaliamoorthy S, Venkatapathy R, Babu P, Veeran V. Practical significance of utilizing fine needle aspiration cytology as an adjunct diagnostic aid in the preoperative presumptive diagnosis of ameloblastoma. *J Cytol* 2013; 30:247-51.

48. Hentry-Tillman RS, Korourian S, Rubio IT, Johnson AT, Mancino AT, Massol N et al: Intraoperative touch preparation for sentinel lymph node biopsy: a 4-year experience. *Ann Surg Oncol.* 2002 May; 9(4): 321-3.
49. Arganini M, Behar R, Wu T-C, et al. Hürthle Cell Tumors: A Twenty-Five-Year Experience. *Surgery* 100: 1986; 1108-1115.
50. Tsou MH, Wu ML, Chuang AY, Lin CY, Terng SD (2006) nasopharyngeal biopsy imprint cytology: a retrospective analysis of 191 cases. *Diag. Cytopathol.* 34: 204–207.
51. Springfield DS, Rosenberg A (1996) Biopsy: complicated and risky. *J Bone Joint Surg Am* 78:639–643.
52. Cibas E, Ducatman S. Cytology diagnostic principles and correlates. In: 3rd ed. Saunders Elsevier; 2008. p. 31–5.
53. Marluce Bibbo. *Comprehensive Cytopathology*. 2nd ed. Philadelphia: Saunders Elsevier.; 1997. 601-690.
54. Burgess KL, Hartwick RWJ, Bedard YC: Metastatic Squamous Carcinoma Presenting as a Neck Cyst: Differential Diagnosis from Inflamed Branchial Cleft Cyst in Fine Needle Aspirates. *Acta Cytol* 37: 1993. 494-498
55. Richard D. Demay. *Art and Science of Cytopathology Part 1*. Chicago: American Society of Clinical pathologist Press; 1996. 225-423.
56. Hania Naveed, Mariam Abid, et al. Diagnostic accuracy of touch imprint cytology for head and neck malignancies: a useful intraoperative tool in resource limited countries 2017. <https://doi.org/10.1186/s12907-017-0063-y>
57. R J Sanderson. Squamous cell carcinomas of the head and neck. *BMJ.* 2002; 325(7368):822–7.
58. Shambayati. B. *Cytopathology*. 1st edition. Oxford: Oxford University Press; 2012. 88,140-1 p.
59. Chan MKM, McGuire LJ, King W, et al. Cytodiagnosis of 112 Salivary Gland Lesions: Correlation with Histologic and Frozen Section Diagnosis. *Acta Cytol* 36: 1992; 353-363.
60. Piao Y, Guo M, Gong Y. Diagnostic challenges of metastatic spindle cell melanoma on fine-needle aspiration specimens. *Cancer.*2008; 114(2):94–101.
61. Stevenson DS, Allison RS, Robertson MS, et al: *Aspiration Cytology in the Diagnosis of*

- Head and Neck Masses: The Early Christ church Experience. *NZ Med J* 102: 1989; 639641
62. Elliott JN, Oertel YC: Lymphoepithelial Cysts of the Salivary Glands: Histologic and Cytologic Features. *Am J Clin Pathol* 1990; 93: 39-43.
63. Dehner LP: Favorable vs Unfavorable Histologic Appearance: The Lexicon of Pathologic Grading of Solid Malignant Neoplasms in Children. *Arch Pathol Lab Med* 116: 1992; 817-819.
64. Gardner DF, Frable WJ: Primary Lymphangioma of the Thyroid Gland. *Arch Pathol Lab Med* 113: 1989; 1084-1085.
65. Carlsen NLT: How Frequent is Spontaneous Remission of Neuroblastomas Implications for Screening. *Br J Cancer* 61: 1990; 441-446.
66. Fulciniti F, Di Mattia D, Bove P, et al. Fine needle aspiration of metastatic epithelioid angiosarcoma: a report of 2 cases. *Acta Cytol.* 2008; 52(5):612–618.
67. Gamborino E, Carrilho C, Ferro J, et al. Fine-needle aspiration diagnosis of Kaposi's sarcoma in a developing country. *Diagn Cytopathol.* 2000; 23:322–325.
68. Stevenson DS, Allison RS, Robertson MS, et al: Aspiration Cytology in the Diagnosis of Head and Neck Masses: The Early Christchurch Experience. *NZ Med J* 102: 1989; 639641.
69. Richard D. Demay. *Art and Science of Cytopathology Part 2.* Chicago: American Society of Clinical pathologist Press; 1996. 1314-2358.
70. Gnepp DR, Schroeder W, Heffner D: Synchronous Tumors Arising in a Single Major Salivary Gland. *Cancer* 63: 1989; 1219-1224.
71. Smallman LA: Pathologic Disorders of the Salivary Glands. *Ear Nose Throat J* 68: 1989; 104-119.
72. Gonzalez M1, Blanc JM PJ et al. Head and neck fine-needle aspiration: cytohistological correlation. *Acta Otorrinolaringol Esp.* 59(5):205–11.
73. Tatomirovic Z1, Skuletic V BR et al. Fine needle aspiration cytology in the diagnosis of head and neck masses: accuracy and diagnostic problems. *J BUON.* 2009; 14(4):653–9.
74. Ayugi J1, Ogengo J MI et al. Pattern of acquired neck masses in a Kenyan paediatric population. *East Afr Med J.* 2006; 83(5):288–94.

75. Elibariki M Lucumay, Japhet M Gilyoma PF et al. Paediatric neck masses at a University teaching hospital in north-western Tanzania: a prospective analysis of 148 cases. *BMC Res Notes*. 2014; 7(772):1186.
76. Bossuyt PM, Reitsma JB, Bruns DE, Gatsonis CA, Glasziou PP, Irwig LM, et al. The STARD statement for reporting studies of diagnostic accuracy: explanation and elaboration. *Clin Chem* 2003; 49:7-18.
77. Fisher, R.A. Oliver and Boyd. *Statistical Methods for Research Workers*. ISBN (1954); 0-05-002170-2.
78. Wenig BM. Intraoperative consultation (IOC) in mucosal lesions of the upper Aerodigestive tract. *Head Neck Pathol*. 2008; 2(2):131–44.
79. Orki A, Tezel C, Kosar A, Ersev AA, Dudu C, Arman Feasibility of imprint cytology for evaluation of mediastinal lymph nodes in lung cancer. *Jpn J Clin Oncol* 2006; 36:76- 9.
80. Gunhan O, Doan N, Celasun B, Sengun O, Onder T, Finci R. Fine needle aspiration cytology of oral cavity and jaw bone lesions. A report of 102 cases. *Acta Cytol* 1993; 37:135-41.
81. Badami Harnish, Vala Nidhi and Doshi Neena. Usefulness of touch Imprint Cytology in Cancer diagnosis: A study of 119 cases. *International Research Journal of Medical Sciences* 2014; 2(10): 19-25.
82. Gore CR, Singh BK, Chandanwale SS, Gurwale SG, Kumar H, Bawikar R, *et al*. Imprint cytology: A boon in tissue diagnosis. *Med J DY Patil Univ* 2017; 10:58-63.
83. Adeyemi BF, Adekunle LV, Kolude BM, Akang EE, Lawoyin JO. Head and neck cancer—a clinicopathological study in a tertiary care center. *J Natl Med Assoc*. 2008;100(6):690–7.
84. Alvarenga Lde M, Ruiz MT, Pavarino-Bertelli EC, Ruback MJ, Maniglia JV, Goloni Bertollo M. Epidemiologic evaluation of head and neck patients in a university hospital of Northwestern São Paulo state. *Braz J Otorhinolaryngol*. 2008;74(1):68–73.
85. Mirbod SM, Ahing SI. Tobacco-associated lesions of the oral cavity: part II. Malignant lesions. *J Can Dent Assoc*. 2000;66(6):308–11.

7.0. APPENDICES

Appendix I : Data Collection Sheet

Study identification number-----

Demographic and socio-economic data

- a. Age -----
- b. Gender M () or F ()
- c. tobacco/cigarette smoking Y () or N ()
- d. Occupation -----
- e. Alcohol consumption----- Y() or N ()

Clinical reasons for requesting an intraoperative pathological consultation-----

Clinical history and examination

- a. Location of the lesion-----
- b. Duration of the lesion-----
- c. Tenderness tender () non tender
- d. Mass consistency
- e. Family history of head and neck masses-----
- f. History of exposure to x ray/imaging studies Y() or N ()
- g. Other underlying condition/s-----
- h. Clinical diagnosis-----

Specimen reporting

Specimen adequacy satisfactory (1) unsatisfactory (2)

Microscopic description-----

----- Interpretation-----

- a. Specimen adequacy- satisfactory (1) -----unsatisfactory (2)
- b. Negative for malignancy (3) -----specify-----
- c. Suspicious for malignancy (4) -----specify-----
- d. Positive for malignancy (5) -----specify-----
- e. Infections (6) -----specify-----

Signatures

Cytologist

pathologist 1

pathologist 2

Appendix II : Papanicolaou Staining Technique.

A conventional smear was stained using PAP stain and examined microscopically by PI and reported by two pathologists.

Papanicolaou staining method Principle of the stain

Hematoxylin stains the nuclei blue by dye lake formation. The eosin azure solution being acidic stains the cytoplasm. The eosin stains the mature cells while light green stains the young cells. Orange G stains the cytoplasm and stains keratin.

Staining technique

1. The smears were fixed in 95% ethanol for 15 minutes.
2. Hydrated smears through ethanol grades of 80%, 70% and then 50%
3. Rinsed in distilled water ----- 10 dips
4. Stained in Harris hematoxylin ----- for 4 minutes
5. Rinsed in tap water
6. Differentiated in 0.05% acid water ----- 10 dips
7. Rinsed in tap water and blue in Scott's tap water ----- 10 dips
8. Rinsed in 95% ethanol ----- 10 dips
9. Stained in O.G 6 for ----- 2 minutes
10. Rinsed in 95% ethanol ----- 10 dips
11. Stained in E.A.50 for ----- 4 minutes
12. Rinsed in 95% ethanol ----- 10 dips
13. Dehydrated in changes of absolute ethanol ----- 10 dips each
14. Cleared in 3 changes of Xylene ----- 10 dips each
15. Mounted in D.P.X

Appendix III : Modified Pap Technique

Principle of the stain

Hematoxylin stains the nuclei blue by dye lake formation. The eosin azure solution being acidic stains the cytoplasm. The eosin stains the mature cells while light green stains the young cells.

Staining technique

1. The air-dried smears were placed in normal saline for 30 sec and then in alcoholic formalin for 10 sec
2. They were rinsed in tap water 6 slow dips
3. Stained in hematoxylin for 30 sec
4. Rinsed in tap water 6 slow dips
5. Rinsed in isopropyl alcohol 95% (6 dips)
6. Stained in EA 36 (15 sec)
7. Dehydrated in isopropyl alcohol 95% (6 dips)
8. Dehydrated in isopropyl alcohol 100% (6 dips)
9. Cleared in Xylene (10 slow dips)
10. Mounted in DPX.

Appendix IV: Touch Imprint Procedure

1. Immediately after surgical removal of biopsy gross examination of the specimen was done.
2. The specimen was cut with a sharp knife into two halves.
3. The cut surface was wiped off the excess blood, if present, with the help of a filter paper.
4. The labelled glass slide was pressed gently on to the freshly cut surface of the specimen, avoiding a gliding movement, and lifting up the slide. The excess of fluid i.e. blood, saline water, cyst contents, was gently blotted with dry gauze to facilitate adhesions of the cells to the surface of glass.
5. For squash smear, small fragments of tissue were kept between two slides, which then were pulled apart gently.
6. A minimum of four smears was obtained from each specimen.

7. One imprint slide was immediately fixed in 95% ethyl alcohol for a minimum of 15 minutes. This was stained with routine Papanicolaou stain (appendix 4).
8. Air-dried smears were stained by May Grünwald Giemsa (MGG) (appendix 7) and modified Papanicolaou method (appendix 5)
9. The other remaining slide were kept for ancillary testing.
10. After completion of the cytological procedure, the surgical biopsy specimen was immediately fixed in 10% buffered formalin and taken to histology laboratory for routine processing and reporting by pathologists.

Appendix V: May Grunwald- Giemsa Staining Technique

Principle of the stain

May-Grünwald staining combines the effect of acidic eosin and alkaline methylene blue. Giemsa staining makes effect of azure. This stains all cellular components. The pH is a very important factor in staining, so any change will lead to wrong staining reaction. The suitable pH is 6.8.

Method

1. Air dried smear were fixed in absolute methanol for 15 minutes
2. Stained in May-Grünwald solution for 5 min.
3. Stained in Giemsa working solution for 10 min.
4. Rinsed in buffer 6.8
5. Rinsed in buffer/acetone.
6. Dehydrated in acetone x2.
7. Cleared in xylene x3.
8. Mounted in DPX.

Notes: dissolve 5 ml of Giemsa dye in 50 ml of distilled water.

Results:

1. Methylene blue stains blue the acidic components of the cell blue
2. Eosin stains orange-red the alkaline components of the cell

3. Azure stains red and purple the basic cellular component