

ORIGINAL ARTICLE

Evaluation of anesthesia produced by ketofol in acepromazine- or medetomidine-sedated dogs

Moses Njino Wamaitha, Eddy M. Mogo, John D. Mande

Department of Clinical Studies, Faculty of Veterinary Medicine, University of Nairobi, Nairobi, Kenya

ABSTRACT

Objective: A randomized, blinded clinical study was conducted to evaluate ketofol (Ketamine + Propofol combination) anesthesia in 12 entire male mongrel dogs sedated with either acepromazine (ACP) or medetomidine.

Materials and Methods: Group A (6) dogs were pre-medicated with ACP and Group B (6) dogs with medetomidine. Anesthesia was induced and maintained using ketofol (ketamine and propofol). Routine open pre-scrotal castration was performed. Sedation score and ease of arousal were assessed and recorded. Duration and depth of anesthesia were evaluated using apnea and the absence of palpebral and pedal reflexes, attempts to stand up, and muscle tremors and post-operative pain. Simple statistics were compared using Student *t*-test and Mann–Whitney test ($p < 0.05$).

Results: Medetomidine-sedated dogs had higher sedation scores compared to ACP-sedated dogs. Medetomidine-ketofol produced significantly ($p < 0.05$) longer duration of anesthesia (24.5 ± 3.1 min) compared to ACP-ketofol (10.0 ± 4.4 min). Sixty-seven percent of dogs anesthetized with ACP-ketofol required top up with ketofol to complete the castration. However, none of the Med-ketofol anesthetized dogs required top up. Med-ketofol produced a more profound depth of anesthesia and smoother recovery from anesthesia compared to ACP-ketofol. Med-ketofol (median score 6) attained better overall post-operative analgesia compared to ACP-ketofol (median score 7), though not statistically significant ($p = 0.25$). Although both protocols provided adequate anesthesia for castration, top up was required to complete the operation in more than half of ACP-ketofol anesthetized dogs, making Med-ketofol a better protocol.

Conclusion: The study recommends the use of Med-ketofol anesthesia for castration in a dog, and post-operative analgesia to be administered with either protocol, but more so in ACP-ketofol anesthetized dogs undergoing castration.

ARTICLE HISTORY

Received November 07, 2018

Revised November 20, 2019

Accepted December 18, 2018

Published April 14, 2019

KEYWORDS

Acepromazine; medetomidine; ketofol; anesthesia; analgesia



This is an Open Access article distributed under the terms of the Creative Commons Attribution 4.0 Licence (<http://creativecommons.org/licenses/by/4.0>)

Introduction

Premedication is commonly used to reduce anxiety and sedate dogs and cats. Acepromazine antagonizes dopamine centrally, produces sedation, relaxes the muscle, and reduces spontaneous activity, produces no analgesia, and has no reversal agent. Acepromazine at 0.05 mg/kg intravenously produces sedation within 10 min [1,2].

Medetomidine is a widely used alpha-2-adrenoceptor agonist with rapid onset of sedation, analgesia, and muscle relaxation following intramuscular administration to dogs and cats. Administration to dogs at 30 µg/kg,

intramuscularly, provides significant sedation that is evident within 5 min and lasts for 1–2 h [1]. It also produces analgesia and muscle relaxation and substantially reduces the amount of injectable and inhalational anesthetic required to induce and maintain anesthesia when used as a premedicant [3].

Ketamine is a dissociative anesthetic described as a competitive N-methyl-D-aspartate (NMDA) receptor antagonist and at very low doses contributes to analgesia by minimizing central nervous system (CNS) sensitization [4]. Ketamine is more useful for anesthesia and post-operative analgesia in

Correspondence Moses Njino Wamaitha ✉ earmoses@gmail.com 📧 Department of Clinical Studies, Faculty of Veterinary Medicine, University of Nairobi, Nairobi, Kenya.

How to cite: Wamaitha MN, Mogo EM, Mande JD. Evaluation of anesthesia produced by ketofol in acepromazine- or medetomidine-sedated dogs. *J Adv Vet Anim Res* 2019; 6(2):215–21.

integumentary and superficial musculoskeletal surgery [5] and is associated with increased muscle tone, spontaneous movement, violent recoveries, and convulsions.

Propofol, a slightly water-soluble phenolic compound, induces depression by increasing the effects of the inhibitory neurotransmitter gamma-aminobutyric acid and decreasing the brain's metabolic activity. It inhibits NMDA receptors by modulating channel gating [1]. Although associated with post-induction apnea [6], it produces smooth recovery, especially when combined with alpha-2-adrenoceptor agonists [7,8].

Combination of ketamine and propofol in a predetermined ratio [1:1 to 3:7(mg)] produces a mixture called ketofol. The propofol in the admixture provides rapid and smooth induction, maintenance of anesthesia and recovery from anesthesia, and analgesic effects from ketamine. However, propofol results in a dose-dependent drop in respiratory rate and mean arterial pressure [9,10,11].

Veterinarians perform anesthesia and surgery in most practices in developing countries that have resources such as anesthetic machines and monitors and trained veterinary nurses. A less technically demanding protocol with minimal intraoperative monitoring, adequate anesthesia and analgesia is desirable. Total intravenous anesthesia with ketofol is widely used globally. However, inadequate knowledge, skills, and experience have limited its application in Kenya. Data on anesthesia and post-operative analgesia properties of ketofol in medetomidine- or acepromazine (ACP)-sedated dogs are not at sufficient level. This study aimed to evaluate ketofol anesthesia in medetomidine- or ACP-sedated dogs.

Materials and Methods

Ethical approval

This experiment was approved by Biosafety, Animal Use and Ethics committee. REF: FVM BAUEC/2016/93. The experiment observed proper animal welfare and did not adversely affect the animals, and dogs were re-homed after completion of the experiment.

Study design

This was a prospective, blinded experimental study in which 12 male dogs were randomly allocated into two groups A and B of six animals each. Dogs in group A were anesthetized using ACP + ketofol, while those in group B were anesthetized using medetomidine + ketofol. Anesthesia was followed by routine castration and evaluation of parameters.

The experimental animals

Twelve male mongrel dogs were used in this study. The dogs were acquired from willing owners within the vicinity

of the Faculty of Veterinary Medicine's Animal Hospital. Once acquired, dogs were subjected to routine clinical examination to screen them for the presence of any disease. Only dogs free from clinical disease(s) were used in this study. The dogs were housed in individual kennels at the Department of Clinical Studies and fed on commercial dog ration once daily. Water was provided *ad libitum*.

All animals were dewormed using a broad spectrum dewormer (Vermic Total®, Laboratorios Microsules, Uruguay) and ectoparasites were controlled using an acaricide (Steladone®, Zagro Singapore PTE Limited) once a week. Dogs were allowed to acclimatize to their new environment for a period of 2 weeks before enrollment in the study. During the acclimatization period, dogs were subjected to weekly clinical examination and regular interactions to get them used to handling and manipulation. The 12 dogs were randomly assigned via a computer-generated random number table to two treatment groups of six dogs each. The two groups were designated as Group A and B.

Experimental drugs and dosages

The following drugs were used in this study at the specified dosages:

- a. Acepromazine maleate (0.1 mg/kg body weight) (Aceprom Inj, Centaur Labs, Isando, South Africa) was administered intramuscularly to sedate the dogs in Group A.
- b. Medetomidine (0.02 mg/kg body weight) (Domitor® 1 mg/ml, Orion Pharma, Vetoquinol, United Kingdom) was administered intramuscularly to sedate the dogs in Group B.
- c. Ketofol (4.0 mg/kg body weight) was administered intravenously to induce and maintain anesthesia in all dogs. Ketofol was prepared in a ratio of 1:1 by mixing 2 mg/kg body weight of ketamine (Ketamine Hydrochloride injection USP, Rotexmedica, Trittau, Germany) and 2 mg/kg bodyweight of propofol (Propofol® Lipuro 1%, B Braun, India) in the same syringe.

Treatment 1

Each of the six dogs in group A was premedicated using ACP (0.1 mg/kg body weight) administered intramuscularly and anesthesia was induced and maintained using ketofol (4.0 mg/kg body weight) administered intravenously.

Treatment 2

Each of the six dogs in group B was premedicated using medetomidine (0.02 mg/kg body weight) administered intramuscularly and anesthesia was induced and maintained using ketofol (4.0 mg/kg body weight) administered intravenously.

Experimental procedure

Food and water were withheld from each dog 12 h before the surgery as a routine pre-anesthetic preparation. Each dog was weighed before the experiment using a digital weighing scale (Momert® Large Pet Scale, Scandivet). The sedation and pain scores, pedal and palpebral reflexes were assessed before sedation (baseline values). Dogs in Group A were sedated with ACP (0.1 mg/kg), while those in Group B were sedated with medetomidine (0.02 mg/kg) administered intramuscularly into the lateral thigh muscle. The investigator was blinded to treatments so as to reduce any bias. Each dog was muzzled and restrained by an assistant during the injections.

Ten minutes after premedication, an intravenous catheter was placed into the cephalic vein of the right forelimb of each dog. The pre-scrotal area for each dog was then shaved, scrubbed, and disinfected with 70% ethyl alcohol in preparation for an aseptic surgery with the dog restrained in dorsal recumbency by an assistant. Anesthesia was induced by injecting ketofol intravenously, 30 min after administration of the respective sedative. The pre-calculated dose of ketofol in each dog was administered slowly as a bolus and this was followed by endotracheal intubation. Following induction and intubation, dogs were moved from the preparation room to the theatre and positioned on a surgical table in dorsal recumbency with the limbs loosely secured onto the surgical table. A multi-parameter physiological monitor (S. cure, Silverline Meditech Private Limited, S.G. Highway, Ahmedabad, Gujarat, India) was used as an aid for anesthesia monitoring. Dogs were monitored until the restoration of the laryngeal reflex (indicated by coughing) following which, ketofol top up at a standardized dose (50% of the induction dose) was administered intravenously as a bolus to all dogs. In case where surgery would not be completed without an extra top up from the prior mentioned, then ketofol 25% of the induction dose was prepared for administering intravenously upon need. Orchiectomy (castration) was then performed routinely. Warm lactated Ringer's solution (RL, Compound sodium lactate intravenous infusion, REG KE: H2010/21423/585, Abacus Parenteral Drugs Ltd, Uganda) was administered intravenously via the same preplaced catheter at 10 ml/kg/hr to each dog throughout the period of anesthesia until the animal was extubated.

Evaluation of sedation and anesthesia

The sedation score was assessed every 5 min from the time of injection of the premedicant using a previously described protocol of Tsai et al. [12]. During the sedation period, dogs were monitored in the preparation room for ease of arousal from normal movement or noise in the room.

Anesthesia was assessed using duration of anesthesia, extubation time, and time standing. Dogs were assessed for apnea following induction with ketofol. Furthermore, the depth of anesthesia was evaluated by assessing the pedal and palpebral reflexes during anesthesia. Duration of anesthesia was defined as the time between induction of general anesthesia and the first ketofol top up. The endotracheal tube was removed when the laryngeal reflex (indicated by coughing) was restored. Extubation time was defined as the time from intubation to the time when the endotracheal tube was removed. Presence or absence of the pedal reflex (based on limb withdrawal or non-withdrawal, respectively) was obtained by application of firm pressure on the interdigital skin of either hindlimb of the treatment animals while under general anesthesia. Furthermore, the onset and duration of absence of the pedal reflex were noted for each dog in both treatment groups. The palpebral reflex was evaluated by running a finger along the eyelashes of the dogs while under general anesthesia in both treatment groups. The presence or absence of the reflex was determined by the presence or absence of blinking/movement of eyelids, respectively. In addition, the duration of absence for both palpebral and pedal reflexes was noted for each dog in both treatment groups. During recovery, dogs were monitored for tremors by observation. Furthermore, attempts to stand unaided were counted and noted for each dog.

Assessment of post-operative pain

Post-operative pain was assessed based on changes in animal behavior, using the Short Form Glasgow Composite Pain Scale [13].

Animal behavior characteristics evaluated included posture, comfort and vocalization, attention to the wound, demeanor and response to humans, mobility, and response to touch. The four parameters: comfort, vocalization, posture, and attention to the wound were evaluated by the observation of the dog. Response to touch was evaluated by applying gentle pressure 2 inches from the wound margin. Mobility was evaluated by putting the dog on a lead and walking out of the examination room. The scores obtained for the component categories of the pain scale were summed to get a total pain score. The minimum possible total pain score obtainable using this scale is 0, while the maximum possible pain score is 24. Post-operative total pain scores at each observation were recorded based on the classification by Tsai et al. [12]. Pain was assessed before sedation (baseline) and then at 1, 2, 4, 8, and 24 h post-operatively. There was a pre-determined criterion for exclusion of any dog from the study based on total pain score. Any patient with a total pain score of ≥ 13 at any assessment period was to be discontinued from the study and treated with Phenylbutazone (Butamic®, Phenylbutazone 20% Laboratorios Microsules, Uruguay) at 8 mg/kg body weight, intramuscularly.

Data management and analysis

Data were entered into Microsoft Office Excel 2010. Parametric data were expressed as mean \pm SD and compared between the two treatment groups using student *t*-test. Non-parametric data were expressed as median values. The median values were compared using the Mann-Whitney test. Statistical significance was set at $p \leq 0.05$

Results

Eighty-three percent of dogs (5 out of 6) sedated with medetomidine had a sedation score of 1 at 5 min following administration of the drug. However, all dogs in this group eventually attained sedation score 2 during the 30 min of pre-induction evaluation. 33% of dogs pre-medicated with ACP attained sedation score 1 within 10 min of administration. However, only one out of the 6 dogs in this group managed to attain score 2 sedation within 30 min of pre-induction evaluation. Dogs sedated with ACP (67%) were easily aroused from sedation by normal movement or noise during the sedation evaluation period. On the contrary, only 33% of dogs sedated with medetomidine were easily aroused while sedated. Apnea was experienced in 67% of dogs in Med-ketofol as compared to 33% of dogs in ACP-ketofol.

Dogs that were treated with Med-ketofol had significantly ($p = 0.02$) shorter duration of anesthesia and a significantly ($p < 0.01$) longer extubation time as compared to dogs that were treated with ACP-ketofol. Dogs that were anesthetized with ACP-ketofol took significantly ($p = 0.04$) longer (37.2 ± 18.7 min) time to stand, when compared to dogs that were treated with Med-ketofol (17.0 ± 7.1 min).

Despite no significant difference ($p = 0.68$) in the number of attempts made by dogs to stand between the two treatments groups, dogs anesthetized with Med-ketofol made relatively fewer attempts (2.0 ± 0.63) to stand compared to those in the ACP-ketofol treatment group (2.2 ± 0.75). Furthermore, dogs in Med-ketofol treatment group appeared to struggle less while attempting to stand compared to those in the ACP-ketofol treatment group.

The loss of pedal reflex in both treatment groups was evident 5 min post-induction. However, the pedal reflex was absent for significantly ($p = 0.01$) longer time (50 min) in dogs in the Med-ketofol treatment group than it was for those in the ACP-ketofol group (10 min). The absence of the palpebral reflex was recorded in both treatment groups at 5 min following induction of general anesthesia. However, following this, the duration the palpebral reflex was absent was significantly ($p = 0.04$) longer in the Med-ketofol treatment group (30 min) when compared to that in the ACP-ketofol treatment group (5 min).

Even after the 50% ketofol dose top-up for all dogs, four out of 6 dogs (67%) anesthetized with ACP-ketofol required yet another top up with ketofol for the surgery

to be completed. However, none of the dogs anesthetized with Med-ketofol required an extra top up of ketofol for the completion of surgery. On the other hand, five dogs (83%) under the ACP-ketofol treatment group experienced tremors during recovery compared to two dogs (33%) in Med-ketofol treatment group.

Post-operative analgesia

The median pain scores in both treatment groups gradually dropped from the first hour post-operatively to 24 h post-operatively. Dogs that were anesthetized with ACP-ketofol had lower median pain score in the first hour post-operatively (median score 8.5) compared to dogs that were anesthetized with Med-ketofol (median score 9) (Table 1, Fig. 1). However, the difference was not statistically significant ($p = 0.81$). In the second hour post-operatively, the median pain score in dogs that were anesthetized with ACP-ketofol (median score 8) was significantly ($p = 0.01$) higher compared to dogs that were anesthetized with Med-ketofol (median score 6). In the fourth hour post-operatively, the median pain score in dogs that were anesthetized with ACP-ketofol (median score 7) was significantly ($p = 0.01$) higher compared to that in dogs that were anesthetized with Med-ketofol (median score 6). In the eighth hour post-operatively, the median pain score in dogs that were anesthetized with ACP-ketofol (median score 6.5) was significantly ($p = 0.004$) higher than that in dogs that were anesthetized with Med-ketofol (median score 4.5). At the end of the monitoring period (24 h post-operatively), the median pain score in dogs that were anesthetized with ACP-ketofol (median score 5.5) was significantly ($p = 0.01$) higher compared to that in dogs that were anesthetized with Med-ketofol (median score 2.5). However, despite the median pain scores in dogs that were anesthetized with medetomidine-ketofol (median score 6) being lower compared to those dogs anesthetized with ACP-ketofol (median score 7), the difference was not statistically significant ($p = 0.25$).

Discussion

In this study, it was observed that medetomidine scored higher sedation scores than ACP early in the sedation

Table 1. Median values for pain scores in dogs anesthetized with ACP-ketofol and medetomidine-ketofol.

Time Group	1 h	2 h	4 h	8 h	24 h	<i>P</i> value
ACP-ketofol	8.5	8	7	6.5	5.5	0.0007*
Med-ketofol	9	6	6	4.5	2.5	0.0007*
<i>p</i> value	0.81	0.01	0.01	0.004	0.01	

*significant ($p < 0.05$) difference within group, bold figures—significant ($p < 0.05$) difference between the treatment groups.

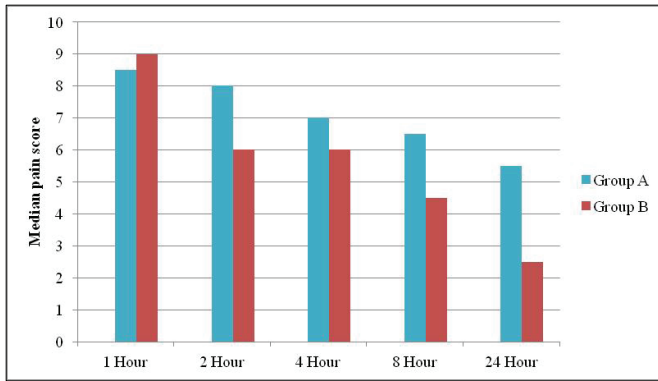


Figure 1. Median values for pain scores in dogs anesthetized with ACP-ketofol (Group A) and medetomidine-ketofol (Group B).

monitoring period. These findings were similar to other previous studies where medetomidine was intravenously administered to dogs (20 or 40 µg/kg, body weight); peak sedation was achieved in 10 min and peak analgesia occurred at 20 min [1]. Dogs sedated with ACP (67%) were easily aroused from sedation by normal movement or noise during the sedation evaluation period. However, only 33% of dogs sedated with medetomidine were easily aroused while sedated. The observation in the study that dogs sedated with medetomidine had deeper and smoother sedation compared to those sedated with ACP was not unexpected and has documented evidence that medetomidine is a potent sedative and analgesic [1]. Similar findings have also been replicated in different studies which established that dogs treated with dexmedetomidine-hydromorphone significantly resulted in more profound sedation than those treated with ACP-hydromorphone [14]. Sedation in veterinary practice is invaluable as it does not only facilitate procedures that do not require general anesthesia but also improve safety when handling veterinary patients. Medetomidine was a better sedative than ACP as it was found to provide anxiolysis and contribute to balanced anesthesia, pre-emptive analgesia, and smooth recovery [15].

There were more dogs that experienced apnea after induction with ketofol in Medetomidine-ketofol group (67%) compared to dogs in ACP-ketofol group (33%). This finding was not unexpected, as both medetomidine and propofol have been documented to cause ventilatory depression while ACP alone has little or no effect on respiration [16]. The post-induction apnea with ketofol is majorly attributed to propofol. Post-induction apnea following administration of propofol has been well documented in both human [17] and animal studies [6,18]. Ketamine and ACP are documented not to cause significant respiratory depression when used solely in animals as the only anesthetic agent [1].

Four out of six dogs (67%) anesthetized with ACP-ketofol required an extra top up with ketofol for the surgery to be completed. However, none of the dogs anesthetized with Medetomidine-ketofol required an extra top up for completion of surgery. This is because dogs anesthetized with ACP-ketofol had a significantly shorter duration of anesthesia compared to dogs that were anesthetized with medetomidine-ketofol. The short duration of anesthesia among dogs anesthetized with ACP-ketofol was attributed to the lack of analgesia from ACP [1]. Analgesia with medetomidine peaks within 30 min of administration and persists for 1–2 h [19,20]. It was observed in this study that dogs anesthetized with Med-ketofol experienced peak analgesia by induction time; hence, the longer duration of anesthesia.

ketofol was used in both treatment groups in this study. Therefore, the difference in the duration of anesthesia is postulated to be a factor of analgesic properties that medetomidine possesses. Medetomidine is a more potent sedative [1] than ACP; hence, producing better muscle relaxation for surgery. The analgesic properties attributed to medetomidine were moreover augmented by the analgesic properties of ketamine [5] in ketofol admixtures. The prolonged duration of anesthesia could also be attributed to medetomidine-ketamine ability to depress the thermoregulatory center, muscle relaxation, and reduced shivering [21].

The absence of palpebral reflexes in both anesthesia protocols at 5 min following induction was an indication of sufficient central nervous system depression. However, in the ACP-ketofol treatment group, the absence of the palpebral reflex was short-lived and hence the shorter duration of anesthesia in this treatment group. The difference was attributed to the degree of sedation and depth of anesthesia accorded by either of the anesthetic protocols. Medetomidine is a more potent sedative [1]. In addition, the analgesic properties of ketamine and medetomidine [5] produced a lack of arousal and thus the longer duration of anesthesia.

The study findings revealed that four dogs (83%) in ACP-ketofol protocol experienced tremors during recovery compared to two dogs (33%) in Medetomidine-ketofol anesthesia protocol. Since dogs were housed in the same recovery room with similar ambient temperature, the higher percentage of dogs with tremors in the ACP-ketofol group would be attributed to the sedative used. The study postulates that ACP was not potent enough to cancel out the effects of ketamine on muscle tone. Ketamine is attributed to convulsions, spontaneous movement and increases the muscle tone in dogs [22]. Muscle relaxation can be improved with co-administration of alpha-2-adrenergic receptor agonists [1]. Therefore, it is possible that the use of medetomidine in the Medetomidine-ketofol

group countered the development of tremors during recovery more than ACP did in the ACP-ketofol group.

Despite lack of significant difference ($p = 0.68$) in attempts to stand within the two treatment groups, dogs anesthetized with Medetomidine-ketofol made relatively fewer attempts to stand compared to dogs under the ACP-ketofol protocol. Furthermore, dogs under the Medetomidine-ketofol anesthesia protocol appeared to struggle less while attempting to stand, compared to dogs in ACP-ketofol anesthesia protocol. Recovery was relatively smoother for dogs in Medetomidine-ketofol group compared to ACP-ketofol group. Propofol has been associated with smooth recovery from anesthesia and especially when combined with an alpha-2-adrenergic [7,8]. The insignificant but notable difference in recovery between the study groups could be attributed to medetomidine and ketamine which have analgesic effects. In addition, ketamine [4], propofol [23], and ACP [1] do not possess any analgesic effects. It is possible that the patients in the ACP-ketofol group struggled to wake up due to the ketamine's increase in muscle tone, rough recovery, and some discomfort occasioned by some degree of pain post-surgically. However, the patients in the Med-ketofol group had some analgesia from medetomidine and ketamine, hence probably a more comfortable post-operative period and smoother recovery.

Post-operative median pain score among subjects anesthetized with ACP-ketofol was insignificantly lower in the first hour post-surgery than dogs anesthetized with medetomidine-ketofol. However, the median pain scores among dogs anesthetized with ACP-ketofol remained significantly higher from the second hour up to 24 h post-operatively when compared to pain scores in dogs anesthetized with Med-ketofol. This finding was not unexpected since the analgesic effect of medetomidine peaks within 30 min following its intramuscular administration and persists for 1–2 h [19,20]. The synergy between the analgesic effects of both medetomidine [20] and ketamine [24] cannot be overlooked.

The combined potent sedative effect of medetomidine [20], analgesia, and muscle relaxation would be postulated to make the animals anesthetized more comfortable post-surgically and hence the persistently lower median scores in the Med-ketofol treated group. Since ACP has no analgesic effects [1], the higher pain scores are noted in the dogs in the ACP-ketofol treated group.

The overall insignificant difference in median pain score between the two anesthesia protocols could be explained by the difficulty to evaluate pain scores immediately post-operatively because of changes associated with recovery from anesthesia, such as residual sedation or shivering [25]. Furthermore, the sedation induced by the drug can overcome the pain by dampening the overt signs even though the pain may not be attenuated, and therefore the important need to use a more sensitive pain

evaluation process to distinguish between sedation and analgesia is required [26]. Despite the reducing pain score over the 24 h period, animals in both groups still experienced pain at the end of the 24 h. This study, therefore, recommends that animals undergoing castration under the two study anesthesia protocols, and more especially where the ACP-ketofol regime is used, should receive analgesics post-operatively. This will help not only in managing post-operative pain of the patients but also contribute to the improvement of their welfare.

Conclusion

Dogs premedicated with medetomidine and anesthetized with ketofol had smoother and more profound sedation; more profound depth of anesthesia; longer duration of surgical anesthesia; and smoother recovery from anesthesia, compared to those dogs anesthetized with ACP-ketofol. Furthermore, dogs anesthetized with the Med-ketofol protocol attained better analgesia in the post-operative period as compared to those under the ACP-ketofol protocol. It is the recommendation of this study that the Med-ketofol protocol, at the dosages used in this study, is suitable for short-term surgical procedures in dogs. It is recommended that animals undergoing castration and short-term invasive surgeries, especially with ACP-ketofol regime, should receive analgesics post-operatively for proper post-operative pain management and improved welfare of the patients.

Acknowledgment

The authors wish to appreciate the moral support of Mr. Evans Mburu, Mr. Jones Waigwa, Dr. Wille Mwangi, and Ms. Phyllis Wangari.

Conflicts of Interests

The authors declared that they have no conflict of interest.

Authors' Contribution

Moses Njino Wamaitha designed and conducted the actual research works. Prof. Eddy Mogo and Prof. John Demesi Mande supervised the work. All the authors read and finally approved the manuscript for publication.

References

- [1] Rankin CD. Sedatives and tranquilizers. In: Grimm KA, Lamont LA, Tranquilli WJ, Greene SA, Robertson SA (eds.). 'Lumb and Jones' veterinary anesthesia and analgesia. 5th edition, Blackwell Publishing Ltd, Oxford, UK, pp 196–206, 2015; <http://doi.org/10.1002/9781119421375.ch10>
- [2] Vesal N, Sarchahi AA, Nikahval B, Karampour A. Clinical evaluation of the sedative properties of acepromazine-xylazine combinations

with or without atropine and their effects on physiologic values in dogs. *Vet Arch* 2011; 81:485–98.

- [3] Benson GJ, Grubb TL, Neff-Davis C. Perioperative stress response in the dog: effect of pre-emptive administration of medetomidine. *Vet Surg* 2000; 29:85–91; <http://doi.org/10.1111/j.1532-950X.2000.00085.x>
- [4] Annetta MG, Iemma D, Garisto C, Tafani C, Proietti R. Ketamine: new indications for an old drug. *Curr Drug Targets* 2005; 6(7):789–94; <http://doi.org/10.2174/138945005774574533>
- [5] Sawyer DC, Rech RH, Durham RA. Effects of ketamine and combination with acetylpromazine, diazepam or butorphanol on visceral nociception in the cat. In: Domino EF (ed.). Status of ketamine in anesthesiology, NPP, Ann Arbor, MI, pp 247, 1990.
- [6] Amengual M, Flaherty D, Auckburally A, Bell AM, Scott EM, Pawson P. An evaluation of anaesthetic induction in healthy dogs using rapid intravenous injection of propofol or alfaxalone. *Vet Anaesth Analg* 2013; 40(2):115–23; <http://doi.org/10.1111/j.1467-2995.2012.00747.x>
- [7] Steffey EP, Mama KR, Brosnan RJ, Imai A, Maxwell LK, Cole CA, Stanley SD. Effect of administration of propofol and xylazine hydrochloride on recovery of horses after four hours of anesthesia with desflurane. *Am J Vet Res* 2009; 70(8):956–63; <http://doi.org/10.2460/ajvr.70.8.956>
- [8] Wagner AE, Mama KR, Steffey EP, Hellyer PW. Evaluation of infusions of xylazine with ketamine or propofol to modulate recovery following sevoflurane anesthesia in horses. *Am J Vet Res* 2012; 73(3):346–52; <http://doi.org/10.2460/ajvr.73.3.346>
- [9] Aguiar AJA, Luna SPL, Oliva VNLS. Continuous infusion of propofol in dogs premedicated with methotrimeprazine. *Vet Anaesth Analg* 2001; 28:220–4; <http://doi.org/10.1046/j.1467-2987.2001.00048.x>
- [10] Donnelly RF, Willman E, Andolfatto G. Stability of ketamine-propofol mixtures for procedural sedation and analgesia in the emergency department. *Canad J Hospital Pharmacol* 2008; 61:426–30.
- [11] Kennedy MJ, Smith LJ. A comparison of cardiopulmonary function, recovery quality, and total dosages required for induction and total intravenous anesthesia with propofol versus a propofol-ketamine combination in healthy Beagle dogs. *Vet Anaesth Analg* 2015; 42:350–9; <http://doi.org/10.1111/vaa.12218>
- [12] Tsai TY, Chang SK, Chon PY, Yeh LS. Comparison of postoperative effects between lidocaine infusion, meloxicam and their combination in dogs undergoing ovariohysterectomy. *Vet Anaesth Analg* 2013; 40:615–22; <http://doi.org/10.1111/vaa.12064>
- [13] Reid J, Nolan AJ, Hughes JML, Lascelles D, Pawson P, Scott EM. Development of the short-form Glasgow Composite Measure Pain Scale (CMPS-SF) and derivation of an analgesic intervention score. *Anim Welfare* 2007; 16:97–104.
- [14] Wagner MC, Hecker KG, Pang DSJ. Sedation levels in dogs: a validation study. *BMC Vet Res* 2017; 13(110):1–8; <http://doi.org/10.1186/s12917-017-1027-2>
- [15] Murrell JC. Pre-anaesthetic medication and sedation. In: Duke-Novakovski T, de Vries M, Seymour C (eds.). BSAVA manual of canine and feline anesthesia and analgesia. British Small Animal Veterinary Association, Quedgeley, UK, pp 170–89, 2016; <http://doi.org/10.22233/9781910443231.13>
- [16] Canfrán S, Bustamante R, González P, Cediél R, Re M, de Segura IAG. Comparison of sedation scores and propofol induction doses in dogs after intramuscular administration of dexmedetomidine alone or in combination with methadone, midazolam, or methadone plus midazolam. *Vet J* 2016; 210:56–60; <http://doi.org/10.1016/j.tvjl.2016.01.015>
- [17] Stokes DN, Hutton P. Rate-dependent induction phenomena with propofol: implications for the relative potency of intravenous anesthetics. *Anesth Analg* 1991; 72(5):578–83; <http://doi.org/10.1213/00000539-199105000-00002>
- [18] Muir W, Lerche P, Wiese A, Nelson L, Pasloske K, Whittam T. The cardiorespiratory and anesthetic effects of clinical and supraclinical doses of alfaxalone in cats. *Vet Anaesth Analg* 2009; 36(1):42–54; <http://doi.org/10.1111/j.1467-2995.2008.00428.x>
- [19] Ansah OB, Raekalio M, Vainio O. Comparison of three doses of dexmedetomidine with medetomidine in cats following intramuscular administration. *J Vet Pharmacol Therap* 1998; 21:380–7; <http://doi.org/10.1046/j.1365-2885.1998.00155.x>
- [20] Vainio O, Vaha-Vahe T, Palmu L. Sedative and analgesic effects of medetomidine in dogs. *J Vet Pharmacol Therap* 1989; 15:194–201; <http://doi.org/10.1111/j.1365-2885.1989.tb00664.x>
- [21] Pypendop BH, Verstegen JP. Hemodynamic effects of medetomidine in the dog: a dose titration study. *Vet Surg* 1998; 27:612–22; <http://doi.org/10.1111/j.1532-950X.1998.tb00539.x>
- [22] Kovalcuka L, Birgele E, Bandere D, Williams D. The effects of ketamine hydrochloride and diazepam on the intraocular pressure and pupil diameter of the dog's eye. *Vet Ophthalmol* 2013; 16(1):29–34; <http://doi.org/10.1111/j.1463-5224.2012.01015.x>
- [23] Wilder-Smith OH, Kolletzki M, Wilder-Smith CH. Sedation with intravenous infusions of propofol or thiopentone. 'Effects on pain perception'. *Anaesthesia* 1995; 50(3):218–22.
- [24] Haskins SC, Peiffer RL, Stowe CM. A clinical comparison of CT-1341, ketamine and xylazine in cats. *Am J Vet Res* 1975; 36:1537.
- [25] Matthews KA, Pettifer G, Foster R, McDonnell W. Safety and efficacy of preoperative administration of meloxicam, compared with that of ketoprofen and butorphanol in dogs undergoing abdominal surgery. *Am J Vet Res* 2001; 62:183–93; <http://doi.org/10.2460/ajvr.2001.62.882>
- [26] Seliskar A, Rostaher A, Ostrouska M, Butinar J. Intra- and post-operative analgesic effects of carprofen in medetomidine premedicated dogs undergoing ovariectomy. *Acta Vet* 2005; 55(5–6):435–48; <http://doi.org/10.2298/AVB0506435S>