

# The Relation of the Extracranial Spinal Accessory Nerve to the Sternocleidomastoid Muscle and the Internal Jugular Vein

Thomas Mombo Amuti, BSc<sup>1</sup> Fawzia Butt, BDS, FDSRCS, FICD, MDS-OMFS<sup>1</sup>

Beda Olabu Otieno, BSc Hons, MBChB, MSc<sup>1</sup> Julius Alexander Ogeng'o, BSc Hons, MBChB, PhD, MD<sup>1</sup>

<sup>1</sup>Department of Human Anatomy, University of Nairobi, College of Health Sciences, Nairobi, Kenya

Address for correspondence Thomas Mombo Amuti, BSc, Department of Human Anatomy, University of Nairobi, College of Health Sciences, Nairobi 28148-00200, Kenya (e-mail: tomamuti@gmail.com).

Craniofacial Trauma Reconstruction 2019;12:108–111

## Abstract

The spinal accessory nerve (SAN) exhibits variant anatomy in its relation to the internal jugular vein (IJV) as well as the sternocleidomastoid muscle (SCM). These variations are important in locating the nerve during surgical neck procedures to avoid its inadvertent injury. These variations, however, are not conserved among different populations and data from the Kenyan setting are partly elucidated. This study, therefore, aims to determine the variant anatomical relationship of the SAN to the SCM and IJV in a select Kenyan population. Forty cadaveric necks were studied bilaterally during routine dissection and the data collected were analyzed using SPSS version 21. Means and modes were calculated for the point of entry of the SAN into the posterior triangle of the neck as well as for its relation to the SCM. Side variations for both of these were analyzed using Student's *t*-test. Data relating the SAN to the IJV were represented in percentages and side variations were analyzed using the chi-square test. The SAN point of entry into the posterior triangle of the neck was 5.38 cm (3.501–8.008 cm) on the left side and 5.637 cm (3.504–9.173 cm) on the right side ( $p = 0.785$ ) from the mastoid process. The nerve perforated the SCM in four cases (10%) on the left side and in eight cases (20%) on the right ( $p = 0.253$ ). The SAN lay predominantly medial to the IJV on both sides of the neck, 87.5% on the left side of the neck versus 82.5% on the right ( $p = 0.831$ ). In conclusion, the variant relation of the SAN to the IJV and SCM as observed in this setting is an important consideration during radical neck procedures and node biopsies.

## Keywords

- ▶ Iatrogenic nerve injury
- ▶ sternocleidomastoid perforation
- ▶ radical neck dissections

The spinal accessory nerve (SAN), a component of the accessory nerve, originates from the segments C1–C5. It then ascends lateral to the spinal cord and enters the cranium via the foramen magnum.<sup>1</sup> It exits the cranium via the jugular foramen (JF) descending on the lateral or medial side of the internal jugular vein (IJV).<sup>2</sup> At a point between the upper and the middle thirds of the sternocleidomastoid muscle (SCM) as measured from the mastoid process (MT), the SAN enters the posterior triangle of the neck by perforating the SCM or passing beneath it.

The anatomy of the extracranial SAN displays variations in its relation to the SCM and IJV as well as in its point of entry into the posterior triangle of the neck.<sup>3–8</sup> Data collected from France, the United States of America, and the United Kingdom showed that the SAN perforates the SCM in the majority of their populations and enters the posterior triangle of the neck at a point 4 to 6.7 cm as measured from the MT. In its relation to the IJV, data collected from the United States of America and Australia suggest that the SAN predominantly lies lateral to the IJV. These relations and positions are, however, not conserved

received  
November 27, 2017  
accepted  
December 23, 2017  
published online  
April 4, 2018

Copyright © 2019 by Thieme Medical Publishers, Inc., 333 Seventh Avenue, New York, NY 10001, USA.  
Tel: +1(212) 584-4662.

DOI <https://doi.org/10.1055/s-0038-1641171>.  
ISSN 1943-3875.

among the different populations and data for the Kenyan population are lacking. Knowledge of these variations is important in locating the SAN and avoiding its inadvertent injury during neck procedures such as node biopsies, SAN blocks, and radical neck surgeries, which are widely being practiced in Kenya owing to a rise in nasopharyngeal cancers.<sup>9</sup>

## Methods

The present study, a descriptive cross-sectional study of sample size 40, was performed during a routine dissection at the Department of Human Anatomy, University of Nairobi. The specimens used were from adult Kenyan indigenous ethnicity. Ethical approval for use of cadaveric materials is provided for in the Kenyan Constitution.

Exposure of the SAN followed an initial incision, which was made from the MT to the lateral end of the clavicle. This incision line was extended to the medial end of the clavicle. Another incision was then made from the medial end of the clavicle to the mental protuberance. Using blunt dissection, the skin flap was detached to expose the platysma muscle, which was then incised at a point 1 cm from its attachment at the mandible and reflected. This exposed the posterior triangle of the neck and its contents. The SAN was identified as the nerve that crossed the triangle most superiorly and terminated on the trapezius muscle. Its distance from the MT as it entered into the posterior triangle of the neck was measured using Vernier calipers (seals, professional tools). SAN indices were also calculated by correlating the length of the SAN with the mean length of the ipsilateral SCM. The relations of SAN to the SCM and IJV were also noted and images taken using a digital camera (Carl Zeiss, 12.1 megapixels).

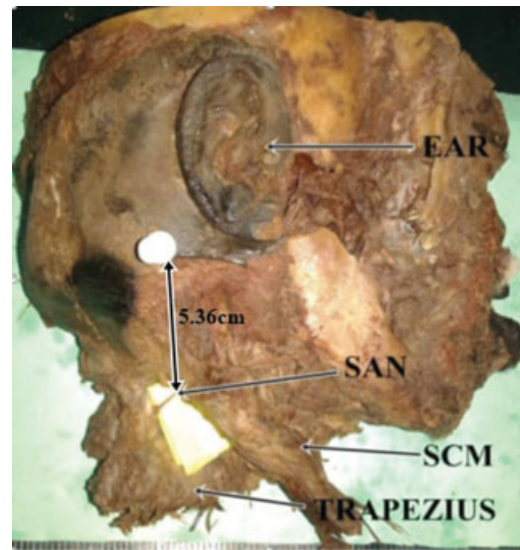
Data collected were analyzed using SPSS (Statistical Package of Social Sciences Version 21.0). The point of entry of the extracranial SAN to the posterior neck triangle of the neck and its relations to SCM was represented in means and modes. Side variations for both of these were analyzed using Student's *t*-test. Data relating the SAN to the IJV were represented in percentages and side variations were analyzed using the chi-square test. A *p*-value of  $\leq 0.05$  was considered significant at 95% confidence interval. Data were presented using tables and photographs.

## Results

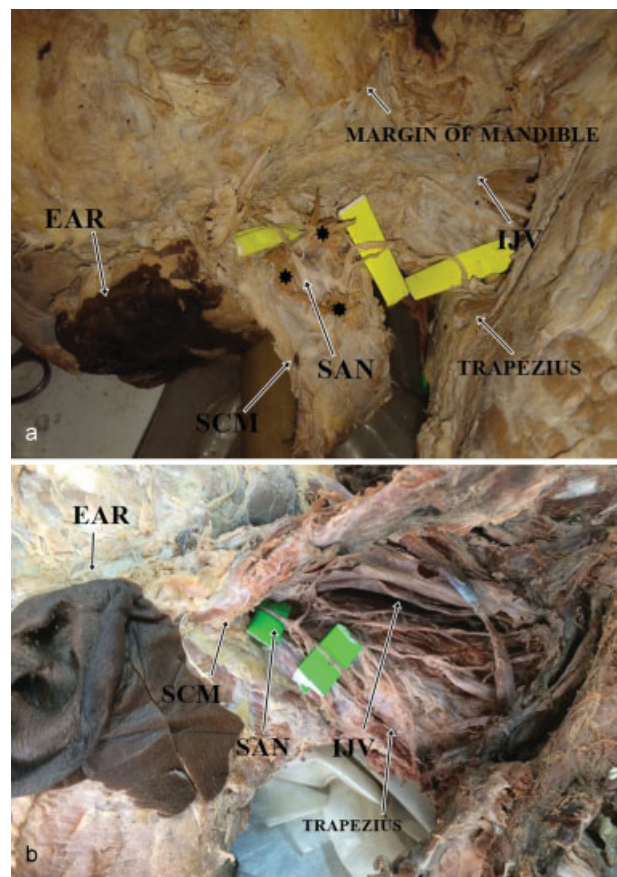
The SAN was found in all 80 dissected necks. The point of entry of the SAN into the posterior triangle of the neck was 5.38 cm (3.501–8.008 cm) on the left side and 5.637 cm (3.504–9.173 cm) on the right side ( $p = 0.785$ ). This distance correlated with the mean length of the ipsilateral SCM (termed SAN index) was  $0.299 \pm 0.0184$  on the left side and  $0.324 \pm 0.00151$  on the right side (**Fig. 1**).

The nerve perforated the SCM in four cases (10%) on the left side and in eight cases (20%) on the right ( $p = 0.253$ ; **Fig. 2a, b**).

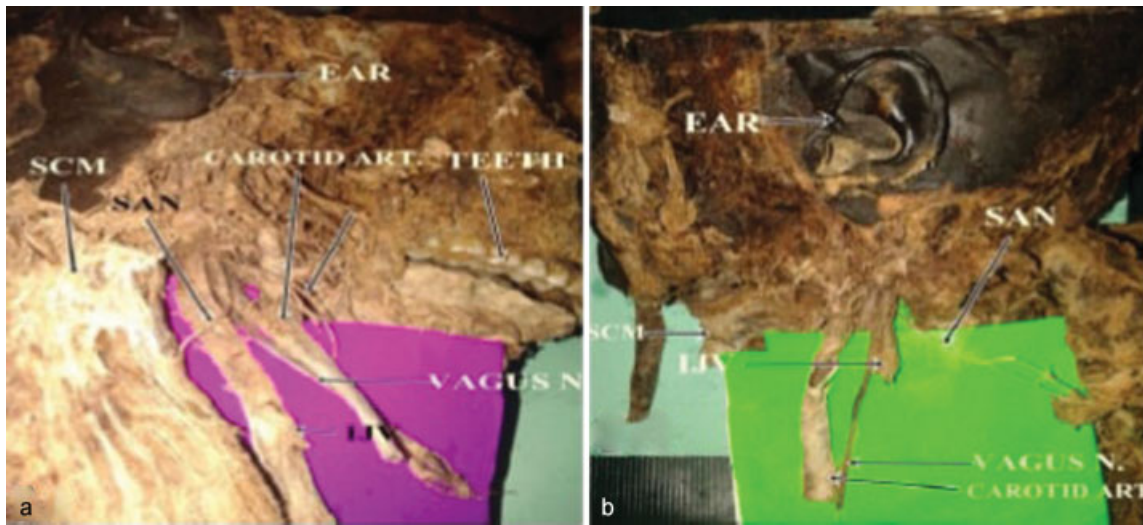
The SAN was found to pass medial to the IJV in 35 out of 40 cases (87.5%) on the left side of the neck and 33 out of 40 cases (82.5%) on the right side ( $p = 0.831$ ; **Fig. 3a, b**).



**Fig. 1** The point of entry of the spinal accessory nerve (SAN) into the posterior triangle of the neck at the posterior border of sternocleidomastoid muscle (SCM) as measured from the mastoid process.



**Fig. 2** (a) The penetration of the sternocleidomastoid muscle (SCM) by the spinal accessory nerve (SAN). Note the dissected muscle fibers (asterisks) of the SCM that have been cut to expose the penetrating SAN. (b) SAN passing beneath the SCM. Note the retracted SCM and its relation to the SAN that is passing beneath it without perforating. IJV, internal jugular vein.



**Fig. 3** (a) Spinal accessory nerve (SAN) passing lateral to the internal jugular vein (IJV). Note the SAN and its relation to the IJV and the carotid artery. (b) SAN passing medial to the IJV. Note the SAN and its relation to the cut IJV.

**Discussion**

When compared with data from the United Kingdom and the United States of America, the SAN in our setting was noted to have a slightly higher point of entry (5.5 cm) into the posterior triangle of the neck as measured from the MT (→Table 1). The higher point of SAN entry in our setting could be attributed to the shorter SCM among the Kenyans as compared with those of the Americans.<sup>10</sup> Since the SAN supplies the SCM, it is possible that its length is affected by the length of the SCM.

The SAN in our setting was also found to perforate the SCM less frequently as compared with data from New Zealand but corresponded with that of France (→Table 2). In lymph node biopsies, the SAN might be confused for the greater auricular or transcervical nerves which appear as if they perforate the SCM and are usually severed.<sup>11</sup> Its variation in terms of perforation of the SCM is therefore of clinical importance. This variation could be attributed to the SCM embryology.<sup>12</sup> During the muscle development, the anterior portions of the muscle develop prior to the posterior portions. As a result, the nerve innervates the anterior portions prior to the

posterior and following full development of the muscle; the SAN appears as if perforating the SCM. This development is tightly regulated by genetic factors. Hence, it is possible that different populations' genetic make-up accounts for the difference in the perforations.

The SAN in the Kenyan population was also noted to maintain a more frequent medial relation to the IJV as compared with the data derived from Australia and the United States of America where the nerve was predominantly on the lateral side<sup>6,7,13</sup> (→Table 3). This variation is important when carrying out node biopsies, since the nerve, being more medial, would make its identification difficult as compared with if it were located lateral to the IJV. The difference on the relation of the SAN to the IJV could be a result of different sizes of the IJV within the JF. A larger IJV within the JF can be hypothesized to displace all nervous contents most medial within the JF just as glomus tumors do.<sup>14</sup> This medial position has been shown to be maintained by the nervous components even past the JF. Studies have shown that indeed Kenyans have a larger IJV than other populations.<sup>15</sup> This might therefore explain the predominant medial relation of the SAN in our setting.

**Table 1** Point of entry of spinal accessory nerve into the posterior triangle of the neck as measured from the mastoid process

Author	Population	Sample size	Point of location at posterior border of SCM
Dailiana et al <sup>3</sup>	France	20	4 cm
Symes and Ellis <sup>4</sup>	United Kingdom	25	6.13 cm
Mirjalili et al <sup>5</sup>	New Zealand	50	6.7 cm
Present study	Kenya	79	5.45 cm

**Table 2** Relation of spinal accessory nerve to sternocleidomastoid muscle

Author	Population	Sample size	Perforated	Not perforated
Cailot et al <sup>8</sup>	France	100	93%	7%
Mirjalili et al <sup>5</sup>	New Zealand	50	58%	42%
Present study	Kenya	79	15%	85%

**Table 3** Relation of spinal accessory nerve to the IJV

Author	Population	Sample size	Lateral to IJV	Medial to IJV
Kierner et al <sup>12</sup>	Austria	46	24/46 (56%)	19/46 (44%)
Hinsley and Hartig <sup>6</sup>	USA	116	112/115 (96%)	3/115 (3%)
Taylor et al <sup>7</sup>	USA	207	198/204 (95.7%)	6/204 (2.8%)
Present study	Kenya	80	11/80 (13.2%)	67/80 (86.8%)

Abbreviation: IJV, internal jugular vein.

## Conclusion

The relations of the SAN to the IJV and SCM in our setting are different from other populations and as such are of clinical importance. These data will also aid in the prevention of future iatrogenic SAN injury in surgical procedures such as lymph node biopsies.

## References

- Sinnatamby C. Last's Anatomy Regional and Applied, 10th ed. Edinburgh: Churchill Livingstone; 1999:388, 494–95, 497–498
- Standring S, Gray H. Gray's Anatomy: The Anatomical Basis of Clinical Practice. Edinburgh: Churchill Livingstone/Elsevier; 2008:460
- Dailiana ZH, Mehdian H, Gilbert A. Surgical anatomy of spinal accessory nerve: is trapezius functional deficit inevitable after division of the nerve? *J Hand Surg [Br]* 2001;26(02):137–141
- Symes A, Ellis H. Variations in the surface anatomy of the spinal accessory nerve in the posterior triangle. *Surg Radiol Anat* 2005; 27(05):404–408
- Mirjalili SA, Muirhead JC, Stringer MD. Ultrasound visualization of the spinal accessory nerve in vivo. *J Surg Res* 2012;175(01): e11–e16
- Hinsley ML, Hartig GK. Anatomic relationship between the spinal accessory nerve and internal jugular vein in the upper neck. *Otolaryngol Head Neck Surg* 2010;143(02):239–241
- Taylor CB, Boone JL, Schmalbach CE, Miller FR. Intraoperative relationship of the spinal accessory nerve to the internal jugular vein: variation from cadaver studies. *Am J Otolaryngol* 2013;34 (05):527–529
- Caliot Ph, Cabanie P, Bousquet V, Midy D. A contribution to the study of the innervation of the sternocleidomastoid muscle. *Anat Clin* 1984;6:21–28
- Linsell CA. Nasopharyngeal cancer in Kenya. Third world of science. *Br J Cancer* 1964;18(01):49–57
- Lefkowitz T, Hazani R, Chowdhry S, Elston J, Yaremchuk MJ, Wilhelmi BJ. Anatomical landmarks to avoid injury to the great auricular nerve during rhytidectomy. *Aesthet Surg J* 2013;33(01): 19–23
- Shiozaki K, Abe S, Agematsu H, et al. Anatomical study of accessory nerve innervation relating to functional neck dissection. *J Oral Maxillofac Surg* 2007;65(01):22–29
- Susanne T. Origin and Development of Cucullaris/Trapezius Sternocleidomastoid Muscles in Birds, Mammals and Reptiles. Anatomical Society of Great Britain and Ireland; 2010
- Kierner AC, Zelenka I, Heller S, Burian M. Surgical anatomy of the spinal accessory nerve and the trapezius branches of the cervical plexus. *Arch Surg* 2000;135(12):1428–1431
- Lustig LR, Jackler RK. The variable relationship between the lower cranial nerves and jugular foramen tumors: implications for neural preservation. *Am J Otol* 1996;17(04):658–668
- Aseta FB, Mwachaka PM, Mandela PI, Ogeng'o J. Variant anatomy of the jugular foramen: an osteological. *Academia Anatomica International* 2016;2(02):38–43