



UNIVERSITY OF NAIROBI

CASE STUDIES

**INVESTIGATOR:
MUNA ALI ABDALLA
H133/25605/2021**

DEPARTMENT OF DIAGNOSTIC IMAGING AND RADIATION MEDICINE,

**A RESEARCH PROJECT SUBMITTED IN PARTIAL FULFILMENT FOR THE
AWARD OF HIGHER DIPLOMA IN MEDICAL DIAGNOSTIC ULTRASOUND,
DEPARTMENT OF DIAGNOSTIC IMAGING AND RADIATION MEDICINE,
FACULTY OF HEALTH SCIENCES, UNIVERSITY OF NAIROBI.**


2023

DECLARATION

I hereby declare that this case studies are my own original work and has therefore not been presented for any award in any other institution.

MUNA ALI ABDALLA

Signature:



Date: 06 September, 2023


SUPERVISORS' APPROVAL

These five case reports compilation in medical ultrasound was carried out at Kenyatta National Hospital and it has been read and approved by Supervisor.

DR. N. M. KIMANI,

Sinor Lecturer and Consultant, Department of Diagnostic Imaging and Radiation Medicine,
Faculty of Health Sciences, University of Nairobi.

Signature:



Date: 06th September, 2023

ACKNOWLEDGEMENT

All praises are to the Almighty God, giver of life who enables me to do all things.

To my parents, husband and entire family, I'm very thankful for your continuous support, encouragement, prayers and having trust in me.

My sincere gratitude goes to all my teachers for their motivation, care, patience for providing their all-time to a single student in a class and providing me with immense knowledge in an excellent atmosphere.

Lastly, I would like to express my deepest gratitude to all University of Nairobi Radiology Department and Kenyatta National Hospital staff.

TABLE OF CONTENTS

DECLARATION AND SUPERVISOR APPROVAL.....	ii
ACKNOWLEDGEMENT.....	iii
CASE 1: UPPER LIMB VENOUS THROMBOSIS.....	1
CASE 2: SURGICAL SITE INFECTION (SSI).....	9
CASE 3: GALL STONES.....	18
CASE 4: BREAST ABCESS.....	25
CASE 5: DECOMPENSATED CHRONIC LIVER DISEASE DUE TO ALCOHOL ABUSE.....	34

Case 1: upper limb venous thrombosis

ABSTRACT

A deep-vein thrombosis (DVT) is a blood clot that forms within the deep veins, usually of the leg, but can occur in the veins of the arms and the mesenteric and cerebral veins. Deep-vein thrombosis is a common and important disease. It is part of the venous thromboembolism disorders which represent the third most common cause of death from cardiovascular disease after heart attacks and stroke. Even in patients who do not get pulmonary emboli, recurrent thrombosis and "post-thrombotic syndrome" are a major cause of morbidity. DVT is a major medical problem accounting for most cases of pulmonary embolism. Only through early diagnosis and treatment can the morbidity be reduced.

The incidence of deep vein thrombosis (DVT) of the upper limb is increasing due to the frequent use of intravenous devices for various indications, underlying disease, sometimes develops as a complication of pacemaker use, long-term use of a central venous catheter (CVC), or cancer.

INTRODUCTION

To withstand the pressure of the heart pumping blood to the far reaches and extremities of the body, arteries have relatively thin muscles within their walls. Since there is nothing pumping blood back to the heart except a physiology, veins do not have a significant lining.

Blood flows from the superficial veins into the deep venous system through small perforator veins. Superficial and perforator veins have one-way valves allowing unidirectional blood to flow only in the direction of the heart when the veins are squeezed.¹

A thrombus in the deep venous system of the leg is not in itself dangerous. The situation becomes life-threatening when an embolus travels through the heart into the pulmonary circulation system and is lodged in the lung. Diagnosis and treatment of deep venous thrombosis (DVT) are to prevent pulmonary embolism (PE).²

There are 2 forms of upper-extremity DVT which are:

- (1) effort-induced thrombosis (Paget-von Schrötter syndrome).
- (2) secondary thromboembolism.

Effort-induced thrombosis, or Paget-von Schrötter syndrome, accounts for 25% of cases. In this primary form of the disease, an underlying chronic venous compressive abnormality caused by the musculoskeletal structures in the costoclavicular space are present at the thoracic inlet and/or outlet.³

CASE REPORT

A 36-year-old female who was a known case of antiphospholipid syndrome presented in the rheumatology clinic with right shoulder and subclavian area pain that is worse on movement with throbbing character on 26/01/2022.

Previously the patient had developed shortness of breath that was severe, occurring during both rest and activity and associated with chest pain and generalized body weakness and cyanosis and was admitted to the ICU.

Investigations were requested including a Doppler assessment of the right subclavian vein to rule out thrombus.

Grey scale and color Doppler evaluation of the right internal jugular and subclavian veins was done and showed echogenic thrombus.

After confirming the diagnosis of thrombus, the patient was admitted to the rheumatology ward and started on CLEXANE 60mg and WARFARIN 10mg.

After those two weeks of treatment, patient clinically was better and the right shoulder pain has completely resolved and was safely discharged home to come again in one month for follow up.

SONOGRAPHIC IMAGES

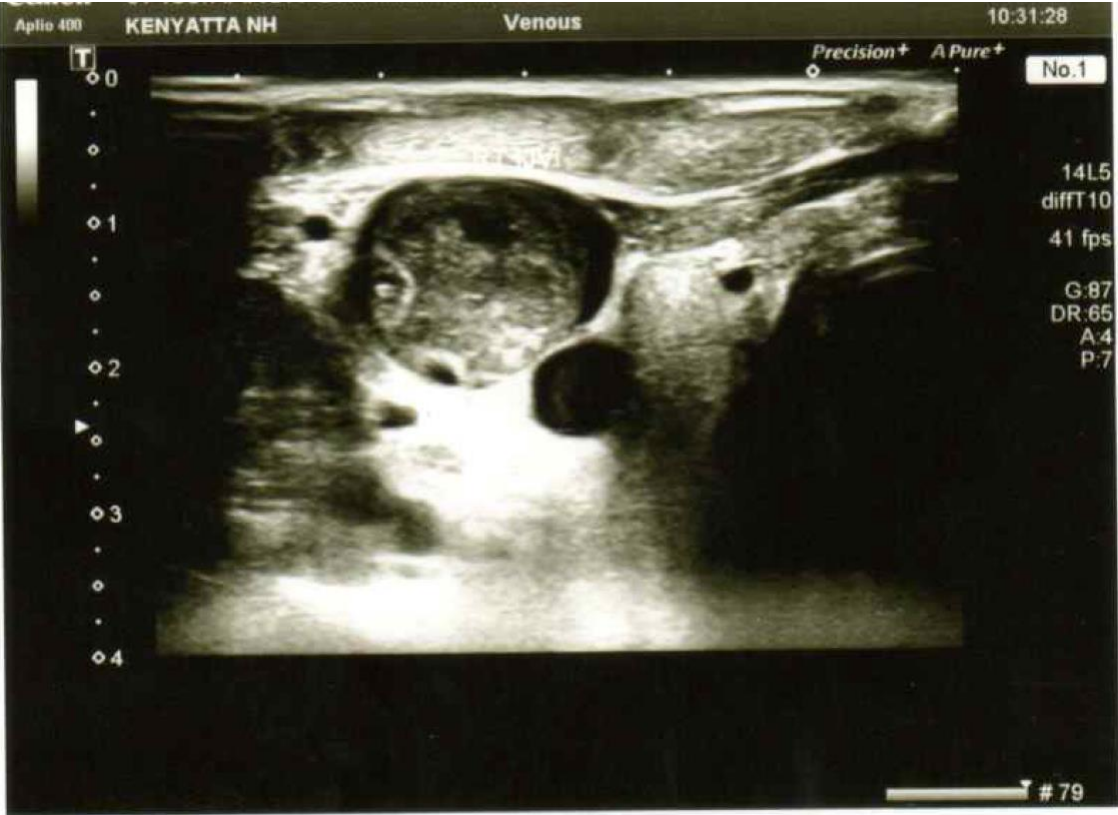

Figure 1: Grey scale transverse scan of right internal jugular vein showing echogenic thrombus.

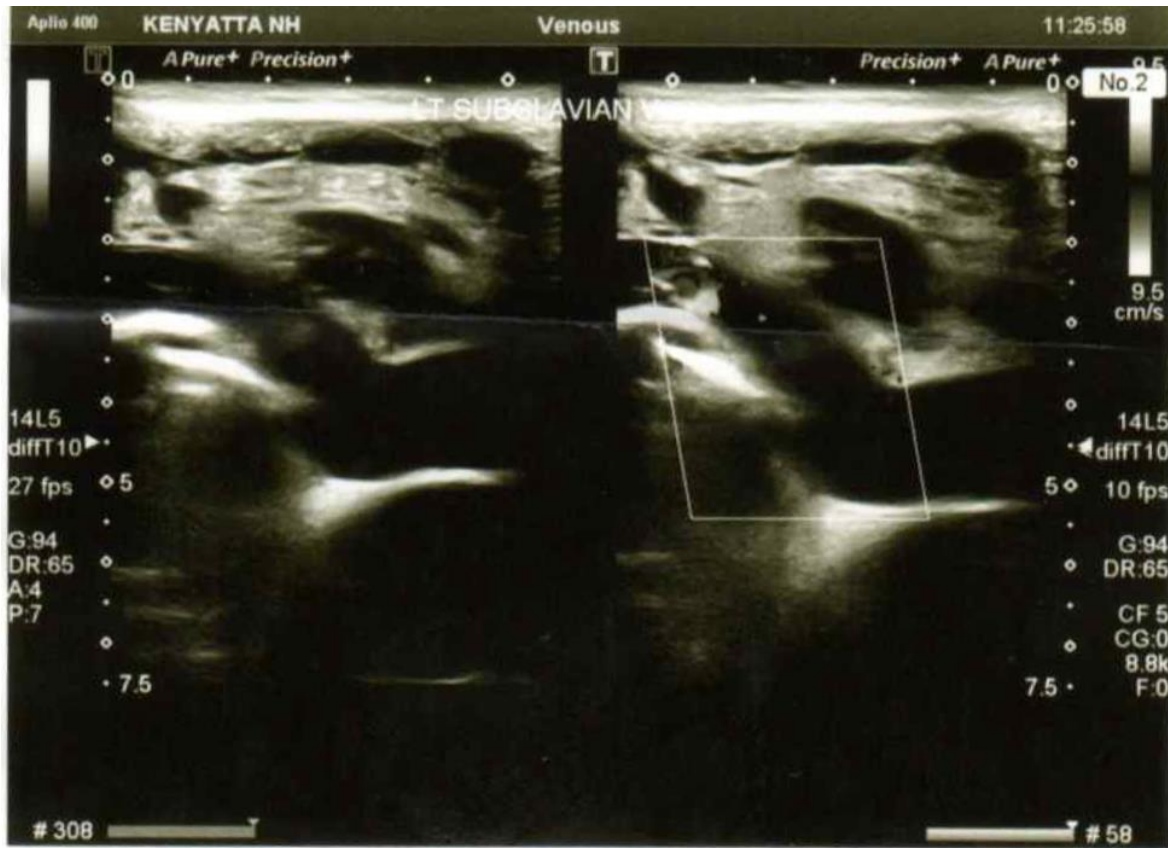


Figure 2: Grey scale and color doppler longitudinal scan of the right subclavian vein showing thrombus with no flow in that part.

DISUSSION

The antiphospholipid syndrome is a relatively common acquired cause of venous thrombosis and the case was a known case of antiphospholipid syndrome.

Antiphospholipid syndrome is a condition in which the immune system mistakenly creates antibodies that attack tissues in the body. These antibodies can accumulate in the vein and produce obstruction to venous outflow and/or vessel wall inflammation.⁴

The spectrum of thrombosis in antiphospholipid syndrome includes both venous and arterial events and thrombosis at nearly every site in the vasculature has been reported.

The most common type of venous thrombosis associated with antiphospholipid syndrome is lower and upper extremity deep vein thrombosis (DVT) with or without pulmonary embolism.

Detailed history taking should look for previous episodes and for inherited disorders of protein C and S deficiency, antithrombin (AT) III deficiency, or an abnormal factor V (factor V_{LEIDEN}).⁵

Pain, swelling and tenderness are the symptoms present in most of patients. The differential diagnosis includes ruptured Baker's_cyst, muscle tear, cramp, hematoma, arthritis, bone disease, varicose veins, and postphlebitic syndrome.

Treatment for DVT usually involves taking anticoagulant medicines. These reduce the blood's ability to clot and stop existing clots getting bigger. Heparin and warfarin are two types of anticoagulants often used to treat DVT. Heparin is usually prescribed first because it works immediately to prevent further clotting.

Clexane which is a low molecular weight heparin and warfarin are the drugs given by the case and resolved the clot.⁶

CONCLUSION

Ultrasound scanning has the advantage as a diagnostic tool to detect DVT because it is noninvasive, requires no contrast medium, can be performed at the bedside, and its relatively low cost.

More recently, duplex scanning has been introduced as another modality for DVT diagnosis. Duplex ultrasound combines B-mode imaging with pulsed-wave Doppler technology.

The ability of ultrasound to detect proximal venous thrombi is dependent upon the clinical milieu in which it is applied. The sensitivity of ultrasound to detect proximal vein thrombosis in symptomatic patients has been shown to be 94 percent to 97 percent.

The limitations of ultrasound must be realized, the ultrasound exam is highly dependent upon technician experience and body habitus of the patient.

REFERENCES

1. Carroll BJ, Piazza G. Hypercoagulable states in arterial and venous thrombosis: When, how, and who to test? *Vasc Med*. 2018 Aug;23(4):388-399.
2. Joffe HV, Goldhaber SZ. Upper extremity deep vein thrombosis. *Circulation*. 2002; 106: 1874-1880.
3. Richard L. Drake, A. Wayne Vogl, Adam W.M. Mitchell, *The veins, Gray's anatomy for students*. 2nd edition, International Edition, Churchill Livingstone elsavier.
4. Guillermo Gonzalez-Osete MD, Manuel Modiano MD, in *Decision Making in Medicine (Third Edition)*, 2010.
5. Wheeler HB, Anderson FA Jr. Diagnostic methods for deep vein thrombosis. *Haemostasis*. 1995; 25: 6-26.
6. Sumner DS. Noninvasive tests in the diagnosis and management of thromboembolic disease. *Surg Annu*. 1986;18:1–28.

CASE 2: POST CAESAREAN SURGICAL SITE INFECTION

ABSTRACT

Post-caesarean section surgical site infection- is defined as the infection that occurred within the first 30 post-operative days and with at least one of the following signs and/ symptoms.

1. Purulent drainage from surgical site.
2. At least one of the following signs or symptoms of infection: pain or tenderness, localized swelling, redness, or heat.
3. Surgical site abscess.
4. Surgical site infection diagnosed by the surgeon or attending physician.

INTRODUCTION

Surgical site infections (SSI) are a common complication after a caesarean section (C-section) and mainly responsible for increased maternal mortality and morbidity, dissatisfaction of patients, longer hospital stays as well as higher treatment costs.¹

Caesarean section is an operative procedure by which a fetus, placenta, and membranes are delivered through an abdominal and uterine incision which is performed whenever abnormal conditions complicate labor and vaginal delivery that threatening the life or health of the mother or the baby.²

In 1985, WHO declared that, the optimal threshold for caesarean section rate should be 10–15%.⁴ But recent studies have reported that the rate of cesarean section is rising rapidly that leads to actual, potential, and life-long maternal and neonatal complications. Despite World Health Organization (WHO) recommended the optimal rate of caesarean section should lie between 5 and 15%, it is significantly increasing; even the reasons for the continued increase in the cesarean rates are not completely understood.³

Women having fewer children, maternal age is rising, use of electronic fetal monitoring is widespread, Malpresentation especially breech presentation, frequency of forceps and vacuum delivery is decreased, rate of labor induction increases, obesity dramatically raises and vaginal birth after cesarean section decreased are some of the possible explanations for increased incidence of cesarean section delivery.⁴

Despite caesarean section a lifesaving medical intervention and procedures to the decrease adverse birth outcome, controlling different postoperative neonatal and maternal complications are challenging in terms of patient safety; postpartum fever, surgical site infection, puerperal sepsis and maternal mortality are among common complications of cesarean section.⁵

CASE REPORT

26 years old Gravida 2 Para presented in the emergency unit 05/08/2022 with localized tenderness and fever three days after an emergency caesarean section.

She was referred from Pumwani Hospital after an emergency caesarean section secondary to preeclampsia and had a post-partum hemorrhage.

Patient was sent for a pelvic ultrasound, Sonographic examination of the pelvic was done, the uterus and both adnexa were assessed for size, shape, echogenicity and vascularity.

The uterus was bulky in size measuring 11.8 x 5.6 x 8.5cm. there was an anterior surgical site complex cystic multiseptated mass measuring 6.3 x 5.2cm. A similar but superficial mid surgical site mass is noted 9.4 x 5.4cm. POD was clear and no adnexal mass seen.

A diagnosis of surgical site infection with abscess was made.

The patient was taken to theatre on 02/09/2022 to do incision and drainage of the abscess and the wound was dressed.

The patient was given FLAGYL 500mg, CEFTRIAZONE 1g, and MEROBENEM 1g.

After five days of medications and wound dressing, the incision had healed and the patient was discharged home.

SONOGRAPHIC IMAGES

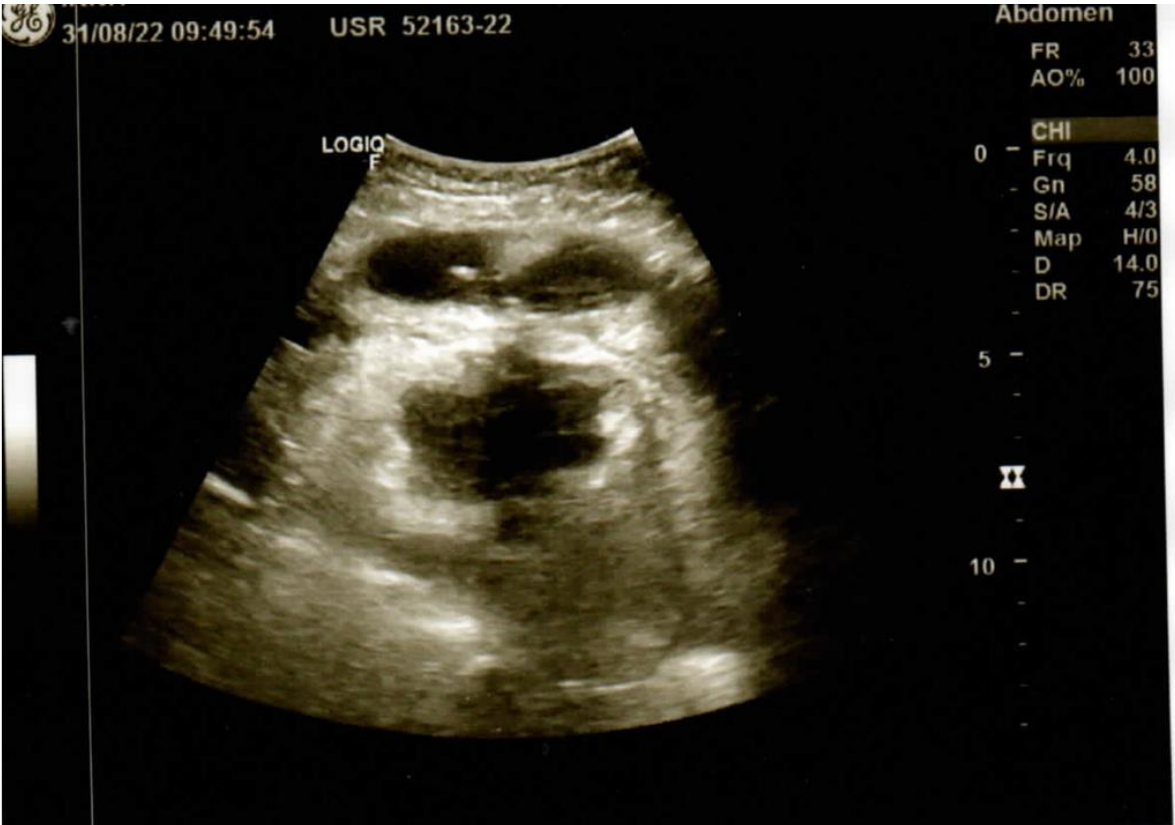

Figure 1: grey scale transverse scan of the surgical site showing septated collection.

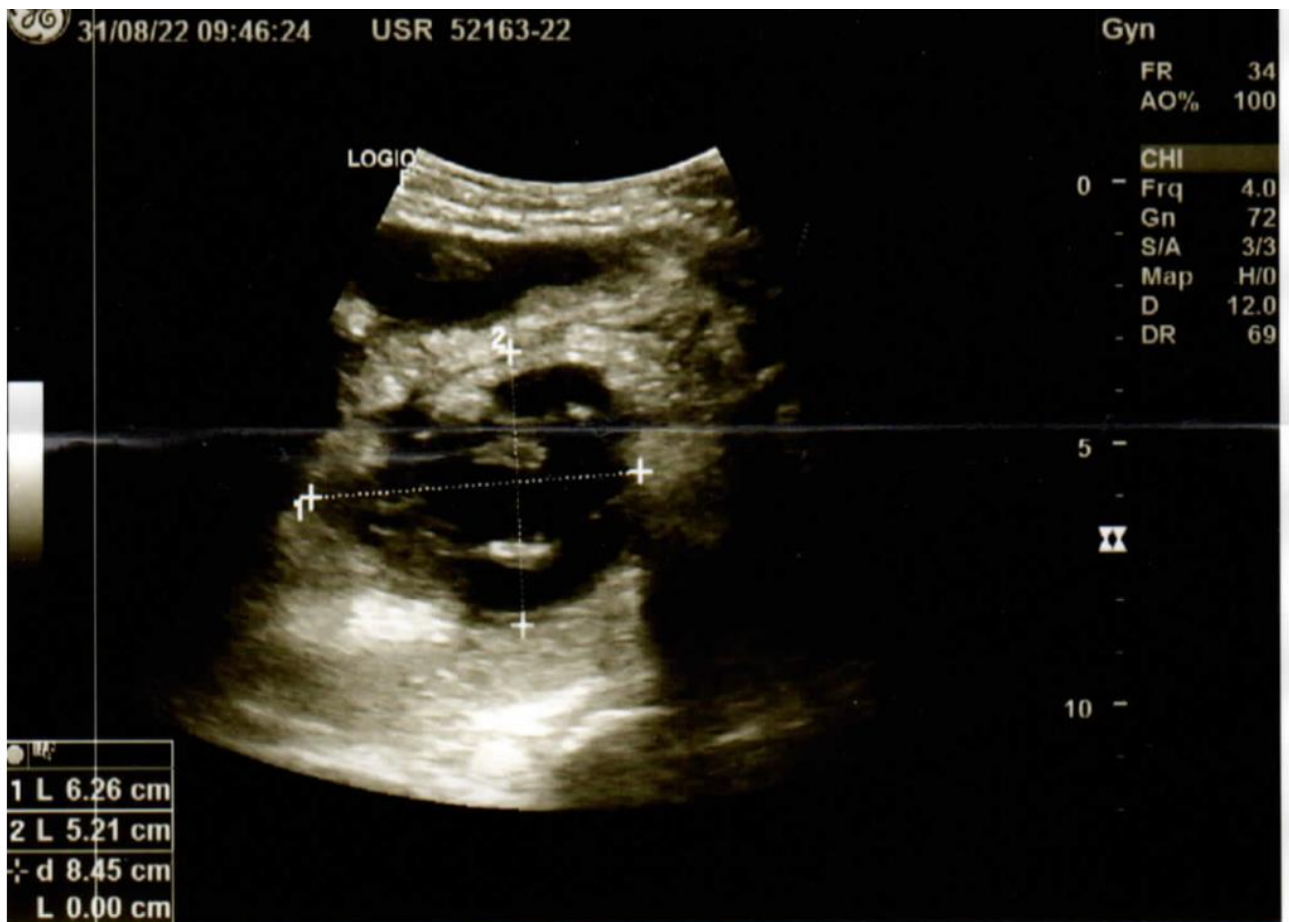

Figure 2: greyscale transverse scan of the surgical site showing collection in pelvic area

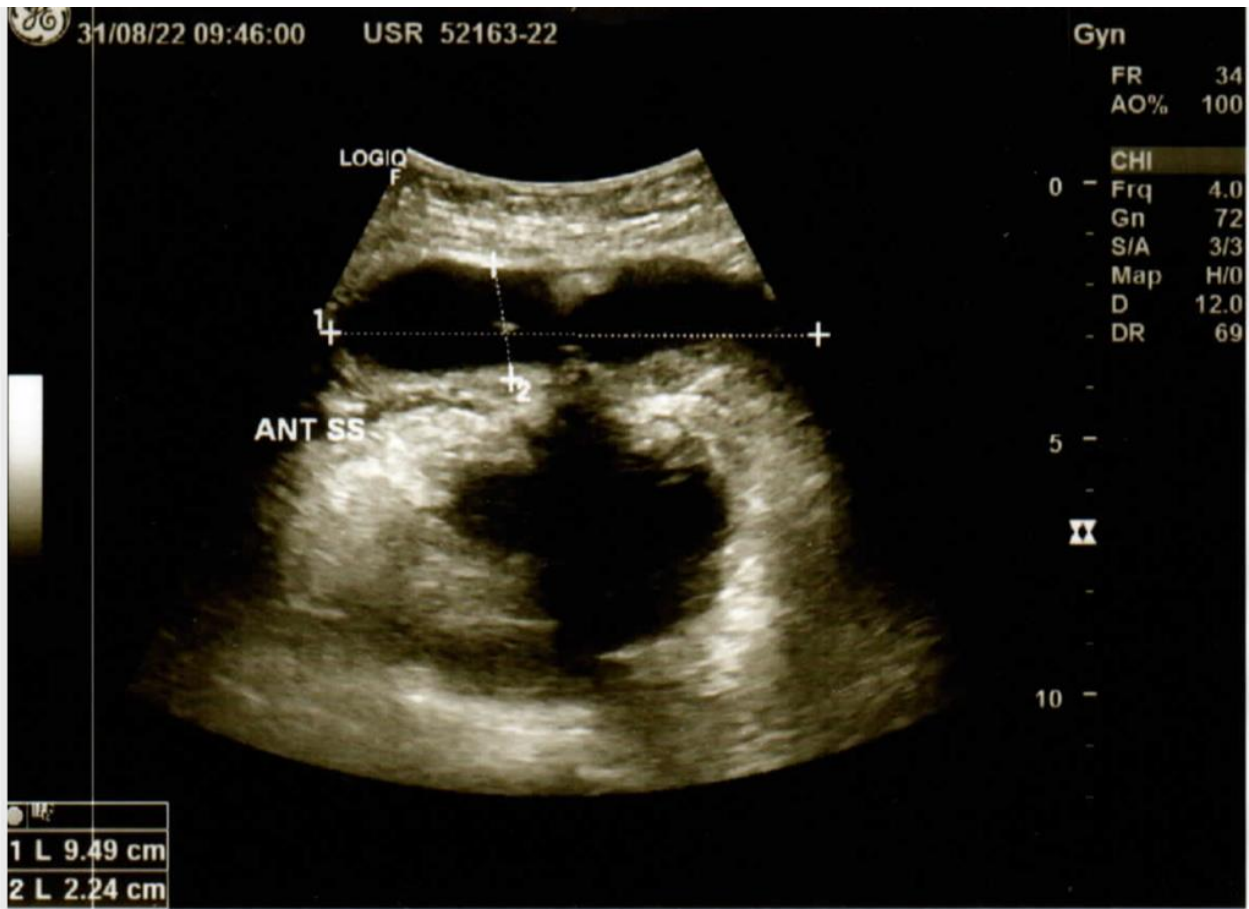


Figure 3: greyscale transverse scan of the surgical site showing septated collection in the anterior fascia.

DISCUSSION

Postoperative wound infections, also known as surgical site infections (SSIs), complicate the recovery course of many patients. As defined by the Centers for Disease Control and Prevention (CDC), these infections typically occur within 30 days of an operation at the site or part of the body where the surgery took place, or within a year if an implant is left in place and the infection is thought to be secondary to surgery.⁶

Although waiting time between surgeries is recommended, emergency surgeries may need to be done close together like in this case which went through two consecutive surgeries which were the caesarean section and exploratory laparotomy. The most common cause of emergency reoperation is hemorrhage and infection.

There are many other factors which can increase the incidence of caesarean sections; for example, women who had a duration of labor greater than 24hrs prior to cesarean section with ruptured membrane are more likely to have surgical site infection than those who were not in labor. The possible explanation could be that as the duration of labor increases, the frequency of vaginal examinations also increases, which leads to ascending infections that might induce post-operative infection.⁷

Women with pregnancy-induced hypertension are more likely to develop SSI than those mothers without the problem, this is because of the hypo-perfusion of the wound caused by the peripheral vasoconstriction effect of hypertension. In addition, those mothers with such problems might have edematous wound edges responsible for the further entry of organisms and establishment of infection. Vascular disruption and high oxygen consumption by metabolically active cells may lead to oxygen depletion and hypoxic wound conditions.⁸

CONCLUSION

The multivariable analysis indicates that emergency surgeries, age of the mother, number of per vaginal examination, previous history of caesarean section, provision of antibiotics prophylaxis, perioperative hematocrit level and duration of rupture of membrane were the independent determinants of post cesarean section surgical site infection. Proper assessment of risk factors that predispose to surgical site infection is critical for the development of strategies for reducing the occurrence of SSI like minimizing the number of vaginal examinations and minimizing the time gap between rupture of membrane and delivery.

Despite one-third of the world population lacking access to essential medicines, governmental and non-governmental stakeholders should apply certain efforts to access prophylactic antibiotics across each health facility to address all the mothers undergoing cesarean section. In addition; health professionals should be comprehensive in providing prophylactic antibiotics for mothers undergoing cesarean section. Health professionals should strengthen their continuous follow-up and SSI risk minimization should be emphasized if chorioamnionitis has developed.

REFERENCE

1. Khan HA, Ahmad A, Mehboob R. Asian Pacific Journal of Tropical Biomedicine. 2015.
2. Horan TC, Gaynes RP, Martone WJ, Jarvis WR, Emori TG. CDC definitions of nosocomial surgical site infections, 1992: a modification of CDC definitions of surgical wound infections. Infection Control & Hospital Epidemiology. 1992;13(10):606–8.
3. Solomokin J, P G, P B, A L, S B, M E, et al. WHO global guidelines for the prevention of surgical site infection Geneva. Switzerland. Lancet Infect Dis. 2017.
4. WHO statement on caesarean section rates. BJOG: An International Journal of Obstetrics & Gynaecology. 2016.
5. Rates of caesarean section: analysis of global, regional and national estimates. Paediatric and perinatal epidemiology. 2007.
6. definition of health care-associated infection and criteria for specific types of infections in the acute care setting. Am J Infect Control. 2008.
7. Magnitude and factors associated with post-cesarean surgical site infection at Hawassa University teaching and referral hospital, southern Ethiopia,2017.
8. Surgical site infection and associated factors among women underwent cesarean delivery in Debretabor General Hospital, Northwest Ethiopia, 2019.

CASE 3: GALL STONES

ABSTRACT

Gallstone disease (choledocholithiasis) is one of the most prevalent gastrointestinal diseases, with a substantial burden to health care systems. Gallstones may form because of many different disorders. Gall stone disease is a chronic recurrent hepatobiliary disease, the basis for which is the impaired metabolism of cholesterol, bilirubin or bile acids.

INTRODUCTION

Choledocholithiasis or gallstones are hardened deposits of digestive fluid that form in the gallbladder. The gallbladder is a small organ located just beneath the liver and it holds a digestive fluid known as bile that is released into the small intestine.¹

It's mostly common in women and most of which are asymptomatic. In patients with asymptomatic gallstones discovered incidentally, there is a likelihood of developing symptoms or complications in the future. Asymptomatic gallbladder stones found in a normal gallbladder and normal biliary tree do not need treatment unless they develop symptoms. However, approximately 20% of these asymptomatic gallstones will develop symptoms over 15 years of follow-up.

These gallstones may go on further to develop complications such as cholecystitis, cholangitis, choledocholithiasis, and pancreatitis.²

Diagnosis of choledocholithiasis is not always straightforward in clinical evaluation and biochemical tests are often not sufficiently accurate to establish a firm diagnosis. Imaging tests, particularly abdominal ultrasound, are used routinely to confirm the diagnosis.³

CASE REPORT

An 11-year-old female, a known case of sickle cell disease presented to the pediatric clinic on 31/10 2022 with history of mild right upper quadrant pain, nausea, vomiting and a mild yellowish discoloration of the sclera for three days.

The patient was sent for lab investigations and the results are as below:

Lab works: HB 9.9, WBC 5.7, urea 3.7, creatinine 82, K+ 3.9, NA+ 140.4, CL- 106.9, ALB 44, ALT57, AST 39, ALP 169, gamma-GT 169.

The patient was sent to the ultrasound department for abdominal ultrasound.

The liver was normal in echogenicity and surface contour. It spans 13.1cm. no focal liver lesions seen and hepatic vessels were normal.

The gallbladder was well distended and had thin walls. An echogenic lesion with posterior shadowing was noted within the gallbladder lumen. No biliary duct dilation seen.

The spleen was enlarged with normal echogenicity and no splenic masses seen.

The pancreas and both kidneys were normal in size, shape, and echogenicity.

No visceral node enlargement or free peritoneal fluid was seen.

CONCLUSION:

- Gall stones (choledocholithiasis).
- Splenomegaly.

The case has been diagnosed with gall stones secondary to sickle cell disease. Analgesics and antiemetics were given and she came back after two weeks for follow up with her symptoms resolved. She was told to do a routine ultrasound for every 3 months to assess the status of her gallstones.

SONOGRAPHIC IMAGES

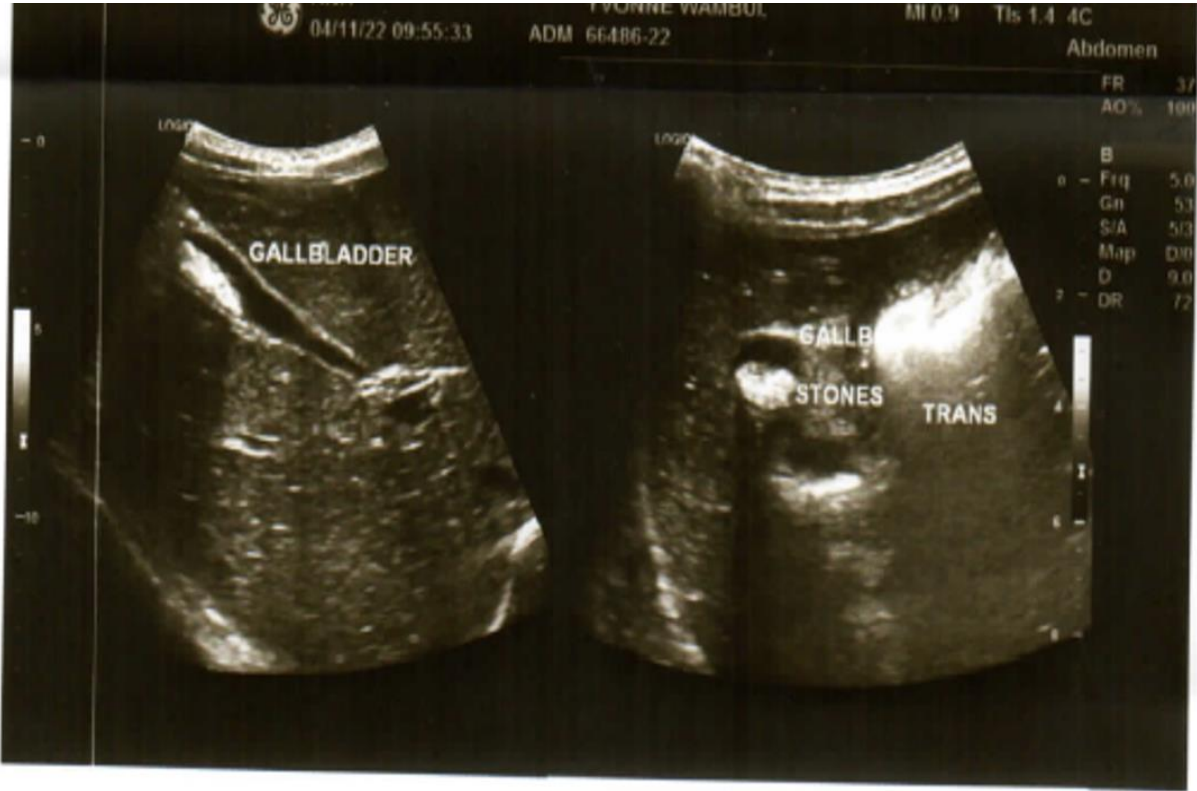

figure1: grey scale image of the gall bladder showing a stone with posterior shadowing.

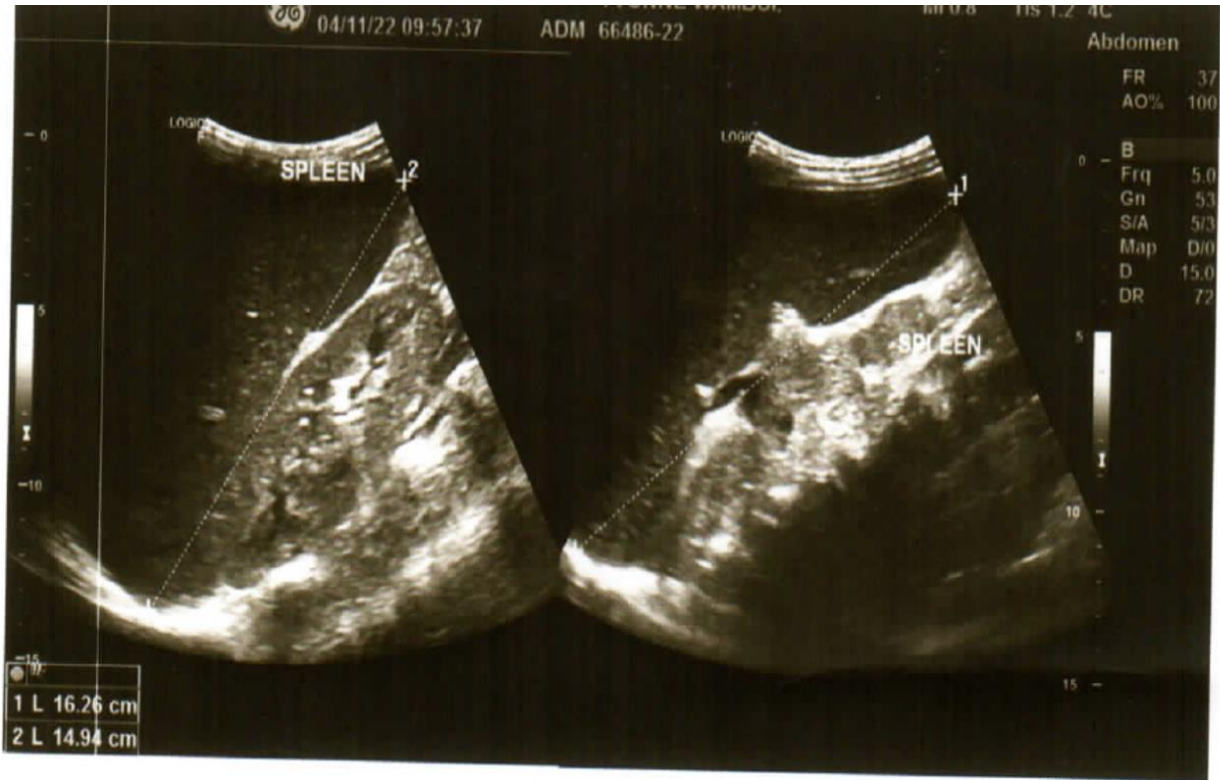

Figure2: grey scale image of the splee showing enlarged spleen.

DISCUSSION

Sickle cell disease is a chronic disorder with multisystem complications. Sickle cell disease is an inherited blood disorder usually diagnosed at birth, most people with the disease begin to show symptoms by 4 months of age or shortly thereafter. The case was diagnosed with sickle cell disease when she was 6 months old.

Gall bladder stones (GBS), also known as choledocholithiasis, are a common complication of Sickle cell disease. The sickle red blood cells have a shorter life span than the normal ones, chronic hemolysis leads to continuous production of bilirubin and increased bilirubin excretion cause bilirubin to build up in the gallbladder.⁴

There are multiple other risk factors for developing gall stones like Obesity, excess estrogen from pregnancy, hormone replacement therapy, or birth control pills, being women, drugs that lower cholesterol in the blood can actually increase the amount of cholesterol secreted in bile, which, in turn, increases the risk of gallstones. People with diabetes generally have high levels of fatty acids, called triglycerides, which increase the risk for gallstones. Fasting decreases gallbladder movement, which causes the bile to become overconcentrated with cholesterol.

Most patients with gallstones (choledocholithiasis) experience no symptoms. Their gallstones are often discovered incidentally during imaging tests for unrelated or unexplained abdominal symptoms but if a gallstone lodges in a duct and causes a blockage, the resulting signs and symptoms may include sudden and rapidly intensifying pain in the upper right portion of the abdomen, sudden and rapidly intensifying pain in the center of the abdomen, back pain between the shoulder blades, pain in the right shoulder, nausea or vomiting.⁵

Gall stones should be treated to prevent their long-term complications, treatments are surgical which is removal of the gall bladder and non-surgical which is the use of medications for symptomatic treatment, if

left untreated it might lead to life threatening conditions such as cholestasis, pancreatitis and sepsis.⁶

CONCLUSION

Ultrasound is the most common test performed to evaluate gallbladder abnormalities, It provides valuable information about gallstones, such as location, size and effect on organ function.

Ultrasound produces images of the gallbladder and bile ducts. It shows if there are signs of inflammation or indications that there is blockage of bile flow.

patients with sickle cell disease should be monitored on a regular basis by undergoing regular screening tests to prevent the complication of chronic hemolysis.

REFERENCE

1. Sun H, Tang H, Jiang S, Zeng L, Chen EQ, Zhou TY, Wang YJ. Gender and metabolic differences of gallstone diseases. *World J Gastroenterol.* 2009.
2. Di Ciaula A, Portincasa P. Recent advances in understanding and managing cholesterol gallstones.
3. Peng WK, Sheikh Z, Paterson-Brown S, Nixon SJ. Role of liver function tests in predicting common bile duct stones in acute calculous cholecystitis. *Br J Surg.* 2005;92:1241–1247.
4. Gumiero, A.P., Bellomo-Brandão, M.A. and Costa-Pinto, E.A. (2008) Gallstones in Children with Sickle Cell Disease Followed up at a Brazilian Hematology Center.
5. Lee JY, Keane MG, Pereira S. Diagnosis and treatment of gallstone disease. *Practitioner* 2015.
6. Cohen ME, Slezak L, Wells CK, Andersen DK, Topazian M. Prediction of bile duct stones and complications in gallstone pancreatitis using early laboratory trends. *Am J Gastroenterol.* 2001;96:3305–3311.

CASE 4: BREAST ABSCESS

ABSTRACT

A breast abscess is a localized collection of purulent material within the breast. Breast abscesses most commonly affect women aged between 18 and 50 years. In women of reproductive age these are predominantly lactational but non-lactational abscesses are also seen in premenopausal older women.

Breast abscess in lactating mothers is a common entity, but however, it has been noticed that the number of non-lactating women presenting with breast abscesses is rising.

Breast abscess is a complex disease and presents difficulties in diagnosis and treatment due to various confounding factors as epidemiological, etiological, and clinical aspects.

INTRODUCTION

Breast infections are divided into lactational and non-lactational, or puerperal and nonpuerperal categories. They can be associated with superficial skin or an underlying lesion.

Breast abscesses are more common in lactating women but do occur in nonlactating women as well. It is important to rule out more serious pathology like breast cancer when a non-lactational patient presents with signs and symptoms of breast abscess. The vast majority of these infections occur in females, but they can occur in males as well.

Diagnosis and treatment for breast abscesses are not difficult, but there is a high rate of recurrence.^{1,2,3}

Lactational breast abscesses are most often caused by *Staphylococcus aureus* and *Streptococcal* species. Methicillin-resistant *S. aureus* is becoming increasingly common.

Typically, non-lactational breast abscesses are a result of a mixed flora with *S. aureus*, *Streptococcus*, and anaerobic bacteria.

Nonlactating breast abscesses have a wider age range, with a peak incidence in the fourth decade of life. There is a strong association between diabetes and smoking with non-lactational breast abscesses.⁴

CASE REPORT

54 years old female presented with gradual onset pain in the left breast.

The pain was moderate in severity, that is localized to the left breast. It was dull in character that has no radiation, relieving or aggravating factor.

It was associated with redness and tenderness. the overall duration of those symptoms were three days where she attended to the clinic for the above complaint.

on 20/07/2022 she was sent for a bilateral breast mammogram which showed no dominant masses or suspect calcifications in the right breast.

The left breast showed diffusely increased parenchymal density, increased skin thickening, small ill-defined nodular masses, and microcalcifications with unremarkable axilla.

The mammogram conclusion was unremarkable bilateral breast and recommended ultrasound for correlation.

On ultrasound, Both breasts were scanned systematically quadrant by quadrant using linear probe, the right breast showed multifocal echogenic lesions with acoustic shadowing suggestive of calcifications, largest one measuring 0.5 x 0.4cm.

There was a right upper quadrant (10 o'clock) small mass with posterior shadowing measuring 1.1 x 1.0cm, the right breast parenchyma was well outlined and no right axillary nodes seen.

The left breast showed subcutaneous edema and diffuse retro areolar thickening and no obvious masses seen.

Normal vascularity is noted within the thickened tissues.

No (suspected) lymph nodes seen.

An ultrasound diagnosis was made, features suggestive of inflammatory breast malignancy (BIRADS 4). And biopsy correlation was recommended.

The patient was sent for biopsy for further assessment, the image-guided biopsy aspirated 100mls of pus in the left breast, and the pus was sent to the lab for microscopic culture and sensitivity and for acid-fast bacillus.

After the labs for microscopic culture and sensitivity and for acid-fast bacillus came out, the culture showed staphylococcus aureus with negative acid-fast bacillus.

An incision and drainage were made on 08/08/2022, and around 150ml of pus with a foul smell was drained. Curettage was carried out to break loculations, wound packed with gauze and bactigras and a wound dress was made as needed.

She was given pain killers and anti-inflammatory such as KETESSE and BETAPYN, also she was given an antibiotic CLINDAMYCIN 600mg.

The patient has healed, reassured and started her work as a nurse 10 days later.

SONOGRAPHIC IMAGES

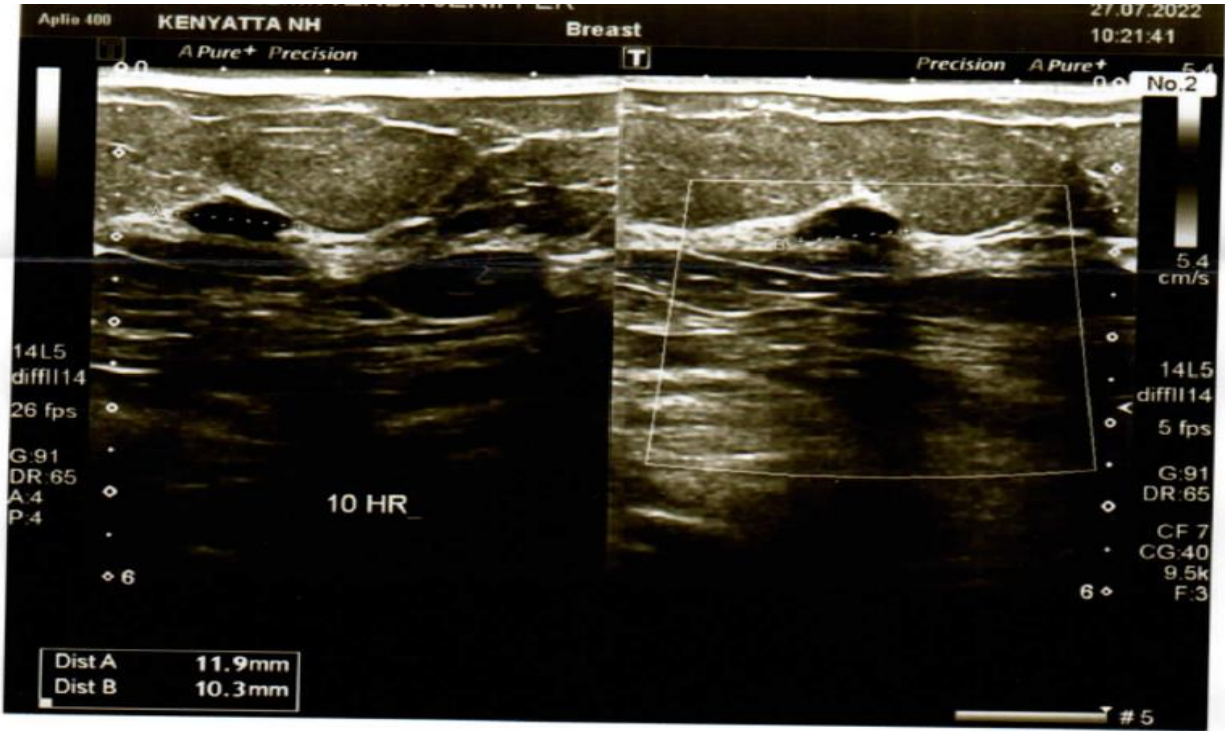


Figure 1: grey scale ultrasound scan showing right upper quadrant mass.

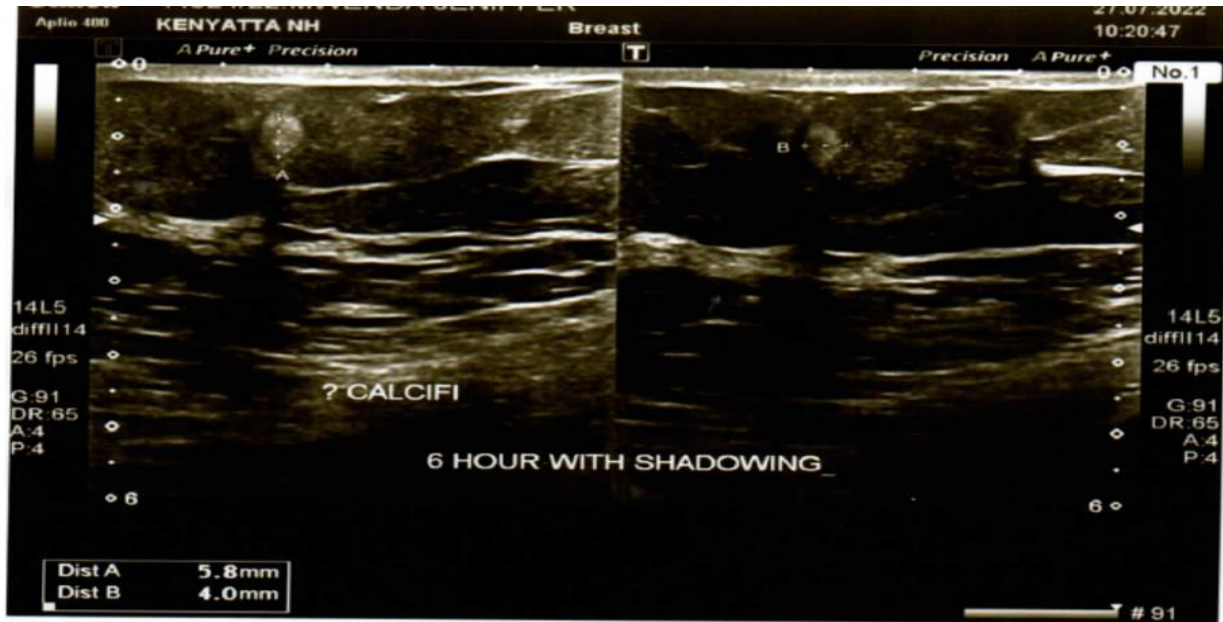


Figure 2: grey scale ultrasound scan of the right breast showing calcifications.

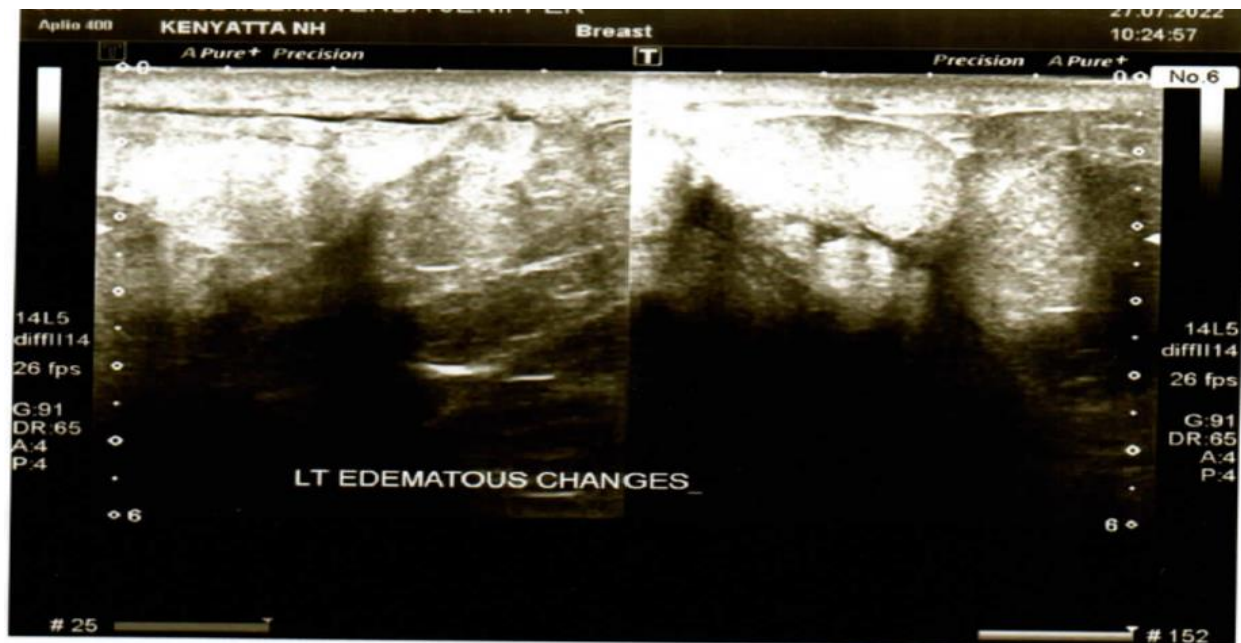


Figure 3: grey scale scan of the left breast indicating skin and subcutaneous edema.

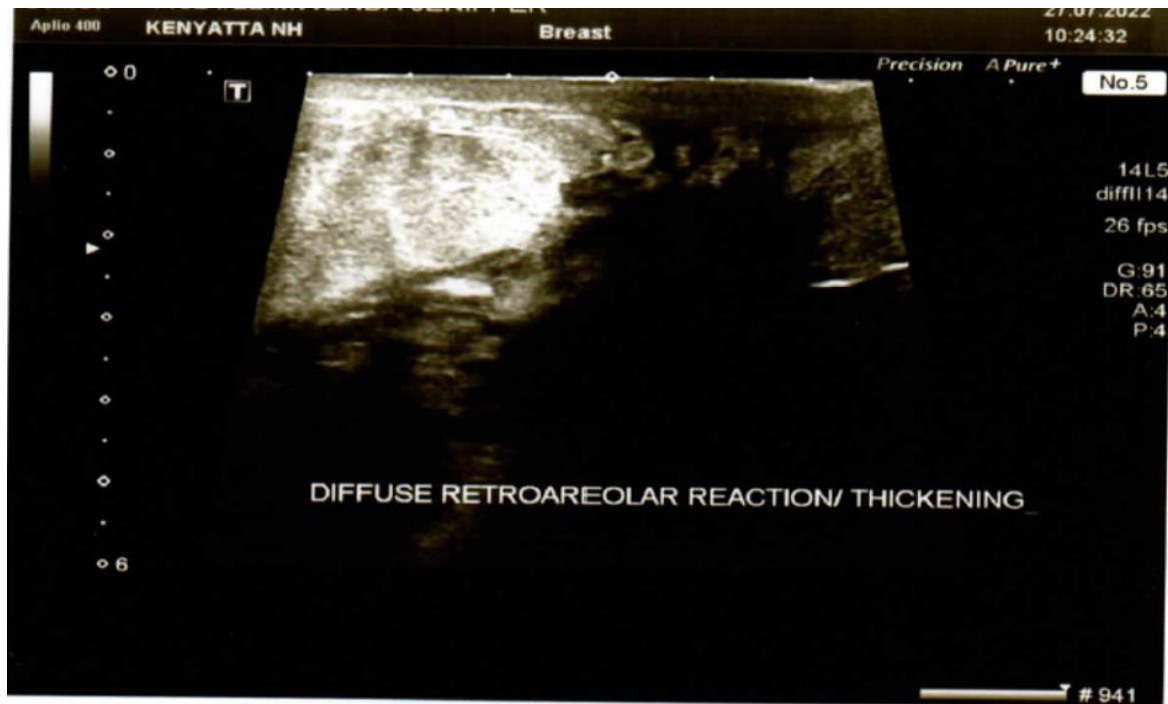

Figure 4: grey scale scan of the left breast showing retro areolar thickening.

DISCUSSION

Due to the delicate nature of the active breast tissue, prompt and appropriate management of breast infections is essential. Delay or inadequate management may lead to tissue destruction, chronic infections, periductal fistulas and breast deformities.⁵

Pyogenic infections are the commonest with a variety of causative bacteria. However, many other uncommon organisms have been reported. Infrequent nonlactating infections can be divided into those occurring centrally in the periareolar region and those affecting the peripheral breast tissue.⁶

On ultrasound scanning of the case, there was no any sonographic evidence showing pus collection though there were clinical signs of inflammation like redness, tenderness, and edema. The time gap between the scan and the biopsy was 11 days which is the time that the pus built up.

Inflammatory breast cancer is a devastating disease with an extremely high rate of morbidity and mortality. Differentiating this disease from acute mastitis may be difficult on initial diagnosis as they both have similar symptoms including Swelling (edema) of the skin of the breast on ultrasound, redness involving more than one-third of the breast, thickening of the skin of the breast, a retracted or inverted nipple, a breast that may be tender, painful or itchy and swelling of the lymph nodes under the arms.

Inflammatory breast cancer typically occurs in older women, while acute mastitis usually affects younger, lactating women. If a trial of antibiotics does not decrease the signs and symptoms in the inflamed breast, inflammatory breast cancer must be considered, especially in older, nonlactating women.

The similarity in symptoms was what made us reach an initial conclusion of inflammatory breast cancer as the case was old in age and nonlactating before it was correlated with the biopsy when mammogram gave undefined results (BIRADS 0).

CONCLUSION

Breast infection is common and if managed appropriately will usually resolve with antibiotics alone. Breast abscesses require minimally invasive aspiration in combination with antibiotics to give the most favorable outcome. If managed appropriately invasive Incision & Drainage is rarely required when managing an uncomplicated breast abscess. It is important that clinicians in primary and secondary care are aware of the current management pathways and make urgent referrals for any patient for which resolution does not rapidly occur with a single course of appropriate antibiotics. Delay in referral or appropriate management can have serious consequences on residual morbidity and cosmesis.

REFERENCES

1. Patani N, MacAskill F, Eshelby S, Omar A, Kaura A, Contractor K, Thiruchelvam P, Curtis S, Main J, Cunningham D, Hogben K, Al-Mufti R, Hadjiminias DJ, Leff DR. Best-practice care pathway for improving management of mastitis and breast abscess. *Br J Surg*. 2018.
2. Choices in Benign Breast Disease: An Initiative of the American Society of Breast Surgeons for the American Board of Internal Medicine Choosing Wisely® Campaign. *Ann Surg Oncol*. 2018.
3. Zhang Y, Zhou Y, Mao F, Guan J, Sun Q. Clinical characteristics, classification and surgical treatment of periductal mastitis. *J Thorac Dis*. 2018.
4. Leung SS. Breast pain in lactating mothers. *Hong Kong Med J*. 2016.
5. Efrat M, Mogilner JG, Iujtman M, Eldemberg D, Kunin J, Eldar S. mastitis--diagnosis and treatment. *Isr J Med Sci*. 1995.
6. Rizzo M, Gabram S, Staley C, Peng L, Frisch A, Jurado M, Umpierrez G. Management of breast abscesses in nonlactating women. *Am Surg*. 2010.

CASE 5: DECOMPENSATED CHRONIC LIVER DISEASE DUE TO ALCOHOL ABUSE

ABSTRACT

Decompensated liver disease is also known as decompensated cirrhosis. Cirrhosis is a chronic liver disease that's commonly the result of hepatitis or alcohol use disorder. Cirrhosis is the severe scarring of the liver seen at the terminal stages of chronic liver disease. When the liver is damaged, scar tissue is formed as it tries to repair itself.

Cirrhosis is divided into two categories:

- **Compensated:** When there are no symptoms of the disease, its considered to be compensated cirrhosis.
- **Decompensated:** When the cirrhosis has progressed to the point that the liver is having trouble functioning and symptoms of the disease appear, it is considered to be decompensated cirrhosis.

INTRODUCTON

Decompensated cirrhosis is a frequent reason for admission to the acute medical unit, and such patients typically have complex medical needs that can lead to a prolonged hospital stay and a significant risk of an in-hospital death (10–20%).

It is therefore vital that these patients receive the appropriate investigations and treatment as early as possible in their patient journey.¹

Decompensated cirrhosis is defined as an acute deterioration in liver function in a patient with cirrhosis and is characterized by jaundice, ascites, hepatic encephalopathy, hepatorenal syndrome or variceal hemorrhage.

Common precipitants of hepatic decompensation include infections, gastrointestinal (GI) bleeding, high alcohol intake / alcohol-related hepatitis or drug-induced liver injury although no specific cause is found in approximately 50% of cases.²

It is important to try to determine the underlying cause of hepatic decompensation through a careful history, examination and investigations so appropriate treatment can be given.³

CASE REPORT

A 39-year-old male presented in the emergency unit on 24/08/2022 abdominal distension, cough and confusion.

The patient had moderately worsened abdominal distension that started on the flanks and progressed through the whole abdomen. The patient felt heavy walking and short of breath while lying. It was also associated with productive non-blood-stained cough and nausea.

The patient is a known case of Diabetes mellitus and known chronic liver disease secondary to alcohol abuse.

The patient was admitted before in the hospital for the same condition and treated.

The patient was sent for lab investigations and the results are as below: lab works: WBC, 9.62, HB 8.2, MCV 95, Platelet count 135, INR 3.12, PT 36.7, APTT 41.8, NA⁺ 129, AST 100, ALT 98.

The patient was sent to the ultrasound department for abdominal ultrasound to assess the status of his liver.

The liver was normal in size with heterogeneous echotexture and shrunken surface. It spans 13.9cm and no focal lesions seen. Hepatic vessels and bile ducts were normal and not dilated. There was marked amount of intra peritoneal fluid.

The gall bladder was minimally distended, acalculus and thin walled, the pancreas, spleen and both kidneys were normal in size, shape position and echo pattern.

There was no visceral node enlargement or abdominal mass lesion seen.

Impression:

- Hepatic parenchymal disease.
- Ascites.

The patient was admitted to ward 6B and started giving ALBUMIN, HYPOTONIC SALINE 3% 100ml, CEFTRIAXONE 1g, VITAMIN K 10mg, PROPANALOL 40mg, METFORMIN 500mg, MIXTRURD, RIFAXIMIN 550mg, ALDACTONE 100mg, LASIX 40mg.

After an intensive symptomatic treatment for 4 days, the patient was reassured and discharged with clinic follow-up every three months.

SONOGRAPHIC IMAGES

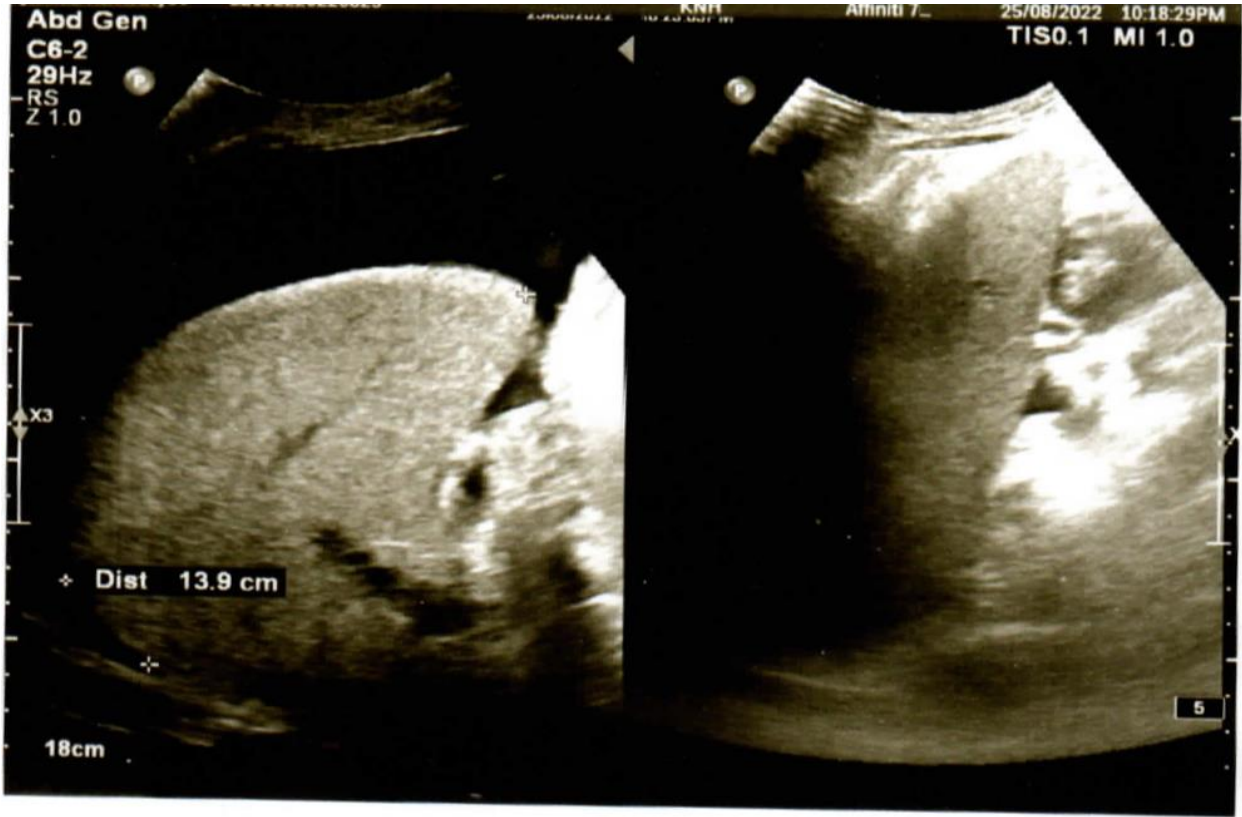

Figure 1: grey scale scan of the right and left lobe of the liver with marked ascites.

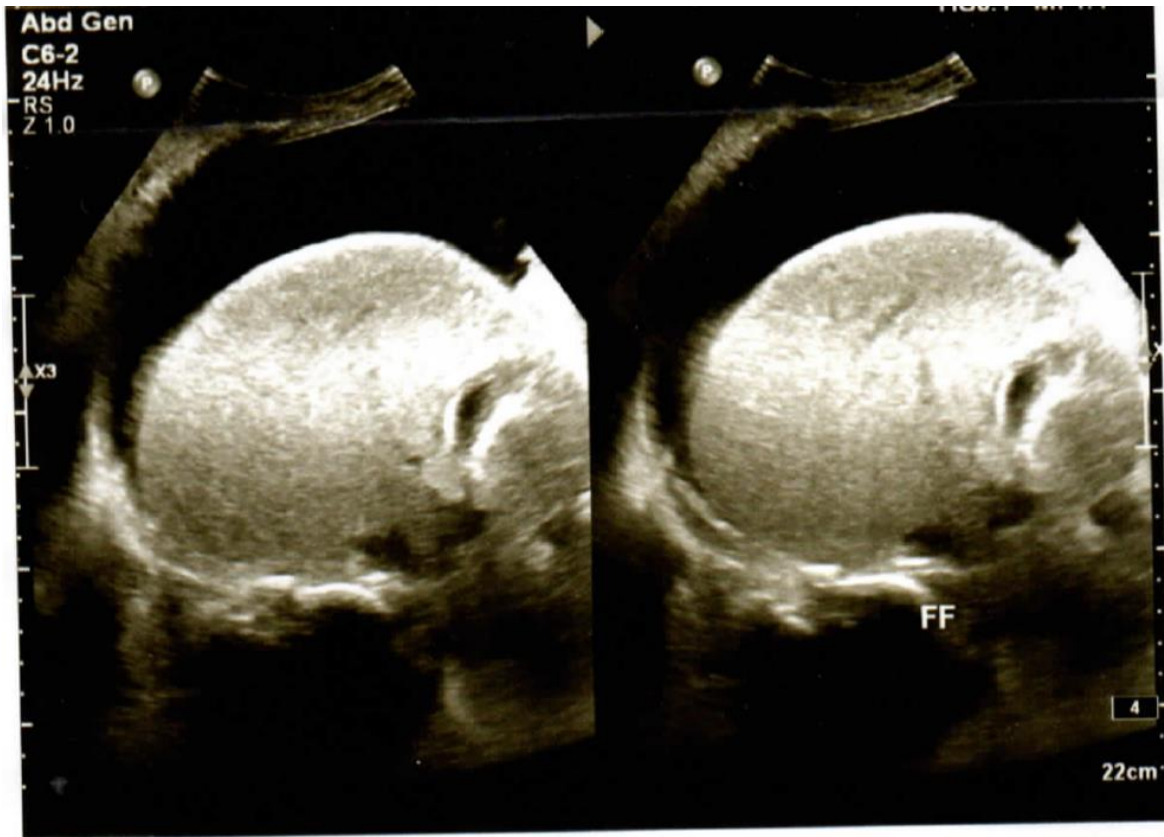


Figure 2: grey scale scan of the liver showing shrunken liver.

DISCUSSION

Excessive alcohol consumption is a global healthcare problem. The liver sustains the greatest degree of tissue injury by heavy drinking because it is the primary site of ethanol metabolism.

Chronic and excessive alcohol consumption produces a wide spectrum of hepatic lesions, the most characteristic of which are steatosis, hepatitis, and fibrosis/cirrhosis.⁴

Steatosis (fat build up in the liver) is the earliest response to heavy drinking and is characterized by the deposition of fat in hepatocytes. Steatosis can progress to steatohepatitis, which is a more severe, inflammatory type of liver injury.

This stage of liver disease can lead to the development of fibrosis, during which there is excessive deposition of extracellular matrix proteins. The fibrotic response begins with active pericellular fibrosis, which may progress to cirrhosis, characterized by excessive liver scarring, vascular alterations, and eventual liver failure.⁵

Among problem drinkers, about 35 percent develop the advanced liver disease because a number of disease modifiers exacerbate, slow, or prevent alcoholic liver disease progression.⁶

There are still no FDA-approved pharmacological or nutritional therapies for treating patients with alcoholic liver disease. The case has received symptomatic treatment which is the treatment of choice so far. Cessation of drinking (i.e., abstinence) is an integral part of therapy. Liver transplantation remains the life-saving strategy for patients with end-stage alcoholic liver disease.⁷

CONCLUSION

long-term intake of more than 30g of absolute alcohol per day increases the risk of alcoholic liver disease; liver disease is nearly certain in long-term consumption in excess of 80g of absolute alcohol per day.

Alcoholic liver disease may take the chronic form (steatosis, steatohepatitis, fibrosis, cirrhosis) or that of acute hepatitis. Steatosis is fully reversible, which does not apply to the other conditions; cirrhosis is associated with a markedly shortened life expectancy.

The results of laboratory testing in alcoholic liver disease usually include: increased GGT, AST/ALT ratio greater than 2 and increased MCV.

Sonography will reveal enlarged liver and signs of steatosis. Absolute abstinence is an essential therapeutic precaution; no hepatoprotective treatment has been shown to improve the course of the disease.

Likewise, there is no medicine that would demonstrably “protect” from the effects of alcohol.

The clinical course of severe alcoholic hepatitis could be improved with corticoids, enteral nutrition and pentoxifylline, although more clinical data are necessary to standardize or combine this treatment.

REFERENCES

1. Comprehensive text book of medical physiology volume 1.
2. Sherlock S, Dooley J. Acute-on-chronic liver failure is a distinct syndrome that develops in patients with acute decompensation of cirrhosis. *Gastroenterology*. 2013.
3. Angeli P, Gines P, Wong F, et al. Diagnosis and management of acute kidney injury in patients with cirrhosis: revised consensus recommendations of the International Club of Ascites. *J Hepatol*. 2015.
4. Addolorato G, Capristo E, Greco AV, et al. Energy expenditure, substrate oxidation, and body composition in subjects with chronic alcoholism: New findings from metabolic assessment. *Alcoholism: Clinical and Experimental Research*. 1997
5. Addolorato G, Capristo E, Greco AV, et al. Influence of chronic alcohol abuse on body weight and energy metabolism: Is excess ethanol consumption a risk factor for obesity or malnutrition? *Journal of Internal Medicine*. 1998.
6. Ambade A, Mandrekar P. Oxidative stress and inflammation: Essential partners in alcoholic liver disease. *International Journal of Hepatology*. 2012.
7. Maddrey WC, Boitnott JK, Bedine MS, Weber FL, Mezey E, White RI. Corticosteroid therapy of alcoholic hepatitis. *Gastroenterology*. 1978.