

TITLE

**VOCAL CORD PARALYSIS; A
COMPLICATION OF THYROID SURGERY.**

**A STUDY AT THE KENYATTA
NATIONAL HOSPITAL, KENYA.**

**By DR. GEORGE MWAVISWA MBOGHO
MBCHB 1991 (NRB).**

**THIS DISSERTATION IS SUBMITTED IN PART
FULFILLMENT FOR THE DEGREE OF MASTER
OF MEDICINE IN EAR, NOSE AND THROAT –
HEAD AND NECK SURGERY (E.N.T – H&N) IN
THE UNIVERSITY OF NAIROBI 2001.**

**MEDICAL LIBRARY
UNIVERSITY OF NAIROBI**




DECLARATION

This is my original work and has not been presented for a degree in any other university.

DR. GEORGE MWAVISWA MBOGHO (Candidate)

SIGNATURE: 
30/1/2001.

This Dissertation was supervised and has been submitted for examination with my approval.

SIGNATURE: 

**DR. PETER MUGWE
(Supervisor)
SENIOR LECTURER UNIVERSITY OF NAIROBI
AND E.N.T - H & N SURGEON.**

DEDICATION

This work is dedicated to my wife Mrs. Betty Mkang'ombe, my children Miss Violet Zighe, Miss Deborah Mkamburi and Mr James Mwambanga for their patience and support throughout the study.

ACKNOWLEDGEMENTS

I would like to thank my supervisors Dr P. Mugwe, for continued guidance and assistance and also Mr. O. Oburra and Dr. M. Macharia for their contributions towards the completion of this study.

I would also like to thank the staff of the records department for their kind co-operation.

Finally, special thanks to Miss Esther Mbiro and Mrs Mary Mwawaza for kindly accepting to offer secretarial services.

CONTENTS

1. TITLE	(i)
2. DECLARATION	(ii)
3. DEDICATION	(iii)
4. ACKNOWLEDGEMENT	(iv)
5. CONTENTS	(v)
6. GLOSSARY	(vi)
7. SUMMARY	1
8. INTRODUCTION	2
9. APPLIED ANATOMY OF THE THYROID GLAND AND ITS RELATION TO THE LARYNGEAL NERVES.	3
10. LITERATURE REVIEW	6
11. JUSTIFICATION OF THE STUDY	14
12. AIMS AND OBJECTIVES	15
13. MATERIALS AND METHODS	16
14. RESULTS	18
15. DISCUSSION	29
16. CONCLUSIONS	35
17. PROFORMA (APPENDIX 1)	37
18. BIBLIOGRAPHY	39

GLOSSARY

1. **KNH** **Kenyatta National Hospital**
2. **E.N.T - H & N** **Ear, Nose and Throat - Head and Neck**
3. **CO₂** **Carbondioxide**
4. **HDU** **High Dependency Unit**
5. **D/L** **Direct Laryngoscopy**
6. **U.S.A.** **United States of America**
7. **I/L** **Indirect Laryngoscopy**

SUMMARY

This is a retrospective descriptive study on vocal cord paralysis following thyroidectomy at the Ear, Nose and Throat – Head and Neck (E.N.T. – H&N) surgical unit of Kenyatta National Hospital (KNH). A total of 454 patients were included in this study. Out of this 28 (6.2%) had developed vocal cord paralysis. In this study therefore the crude incidence of vocal cord paralysis was found to be 6.2%. The left vocal cord was found paralyzed in more than 50% of the cases. It was also found that patients with repeat thyroidectomies, cancer of the thyroid gland, and total thyroidectomies had a higher risk of developing vocal cord paralysis. Patients who had vocal cord paralysis with upper airway obstruction were done arytenoidectomy and lateralisation of vocal cords to improve the airway. One patient had a tracheostomy and a metallic tracheostomy tube with speaking valve fitted with satisfactory phonation, while eight patients are still being followed up in Ear, Nose and Throat, Head and Neck clinic at Kenyatta National Hospital for possible lateralisation of vocal cords.

INTRODUCTION

Thyroidectomy is one of the oldest methods of treatment provided to various thyroid diseases. Like any other operation, it has several associated surgical complications. Research findings show that in our set up, hoarseness of voice, haematoma formation, and tetany are amongst the important complications as noted in a study by Alkhama in 1987⁽⁴³⁾. According to the study laryngeal oedema, laryngomalacia and vocal cord paralysis were found to be the possible causes, while thyroid diseases and thyroid surgery contributed to 20 – 30% in the aetiology of vocal cord paralysis⁽⁵⁾. It was on the above basis that this study was undertaken to determine the incidence of vocal cord paralysis amongst thyroidectomy patients and their management at the Kenyatta National Hospital.

**APPLIED ANATOMY OF THE THYROID GLAND
AND ITS RELATION TO THE LARYNGEAL
NERVES.**

The thyroid gland is composed of two lateral lobes joined in the midline by an isthmus, and a pyramidal lobe, which represents the thyroglossal duct ⁽¹⁾. Each lobe extends from the middle of the thyroid cartilage to the 6th tracheal ring ⁽²⁾. It is related anteriorly to the strap muscles, posterolaterally to the neurovascular bundle. The superior pole of each lobe is related to the larynx and superior laryngeal nerve, while the inferior pole is related to the trachea and recurrent laryngeal nerve. The average weight of the gland is 20 grams.

The thyroid gland is covered by a fibroareolar capsule which send septa into the parenchyma of the thyroid gland splitting it into smaller units. The functional unit of the thyroid gland is the acinus^(1,2). It is composed of cuboidal epithelium surrounding a colloid which is the storage form of thyroid hormones. Between the acinus there are found parafollicular cells, which secrete calcitonin important in calcium metabolism

(2.3)

The thyroid gland is very vascular and is supplied by a pair of both superior and inferior thyroid arteries. The thyroidea ima artery and accessory arteries, also supply the oesophagus and trachea as well. The superior

thyroid artery is the first branch of the external carotid artery. It descends alongside the external branch of the superior laryngeal nerve to reach the superior pole of the thyroid gland. The external branch is a little higher and medial to the artery. Ligation of this vessel during thyroidectomy should be done lower and closer to the superior pole of the thyroid gland to avoid iatrogenic injury to this nerve^(1,2,3). The chances of injury to this nerve are further reduced by dividing the strap muscles to attain good exposure of the superior laryngeal nerve. This may result to loss of production of high pitched sounds important to singers and some professional voice users, since it supplies the cricothyroid muscle which lengthens and tenses the vocal cords.

The inferior thyroid artery arises from the thyro-cervical trunk. It ascends up in the neck, branches and enters the posterior border of the thyroid gland to which it is finally distributed. As the artery approaches the thyroid gland it is crossed anteriorly, posteriorly or in between its branches by the recurrent laryngeal nerve ^(1,5,9,40). Ligation of this artery should be delayed until the nerve has been identified. If ligated, it should be as lateral as possible. The right recurrent laryngeal nerve arises from the main trunk of the vagus nerve at the anterior surface of the right subclavian artery lateral to the origin of the common carotid artery. It hooks round the artery and ascends superiorly and medially to enter the

tracheosophageal groove. Because of the high origin, it lies more lateral than the left and is therefore prone to iatrogenic trauma because it is frequently mistaken to lie in the tracheosophageal groove^(5,7,9.). An abnormality in the course of the right recurrent laryngeal nerve may arise when the right subclavian artery is derived from the caudal portion of the aortic arch. In such instances the right recurrent laryngeal nerve branches directly to the larynx high up in the neck since there is no artery to displace it inferiorly. A fact that predisposes the nerve to iatrogenic injury. This abnormality is frequent in mongoloids⁽⁸⁾. The left recurrent laryngeal nerve has a similar course except that it is carried deep into the mediastinum, goes round the aortic arch and ascends in the tracheosophageal groove hence less vulnerable to iatrogenic injury when compared to the contralateral nerve.

LITERATURE REVIEW

The aetiology of vocal cord paralysis may be categorized into central and peripheral causes. Central causes constitute about 10%. They account for a small proportion of vocal cord paralysis. On the other hand peripheral causes are by far the commonest and account for over 90%.

According to study findings, Ramadan et-al (1998) carried out a study of 98 patients in the department of otolaryngology, West Virginia University Hospital U.S.A. In this study it was found that 70% of patients had their left vocal cord involved. While 30% had their right cord paralysed. It was found that 30% of the patients had physical trauma, neoplasms 32%, surgical trauma 30%, central causes 8%, infections 3% and idiopathic 16%.

Stell and Maran (1978) ⁽⁵⁾, came up with similar findings. In their study neoplastic causes accounted for 25%, surgical trauma 20%, inflammatory 13%, non surgical 11%, central or neurological causes 7%, miscellaneous 11% and 13% were idiopathic. It is therefore evident that surgical trauma accounts for 25% – 30% of vocal cord paralysis. This being a retrospective review these figures are by no means comprehensive because other medical causes like cerebrovascular accidents, myaesthesia gravis, Guillian-Barre syndrome, serum electrolyte

imbalance and lateral sclerosis would not appear in such a series.

Vocal cord paralysis has also been caused by thyroidectomy. But improved surgical techniques and meticulous dissection and identification of the recurrent laryngeal nerves has greatly decreased this incidence⁽⁹⁾.

Available literature show the incidence to range from 1% – 5% David D et al (1980) ⁽⁴⁵⁾. In various studies done in North America Gould et al (1974) found an incidence of 0.2% ⁽²⁾. In another study done by Colcock and King (1974) evaluating 1,246 thyroid operations noted one (1) patient (0.08%) with bilateral recurrent laryngeal nerve paralysis. Thompson and Harness (1974) reported an incidence of 4.8% ⁽²⁾.

Other studies done elsewhere in the world show varying figures. Kasemsuwan et al (1997) in a retrospective study found the incidence to be 2.38%. In both permanent and temporary paralysis of recurrent laryngeal nerve, the incidence was related to histopathological findings of malignancy.⁽⁴⁴⁾ Repeat operations has also been associated with recurrent laryngeal nerve palsy. This may be due to interference with the anatomy during the first operation, or the nerve may be incorporated into the formation of scar tissue later on⁽⁴¹⁾

Position of the paralysed cords

Several theories trying to explain the positions attained by the paralyzed cords have been advanced by various authors. According to Semon (1881), observed that in recurrent laryngeal nerve palsy, the vocal cords finally rested in the median position. He observed that the nerve fibres innervating the adductor muscles are more resistant to pressure injury than those innervating the abductors. This could be attributed to phylogenetic development of the larynx, where adduction function being more primitive was more resistant to pressure injury. This theory does not have any empirical evidence partly due to the difficulty of designing such an experiment.^(5,9,10)

A second theory by King and Gregg (1948) explained the positions of the vocal cords in post thyroidectomy patients as being due to injury to the adductor or abductor branches of the recurrent laryngeal nerve. They ascertained that the posterior division of the recurrent laryngeal nerve supplied innervation to the posterior cricoarytenoid and interarytenoidus muscles and the anterior branch to other intrinsic muscles. Hence in selective injury of any one of the branches will result to paralysis of a particular muscle group i.e. abductor in case of injury to the posterior branch. This

theory has been proven wrong since the posterior branch is chiefly sensory^(9,10,11,12,40).

Wagner (1890) and Grossman (1897) explained the median and paramedian positions of the vocal cords in recurrent laryngeal nerve palsy as a result of continued function of the cricothyroid muscle. This muscle is innervated by the external branch of the superior laryngeal nerve. It tenses the vocal cords and adducts the arytenoids. This theory has been proven experimentally correct and generally accepted^(9,10).

In addition to these theories, other factors may be playing part in determination of the position attained by the vocal cords. These include fibrosis and ankylosis of the cricoarytenoid joint, atrophy of the paralysed muscles and persistence of tonus associated with autonomic nerve supply⁽⁹⁾.

Presentation

The presentation varies from one individual to another depending on the type of paralysis in question i.e. whether unilateral or bilateral, adductor or abductor and the degree of compensation attained by the unparalysed cord.

Unilateral paralysis in median and paramedian position

Symptoms are minimal, mild hoarseness may prevail with impairment of high-pitched sounds as in singing. Hoarseness of voice, and stridor may occur on extreme exertion.

In case compensation occurs there is improved quality of voice produced, and the patient may not complain of any voice change. On laryngoscopy the paralysed cord appears atrophic and at a lower level than the normal cord^(5,9). Its inability to move is the basis of the diagnosis. In some instances the pitch may be abnormally high because of attempted compensation by the elliptical glottis (Compensatory falsetto)⁽²⁵⁾.

Bilateral paralysis in median and paramedian position

This is most frequent due to damage on both recurrent laryngeal nerves as at thyroidectomy⁽¹⁰⁾. Other treatable causes are rare. The cords come to lie in the paramedian position. The voice might be good but the degree of dyspnoea and stridor is variable. Dyspnoea may not be significant at rest but become marked on exertion. Paralysis in the median position can present with marked dyspnoea and stridor at rest. The patient tends to limit activities that worsen the stridor. Any upper

respiratory tract infection might precipitate complete laryngeal obstruction. (9)

Paralysis in intermediate position and abduction

This is seen in patients with paralysis of both the superior and recurrent laryngeal nerves. They present with weak husky voice, hoarseness of voice, short phonation time due to air leak through an incompetent glottis.^(5,9,10) Thyroidectomy can predispose both nerves to such and injury. Compensation can occur with improvement of laryngeal functions. Paralysis in abduction is extremely rare, it occurs in diffuse cortical lesions. It is spastic in nature. Aspiration pneumonia is a life threatening complication due to loss of cough reflex mediated through the superior Laryngeal nerve^(9,19,21,37).

Surgical treatment of vocal cord paralysis

Failure of recovery of the paralysed cords with persistence of symptoms will necessitate surgical intervention. Timing of surgical intervention is variable and the patient may be observed for three (3) to six (6) months or more to allow for spontaneous compensatory mechanisms to occur.^(9,44)

Adductor paralysis

Surgical intervention is indicated to improve the voice and prevent aspiration of foodstuffs and upper

gastrointestinal secretions. Intracordal injections by telfon paste, dermograf fat injections and implantation of autologus cartilage and fascia have been used^(9,32). The intracordal telfon paste injections are performed via direct or indirect laryngoscopy^(6,26), as well as via transcutenous under laryngovideoscopy. Use of laryngovideostroboscopy monitor during intracordal telfon injections has further simplified the procedure and also made it time and cost effective. This new technique also allows the surgeon to access glottic movement and amount of telfon paste injected facilitates the extent of medialization achieved.

However telfon paste can initiate tissue reaction with formation of injection granuloma in some patients, since it is a foreign substance. To overcome this complication dermograf fat injection has been introduced ⁽²⁹⁾. This has received acceptance worldwide and has replaced telfon paste injections. Dermograf fat has less tissue reaction and is readily available ⁽²⁹⁾. In various studies conducted using this, the average survival of the implanted fat is about 1 year.⁽³⁰⁾ Repeat injections are recommended.

Medialization can be achieved by cartilage implantation. The autologus cartilage is harvested from ribs or thyroid alae. It is implanted between the thyroid alae and the

perichondrium of the medial surface of the thyroid cartilage at the level of the vocal cords^(9,31).

A combination of surgical medialization and nerve muscle pedicle reinnervation of the larynx has been tried in

some centres with good success.^(33,36) (Turker H.M ; U.S.A, (1998) ⁽³³⁾, Zheng et al; China (1996) ⁽³⁶⁾. The nerve used is ansa hypoglossi with omohyoid muscle pedicle.

Abductor paralysis

Unilateral abductor paralysis does not require surgical intervention, but speech therapy. ⁽¹⁰⁾ On the other hand bilateral paralysis require surgical intervention to improve the airway. Arytenoidectomy and endoscopic lateralisation of the vocal cords though old is the main method still practiced. The procedure improves the airway but with deterioration of voice. The current treatment of choice in many centres worldwide is Carbon dioxide (CO₂) laser arytenoidectomy^(38,39). This attains a good airway with reasonable voice production as compared to arytenoidectomy and lateralisation of the vocal cords. "

JUSTIFICATION OF THE STUDY

Vocal cord paralysis is a debilitating condition. It does not only interfere with voice production, but also the sphincteric function of the larynx. Its aetiology is wide and varied with the incidence from thyroid surgery of between 1-5%⁽⁴⁵⁾.

Depending on the type of paralysis in question the patient may present with upper airway obstruction in cases of abductor paralysis or with life threatening aspiration pneumonia in adductor paralysis. Regardless of the aetiology, all these patients need treatment to improve their quality of life.

This study therefore hopes to provide to surgeons baseline information to the contribution thyroid surgery has to the development of vocal cord paralysis. The study is the first of its kind in Kenyatta National Hospital. The findings will help in formulating an appropriate management protocol.

AIMS AND OBJECTIVES

Main aims

This study is aimed at determining the incidence of recurrent laryngeal nerve palsy amongst patients who underwent thyroidectomy, its presentation and management at the Kenyatta National Hospital.

Objectives

- 1) To determine age and sex distribution.
- 2) To determine the clinical presentation of these Patients.
- 3) To determine if there is any relationship between the type of thyroidectomy performed and the occurrence of laryngeal nerve paralysis.
- 4) To determine if there is any relationship between Histopathological process and occurrence of laryngeal nerves paralysis.

INCLUSION AND EXCLUSION CRITERIA

Inclusion Criteria

All post-thyroidectomy patients with laryngoscopically verified vocal cord paralysis were included in the study.

Exclusion criteria

All patients who had vocal cord paralysis or pre-existing dysphonia before thyroidectomy as well as those who were operated outside Kenyatta National Hospital, were excluded from the study.

MATERIALS AND METHODS

This is retrospective study of all patients who developed vocal cord paralysis following thyroidectomy at the Kenyatta National Hospital during the period January 1989 to and including December 2000. Records from patients case notes, files and operating theatre registers compiled during the period under study were retrieved. Information pertaining to demographic data, type of thyroidectomy performed, and histopathological diagnosis was extracted. For patients who developed vocal cord paralysis, further information was searched pertaining to clinical presentation, laryngoscopy findings and management. A total of 454 cases were included in this study. This included all thyroidectomy patients case files available at the records department of the Kenyatta National Hospital during the study period. All this

information was entered into a proforma and analysed using tables and bar charts. (See appendix 1).

RESULTS

A total of 454 patients had thyroidectomy during the study period. Out of this, 416 (91.6%) were females and 38 (8.4%) were males. Thus the male to female ratio being 1:11. The age range was 4 to 83 years. Median age was 45 years. Twenty-eight patients (28) (6.2%) developed vocal cord paralysis.

Table 1 shows the age distribution of the 454 patients who underwent thyroidectomy, while Table 2 shows the age distribution of the patients who developed vocal cord paralysis.

Table 1: AGE DISTRIBUTION AMONG THYROIDECTOMY PATIENTS

AGE IN YEARS	FREQUENCY	PERCENTAGE
0 - 10	2	0.4
11 - 20	15	3.3
21 - 30	108	23.8
31 - 40	147	32.4
41 - 50	109	24.0
51 - 60	53	11.7
61 - 70	17	3.8
71 - 80	2	0.4
81 - 90	1	0.2

TABLE 2: AGE DISTRIBUTION OF PATIENTS WHO DEVELOPED VOCAL CORD PARALYSIS

AGE IN YEARS	FREQUENCY	PERCENTAGE
0-10	0	0
11-20	1	3.6
21-30	5	17.9
31-40	8	28.6
41-50	10	35.7
51-60	2	7.1
61-70	2	7.1
71-80	0	0
81-90	0	0

As the table shows patients who developed vocal cord paralysis were mainly female. Their ages ranged from 20 and 70 years. The peak age was located at the 5th decade (35.7%).

TYPE OF THYROIDECTOMY AND VOCAL CORD PARALYSIS

The relationship between the kind of thyroidectomy performed and the development of vocal cord paralysis is shown in Table 3 below:

Table 3: TYPE OF THYROIDECTOMY AND VOCAL CORD PARALYSIS DEVELOPED TABULATION COUNT

TYPE OF THYROIDECTOMY	VOCAL CORD PARALYSIS DEVELOPED		TOTAL	PERCENTAGE DEVELOPING PARALYSIS
	YES	NO		
Total Thyroidectomy	6	15	21	28.6
Sub Total Thyroidectomy	11	147	158	7.0
Lobectomy with or without Isthmoidectomy (Hemithyroidectomy)	10	221	231	4.3
Adenectomy	1	43	44	2.3

From the above table, patients who underwent total thyroidectomy carried a higher risk of developing vocal cord paralysis compared to the rest. Enucleation of a thyroid adenoma (adenectomy) carried the least risk of developing paralysis.

Repeat Operations

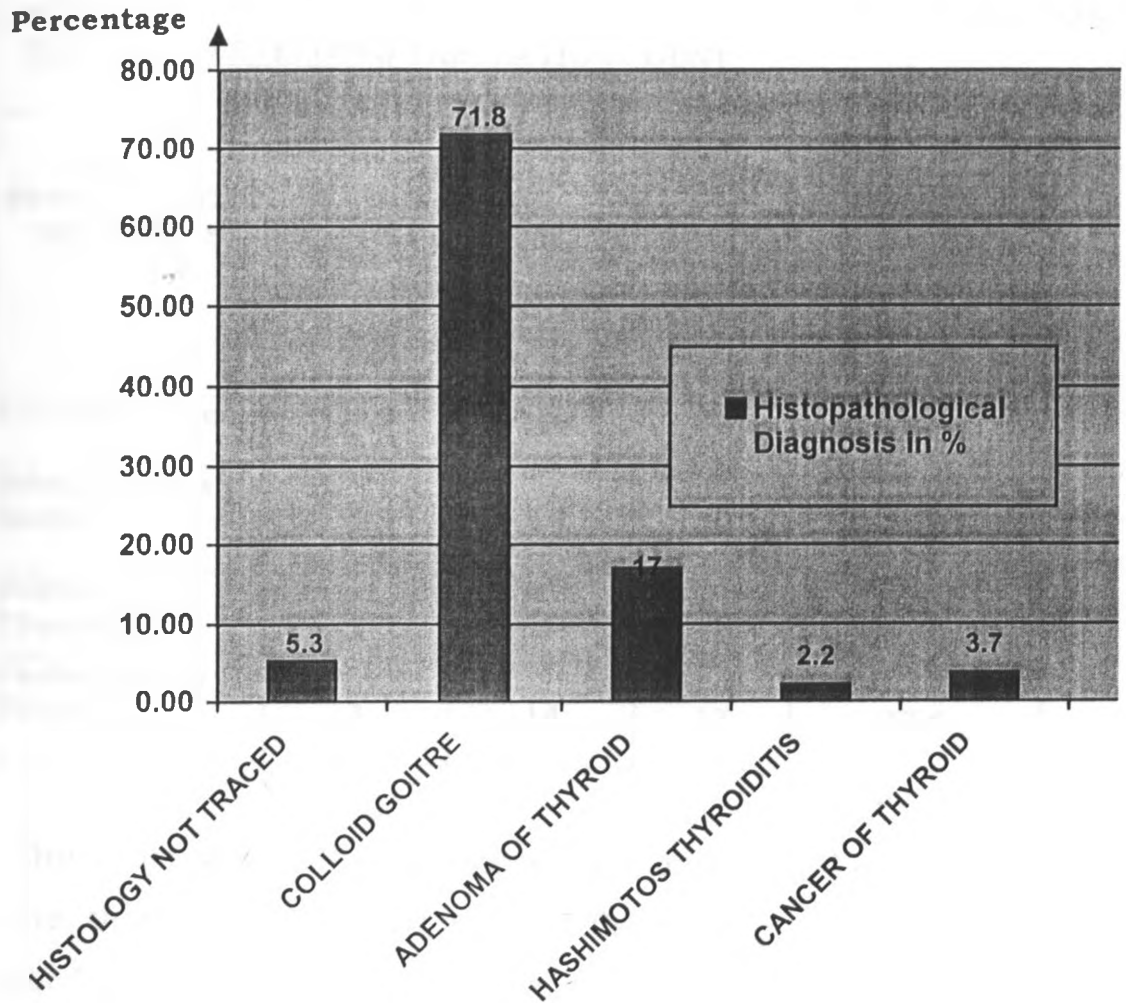
Twenty-two patients (22) underwent a second operation. This was mainly due to recurring colloid goitre (19 patients). Other histopathological types had one patient each. The relationship between repeat operations and development of vocal cord paralysis is shown in the table 4 below.

Table 4: RE-OPERATION VERSUS DEVELOPMENT OF VOCAL CORD PARALYSIS TABULATION COUNT.

	VOCAL CORD PARALYSIS DEVELOPED		TOTAL	PERCENTAGE DEVELOPING PARALYSIS
	YES	NO		
Operated once only	20	412	432	4.6
Operated for the 2 nd Time	8	14	22	36.4

Four hundred and thirty two (432) patients were operated once. Out of these 20 (4.6%) developed vocal cord paralysis. Twenty – two (22) of these underwent a second operation, with 8 (36.4%) of them having developed vocal cord paralysis. It was found that there was an increased risk of developing vocal cord paralysis in patients operated twice as compared to those operated once.

FIGURE 1 HISTOPATHOLOGICAL DIAGNOSIS



Out of the total three hundred and twenty six (326) patients (71.8 %) had coloid goitre, 77 (17.0 %) had thyroid adenoma, 17 (3.7%) had cancer of the thyroid gland, 9 (2.2%) had hashimotos thyroiditis. The remaining 24 (5.3%) patients had their histology results missing.

The relationship of histopathological diagnosis and development of vocal cord paralysis is shown in the table below (Table 5).

Table 5: HISTOPATHOLOGICAL DIAGNOSIS AND VOCAL CORD PARALYSIS DEVELOPED TABULATION COUNT

HISTO PATHOLOGICAL DIAGNOSIS	VOCAL CORD PARALYSIS DEVELOPED		TOTAL	PERCENTAGE DEVELOPING PARALYSIS
	YES	NO		
Colloid Goitre	22	304	326	6.7
Adenomatous Goitre	2	75	77	2.6
Hashimotos Thyroiditis	1	9	10	11.1
Cancer of the Thyroid	3	14	17	17.6

The table shows that patients with carcinoma of the thyroid had higher risk of developing vocal cord paralysis compared to the rest. It was found that papillary carcinoma was the commonest form of cancer of the thyroid gland found in 8 patients. Four (4) patients had medullary carcinoma, 2 had follicular carcinoma and 1 patient each had oncocytoma, hurle cell tumour and adenocarcinoma.

PRESENTATION

Twenty eight (28) patients who underwent thyroidectomy within the study period developed vocal cord paralysis. They were mainly female. Although this may not be relevant, the overwhelming proportion of female

patients undergoing thyroidectomy cannot go unnoticed. Four patients (4) developed symptoms of dysphonia and stridor immediately post operation. The rest presented within 2 weeks to 5 months post operation with dysphonia as their main complain. Their presentation is summarized in the table below: (Table 6)

Table 6: PRESENTING SYMPTOMS

Dysphonia	27
Disphagia	2
Stridor on Exertion	4
Stridor at Rest	2
Voice fatigue and inability to sing high tones	2
Throat irritation and discomfort	3

Results from table 6 show that twenty seven (27) out of the 28 patients presented with dysphonia. One (1) patient developed respiratory distress immediately post thyroidectomy and had to be re intubated and taken to high dependance unit

(HDU). Direct laryngoscopy (D/L) was later done and the cause was due to bilateral abductor paralysis. An emergency tracheostomy was performed to relieve the upper airway obstruction.

Further the table show that four (4) patients presented with dysphonia and stridor on exertion, while 2 presented with dysphonia and stridor at rest. Another 2 patients presented with dysphonia and dysphagia and 2 patients with dysphonia and voice fatigue, which was accompanied by inability to sing high tones. Three (3) other patients who had dysphonia also complained of throat irritation and discomfort.

Laryngoscopic Findings

Twenty five (25) out of the 28 patients received indirect laryngoscopy and 2 patients direct laryngoscopy. One (1) patient received fiberoptic naso laryngoscopy. The findings are summarised in the Table below: (Table 7]

Table 7: LARYNGOSCOPIC FINDINGS

TYPE OF PARALYSIS	RIGHT	LEFT	BILATERAL	TOTAL
Adductor	2	0	0	2
Abductor	5	16	5	26

Abductor paralysis was the commonest finding on laryngoscopy.

Sixteen (16) patients had left abductor paralysis while five (5) had right abductor paralysis. Another five (5) had bilateral abductor paralysis. Two (2) patients had adductor paralysis both of which had right adductor paralysis. None had bilateral or left adductor paralysis.

TREATMENT MORDALITIES

Thirteen (13) of the twenty eight (28) patients with vocal cord paralysis following thyroidectomy had spontanous recovery within a period 3 – 6 months post operation. However, fifteen (15) had persistent paralysis. Their management is summarized in the table 8 below:

Table 8: TREATMENT MORDALITIES

TREATMENT MORDALITIES	FREQUENCY
1. Tracheostomy Only	2
2. Teflon Paste Injections	0
3. Arytenoidectomy and Lateralisation of Vocal Cords	1
4. Combination of (1) and (3)	3
5. Being followed up	8
6. Others: Insertion of metallic tracheostomy tube with a speaking valve.	1
7 Spontaneous recovery.	13

Patients who presented with stridor at rest often with respiratory distress were done tracheostomy (This is a life saving procedure.) In total six (6) patients were done tracheostomy. Two (2) patients were successfully decanulated after arytenoidectomy and lateralisation of vocal cords, while one (1) patient had a metallic tracheostomy

tube with speaking valve fitted with satisfactory phonation.

It was also found that, by the time (December 2000) data extraction of this study was coming to an end, eight (8) patients were still being followed up in the Ear, Nose and Throat – Head and Neck clinic. Two patients ready for arytenoidectomy and lateralisation of vocal cords.

DISCUSSION

This is a retrospective descriptive study on vocal cord paralysis as a complication of thyroidectomy. A total of 454 patients with a 1:11 male to female proportion were done thyroidectomy. This is similar to other studies done in Britain and U.S.A. and reported in literature^(2,5,42). Neril (1983) and Alkhama (1987) found a similar incidence.

Findings in this study show that the commonest type of thyroidectomy done was hemithyroidectomy with 231 patients (50.9%). Subtotal thyroidectomy 158 patients (34.8%), adenectomy; 44 patients (9.7%) and total thyroidectomy with 21 patients (4.6%). Hypothyroidism complicates total thyroidectomy. This complication requires the patient be put on thyroxine supplementation for life. It is for this reason that partial thyroidectomy with preservation of normal thyroid tissue is preferred.

Cancer of the thyroid is associated with a high incidence of vocal cord paralysis. This was evident in this study. The overall incidence of carcinoma of the thyroid world wide ranges from 10 - 50 per million/year. Britain has an incidence of 12, while U.S.A has 36. However, the most

important fact is that thyroidectomy for malignant thyroid tumour carries more risk to recurrent laryngeal nerve injury than non-malignant conditions.

Repeat surgery is more likely to result in vocal cord paralysis than primary surgery. The most likely reasons here are the distorted anatomy at the thyroid region at the second operation and the radical nature of the repeat operation. In some patients the nerves maybe incorporated into the formation of scar tissue later on which is more extensive in the re-operated patients. This explains why some patients without paralysis immediately post operation present with vocal cord paralysis several months later. Repeat thyroidectomies for the second and third times have been associated with increased incidence of vocal cord paralysis in studies done elsewhere in the world as reported in the literature. (41,45).

Vocal cord paralysis is a complication of thyroid surgery that poses a challenge to the otolaryngologist head and neck surgeon in terms of its management. The otolaryngologist in some instances has to sacrifice voice in favour of an adequate airway. In most third world countries where laser surgery is still at its infancy, more

often than not, an adequate airway is given a priority at the expense of voice quality. This was evident in this study where all patients who presented with stridor were done tracheostomy.

In this study the incidence of vocal cord paralysis was 6.2%. This is similar to other studies done elsewhere in the world where the incidence has been found to range between 1 – 5%. (2,44,45). In these studies, the majority of patients presented with dysphonia as their main symptom. In this study 27 patients out of 28 patients presented with dysphonia as their main symptom. Voice production is an important aspect of human communication (4). A mild voice change is often noticed as soon as it occurs. This was evident in this study.

Abductor paralysis is associated with paralysis of recurrent laryngeal nerve alone while the superior laryngeal nerve is intact. This kind of paralysis can occur in thyroid surgery because of the close relationship this nerve has to the thyroid gland. Two patients presented with adductor paralysis. This is not a common finding in peripheral injuries of the recurrent laryngeal nerve and is associated with intracranial causes of laryngeal nerves paralysis. However, this kind of paralysis

may be seen in patients where both the recurrent and superior laryngeal nerves have been damaged. Damage to both nerves might occur in thyroid surgery. This might have been the cause in these two patients.

Left abductor paralysis was diagnosed in 16 (17.9%) patients while 5 (5.7%), had right abductor paralysis. It must nonetheless be noted that in thyroid surgery, right recurrent laryngeal nerve is the one most vulnerable to iatrogenic injury. This is because it is more lateral than the left, and sometimes its not found in the tracheosophageal groove. Apart from the above, sometimes it is not recurrent but branches directly to the larynx high up in the neck (5,9). This predisposes the right recurrent laryngeal nerve more to iatrogenic injury during thyroidectomy than the left.

However, when other causes of recurrent laryngeal nerve are considered, the left recurrent laryngeal nerve has been found to be more affected than the right at a ratio of 4:1(5,9). This is because the left recurrent laryngeal nerve goes deep into the mediastinum going round the arch of the aorta before ascending in the tracheosophageal groove. This subjects the nerve

to injury in pathology of the mediastinum like bronchogenic carcinomas, pulmonary tuberculosis, patent ductus arteriosus and its ligation amongst others.

The higher frequency of the risk of damage to the left recurrent laryngeal nerve in this study is unexpected, although its relevance cannot be statistically ascertained because of the small numbers involved.

Of the 28 patients who developed vocal cord paralysis post thyroidectomy, 13 had spontaneous recovery of the vocal cord function within a period of 3 to 6 months. It is therefore worthwhile to follow up patients with speech therapy alone for at least 3 months or more with hope that the patient might have spontaneous recovery. The period of time one has to wait before surgical intervention is generally agreed at 6 months. There is no scientific study that has been undertaken to explain why this period should be 6 months. From the available literature this arbitrary figure was taken from an observation that it took 60 days for a damaged recurrent laryngeal nerve of a dog to recover. This was extrapolated to 6 months in man (5). Therefore in most centres a period of 3 months is preferred.

Four patients underwent arytenoidectomy and lateralisation of vocal cords. One patient had tracheostomy and insertion of a metallic tracheostomy tube with a speaking valve. Eight patients are being followed up in Ear Nose Throat - Head and Neck clinic at the Kenyatta National Hospital for possible lateralisation of vocal cords.

CONCLUSIONS

1. Thyroid pathology and surgery should be considered as one of the important aetiological factors of vocal cord paralysis in our set up.
2. In post thyroidectomy patients who present with respiratory distress immediately post operation, damage/injury to the recurrent laryngeal nerve is the most probable cause and should be ruled out and appropriate measures undertaken to safeguard and protect the airway.
3. In repeat thyroidectomy and in thyroid cancer surgery, injury to the laryngeal nerves maybe an eventuality and the surgeon should take all precautions at disposal to avoid injury to these nerves. It is also important that the patient be notified of the increased risk of vocal cord paralysis.
**MEDICAL LIBRARY
UNIVERSITY OF NAIROBI**
4. Patients with unilateral vocal cord paralysis with mild symptoms of airway obstruction should be followed up for 3 – 6 months with speech therapy alone to allow for possible spontaneous recovery in case of partial injury to the nerve or for compensation to occur with disappearance of

symptoms. Definitive management should be started if symptoms persist.

5. Patients with bilateral abductor paralysis with upper airway obstruction or an impending obstruction should be done an emergency tracheostomy. A metallic tracheostomy tube with speaking valve should be fitted for those patients who refuse further surgery. Otherwise, patients who consent need arytenoidectomy with lateralisation of vocal cords with decanulation.

PROFORMA (APPENDIX 1)

1. SERIAL No.
2. NAME
3. AGE
4. SEX
5. I/P No.
6. TYPE OF THYROIDECTOMY. (*Tick correct response*)
 - a) Total Thyroidectomy
 - b) Sub Total Thyroidectomy
 - c) Lobectomy with or without Isthmoidectomy
(Hemithyroidectomy)
 - d) Adenectomy
 - e) State Date Operation performed

 - f) For Repeat Thyroidectomy state the type of 1st
operation and date performed.

7. HISTOPATHOLOGICAL DIAGNOSIS (*Tick correct response*).
 - a) Colloid goitre
 - b) Adenomatous goitre
 - c) Hashimotos thyroiditis
 - d) Cancer of the thyroid
(_____)
8. POST OPERATION PRESENTATION (*Tick correct response*)
 - (a) Normal
 - (b) Paralysis
9. SYMPTOMATOLOGY (*Tick correct response*)
 - a) Dysphonia
 - b) Stridor at exertion
 - c) Stridor at rest

- d) Dysphagia
- e) Other _____ complains.

- f) Time taken between operation(s) and development of _____ symptoms

10. LARYNGOSCOPY FINDINGS (Tick correct response).

- a) Indirect Laryngoscopy (I/L)
- b) Direct Laryngoscopy (D/L)
- c) Fibre optic Laryngoscopy

	RIGHT	LEFT	BILATERAL
Adductor			
Abductor			

11. TREATMENT MORDALITIES PATIENT HAS UNDERGONE

(Tick correct response)

- a) Spontaneous recovery of vocal cord paralysis within 3 - 6 months post operation.
- b) Tracheostomy (alone)
- c) Arytenoidectomy and lateralisation of vocal cords.
- d) Teflon paste injections
- e) A combination of any of the above (state which ones).

- f) Patient still being followed up.
- g) Others.

BIBLIOGRAPHY

1. Jamieson GG. Thyroidectomy. The anatomy of the thyroid gland and related structures. The anatomy of general surgical operations chapter 22 Page 127 – 137. Publishers Churchill Livingstone 1992.
2. Edwin LK. Thyroid and parathyroids. Principles of Surgery 5th Edition Chapter 38 Page 1613 – 1686. Publishers Mcgraw Hill book company 1974.
3. Christopher D. The Thyroid gland. Textbook of Surgery 11th Edition Chapter 25 Page 674 – 717. Publishers Saunders W B Company 1977.
4. James Koufman MD, Glenn I. The spectrum of vocal cord dysfunction. The Otolaryngologic clinics of North America, 1991; 24: 985 - 988.
5. Maran AGD, Gaze M, Wilson JA. Vocal cord paralysis. Stell and Maran's head and neck surgery 3rd edition 1995 chapter 10 Page 139-160 Publishers, Butterworth-Heinemann Ltd. 1993.
6. Chu PY, Chang SY. Transoral Teflon injection under flexible laryngovideostroboscopy for unilateral vocal cord fold paralysis. Annals of Otology, Rhinology and Laryngology, 1997; 106: 783-786.
7. Mellee SM. Functional anatomy of the larynx. The Otolaryngologic clinics of North America, 1984; 17: 3 –12.

8. Hollinshead W H. The pharynx and larynx. Anatomy for Surgeons Volume 1. Head and Neck. Ch. 8 Pp 440 – 496. Publishers Harper and Row Publishers 1968.
- 9 Ballenger JJ. Neurologic diseases of the larynx. Diseases of the nose, throat and ear, Ch. 34. Pp 444-447. Publishers-Hendry Kimpton publishers London 1977.
10. Howard D. Neurological affections of the pharynx and Larynx. Scotts Brown's Otolaryngology. 5th edition Vol. 5 Ch.10 Pp 169-185. Publishers, Butterworth and Company Ltd. 1987.
11. Gray H. Neurology. Grays anatomy 35th edition 1973 Chapter 7 Page 1019-1024. Publishers, Longman group Ltd. 1970.
12. Bei LW, Sanders I, Liancai M. The human communicating nerve. Archives of otolaryngology head and neck surgery, 1994; 120:1329 - 1327.
13. King BT, Gregg RL. An anatomical basis for the various behaviours of paralysed vocal cords. Annals of Otolgy, Rhinology and Laryngology, 1948; 57: 925 - 944.
14. Panosian MS, Quatela VC. Guillian – Barre Syndrome presenting as acute bilateral vocal cord paralysis. Otolaryngology Head and Neck Surgery, 1993; 108:171 – 173.

15. Jerome W, Thompson MD, Stocks RM. Brief bilateral vocal cord paralysis after insecticide poisoning. Archives of Otolaryngology Head and Neck surgery, 1997; 123: 93-96.
16. Webb J. Iraq caught out over nerve gas attack. New scientist 1993; 138:4.
17. Alfredsunder P, Hochman MC, Kaplan BH. Low dose vincristine associated bilateral vocal cord paralysis. N. Y. State journal of medicine, 1992; 92: 268-269.
18. Moralee SJ, Reilly PG. Metabolic stidor; bilateral vocal cord paralysis Secondary to hypokalemia. Journal of Otology and Laryngology, 1992; 102 : 56-57.
19. Wu YR, Chen CM, Tang LM. Vocal paralysis as an initial sign of multiple system atrophy in the central nervous system. Journal of Formosa Medical Association, 1996; 95: 804 – 806.
20. Thompson LD, McCaffrey TV, Krauss WE. Cervicomedullary compression, an unrecognised cause of vocal cord paralysis in rheumatoid arthritis. Annals of Otology. Rhinology and Laryngology, 1998;107: 462-471.
21. Boyd CM, Esclamado RM, Telian SA. Impaired vocal cord morbidity in the setting of acute suppurative thyroiditis. Head and Neck, 1997; 19: 235-237

22. Shafei H, Kholy A, Ebrahim M. Vocal cord dysfunction after cardiac surgery: An overlooked complication. *European Journal of Cardiothoracic Surgery*, 1997; 11: 564-566
23. Laursen RJ, Larsen KM, Molgaard J. Unilateral vocal cord paralysis following endotracheal intubation. *Acta Anaesthesiology Scand*, 1998; 42: 131 – 132.
24. Zbar RI, Chen AH, Behrendt D M. Incidence of vocal fold paralysis in infants undergoing ligation of patent ductus arteriosus. *Annals of Thoracic Surgery*, 1996;61: 814-816.
25. Lundy DS, Casiano RR. "Compensatory falsetto,". Effects on vocal quality. *Journal of voice*, 1995; 9:439-442.
26. Ward PH, Hanson DG, Abemayor E. Transcutaneous injection of the paralysed vocal cord; A new technique. *Laryngoscope*, 1985; 85: 644 - 649.
27. Changs HP, Chang SY. Intracordal injection of Teflon via indirec laryngoscopy. *Journal of Otolaryngology SOC Republic of China*, 1984; 19:141-146.
28. Harries ML, Morison M. Management of unilateral vocal cord paralysis by injection medialization with teflon paste. *Annals of Otorhinolaryngology*, 1998;107: 332-336.
29. Koutman JA, Garry Y S, Mark A. Autologus fat injection into the vocal folds: Technical consideration and long time follow up.

Laryngoscope, 1997;107:117-186.

30. Saccagna P W, Werning J W, Sctrakian S. Lipoinjection in the paralysed feline vocal fold: A study of graft survival. *Otolaryngology head and Neck Surgery*, 1997, 117:465 – 470.
31. Marc EG, Frank RM, Thomas W. Vocal fold medialization using autologus cartilage in a canine model. *Laryngoscope*, 1995; 105: 1047-1052.
32. Brandeburg JH, Kirkham KW. Vocal cord augmentation with autogenous fat. *Laryngoscope*, 1992; 102: 495 - 500.
33. Turker H. Laryngeal re-innervation for unilateral vocal cord paralysis. *Annals of Otology, Rhinology and Laryngology*, 1989; 90:457 – 459.
34. McCaffery TV. Transcutaneous telfon injection for vocal cord paralysis. *Otolaryngology, Head and Neck Surgery*, 1993; 109: 54-59.
35. Iwatake H, Lida J, Hoshikawa T. Transcutaneous intracordal silicon injection for unilateral vocal cord paralysis. *Acta Otolaryngologica supplement – (Stockh)* 1996; 522:133-137.
36. Zheng H., Liz H, Cuan Y.,

Update laryngeal reinnervation for unilateral vocal cord paralysis with ansa cervicalis
Laryngoscope, 1996;106:1522-1527.

37. Ramadan HH, Wax MK, Avery S. Outcome and changing course of unilateral vocal cord paralysis. Otolaryngology Head and Neck Surgery. 1998; 118:199-202.
38. Manish KW, Yarber R, Hengesteg A. Endoscopic laser medial arytenoidectomy versus total arytenoidectomy in the management of bilateral vocal fold paralysis. Annals of Otolaryngology, Rhinology and Laryngology, 1996; 105: 857-862.

MEDICAL LIBRARY
UNIVERSITY OF NAIROBI

39. Ramade M, Mayne A, Jamart J. Subtotal carbon dioxide laser arytenoidectomy by endoscopic approach for treatment of bilateral cord immobility in adduction. Annals of Otolaryngology, Rhinology and Laryngology, 1996;105:438-445.
40. Neil W. Anatomy of the Larynx and Tracheobronchial tree.
Scots Brown's Otolaryngology; Basic Sciences
5th Edition ch.12. Pp 296 - 321.
Publishers Butterworths and Co. (Ltd) 1987.
41. Halsted WS. The operative story of goitre. Rep 19:71.
Reprinted in Halsted W S. Surgical papers.
The John Hopkins Press, 1924;11: 257.

42. Michael H, Selwyn T. Surgery of special systems; The endocrine system. Rose and Carles manual of surgery 19th edition
section 5 Pp 809-831.
Publishers, Bailliere Tindall and Cox Faund and Street – Henrieta street 1960.
43. Hussein AA M.Med 1987. Complications of thyroid operations. A dissertation for fullfillment of M.Med in General Surgery, A publication of the University of Nairobi 1987.
44. Kasemsuwan L, Nubthuenetis. Recurrent Laryngeal nerve paralysis; A complication of thyroidectomy.
Journal of Otolaryngology, 1997; 26: 365 - 367
45. David D, Caldarelli MD, Lauren DH. Complications and sequelae of thyroid surgery. Otolaryngologic clinics of North America; Surgery of the thyroid and parathyroids, 1980; 13: 85-99
Publishers W. B. Saunders company.
46. Nevil G. Complications of thyroid operations.
The proceedings of the Association of Surgeons of East Africa 1983.