

**THE ROLE OF CT SCAN IN IMAGING NECK
STRUCTURES AND LESIONS:
A RADIOLOGICAL - HISTOPATHOLOGICAL
CORRELATION**

**A PROSPECTIVE AND RETROSPECTIVE STUDY AT
KENYATTA NATIONAL HOSPITAL**

By

DR. IAN MATHENGE MURIITHI, MBChB. (NBI)

**DISSERTATION SUBMITTED IN PART-FULFILMENT OF THE
DEGREE OF MASTER OF MEDICINE IN DIAGNOSTIC
RADIOLOGY, UNIVERSITY OF NAIROBI**



SUPERVISOR:


**DR. N. M. KIMANI
MBChB, MMED (NBI)
LECTURER
DEPARTMENT OF DIAGNOSTIC RADIOLOGY
UNIVERSITY OF NAIROBI**

**UNIVERSITY OF NAIROBI
MEDICAL LIBRARY**

DECLARATION

Candidate:


This dissertation is my original work and has not been presented for a degree in any other university.

Signed 

DR. I. MATHENGE MURIITHI MBChB (U.O.N.)

Supervisor:

This dissertation has been submitted for examination with my approval.

Signed 

DR. KIMANI N. M.

MBChB (U.O.N.)

MMED Diagnostic Radiology (U.O.N)

Lecturer

Department of Diagnostic Radiology

University of Nairobi

DEDICATION

This work is dedicated to my family – my parents Mr. and Mrs.

**Mathenge, my brother King'ori and my sister Wangui and her family for
their love, patience and encouragement.**

They have been and continue to be my inspiration.

ACKNOWLEDGEMENT

This study has been made possible with the assistance of a number of persons to whom I would like to express my sincere gratitude.

I am indebted to my supervisor, Dr. N.M. Kimani for his continued guidance, suggestions, comments and encouragement throughout the period and completion of this study.

I would also like to express my gratitude to Dr. Mugi and Dr. Nyabanda for their interest in the study and their assistance in reviewing the radiological data.

I also wish to appreciate the contribution of the Kenyatta National Hospital Department of Radiology for the assistance they afforded me during the study, and especially the radiographers – Mrs. Njuwe and Mrs. Njagi for their continued assistance and patience.

Finally, I owe special thanks to my family – my parents and siblings – for their encouragement and moral support.

Thank you all for your prayers.

May God bless you all.

TABLE OF CONTENTS

DECLARATION	2
DEDICATION	3
ACKNOWLEDGEMENT	4
TABLE OF CONTENTS.....	5
ABBREVIATIONS	6
ABSTRACT.....	7
INTRODUCTION AND LITERATURE REVIEW	9
NORMAL CT ANATOMY AND PATHOLOGY OF THE NECK ⁷	11
RATIONALE.....	22
AIMS AND OBJECTIVES	23
STUDY DESIGN, MATERIALS AND METHODOLOGY	24
ETHICAL CONSIDERATIONS.....	29
RESULTS	30
DISCUSSION	51
CONCLUSION.....	58
RECOMMENDATIONS.....	60
APPENDIX – DATA COLLECTION FORM	61
REFERENCES	62

ABBREVIATIONS

CT	Computed Tomography
MRI	Magnetic Resonance Imaging
KNH	Kenyatta National Hospital
ENT	Ear, Nose and Throat
BS	Buccal Space
CS	Carotid space
MS	Masticator Space
PMS	Pharyngeal Mucosal Space
PCS	Posterior Cervical Space
PS	Parotid Space
PPS	Parapharyngeal Space (Pre- and Post-styloid)
PVS	Prevertebral Space (Anterior and Posterior Compartments)
RPS	Retropharyngeal Space
SLS	Sublingual Space
SMS	Submandibular Space
VS	Visceral Space
CCA	Common Carotid Artery
ICA	Internal Carotid Artery
IJV	Internal Jugular Vein
WHO	World Health Organization
SCC	Squamous Cell Carcinoma
NPC	Nasopharyngeal Carcinoma
LN	Lymphadenopathy

ABSTRACT

Introduction

Between January and July 2004, histological and radiological records of 42 patients with varied pathologies of the neck were reviewed in a prospective/retrospective study carried out at Kenyatta National Hospital. There were 32 retrospective cases dating back to 2001 and 10 prospective cases collected during the duration of the study. All the patients included in the study had correlating histopathologic data acquired following surgery or biopsy of the lesion. The CT images and histological data formed the basis of my study.

Objectives

The aim of this study was to show the pattern of disease of the neck as assessed by computed tomography scanning at Kenyatta National Hospital, the age and sex distribution and correlate this to histopathologic findings.

Study Design and Method

This prospective and retrospective study was done at KNH X-Ray Department. Consecutive patients who presented for CT scan examination of the neck during the study period were included. The patient's clinical summary (age, sex, ? radiological diagnosis) was obtained from the request/report form. Histopathology reports for all patients who subsequently underwent biopsy or surgery of the neck pathology were requisitioned from the Pathology department, KNH.

Data for the retrospective cases (sequential patients with both sets of data in the period between 2001 and 2003 inclusive) was acquired from the respective KNH departments).

Results

The commonest pathologies encountered were malignancies, with carcinoma of the larynx/hypopharynx and nasopharyngeal tumors constituting 57% of the cases seen.

Both showed a male predilection. Mean ages were 55 and 41 years respectively.

Other cases of malignancies seen included lymphomas, thyroid tumors, carcinoma of the tongue, Kaposi's sarcoma and hemangioendothelioma.

Congenital lesions seen during this study included cystic hygroma and branchial cleft cyst, both of which showed typical imaging findings at CT.

Inflammatory lesions demonstrated included submandibular abscess, inflammatory pharyngeal polyps and pharyngeal mucosal adenoids.

Cervical lymphadenopathy, either as a primary process or as part of metastatic disease was also seen at CT.

All the above cases were subsequently confirmed by histopathology.

Conclusion

Assessment by CT provided a correct diagnosis in 83.3% (sensitivity of 83.3%) of the cases reviewed, with diagnostic difficulties being encountered in only 7 cases (16.7%). This proved CT to be a useful modality in assessment of neck pathology.

INTRODUCTION AND LITERATURE REVIEW

Computed tomography (CT) and magnetic resonance imaging (MRI) are the primary imaging modalities used to evaluate the various regions of the neck. Both modalities have proven themselves sensitive and reliable in the evaluation of various disease processes^{1,2,3,4,5}. CT and MRI both provide essential information about the deep extension of clinically detected masses and may delineate additional clinically unsuspected lesions. The choice of the appropriate imaging modality depends on a number of variables. There is no indisputable "winner" under all anatomical or pathological circumstances. The advantages and disadvantages of CT and MRI in certain clinical settings have been studied⁵.

The capabilities of CT to distinguish between soft tissue structures of varying densities, bone and air, coupled with the added advantage of utilizing intravascular contrast, particularly suits this method of examination to the study of neck disorders. In some cases, CT alone may be the only imaging procedure necessary, while in other situations, CT may comprise an important portion of comprehensive imaging evaluation⁶.

Pathologies of the neck region account for a sizeable proportion of the admissions to the ENT surgical unit in KNH. This study of the pathological findings at CT, with corresponding histopathologic data would be useful in assessing sensitivity of CT as a

possible primary imaging/staging modality. Various studies have been carried out in various parts of the world and covering various anatomical regions in the neck^{33, 34, 35, 36}. However no similar study had been carried out in our setup therefore necessitating this study.

NORMAL CT ANATOMY AND PATHOLOGY OF THE NECK ⁷

The advent of cross-sectional imaging heralded an alternative to the traditional cervical triangle method of organizing neck anatomy. The neck is now regarded as being composed of spaces created by the deep cervical fascia which consists of three layers:

- a superficial investing layer
- a middle visceral layer
- a deep prevertebral layer

which divide the neck into 12 identifiable compartments, namely the:

Sublingual space

Submandibular space

Buccal space

Parotid space

Parapharyngeal space

Carotid space

Masticator space

Pharyngeal mucosal space

Visceral space

Retropharyngeal space

Posterior cervical space

Perivertebral space

The differential diagnoses of disease in the neck are thus defined by the contents of the space in which the disease process is found.

CERVICAL SPACES

Table 1

Sublingual Space (Figure 1B)

Extent	Contents	Key Pathologies
Paired spaces in floor of mouth Oral mucosa superiorly to mylohyoid muscle inferiorly	Muscles - Hyoglossus - Styloglossus Nerves - IX Nn. - XII Nn. - Lingual br, V3 Nn. Lingual arteries Submandibular gland duct Submandibular gland, deep lobe Lymph nodes	Carcinomas – tongue - floor of mouth - minor salivary glands Hemangiomas and lymphangiomas Abscesses Calculi Ranulas Lymphadenopathy Dermoids and Epidermoids

Fig. 1B Low Suprahyoid ⁷

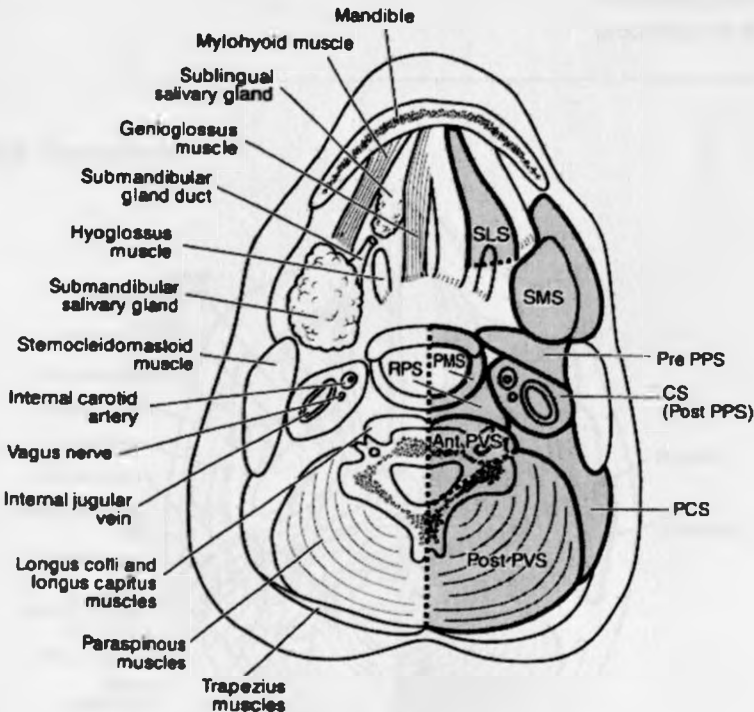


Table 2

Submandibular Space (Figure 1B)

Extent	Contents	Key Pathologies
Posterolateral to sublingual space	Submandibular gland, superficial lobe Lymph nodes	SM tumors - pleomorphic adenomas - mucoepidermoid ca. - adenocystic cancers Inflammatory - abscesses - submandibular LN Congenital - cystic hygroma - branchial cleft cysts - dermoids - epidermoids - thyroglossal duct cysts

Table 3

Buccal Space (Figure 1A)

Extent	Contents	Key Pathologies
Anterior to masseter muscle and lateral to buccinator muscle	Buccal fat pad	Infected fat pad Secondary involvement from processes in adjacent spaces

Fig. 1A High Suprahyoid ⁷

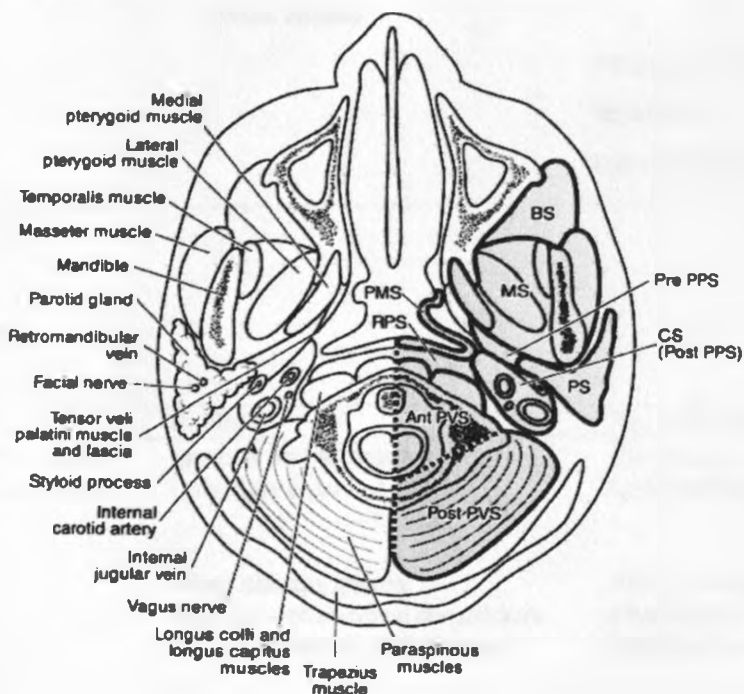


Table 4

Parotid Space (Figure 1A)

Extent/Location	Contents	Key Pathologies
Posterior to masseter muscle	Parotid gland	Parotid tumors - B - pleomorphic adenoma - Warthin's tumor - M - adenocystic carcinoma
	Stenson's duct	
	Facial nerve	
	Intraparotid lymph nodes	LN
	Blood vessels	Hemangiomas, phlebolith Lymphangiomas Calculi Granulomatous diseases Lymphoepithelial cysts (AIDS associated) Lipomas Branchial cleft cysts

Table 5Parapharyngeal Space (Pre-styloid)
(Figure 1A)

Extent	Contents	Key Pathologies
Skull base to hyoid bone	Salivary rests	Pleomorphic salivary adenomas
	Minor salivary glands	
	Fat	Lipoma
	Blood vessels	
		Atypical branchial cleft cysts Metastases Lesions from adjacent compartments

Table 6Pharyngeal Mucosal Space
(Figure 1A - C)

Extent	Contents	Key Pathologies
Mucosal surfaces and submucosa of nasopharynx, oropharynx, oral cavity and hypopharynx	Mucosa and submucosa	Carcinomas
	Lymphoid tissue - adenoids - tonsils	Lymphoid lesions - LN - NHL - tonsillar abscess
	Minor salivary glands	Salivary tumors
	Muscles - pharyngeal constrictors - salpingopharyngeus	Rhabdomyosarcomas Angiofibromas

Table 7

Carotid Space (Figure 1C)

Extent	Contents	Key Pathologies
Jugular foramen to aortic arch	CCA, ICA	Thrombosis, aneurysm or pseudoaneurysm Dissection
	IJV IX – XII cranial nerves Sympathetic chain	Thrombosis, thrombophlebitis Schwannoma, neurofibroma Paraganglioma - Carotid body - Glomus jugulare and vagale
	Deep cervical lymph nodes	Metastases Suppurative LN Abscess Second branchial cleft cyst

Fig. 1C Infrahyoid ⁷

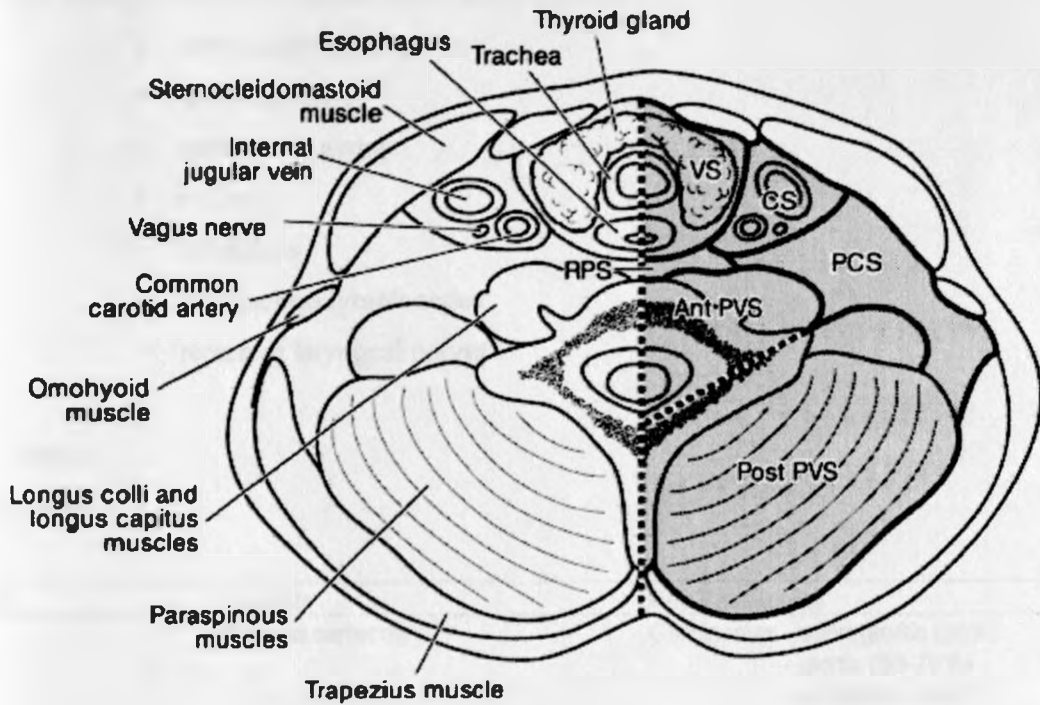


Table 8**Masticator Space (Figure 1A)**

Extent	Contents	Key Pathologies
Formed by the splitting of superficial layer deep cervical fascia	Mandible Muscles of mastication Mandibular division, V3 Nn.	Sarcomas Dental tumors, cysts, abscesses Osteomyelitis Rhabdomyosarcomas Nerve sheath tumors Metastases from oral mucosa and salivary glands

Visceral Space

This midline space is enclosed by the middle layer of deep cervical fascia and extends from the hyoid bone to the mediastinum. It contains the:

- larynx and hypopharynx
- thyroid gland
- parathyroid glands
- trachea
- esophagus
- paratracheal lymph nodes
- recurrent laryngeal nerves

Table 9**Larynx and Hypopharynx (Figure 2A-E)**

Extent/Location	Contents	Key Pathologies
Larynx	Mucosal surfaces Laryngeal cartilages, ligaments and membranes Laryngeal muscles Laryngeal spaces - paralaryngeal - pre-epiglottic	Carcinomas - supraglottic (30%) - glottic (50-70%) - subglottic (rare) Laryngoceles Cartilage lesions - Chondrosarcomas - Chondromas Metastases
Hypopharynx (Paired spaces)	Pyriform sinuses Postcricoid region Posterior hypopharyngeal wall	Carcinoma - pyriform sinus (60%) - postcricoid region (25%) - posterior hypopharyngeal wall (15%)

Fig. 2A High Supraglottic¹⁰

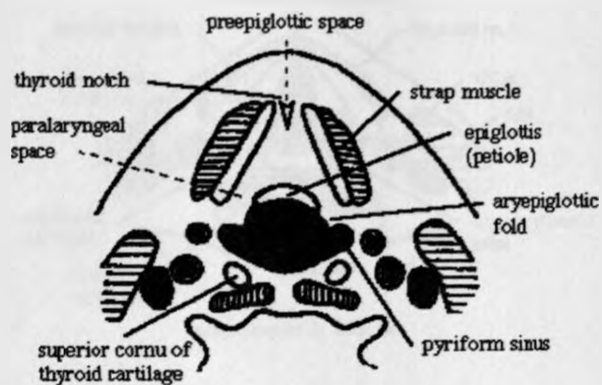


Fig. 2B Mid Supraglottic¹⁰

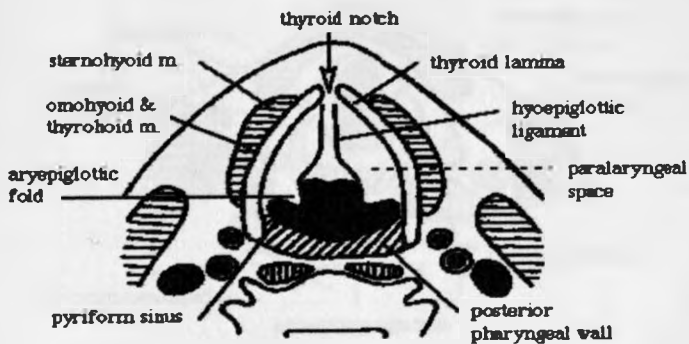


Fig. 2C Low Supraglottic¹⁰

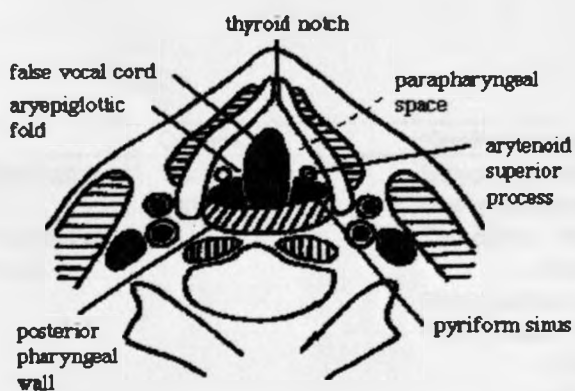


Fig. 2D Glottic¹⁰

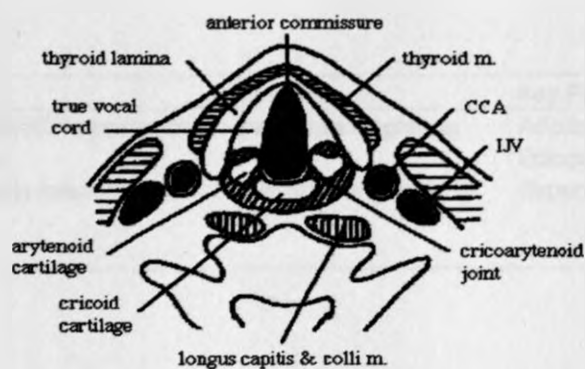


Fig. 2E Subglottic¹⁰

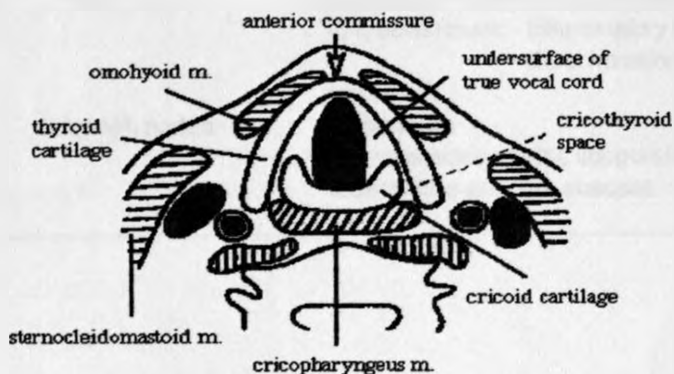


Table 10

Thyroid gland

Extent	Contents	Key Pathologies
Bilateral lobes anterior to larynx and upper trachea	Two lobes	Ectopic thyroid tissue (90% lingual) ⁸
Midline isthmus anterior to trachea at level of 2nd to 4 th tracheal rings	Midline isthmus	Goitre (simple/multinodular)
		Thyroiditis - Hashimoto's
		- Reidel's
		Benign adenomas
		Carcinomas - Papillary (55-75%) ²¹
		- Follicular (15-20%)
		- Medullary (5%)
		- Anaplastic (5%)
		Lymphoma (primary/secondary)

Table 11

Parathyroid Glands

Extent/Location	Contents	Key Pathologies
Superior glands - either side of midline posterior to upper poles of thyroid gland	Two superior glands	Adenomas Ectopic parathyroid glands (20%) ²⁵
Inferior glands - close proximity to inferior poles of thyroid gland	Two inferior glands	Supernumerary glands (25%) ⁹

Table 12Retropharyngeal Space
(Figure 1A-1C)

Extent/Location	Contents	Key Pathologies
Skull base to mediastinum	Fat	Channel for spread of processes from neck to mediastinum: - Inflammatory conditions e.g. abscesses - direct invasion from primary SCC
	Lymph nodes	Lipoma Metastases Reactive adenopathy, suppurative adenopathy, tuberculous adenitis, abscess

Table 13Posterior Cervical Space
(Figure 1B,1C)

Extent/Location	Contents	Key Pathologies
Skull base to clavicle	Fat Spinal accessory nerve (XI Nn.) Lymph nodes	Lipoma/Liposarcoma Schwannoma, Neurofibroma Metastases Reactive adenopathy, suppurative adenopathy, tuberculous adenitis, abscess Congenital lesions - cystic hygromas - branchial cleft cysts

Table 14

Perivertebral Space
(Figure 1A-1C)

Extent/Location	Contents	Key Pathologies
Skull base to mediastinum	Prevertebral, scalene and paraspinal muscles Vertebral body and posterior elements	Abscess Osteomyelitis Metastases Direct invasion of SCC Chordoma Vertebral body primary tumors
	Brachial plexus roots Phrenic nerve Vertebral artery and vein	Schwannoma, neurofibroma Aneurysm or pseudoaneurysm Dissection Thrombosis

Lymph Nodes of the Neck

There are ten major groups of cervical lymph nodes, named after the structures in proximity to the nodes. These nodes form a sentinel ring around the base of the skull that is drained by four chains. The first six groups (occipital, mastoid, parotid, submandibular, facial, and submental) are superficial and easily palpable. The deep groups include the sublingual nodes (group 7) deep in the floor of the mouth, and the deep retropharyngeal nodes (group 8). The paired anterior (group 9) and lateral (group 10) cervical chains of lymph nodes drain the sentinel ring.

The American Joint Committee on Cancer (AJCC) has established guidelines that divide the lymph node groups into a series of levels that have prognostic importance²⁷. Level I consists of the submental and submandibular nodes. Level II includes the internal jugular chain extending from the base of skull to the carotid bifurcation (hyoid bone). Level III corresponds to the internal jugular nodes from the carotid bifurcation to the omohyoid muscle (cricoid cartilage). Level IV refers to all nodes in the internal jugular group from the omohyoid muscle to the clavicle. Level V consists of spinal accessory and transverse cervical nodes. Level VI contains the pretracheal, prelaryngeal, and paratracheal nodes. Finally, level VII includes the nodes in the tracheoesophageal groove and upper mediastinum.

Pathology

The presence of nodal metastases in head and neck cancer patients is associated with a 50% reduction in 5-year survival²⁸. Imaging criteria for lymphadenopathy is based on nodal size, internal heterogeneity, presence of clusters, and associated findings²⁷. Nodes in levels I and II generally are larger compared with nodes in lower levels. The maximum transaxial diameter of a node in levels I or II should not exceed 1.5cm. For levels III to VII, maximum and minimum transaxial diameter should be no greater than 1.0 cm²⁹. Internal lymph node heterogeneity is one of the most reliable criteria for recognizing lymphadenopathy. Normal cervical nodes appear homogeneous and of soft-tissue attenuation on imaging. Central regions within nodes displaying hypodensity on CT should be regarded as abnormal and usually signifies necrosis regardless of nodal size. An exception to this guideline is fatty hila of normal nodes previously inflamed or irradiated. Similarly, nodal homogeneity does not exclude metastases because homogeneous nodes may harbor non-necrotic tumor cells. Nodes involved with lymphoma are typically homogeneous.

Clusters are defined as three or more contiguous, ill-defined nodes within the same level ranging from 8 to 15 mm in size. Clusters may be seen in inflammation, cancer, or lymphoma. Small cancerous nodes, seemingly normal by size criteria, may be clustered with larger obviously malignant nodes.

The presence of extracapsular spread of disease implies a 50% reduction in 2-year patient survival compared with the survival of patients with metastases confined to the nodes³⁰. Nodal extracapsular spread is manifested by capsular enhancement, ill-defined nodal margins, obliterated fat planes surrounding the node, and edema or thickening in the adjacent soft tissues²⁸. The carotid artery should be carefully examined in the presence of internal jugular node extracapsular invasion since tumor can abut and potentially involve this artery, thus altering clinical management. Mimics of extracapsular nodal disease include the changes observed in irradiated or surgically altered nonmalignant nodes.

Additional imaging signs of lymphadenopathy are the presence of enhancement and calcification within nodes. Enhancement on CT is abnormal. Calcification of a node may be seen in granulomatous disease such as tuberculosis, previously radiated neoplastic nodes, and metastatic thyroid carcinoma.

Although controversial, CT generally is preferred to MRI in the imaging evaluation of cervical lymphadenopathy³¹.

RATIONALE

Pathologies of the neck region account for a sizeable proportion of the admissions to the ENT surgical unit. This study of pathological findings at neck CT examinations, with correlative histopathologic data will be useful in the management of patients with such conditions. Various studies have been carried out in various parts of the world and covering various anatomical regions in the neck^{33, 34, 35, 36}. However no similar study has been carried out in our setup therefore necessitating this study.

AIMS AND OBJECTIVES

Broad Objectives

To correlate radiological findings with those of histopathology in the study of neck pathology by computed tomography.

Specific Objectives

To determine the spectrum of neck pathology seen by CT scan in KNH.

To determine the age and sex distribution of patients with these pathologies.

To correlate CT findings with those of histopathology for neck pathologies studied.

STUDY DESIGN, MATERIALS AND METHODOLOGY

STUDY AREA

The study was carried out at Kenyatta National Hospital Radiology and Pathology Departments.

STUDY DESIGN

This prospective and retrospective study was done at KNH X-Ray Department.

Patients who presented for CT scan examination of the neck during the period of the study were included. The patient's clinical summary (age, sex, serial no., x-ray no., radiological diagnosis) was obtained from the request/report form. Histopathology reports for all patients who subsequently underwent biopsy or surgery of the neck pathology were requisitioned from the Pathology department, KNH.

STUDY POPULATION

The study population consisted of patients who had been previously seen and those seen in the KNH Radiology department for CT scan examination of the neck between January 2001 and July 2004 and were admitted to the ENT surgical unit for surgery or biopsy of the neck mass.

SAMPLE SIZE DETERMINATION

Assumption

P = probability of a correct or wrong diagnosis is 0.5

Using Fleis formula:

$$n = \frac{Z^2 \times (1-\beta/2) \times P(1-P)}{d^2}$$

n = sample size.

Z = standard errors from the mean corresponding to 95% confidence level (1.96).

d = absolute precision (15%).

β = level of significance (5%).

$$n = \frac{1.96^2 \times (1-0.05/2) \times 0.5(1-0.5)}{0.15^2}$$

$$= \frac{3.8416 \times 0.975 \times 0.25}{0.0225}$$

$$= \frac{0.93639}{0.0225}$$

$$= 41.6$$

$$= 42$$

Some key factors were considered to determine the sample size. These factors include:

- The amount of required vis-à-vis available information
- Constraints such as time and logistical problems affecting the study, availability of funds, and physical resources.

Bearing in mind these factors, the sample size included consecutive patients who had CT neck examinations and subsequent histopathologic analysis of tissue samples during the period of the study.

METHODOLOGY

CT Scans – the Philips Tomoscan CX \ Q scanner, which is a 3rd generation CT scanner manufactured in 1991, was used. The scanning gantry consists of an x-ray source that produces a highly collimated fan-shaped beam mounted opposite an array of 30 sodium crystalline detectors. The x-ray source and detectors rotate around the patient at 10° increments for a total of 180 with a linear transverse scan occurring at each of the 18 rotational points. A single scan completes in 20sec producing one tomographic scan.

Computed tomography evaluation of the neck began with a general neck survey examination prior to more detailed and focused protocol. Scanning covered the region from the base of the skull to the clavicles with contiguous 5-mm-thick slices. A digital lateral scanogram assisted in planning. In patients without significant dental amalgam, scanning was accomplished in a single range with slices parallel to the laryngeal ventricle/hyoid bone. In patients with numerous dental restorations, two ranges were necessary to avoid streak artifacts. The initial range covered anatomy superior to the

teeth and a second range angled the gantry to avoid metal artifacts. Intravenous contrast was administered by hand injection (initial bolus) then by intravenous drip through a venous catheter. Total volume and injection rates of contrast were tailored to the patient size, venous access, general medical condition and CT technique employed in image acquisition.

The patients were imaged supine while quietly breathing. A typical contrast medium injection protocol involved administration of a bolus of 10 ml, followed by a slow infusion of an additional 40ml. An initial delay of 20 to 25 sec, from the start of the injection to the beginning of scanning, allowed adequate intravascular contrast enhancement.

Patients were subsequently taken to theatre for biopsies via endoscopy for those who had accessible mucosal lesions. Excisional biopsies were performed where masses/lymph nodes were accessible and palpable. Some patients had fine needle aspiration of their neck pathologies. All tissue samples were thereafter taken for histological review. Patient treatment was thereafter instituted (surgery/radiotherapy/chemotherapy) once the diagnosis was confirmed and extent of the lesion assessed.

DATA MANAGEMENT AND ANALYSIS

Data collection was done by use of the questionnaire described in the appendix. Both sets of retrospective data (CT images and histopathology reports) were acquired from the respective departments at KNH. For the prospective cases, images were

reviewed on-screen and hard copies printed. Histopathologic data was acquired from the KNH Pathology department.

All images were reviewed by the researcher with assistance of 3 experienced radiologists and a consensus reached regarding likely CT diagnosis. This was done prior to acquiring histological diagnosis.

Patient serial numbers (in-patient, x-ray) were used to identify individual cases and maintain patient confidentiality.

Statistical analysis of data acquired was performed using

Data and results were subsequently presented in text and table form to fulfill aims/objectives of the study. Representative images were also presented for illustration.

STUDY LIMITATIONS

1. Frequent breakdown of the KNH CT Scanner occasionally led to referral of some patients to other centres for scanning. These patients were therefore not included in the study.
2. Time and financial constraints.
3. Due to KNH being a tertiary health institution, late presentation by patients in the course of their illness may have influenced sensitivity of CT diagnosis.

ETHICAL CONSIDERATIONS

1. Patients' names were not recorded during the study in order to maintain confidentiality and the information acquired will not be used for any purpose other than for the research. For referral purposes, only the patients' hospital numbers were required.
2. No examination was done on a patient apart from one requested by the primary physician. As such there was no need of signed consent; that is only patients sent for examinations (radiological and histopathologic) by the attending physician were considered.
3. Patient information i.e. CT scans and histopathology reports were acquired from the respective departments i.e. Diagnostic Radiology and Pathology Records departments respectively, and as such, there was no need for signed consent from the patient.
4. The results of this study will be delivered to the KNH ethical committee to assist them form a database for future study and reference and to facilitate any possible improvements in patient management.
5. Before commencement of the study, a request was submitted, together with a copy of the proposal to the ethical and research committee for approval.

RESULTS

The study included 28 male and 14 female patients with ages ranging from 2.5 to 80 years. Sixteen different pathologies and the corresponding number of cases were identified.

Carcinoma of the Larynx/Hypopharynx

Thirty one percent of patients (13) had histologically confirmed squamous cell carcinoma of the larynx/hypopharynx (Figure 1). A marked male preponderance with a male:female ratio of 11:2 was noted. The age range was 28 to 80 years, with mean age of 55 years. Because of its proximity to the larynx, tumors of the hypopharynx are discussed with this group of lesions. Eight patients had hypopharyngeal involvement in the laryngeal tumor process. Eleven of the thirteen patients also had associated lymphadenopathy (Level 1 to 7) with encasement of vessels of the carotid space demonstrated in one case.

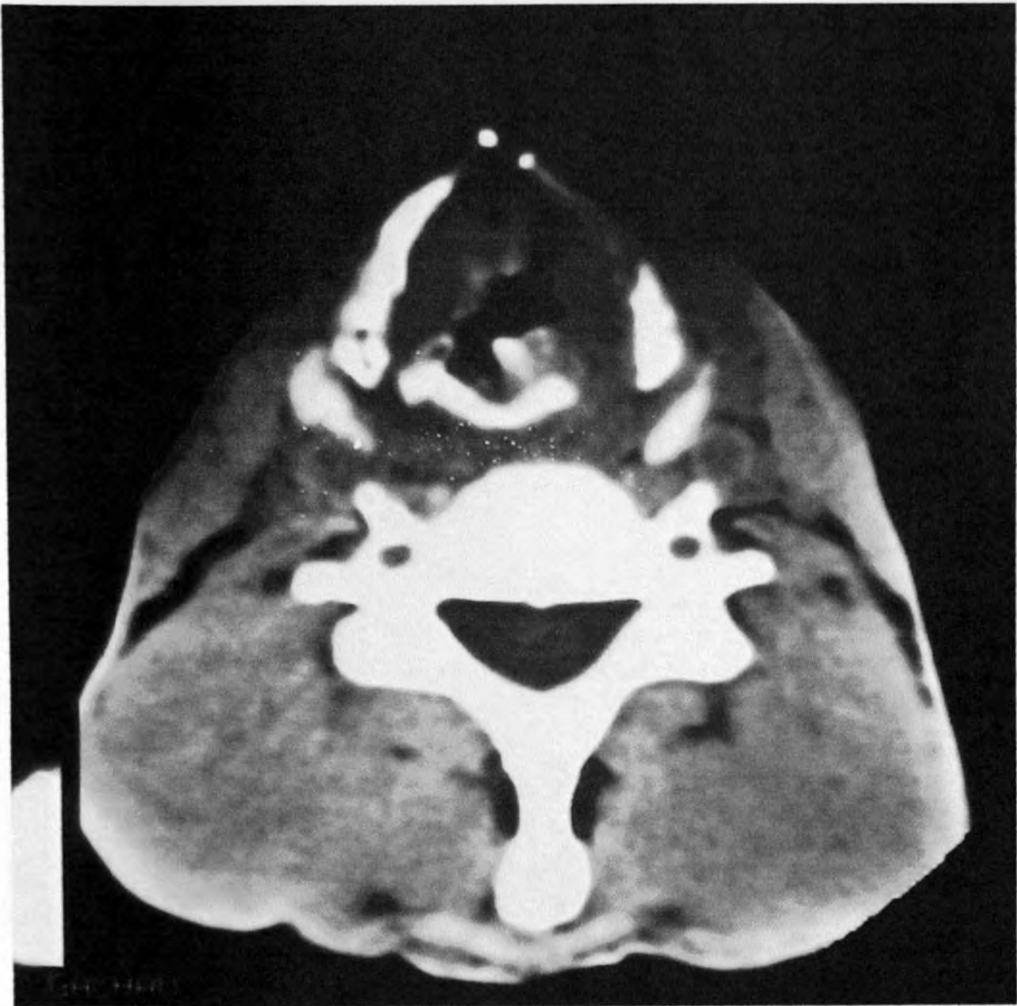Five patients had supraglottic tumors with findings ranging from false cord or aryepiglottic fold soft tissue masses to obliteration of pre-epiglottic space, paralaryngeal space and pyriform sinus normal fat density by soft tissue masses.

Eight patients had transglottic tumors, with 5 having glottic and supraglottic components, 2 having glottic and subglottic components while 1 had supraglottic, glottic and subglottic components. Significant soft tissue thickening of the anterior commissure was noted in three cases, while the rest showed eccentric circumferential narrowing of the laryngeal airway, 6 having tracheostomy tubes in situ.

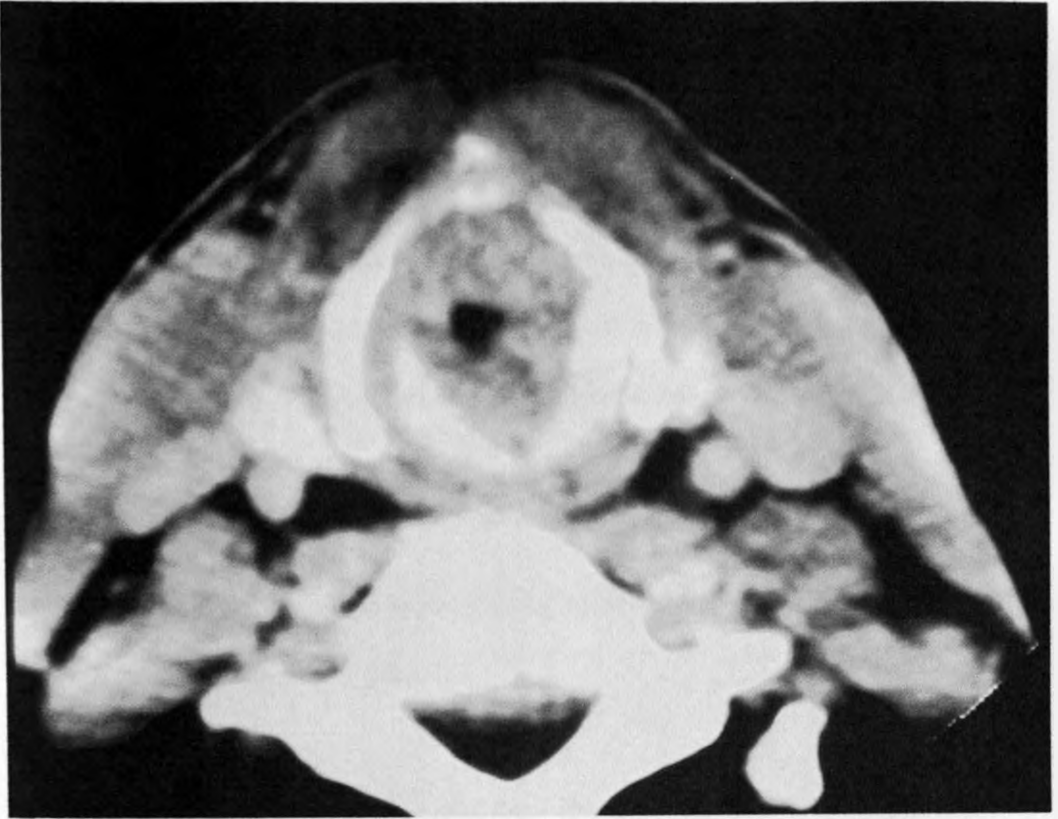
No purely subglottic tumor was identified in this study.

Neoplastic cartilage invasion was inferred in 6 cases. Sclerotic arytenoid cartilages in association with supraglottic tumors were seen in 2 cases. Sclerosis of part of the cricoid cartilage was also seen in association with 1 case of supraglottic carcinoma.

Thyroid cartilage erosions were seen in 3 cases of transglottic tumors.



Non-enhanced CT – Soft tissue thickening of true cords with erosion of the left thyroid cartilage. Patient had transglottic carcinoma of the larynx. (Histology – SCC)



Contrast enhanced CT – circumferential narrowing of the airway at the level of the true cords by soft tissue mass. Sclerosis of cricoid cartilage. Likely erosion of the thyroid cartilages anteriorly. Patient had transglottic carcinoma of the larynx with hypopharyngeal involvement and likely cartilage involvement. (Histology – SCC)

Nasopharyngeal tumors

About 27% of patients (11) had histologically confirmed nasopharyngeal tumors; seven of which were undifferentiated (anaplastic) carcinomas and four were squamous cell carcinomas. There was a slight male predominance noted with a male: female ratio of 7:4. Age distribution lay between 17 to 80 years, with a mean age of 41 years (Fig. 3). Ten of these patients had associated lymphadenopathy (Level 1 to 7).

Obliteration of mastoid air cells as a result of Eustachian tube involvement by the tumor process was seen in 2 cases.

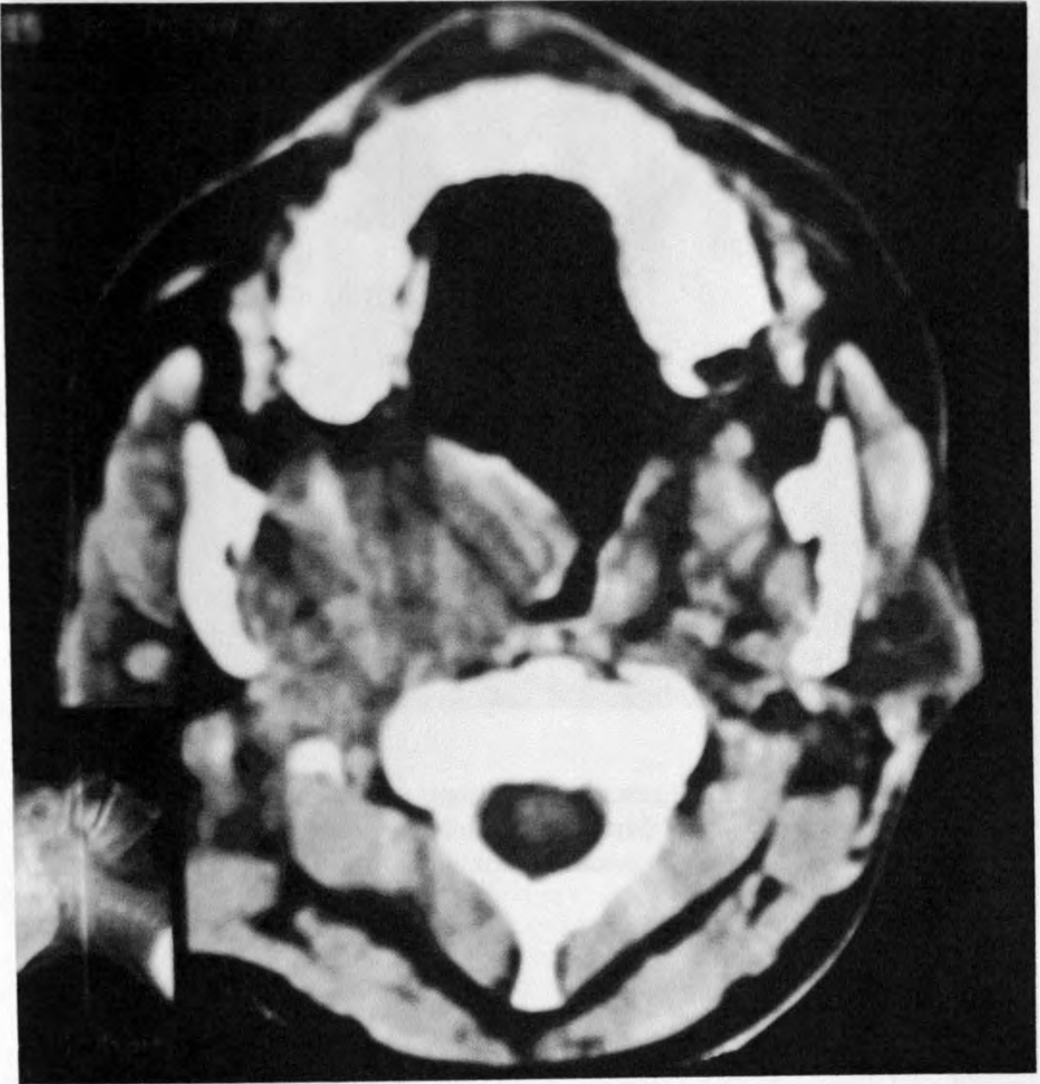Extension of the tumor into the nasal cavities through the posterior choanae or into paranasal sinuses (sphenoid, ethmoid, mastoid) was seen in 4 cases. One patient also demonstrated extension of the tumor mass into the right orbit through erosion of its medial wall by the tumor process.

Four cases showed lateral extension of the tumor process with effacement of the ipsilateral parapharyngeal space.

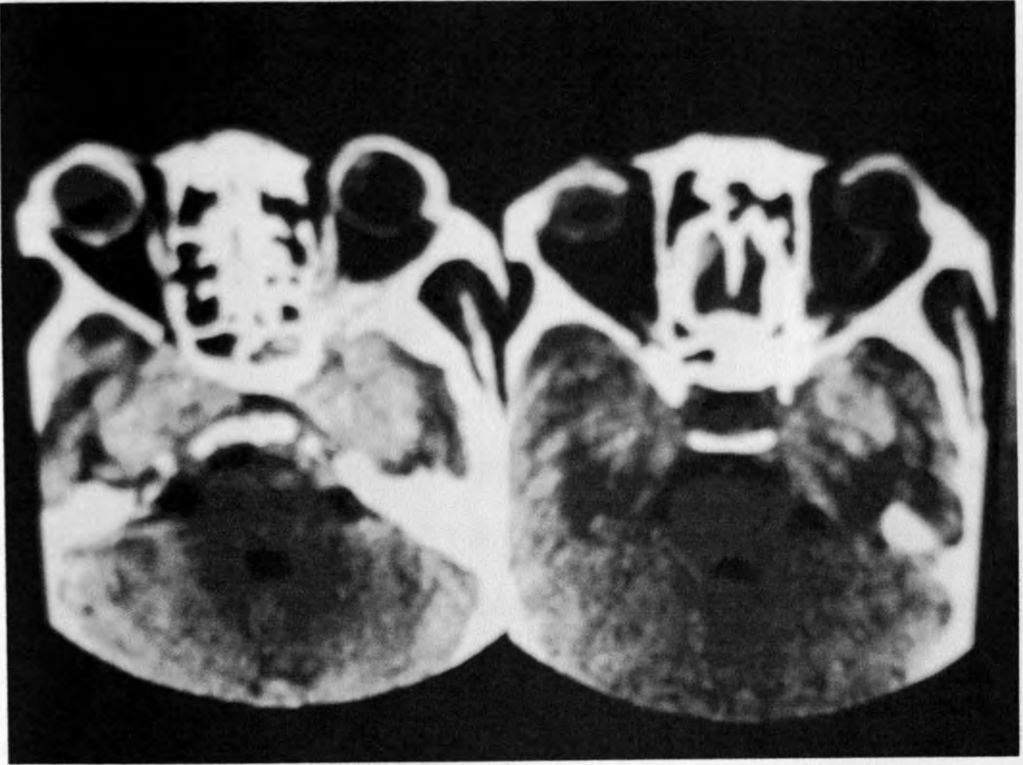
Intracranial extension into the middle cranial fossa through erosion of the skull base was seen in 3 cases.

Hypopharyngeal involvement was also seen in 2 cases.

Pre-vertebral muscle involvement was difficult to assess in all cases.



NECT – nasopharyngeal soft tissue mass extending to oropharynx and causing obliteration of the right parapharyngeal space.



CECT – axial scans showing extension of enhancing tumor process into middle cranial fossae bilaterally and left posterior orbit (same patient as above).

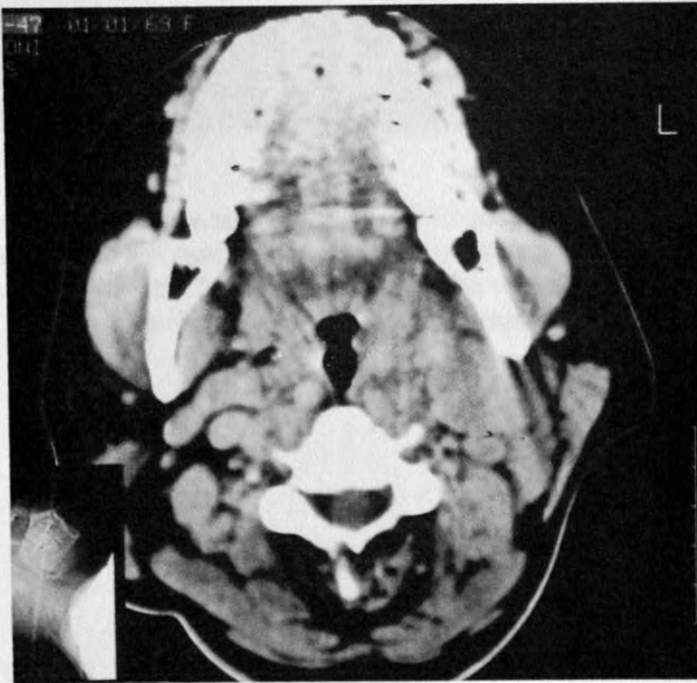
Histology – Undifferentiated carcinoma of the nasopharynx.

UNIVERSITY OF NAIROBI
MEDICAL LIBRARY

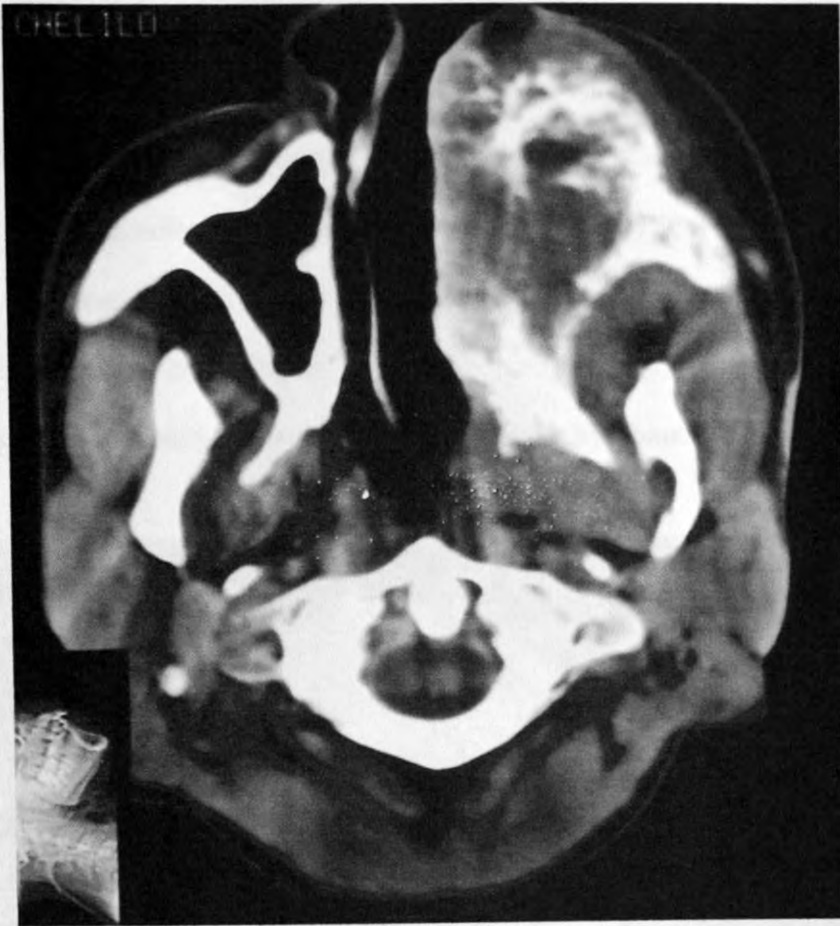Lymphomas

Four of the forty-two cases (9.5%) cases reviewed were biopsy confirmed lymphomas, 2 of the Non-Hodgkin's lymphoma variety, 1 Hodgkin Disease and 1 malignant lymphoma. There was equal sex distribution of the pathology. Age distribution was from 15 to 36 years with a mean age of 29 years.

Three of these involved homogenous, matted enlarged lymph node groups of the neck (unilaterally) corresponding to Level 1 to 4 nodes, with foci of calcification noted in one case. In one case there was an extensive maxillary antrum soft tissue mass with extension into the apex of the left orbit, left infratemporal fossa and nasal cavity with destruction and infiltration of the surrounding bone, soft tissues and overlying skin.



CECT – Multiple, bilateral soft tissue density masses posterior to the angle of the mandible. The masses are discrete, rounded, and show slight rim enhancement.
Histology – Hodgkin Disease (Lymphocyte predominant)



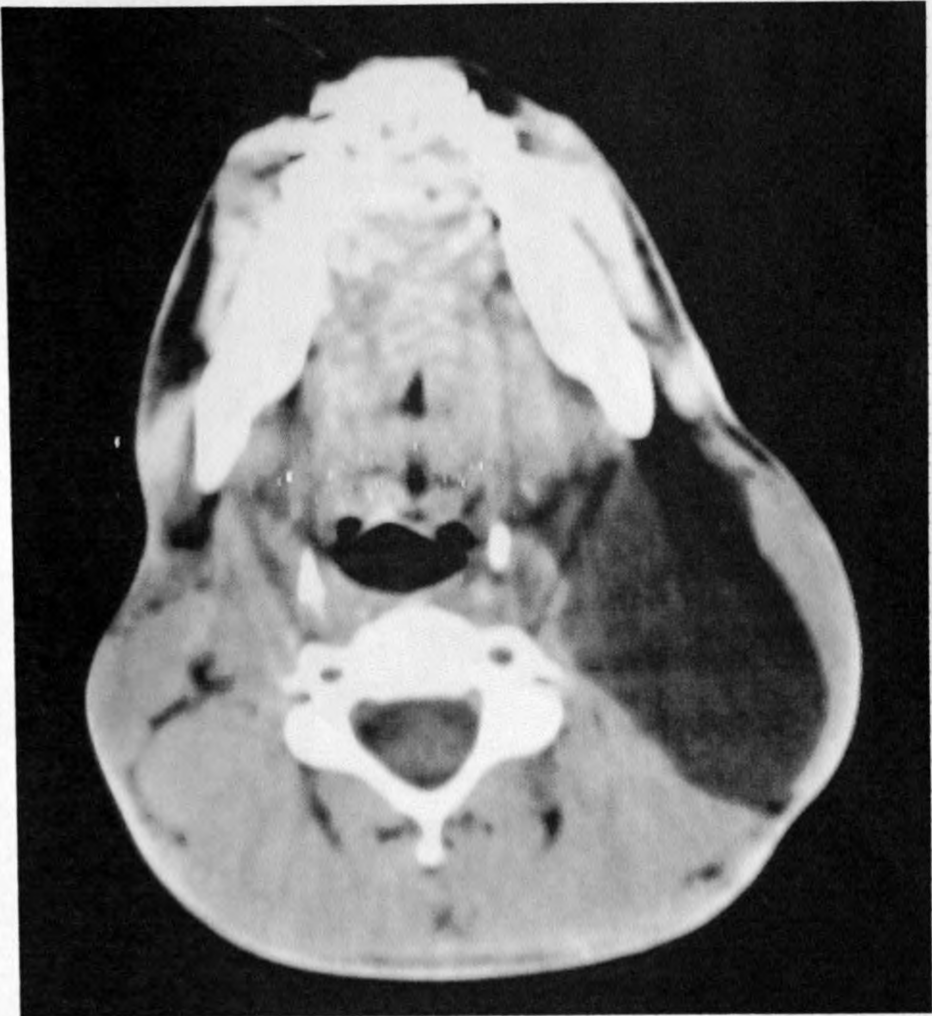NECT – Massive, destructive soft tissue mass infiltrating the left half of the maxilla with obliteration of the left maxillary antrum and widening of the left pterygopalatine fossa. Extension into the apex of the left orbit was also demonstrated.

Histology – Non-Hodgkin's lymphoma.

Cystic Hygroma

One male patient age 17 years had a low density cystic mass in the left posterior cervical space extending from the level of the first cervical to third thoracic vertebrae, causing compression of the ipsilateral carotid space anteromedially. The lesion showed peripheral enhancement.

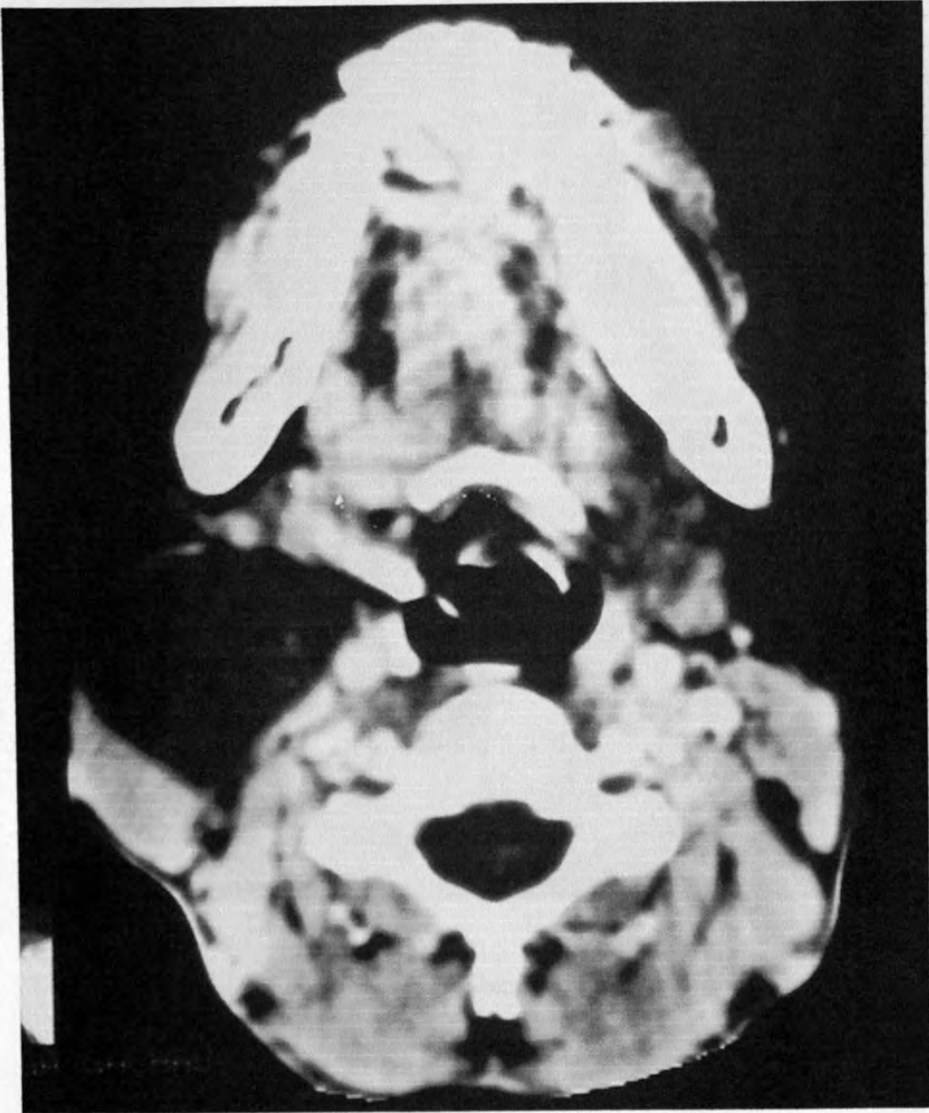
This was a histologically confirmed left infected cystic hygroma.



NECT – Cystic hygroma (cystic lymphangioma)

Branchial Cleft Cyst

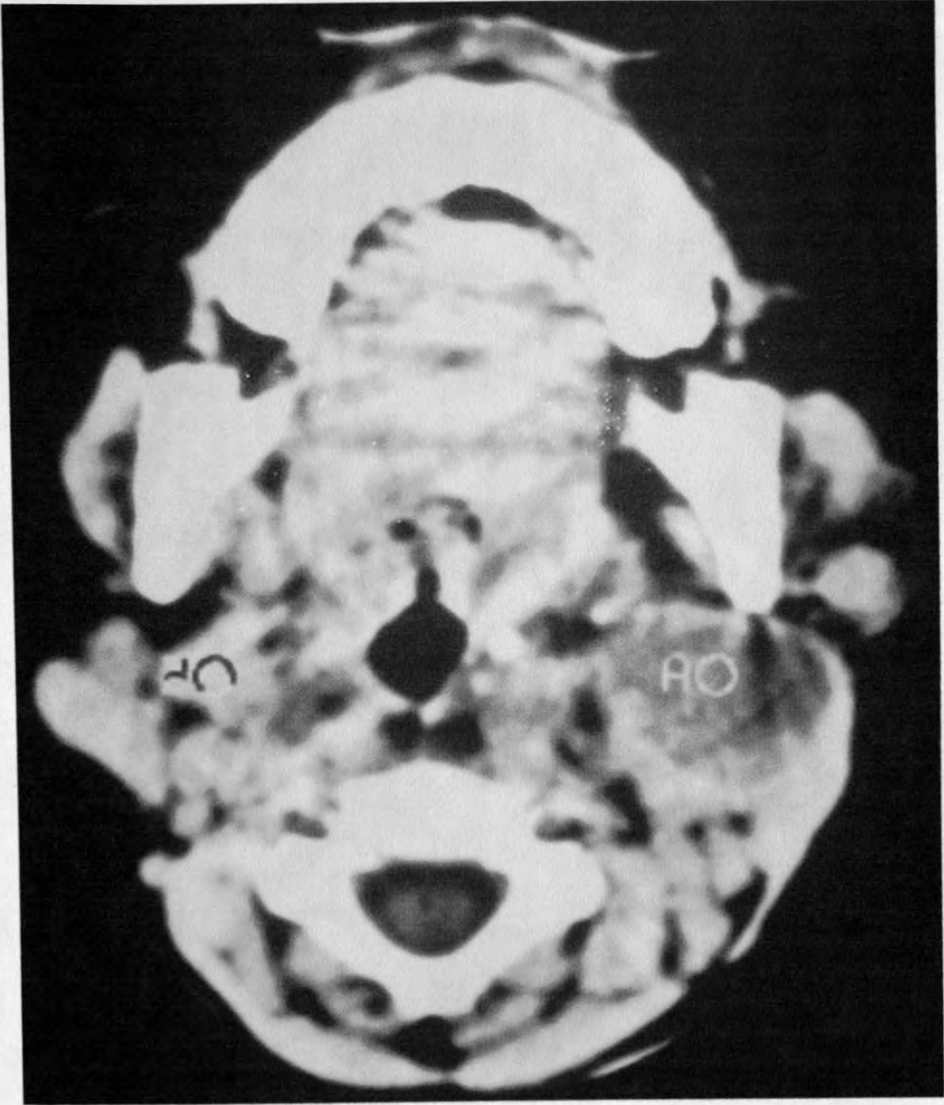
A low density (15.5HU) lesion showing peripheral enhancement was identified anterior to the right sternocleidomastoid muscle extending from the level of C1-C6 vertebrae in one patient aged 24. The lesion was noted to compress and displace posteriorly the right sternocleidomastoid muscle and internal jugular vein. This was histologically confirmed to be an infected branchial cleft cyst.



CECT – Branchial Cleft Cyst

Submandibular Abscess

A 2.5-year-old male patient had a rim enhancing, hypodense lesion in the left submandibular gland, confirmed histologically to be a submandibular gland abscess.

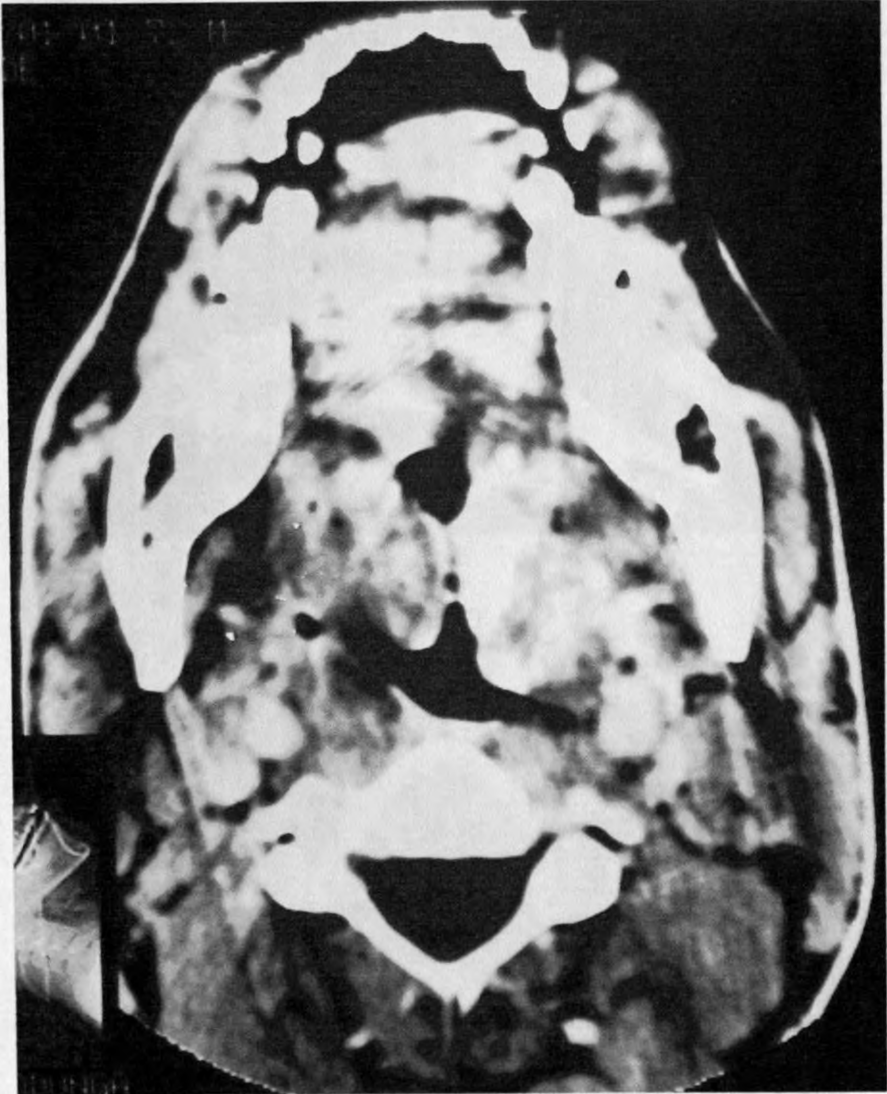


CECT – Submandibular Gland Abscess (marked Ao)

Pharyngeal Mucosal Space Adenoids

A 31 year old female patient had a homogenous, moderately enhancing bilateral nasopharyngeal soft tissue masses.

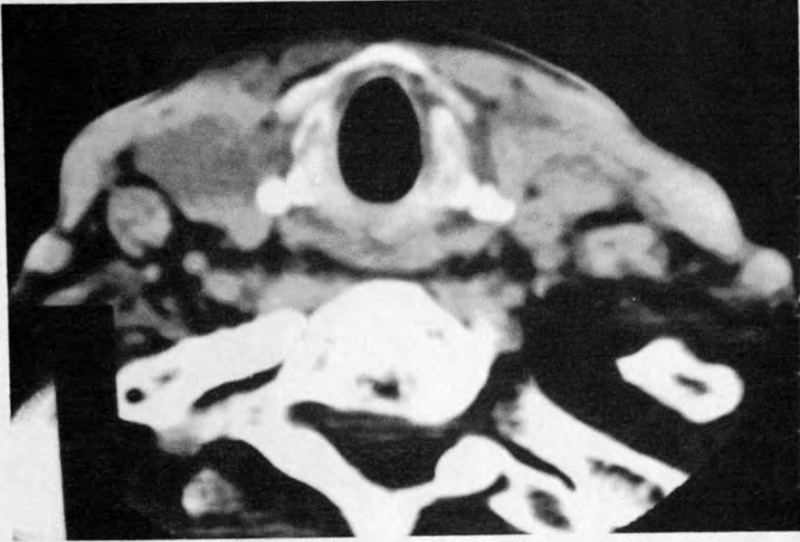
These were histologically confirmed to be enlarged adenoids.



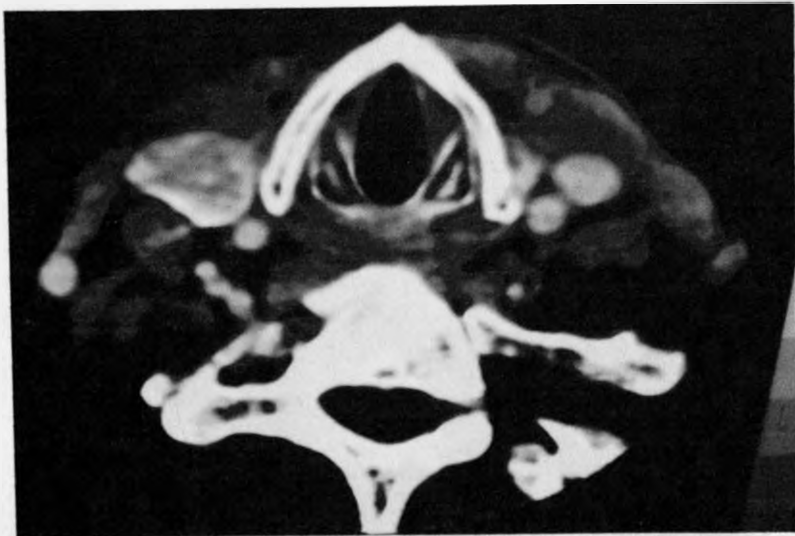CECT – Adenoids

Carcinoma of the Thyroid Gland

One 66-year-old patient had histologically proven follicular carcinoma of the thyroid gland. The entire gland, on imaging, was enlarged and hypodense to muscle, showing intense homogenous enhancement post contrast. No lymphadenopathy was identified.



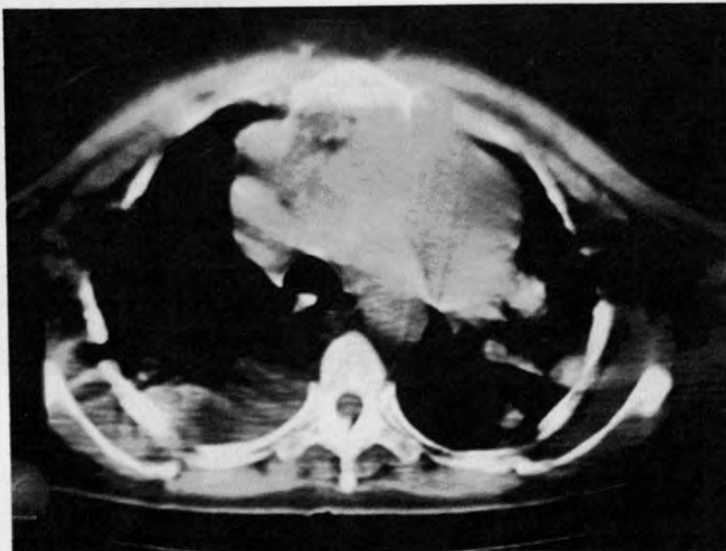
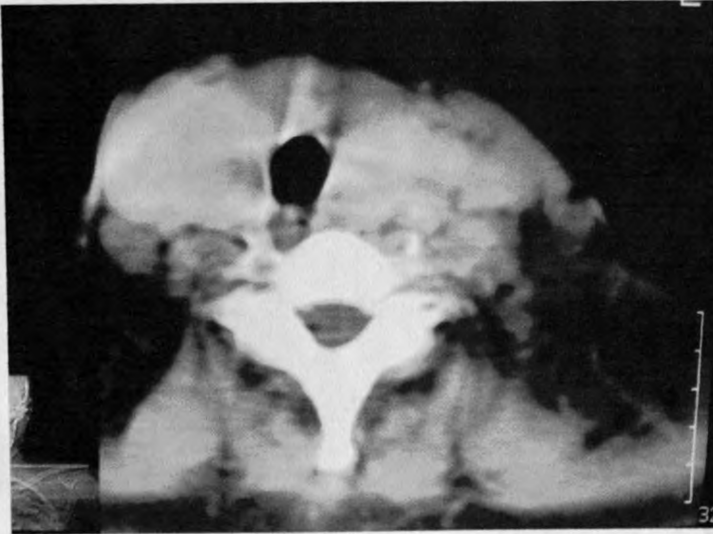
NECT



CECT

Thyroid mass? Lymphoma

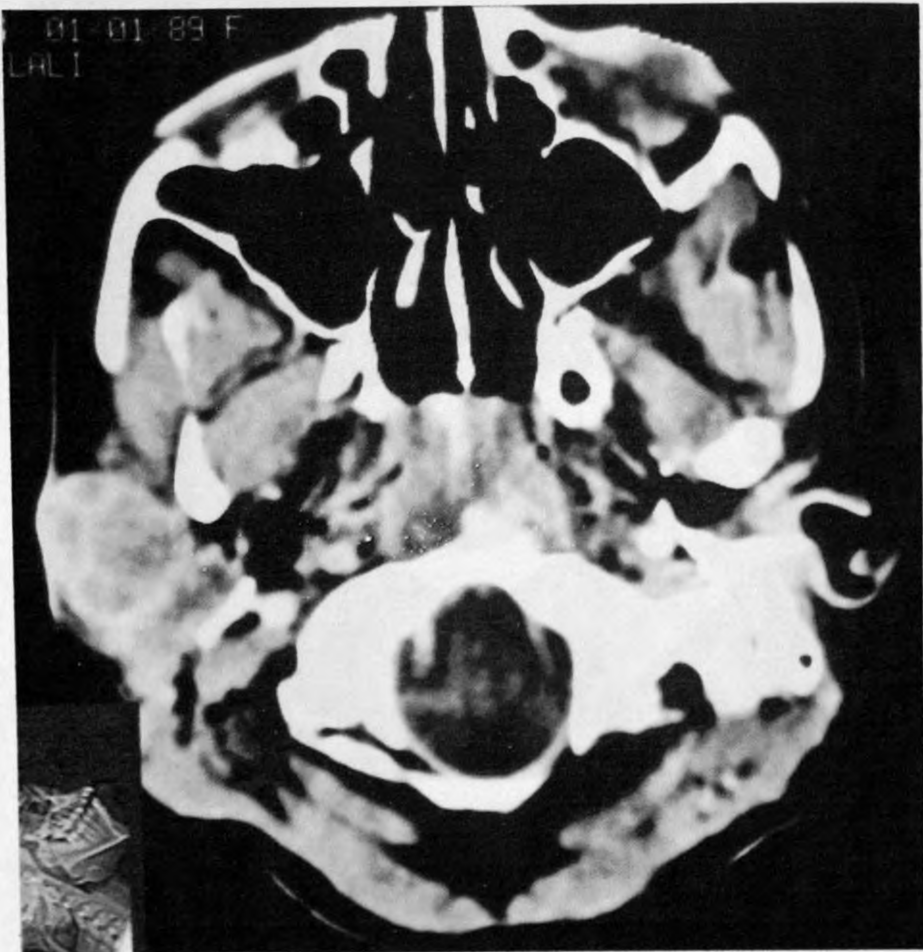
One 55-year-old patient had a homogeneously enhancing, diffusely enlarged thyroid gland, with retrosternal extension. Associated level 2 and 4 lymph nodes showing rim enhancement were also seen. This was histologically defined as a mass with dispersed lymphocytes; however, no follicular cells were identified.



Parotid Lymphadenopathy

One 12-year-old female patient had a mixed density mass involving the superficial lobe of the right parotid gland that showed enhancement of septations on post contrast scans.

This was histologically described as lymph nodes showing salivary gland tissue exhibiting Askanazy cell changes.

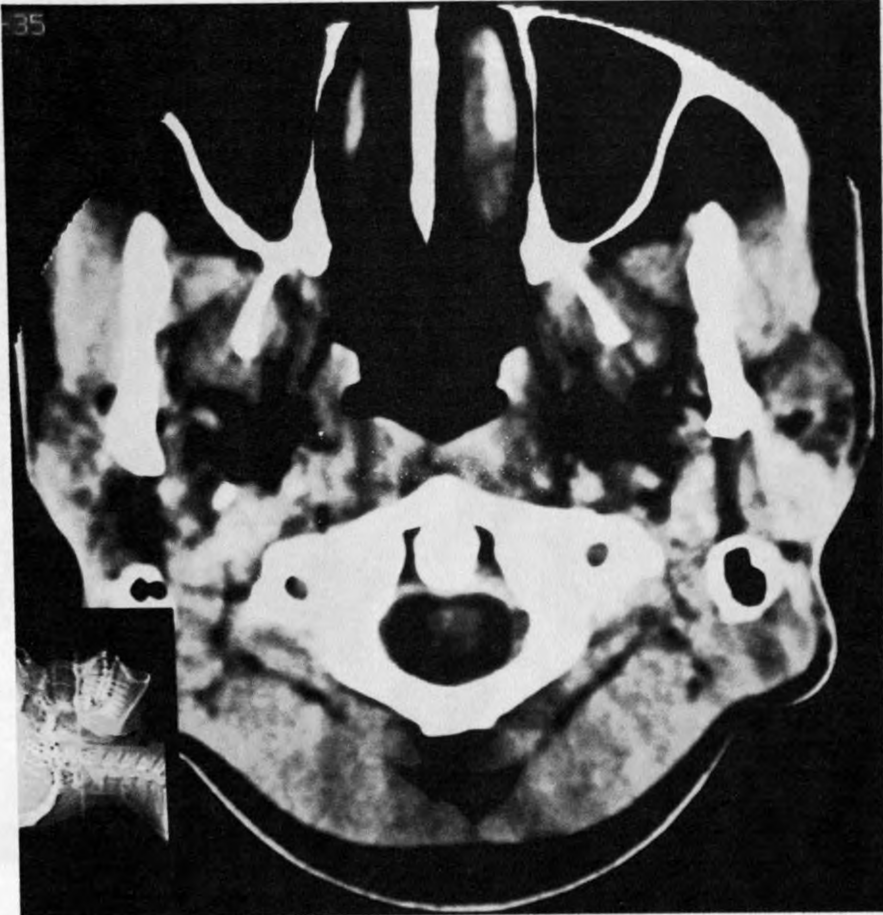


NECT

Parotid Gland Simple Cyst

Multiple, rounded enhancing densities involving both the superficial and deep lobes of the left parotid gland were demonstrated in one 23-year-old male patient.

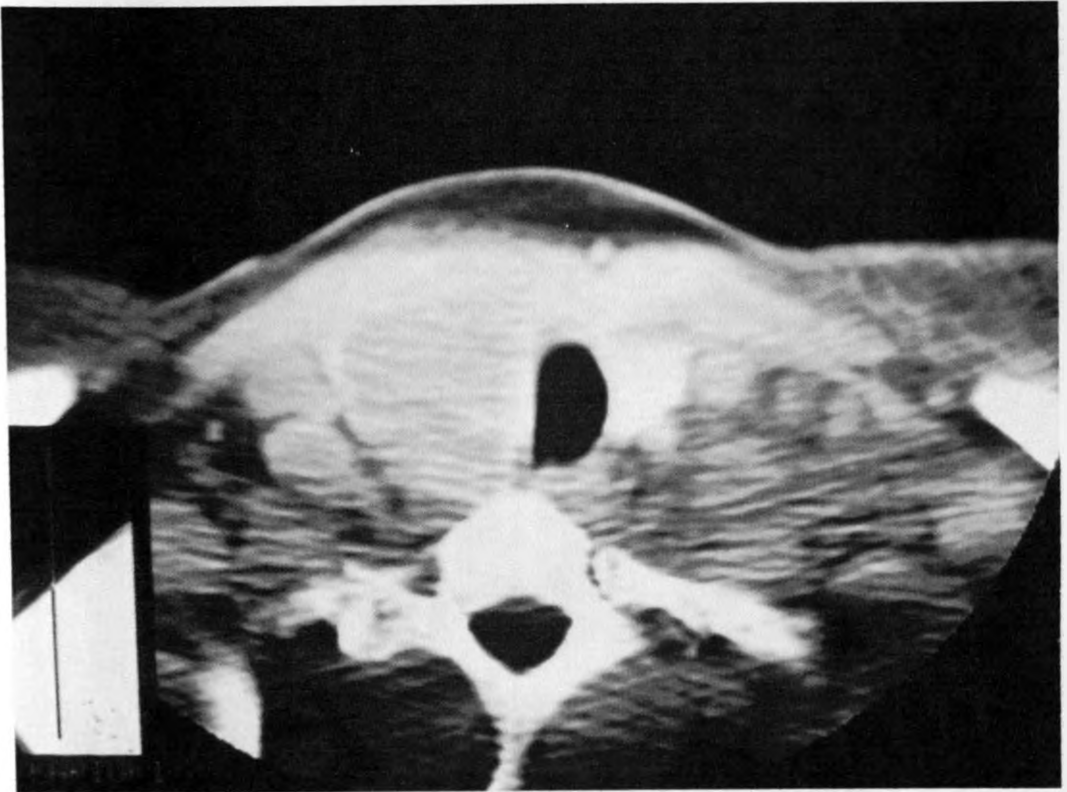
These were confirmed histologically to be simple cysts.



NECT

Metastatic Ductal Carcinoma of the Breast

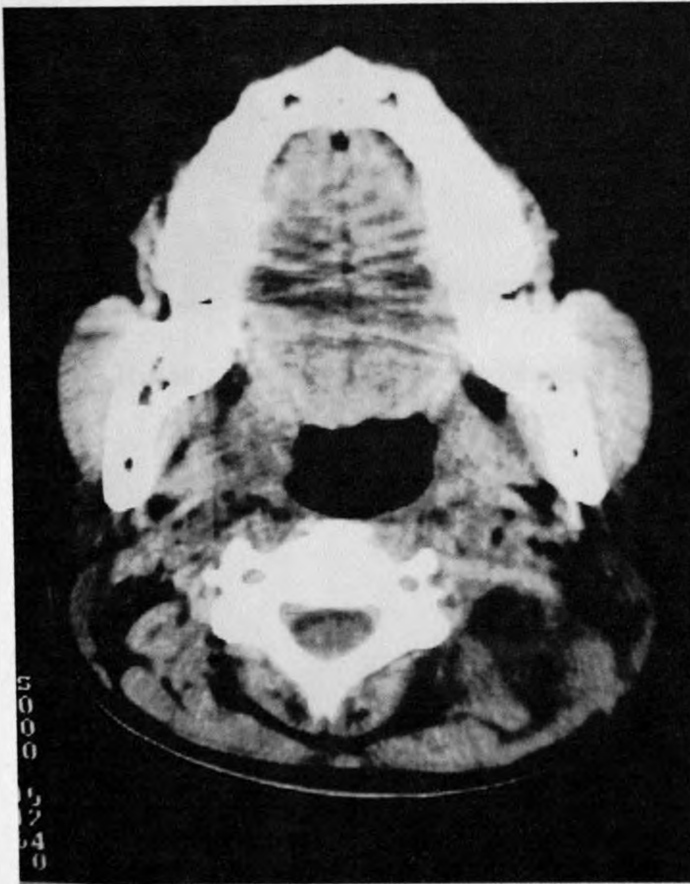One 34-year-old female patient known to have carcinoma of the breast had multiple rim enhancing masses on the right of the trachea in the region of the right thyroid lobe. These were histologically confirmed to be metastatic lymph nodes of the breast carcinoma.



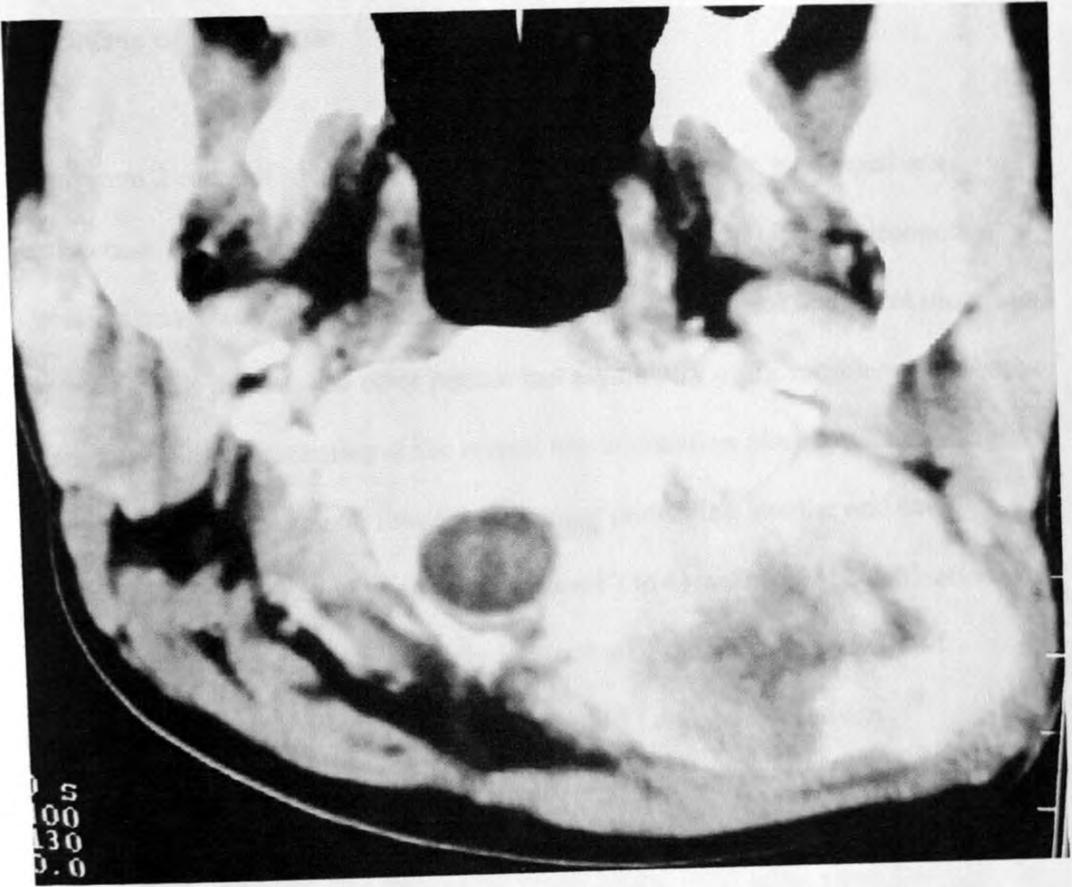
CECT

Hemangioendothelioma

A large, heterogeneously enhancing soft tissue mass was identified involving the left posterior perivertebral space in the region of the erector spinae muscle complex, extending from the level of vertebrae C1 to C4 in a 19 year old patient. Likely erosion of the posterior arch of C1 vertebra with minimal intraspinal extension was also noted. The lesion was histologically defined to be a hemangioendothelioma.



NECT



CECT - Histologically confirmed hemangioendothelioma

Carcinoma of the Tongue

There were 2 cases of squamous cell carcinoma of the tongue, with equal sex distribution. One patient had bilateral level 1 (submandibular) lymphadenopathy identified on the scan. A clinically and histologically confirmed malignant ulcer was reported in this patient. The other patient had asymmetry of the muscles of the base of the tongue with displacement of the central low attenuation plane towards the right. There was an associated soft tissue tongue mass protruding into the oral cavity. Bilateral, extensive, matted lymph nodes (Level 2 to 4) with foci of calcification were also seen in the latter case, with likely infiltration of the adjacent muscles of mastication on the right. The patients were aged 52 and 46 respectively.

Inflammatory Pharyngeal Polyps

Three polypoid soft tissue density masses, two in the oropharynx and one in the nasopharynx were seen in a 48-year-old male patient, all confirmed histologically to be simple inflammatory polyps.

Kaposi Sarcoma

One 27 year old female patient had a ? palatal soft tissue swelling with associated level 1 (submandibular) and level 2, discrete, rim enhancing lymph nodes; a case of histologically confirmed Kaposi sarcoma.

TABLE 1: LESIONS CORRECTLY IDENTIFIED AT CT

PATHOLOGY	IDENTIFIED BY	CORRECTLY IDENTIFIED
	HISTOLOGY	BY CT
Tumors of the larynx /hypopharynx	13	13
Nasopharyngeal Tumors	11	11
Lymphomas	4	4
Tumors of the Tongue	2	1
Branchial Cleft Cysts	1	1
Cystic Hygromas	1	1
Pharyngeal Mucosal Adenoids	1	0
Kaposi Sarcoma	1	0
Parotid Lymphadenopathy	1	1
Submandibular Abscess	1	1
Simple Cyst, Parotid Gland	1	0
Thyroid Tumor/Mass	2	1
Metastatic Breast Tumor	1	0
Pharyngeal Mucosal Polyps	1	1
Hemangioendothelioma	1	0
TOTAL	42	35

DISCUSSION

Laryngeal and hypopharyngeal tumors

All patients in this study who had laryngeal and hypopharyngeal carcinomas had histologically confirmed squamous cell carcinomas, all located at the mucosal surface and thus easily accessible by direct laryngoscopy for biopsy. Submucosal extension, infiltration of deep anatomical structures and lymph node metastases, all of which had implications for treatment and prognosis required cross-sectional imaging by CT. A marked male predilection and mean age of 55 years was also noted.

Approximately 95% of laryngeal and hypopharyngeal tumors are squamous cell carcinomas^{12, 37, 38}. CT scanning accurately demonstrates the anatomical location and gross size of laryngeal tumors^{34, 36, 39}. Until recently, CT was long considered to be insensitive to cartilage invasion. Results of a radiologic-pathologic study by Kurt ad Becker (2000)¹¹ indicate that four different diagnostic signs are recommended to detect neoplastic invasion of laryngeal cartilage on CT, namely extralaryngeal tumor spread (specificity = 95%), sclerosis (specificity = 65%), erosion and lysis (specificity = 93%)^{13, 15}. Using the combination of all four criteria an overall sensitivity as high as 91% may be obtained, with an NPV of 95%. However, this only has a specificity of 68 %¹¹.

Lesions in this region occur in men almost 5 times more commonly than in women and the peak incidence is in the 7th decade⁴⁰.

The study revealed that, in keeping with earlier studies, squamous cell carcinoma is the commonest histological type of laryngeal/hypopharyngeal tumor encountered with predominance in the male population. The mean age at Kenyatta National Hospital was however in the 6th decade, while the worldwide peak incidence is in the 7th decade.

Nasopharyngeal carcinomas

Of the 11 cases reviewed with histologically confirmed NPC, 7 had undifferentiated (anaplastic) carcinomas [UC]. The rest (4) had non-keratinizing carcinoma [NKC]. The mean age for UC was 42 years while that for NKC was 41 years. A slight male predominance was also noted.

Inflammation of the lymphoid tissue of the pharyngeal mucosal space may result in nasopharyngeal soft tissue density mass lesions as seen in one case in this study and could not be distinguished from NPC at imaging. This was histologically confirmed to be adenoidopathy.

WHO classifies NPC into 3 types – keratinizing squamous cell carcinomas [KSC] (Type 1), non-keratinizing carcinoma [NKC] (Type 2) and undifferentiated (anaplastic) carcinoma [UC] (Type 3). WHO type 1 and 2 NPC are predominantly cancers of adults, being rare in children¹⁶. However, UC show a bimodal distribution with peaks in the 2nd and 6th decades, and have been reported in children. There is a male predilection (2-3:1), a feature noted in this study.

This study revealed that NPCs predominantly occurred in the adult population with a slight male predominance, all in keeping with earlier studies by Shanmugratnam K. et al¹⁶.

CT is the most established and widely used staging method, adequately delineating the primary tumor in most cases¹⁷. This, however, is better defined on MRI, the strength of which is most evident in demonstrating perineural infiltration or intracranial extension^{18,19}.

Nodal Masses – Nodal Metastases and Lymphoma

When imaging the neck, size-based criteria, nodal shape criteria, nodal clusters, internal nodal architecture and extranodal/extracapsular spread are applied at CT. Assessment of individual nodal size or shape was, however, difficult in view of the fact that most of the cases reviewed had matted ill-defined clusters of lymph nodes. Low density centres with rim enhancement were demonstrated in the contrast enhanced CT images. The necrotic appearance of these nodal masses on CT pathologically represents both tumor cell and interstitial fluid. Central nodal necrosis is regarded to be the most reliable imaging finding of metastatic disease, regardless of lymph node size¹¹. Extranodal tumor spread was also noted as evidenced from rim enhancement of the irregular nodal margins and infiltration of adjacent fatty tissue. Homogeneity was the rule in the three cases of lymph nodes involved in histologically confirmed lymphomas. Cervical lymphadenopathy is more accurately assessed by CT than by MRI especially in the presence of extracapsular spread and metastatic nodal necrosis^{20, 31}.

Branchial cleft anomalies

A unilocular cystic mass (15.5HU) posterior to the right mandibular angle with irregular capsular enhancement was demonstrated at CT and confirmed histologically to be an infected branchial cleft cyst.

Ninety-five percent of all branchial cleft anomalies arise from the remnant of the second branchial apparatus²². Any permutation of cyst, sinus or fistula is possible. The most common is a cystic mass without sinus or fistula, similar to the one case seen in this study. The most common location of a second branchial cleft cyst is at the angle of the mandible, posterolateral to the submandibular gland, lateral to the

carotid artery and anteromedial to the sternocleidomastoid. When present, a beak pointing medially between the internal and external carotid arteries is pathognomonic of a second branchial cleft cyst¹¹. These occur either in the infant or young adult. CT reveals a unilocular cystic mass of CSF density. Uniform thin peripheral capsular enhancement is characteristic. Thickening or irregular capsular enhancement is seen in infected cysts¹¹, a feature seen in the case reviewed and confirmed histologically. The reviewed lesion was thus found in the characteristic age-group and location with characteristic features of secondary infection.

Cystic lymphangiomas (cystic hygromas)

A low density cystic mass that showed peripheral enhancement was demonstrated in the left posterior cervical space with extension into the mediastinum and was histologically proven to be an infected cystic hygroma.

Cystic lymphangiomas (cystic hygromas) are composed of large dilated lymphatic vessels ranging in diameter from a few millimetres to several centimetres.^{23, 26} Most arise from the posterior cervical space and up to 10% of all cervical cystic hygromas extend into the mediastinum^{23, 26}. The latter feature was noted in the case reviewed in this study. Ninety percent of lymphangiomas become clinically apparent by 2 years of age, while 10% present as neck masses in the young adult¹¹ as was noted in the case reviewed of a 17-year-old patient. CT reveals a multi-septated cystic mass that insinuates itself in and around normal structures.

The lesion reviewed in this study was in the typical location and showed characteristic features of infection. However, it was demonstrated in a 17 year-old patient, a feature seen only in about 10% of cases¹¹.

Salivary Gland Abscesses

A rim enhancing hypodense lesion in the left submandibular space was demonstrated at CT and confirmed histologically to be a submandibular abscess.

Submandibular gland abscesses seen on CT as rim enhancing hypodense lesions involving the submandibular gland are associated with skin thickening, edema of the fat and gas in 50% of cases. The former (rim enhancing hypodense lesion and associated skin thickening) were well appreciated in the case reviewed.

MRI has replaced CT scanning for the imaging evaluation of most masses in the major salivary glands³². Inflammatory lesions or calculi are most common in the submandibular gland. However, approximately 80% of major salivary gland tumors occur in the parotid gland³².

Thyroid masses/lesions

Two thyroid masses were identified at CT during the study. One case revealed an enlarged hypodense thyroid gland with intense uniform enhancement while the other had a homogeneously enhancing, diffusely enlarged isodense thyroid gland with retrosternal extension. The latter case showed associated lymphadenopathy (level 2 and 4 with rim enhancement). Only the former case was conclusively identified at histology as follicular carcinoma of the thyroid gland while the latter was described as a mass with dispersed lymphocytes ? lymphoma. Equal sex distribution and a mean age of 60.5 years were noted

Follicular carcinomas represent 15-20% of thyroid malignancies⁷ and more commonly spread hematogenously than through lymphatics. Lymphoma of the thyroid may be primary or secondary. Primary lymphomas comprise 8% of thyroid malignancies⁷ and are usually seen in middle aged and elderly patients. Women are

more frequently affected²⁴. Systemic lymphoma present as large homogenous masses often infiltrating neighboring structures.

Although ultrasound and radionuclide scintigraphy are the primary imaging modalities in assessing thyroid masses, CT is useful for confirming the location of the mass within the gland, establishing intrathoracic extension, evaluating nodal disease, and assessing the airway⁷. Differentiation between benign and malignant primary thyroid masses is impossible on imaging although associated lymphadenopathy, vocal cord paralysis, and bone or cartilage invasion obviously suggests malignancy⁷.

Carcinoma of the Tongue

Two cases of histologically confirmed squamous cell carcinoma of the tongue were reviewed in this study, the major finding being associated lymphadenopathy in both cases. Equal sex distribution and a mean age of 48 years were noted. No tongue mass was demonstrated in one case while the other had a soft tissue tongue mass protruding into the oral cavity with asymmetry of muscles of the tongue base and displacement of the central low attenuation plane towards the right.

More than 90% of malignant tumors of the oral cavity are squamous cell carcinomas⁴². Squamous cell carcinomas of the base of the tongue are aggressive, deeply infiltrative, moderately to poorly differentiated neoplasms. There is a 75% incidence of lymph node metastasis at presentation (33-50% of which are bilateral) due to a rich lymphatic network⁴². The most commonly involved lymph nodes are the jugulodigastric, jugulo-omohyoid, and the more cephalad lymph nodes of the internal jugular chain (level 2 and 3 nodes). Occult metastatic disease is present in 10-20% of clinically normal lymph nodes^{27,41}.

Hemangioendotheliomas

A large, heterogeneously enhancing soft tissue mass was identified in the left posterior perivertebral space, extending from the level of vertebrae C1 to C4 in a 19 year old patient. Likely erosion of the posterior arch of C1 vertebra with minimal intraspinal extension was also noted. The lesion was histologically defined to be a hemangioendothelioma.

Hemangioendotheliomas *are* rare, slow growing, low grade, and malignant vascular sarcomas of endothelial cell origin.

CONCLUSION

A. The spectrum of neck pathologies seen at CT with corresponding age and sex distribution consisted of:

1. The commonest pathologies seen were malignancies, with carcinoma of the larynx and nasopharyngeal carcinomas forming more than half the cases reviewed. In keeping with findings in literature, the majority of the laryngeal tumors were squamous cell carcinomas, showed a marked adult male predilection, and predominantly involved the glottis in the tumor process. Undifferentiated NPC (WHO Type 3) formed the majority of NPC cases reviewed, with a slight adult male predilection as noted in other studies of the NPC.

Other cases of malignancies reviewed included lymphomas and thyroid carcinoma both of which showed typical imaging findings on CT.

2. Congenital anomalies encountered during this study included cystic hygroma and branchial cleft cyst, both of which showed typical imaging characteristics on CT (location, extent, cystic nature) and posed little difficulty in diagnosis when imaging findings were correlated with clinical history.
3. CT imaging was accurately able to assess cervical lymphadenopathy where pathological nodes were involved either as a primary process (e.g. lymphoma) or as part of metastatic disease (e.g. laryngeal and nasopharyngeal tumors). However, the likelihood of involvement of the vessels of the carotid space, a feature of management importance, was difficult to assess due to poor visualization of vascular structures – attributed to poor enhancement in a good proportion of the images.

4. The salivary gland pathologies seen, other than the submandibular abscess, proved to be diagnostic challenges radiologically. A more extensive radiologic-pathologic correlative study to assess pathologies of the salivary glands would prove useful.

B. Assessment by CT provided a correct diagnosis in 83.3% (sensitivity of 83.3%) of the cases reviewed (see Table 2), with diagnostic difficulties being encountered in only 7 cases (16.7%). This proved CT to be a useful modality in assessment of neck pathology.

RECOMMENDATIONS

1. Neck CT should be considered as the primary imaging modality in assessment of neck disease as it proved most useful in determining the extent of disease and assessing involvement of adjacent structures in most cases seen.
2. Interpretation of neck CT using the compartment approach provides a systematic way of narrowing down possible differential diagnosis.
3. Greater efforts should be made to detect the common pathologies early, namely carcinoma of the larynx/hypopharynx and nasopharyngeal tumors. Majority of the cases seen during this study were advanced at presentation and imaging with associated lymphadenopathy being seen in nearly all the cases (21 out of 24). This would greatly improve prognosis and management.
4. A study to determine the local etiological factors contributing to the male predilection of the commoner pathologies would prove useful in aiding in their prevention.
5. Salivary gland pathologies seen proved to be diagnostic challenges radiologically. A more extensive radiologic-pathologic correlative study to assess pathologies of the salivary glands would prove useful.

APPENDIX – DATA COLLECTION FORM

- 1) Patient No. -
- 2) Age - years
- 3) Sex - M / F
- 4) Anatomical Site of Lesion (Cervical Space) as assessed by CT - (tick)
- | | |
|----------------------|--------------------------|
| Sublingual space | Masticator space |
| Submandibular space | Pharyngeal mucosal space |
| Buccal space | Visceral space |
| Parotid space | Retropharyngeal space |
| Parapharyngeal space | Posterior cervical space |
| Carotid space | Perivertebral space |
- 5) Is The Disease Process Confined To The Space? - Yes / No
- 6) Radiological Diagnosis -
- 7) Histopathologic Findings (Diagnosis) -

REFERENCES

1. Gatenby RA, Mulhern CB Jr, Strawitz J, Moldofsky PJ. Comparison of clinical and computed tomographic staging of head and neck tumors. *AJNR* 1985;6:399-401.
2. Curtin HD, Ishwaran H, Mancuso AA, Dalley RW, Caudry DJ, McNeil BJ. Comparison of CT and MR imaging in staging of neck metastases. *Radiology* 1998;207:123-130
3. Davis WL, Harnsberger HR, Smoker WRK, Watanabe AS. Retropharyngeal space: Evaluation of Normal Anatomy and Diseases with CT and MR Imaging. *Radiology* 1990;174:59-64
4. Becker M, Zbaren P, Laeng H, Stoupis C, Porcellini B, Vock P. Neoplastic Invasion of the Laryngeal Cartilage: Comparison of MR Imaging and Ct with Histopathologic Correlation. *Radiology* 1995;194:661-669
5. Reede DL, Bergeron RT, Holliday R. Contemporary imaging methodology for diagnosis of lesions of the head and upper neck. *Clin Imaging* 1989 Sep; 13(3):179-88
6. Gayler BW, Kashima HK, Martinez CR. Computed tomography of the neck. *Crit Rev Diagn Imaging* 1985;23(4):319-76
7. Lee JKT, Sagel SS, Stanley RJ, Heiken JP, editors. *Computed Body Tomography with MRI Correlation [CD-ROM]*. 3rd ed. Lippincott, Williams & Wilkins; 1998.
8. Willinsky RA, Kassel EE, Cooper PW, Chin-Sang HB, Haight J. Computed tomography of lingual thyroid—case report. *J Comp Assist Tomogr* 1987; 11:182-183.
9. Doppman JL, Shawker TH, Krudy AG, et al. Parathyroid: CT, US, and angiographic findings. *Radiology* 1985;157:419-423.
10. Wolfgang Dähnert. *Radiology Review Manual*. 5th ed. Lippincott, Williams & Wilkins; 2003; 364
11. Becker, Kurt AM. Infrahyoid neck: CT and MR-imaging versus histopathology. *Eur. Radiol* 2000;10 Suppl 2:S53-S68
12. Som PM, Brandwein M. Salivary glands. In: Som PM, Curtin HD, editors. *Head and neck imaging*. 3rd ed. St. Louis: CV Mosby; 1996; 823-914.
13. Becker M. Larynx and hypopharynx. *Radiol. Clin. North Am* 1998; 36(5): 891-920
14. Casselman JW, Biebau G. Imaging of laryngeal cancer. *Acta Oto-rhinolaryngol Bel.* 1992;46:161-174.
15. Becker M, Zbären P, Delavelle J et al. Neoplastic invasion of laryngeal cartilage: reassessment of criteria for diagnosis at CT. *Radiology* 2003:521-532
16. Shanmugratnam K, Chan SH, de-Thé, et al. Histopathology of Nasopharyngeal carcinoma: correlations with epidemiology, survival rates and other biological characteristics. *Cancer* 1979;44:109-1044
17. Chong VFH, Tsao SY. *Nasopharyngeal Carcinoma*. 1997: 53-58
18. Chong VFH, Fan YF, Khoo JBK. Nasopharyngeal Carcinoma with Intracranial spread. *J Comput Tomogr* 1996;20:563-9
19. Chong VFH, Fan YF. Skull base erosion in nasopharyngeal carcinoma. Detection by CT and MRI. *Clin Radiol* 1996;51:625-31
20. Chong VFH, Fan YF, Khoo JBK. MRI features of cervical nodal necrosis in metastatic disease. *Clin Radiol* 1996;51:103-9

21. Som PM, Brandwein M, Lidov W, Lawson W, Biller HF. The varied presentations of papillary thyroid carcinoma cervical nodal disease: CT and MRI findings. *AJNR* 1994;15:1123-1128.
22. Harnsberger HR, Mancuso AA, Muraki AS et al. Branchial cleft anomalies and their mimicks: computed tomographic evaluation. *Radiology* 1984;152:739-748.
23. Zadvinski DP. Congenital malformations of the cervicothoracic lymphatic system: Embryology and pathogenesis. *Radiographics* 1992;12:1175-1189
24. Logue JP, Hale RJ, Stewart AL, Duthie MB, Banerjee SS. Primary malignant lymphoma of the thyroid: a clinicopathological analysis. *Int J Radiat Oncol Biol Phys* 1992;22:929-933.
25. Freitas JE, Freitas AE. Thyroid and parathyroid imaging. *Semin Nucl Med* 1994; 24:234-245.
26. Reede DL. Nodal and non-nodal masses. In: Som PM, Curtin HD, Holliday RA, editors. *A special course in head and neck radiology*. RSNA Inc. Oak Brook, Illinois; 1996:75-85
27. Som PM. Lymph nodes of the neck. *Radiology* 1987c;165:593-600.
28. Som PM. Detection of metastasis in cervical lymph nodes: CT and MRI criteria and differential diagnosis. *AJR* 1992;158:961-969.
29. van den Brekel MWM, Stel HV, Castelijns JA, et al. Cervical lymph node metastasis: assessment of radiologic criteria. *Radiology* 1990;177:379-384.
30. Johnson JT. *A surgeon looks at cervical lymph nodes*. *Radiology* 1990; 175:607-610.
31. Yousem DM, Som PM, Hackney DB, Schwaibold F, Hendrix RA. Central nodal necrosis and extracapsular neoplastic spread in cervical lymph nodes: MRI imaging versus CT. *Radiology* 1992;182:753-759.
32. Yoshimi A, Villablanca JP, El-Saden SM, Kioumehri F, Lufkin RB, Hanafee WH. *Clinical Aspects of Magnetic Resonance Imaging: Magnetic Resonance Imaging of the Head and Neck*. 259-282
33. Moreau P, Goffart Y, Collignon J. Computed tomography of metastatic cervical lymph nodes. A clinical, computed tomographic, pathologic correlative study. *Arch Otolaryngol Head Neck Surg* 1990 Oct;116(10):1190-3
34. Mafee MF, Schild JA, Valvassori GE, Capek V. Computed tomography of the larynx: correlation with anatomic and pathologic studies in cases of laryngeal carcinoma. *Radiology* 1983 Apr;147(1):123-8
35. Saleh EM, Mancuso AA, Stringer SP. Relative roles of computed tomography and endoscopy for determining the inferior extent of pyriform sinus carcinoma: correlative histopathologic study. *Head Neck* 1993 Jan-Feb;15(1):44-52
36. Silverman PM, Bossen EH, Fisher SR, Cole TB, Korobkin M, Halvorsen RA. Carcinoma of the larynx and hypopharynx: computed tomographic- histopathologic correlations. *Radiology* 1984;151: 697-702
37. Batsakis JG. *Tumors of the head and neck. Clinical and pathologic considerations*. 2nd ed. Williams and Wilkins; Baltimore; 1979.
38. Becker M, Moulin G, Kurt AM et al. Non-squamous cell neoplasms of the larynx: radiologic-pathologic correlation. *Radiographics* 1988;18(5):1189-1209
39. Schild JA, Valvassori GE, Mafee MF, Bardawil WA. Laryngeal malignancies and computerized tomography. A correlation of tomographic and

- histopathologic findings. *Ann Otol Rhinol Laryngol* 1982 Nov-Dec; 91(6Pt1): 571-5
40. Sasaki CT, Carlson RD. Malignant neoplasms of the larynx. In: Cummings CW, Frederickson JM, Harker LA, Krause CJ, Schuller DE, editors. *Otolaryngology – Head and Neck Surgery*. St. Louise: CV Morsby; 1993. p. 1925-54.
 41. Wang CC. *Radiation Therapy for Neck Lesions: Indications, Techniques and Results*. Chicago: Year Book Medical Publishers; 1990.
 42. Taveras JM, Ferruci JT, editors. *Radiology [CD-ROM], Diagnosis.Imaging.Intervention*. Lippincott, Williams & Wilkins; 2001.

UNIVERSITY OF NAIROBI
MEDICAL LIBRARY