

(i)

TITLE:

SOME ASPECTS OF HEPATOCELLULAR CARCINOMA AND LIVER  
CIRRHOSIS IN KENYA.

A DISSERTATION SUBMITTED IN PART-FULFILMENT FOR THE  
DEGREE OF MASTER OF MEDICINE (PATHOLOGY)  
UNIVERSITY OF NAIROBI

BY  
DR. JANE MWANGI  
MBCHB(NAIROBI)


University of NAIROBI Library




0324663 4

DECLARATION

This work is original and has not to my knowledge been submitted for a degree in any other University.

  
DR. JANE. MWANGI

This dissertation has been submitted for examination with my approval as the University supervisor

  
.....  
PROFESSOR D.G. GATEI, O.G.W., M.B.Ch.B.(E.A.);  
F.R.C.Path.(U.K.)

ACKNOWLEDGEMENTS

I would like to thank the following to whom I am greatly indebted and without whom this work would not have been possible.

- 1) Professor D.G. Gatei for guidance, supervision and support throughout this project.
- 2) The University of Manitoba - Canada for donating the staining reagents.
- 3) Professor Norman Pettigrew of the University of Manitoba, Canada for his advice and assistance on the methodology.
- 4) Mr. Titus Shiramba, Mrs. Susan Sitati and Mr. John Boro for technical assistance.
- 5) My family; Mwangi, Mucheru and Wambui for their patience and understanding while I was deeply involved in this work.
- 6) Professor P.J. Ojwang for reading the manuscript.
- 7) Mrs. Jane Karanja for typing and re-typing the manuscript.

CONTENTS

Title .....	(i)
Declaration .....	(ii)
Acknowledgement .....	(iii)
Contents .....	(iv)
List of tables and figures .....	(v)
Abbreviations .....	(vi)
Summary .....	1
1. Introduction .....	2
2. Hypothesis and objectives .....	6
3. Materials and Methods .....	7
4. Results .....	8
4.1 Staining Characteristics .....	8
4.2 Analysis of results .....	13
5. Discussion:	
5.1 Discussion of results .....	20
5.2 Constraints .....	22
5.3 Aetiology of hepatocellular carcinoma .....	23
5.4 Prevention of HBV associated HCC and cirrhosis .....	25
6. Conclusions .....	26
7. Recommendations .....	27
8. Appendices:	
8.1 Appendix 1 .....	28
8.2 Appendix 2 .....	29
8.3 Appendix 3 .....	30
References .....	32

LIST OF FIGURES, PLATES AND TABLES

	Page
Figure 1: Schematic presentation of mechanism of PAP for HBSAg	5
Plate 1: Immunoperoxidase stain for HBSAg x 200	9
Plate 2: Immunoperoxidase stain for HBSAg x 400	10
Plate 3: Orcein stain for HBSAg x 400	11
Plate 4: Immunoperoxidase stain for HBCAg x 400	12
Table 1: Comparison of HBV component positivity in HCC biopsies with some non-neoplastic tissue and HCC biopsies consisting wholly of tumour tissue.	14
Table 2: Comparison of HBV positivity in HCC and cirrhosis.	15
Table 3: Comparison of HBCAg positivity in HBSAg positive HCC and cirrhosis.	16
Table 4: Comparison of HBV components positivity in HCC with and without associated cirrhosis	17
Table 5: Comparison of positivity for HBV components in needle biopsies and open biopsies or autopsy specimens with hepatocellular carcinoma.	18
Table 6: Comparison of HBV component positivity in needle biopsies and open biopsies or autopsy specimens with cirrhosis.	19

Abbreviations

- HBCAg - Hepatitis B core antigen
- HBSAg - Hepatitis B surface antigen
- HBV - Hepatitis B virus
- HCC - Hepatocellular carcinoma
- PAP - Peroxidase-anti-Peroxidase

## SUMMARY

The main aim of this study was to examine the role played by Hepatitis B Virus in the causation of hepatocellular carcinoma and liver cirrhosis in Kenya.

Liver biopsy samples were stained by the orcein histochemical method and peroxidase-anti-peroxidase immunohistochemical method to check for the presence of Hepatitis B surface antigen and Hepatitis B core antigen. The study included 108 cases of hepatocellular carcinoma, 35 cases of liver cirrhosis and 40 normal liver biopsies.

Analysis of the results revealed the following important facts:

- 1) Only 2.5% of normal livers had HBSAg.
- 2) In contrast 33% of hepatocellular carcinoma and 26% of liver cirrhosis cases had HBSAg.
- 3) Background cirrhosis was found in 52% of HCC cases.
- 4) Positivity of HBSAg is more demonstrable in open liver biopsies than in needle biopsies; about 44% positivity as opposed to 10% in cirrhosis respectively.
- 5) Cases of liver cirrhosis show a higher positivity for HBCAg than HCC cases; 14% and 11.5% respectively. More cases of cirrhosis were positive for both HBSAg and HBCAg than HCC
- 6) This study also documents that viral antigens are randomly distributed in non-neoplastic tissue and therefore its demonstration is proportional to the amount of tissue examined.
- 7) Survival of the antigen in tissue depends on the type and concentration of fixative, fixation time and size of specimen. The antigen is destroyed or altered at temperatures above 60°C.
- 8) The orcein histochemical stain is as sensitive as the Peroxidase-anti-Peroxidase immunohistochemical stain in the detection of HBSAg.

Current views on the aetiology of hepatocellular carcinoma are discussed and preventive measures suggested.

## 1. INTRODUCTION

Hepatocellular carcinoma is among the ten most common cancers in the world and one of the most prevalent cancers in developing countries. It is estimated that there are at least 250,000 new liver patients every year<sup>(1)</sup>. Mortality is 100% and the incidence continues to rise both in developing and developed countries. Hepatocellular carcinoma (HCC) is the commonest of the malignant tumours of the liver. Other primary liver malignancies are rare and include cholangiosarcoma, angiosarcoma and hepatoblastoma.

There is much geographical variation in the incidence of HCC. In tropical Africa, South East Asia and the Western Pacific regions rates of 12 - 150 per 100,000 have been reported<sup>(2,3,4)</sup>. It is however relatively uncommon in the developed countries of Europe, America and Australia. In Kenya HCC is the third commonest solid cancer in males after skin cancer and lymphoma. The male:female ratio is 9:1 and the peak age incidence is 35-45 yr<sup>(5)</sup>. This is in contrast to the developed countries where the peak age incidence is 65-75 yr. There is a striking worldwide correlation between the prevalence of Hepatitis B surface antigen (HBSAg) chronic carriers and the incidence of hepatocellular carcinoma. Epidemiological data from case control and cohort studies and several laboratory investigations indicate that there is a consistent and specific causal association between Hepatitis B virus (HBV) and hepatocellular carcinoma and that upto 80% of such cancers are attributable to the virus.<sup>(1)</sup> Hepatitis B virus is thus second only to tobacco among known human associated carcinogens.

Hepatitis B virus was discovered by Blumberg in 1965<sup>(6)</sup>. It belongs to a group of animal viruses known as hapadnaviridae and measures 42nm in diameter. It consists of an envelop and nucleocapsid containing a circular DNA molecule, DNA polymerase, a DNA linked protein and a protein kinase. The envelop carries the HBSAg while the capsid carries the hepatitis B core antigen (HBCAg).



Hepatitis B surface antigen is a conformational antigen being a dimer of two major proteins linked by disulphide bridges.

In a study carried out by Beasley et al<sup>(7)</sup> in Taiwan, the relative risk of developing HCC for HBSAg carriers was 217 times as compared to non-carriers. The mortality rate due to HCC in HBSAg carriers was 51% compared to 2% in the control population. Among the non-carriers 90% had an HBV marker (anti HBs and/or anti HBe antibodies). The high incidence of HCC is therefore clearly related to the HBSAg chronic carrier state and not to HBV infection per se.

In a prospective study on patients with chronic liver disease, Kubo et al<sup>(8)</sup> found that HBSAg positive patients developed HCC earlier than did antigen negative patients.

In tropical Africa and Far East Asia chronic HBV carriers represent 10% or more of the population. This is associated with a high incidence of HCC in these regions.

Hepatocarcinogenesis has long been postulated to be related to cell regeneration and the subsequent malignant transformation that ensues. Anthony et al<sup>(9)</sup> demonstrated in Ugandan patients with cirrhosis that hepatocellular swelling and dysplasia were closely associated with the presence of HBSAg. They found dysplasia in 64.5% of 124 patients with HCC as compared to 1% in controls. Dysplasia was considered as a precancerous lesion and HBV infection was postulated to precede malignant change in liver cells. Farther evidence in support of the carcinogenic role of HBV has been obtained from the induction of HCC experimentally in woodchuck by inoculation with woodchuck hepatitis virus at birth. This virus belongs to the same family with HBV. Hepatitis B virus DNA sequences integrated into HBSAg positive liver tissue have been demonstrated by Southern blotting technique. In chronic carriers free viral DNA, without integration is detected while in the early stage of tumour growth both free and integrated HBV DNA sequences are found.

Brechot et al<sup>(10)</sup> have demonstrated integration of HBV DNA in over 90% of HBSAg positive HCC tumour tissue. Similar results were obtained by Shafritz and Kew in 1981, Chen et al in 1982 and Hino et al in 1984<sup>(11,12,13)</sup>.

In some cases of HCC without HBV serological markers integrated HBV DNA was found. Studies based in Kenya have shown a close association between cirrhosis, HCC and the presence of HBV markers in serum<sup>(14)</sup>. Integrated HBV DNA was detected in 41% and episomal DNA in 18% of HBSAg positive HCC liver tissue<sup>(15)</sup>.

Cirrhosis is a chronic disease of many different aetiologies resulting from long-continued loss of liver cells, with a persistent inflammatory reaction accompanied by fibrosis and compensatory reparative hyperplasia.

The high risk for malignancy associated with cirrhosis varies with geographical location, aetiology and morphology. It is highest when cirrhosis follows HBV infection. Gibson et al calculated the approximate risk for HBSAg carriers to develop cirrhosis as 16 and for these to develop HCC as 50<sup>(16)</sup>.

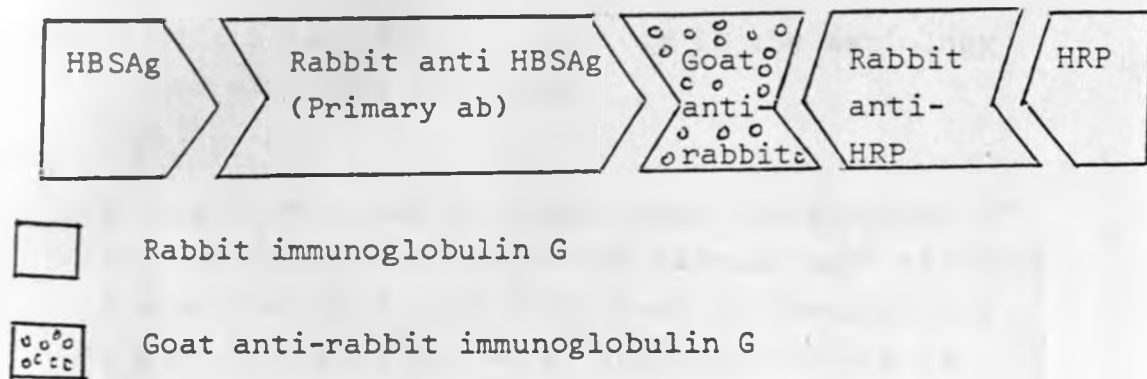
Several studies using immunofluorescent techniques, immunoelectron microscopy, histochemical and immunohistochemical methods have established that the 20 nm particles comprising HBSAg found in the sera of infected persons may be found in hepatocyte cytoplasm of infected individuals<sup>(17-25)</sup>.

Shikata and associates reported a staining method for HBSAg in paraffin sections using orcein stain<sup>(21)</sup>. Shikata's staining technique is based on the presence of disulphide bonds in HBSAg.

Immunoperoxidase methods for detection of HBV antigens have also been developed.<sup>(18)</sup>

These are based on antibody-linked histochemically demonstrable enzymes such as horseradish peroxidase. A sandwich reaction is involved in which antibody to the target antigen (primary antibody of rabbit source), antibody to the primary antibody (link antibody from goat) and peroxidase-anti-peroxidase (PAP) reagent are added sequentially with interposed washing steps. Because the PAP reagent is linked to a rabbit antibody it will be linked by the link antibody (goat anti-rabbit) to the primary antibody and tissue antigen. Horseradish peroxidase acts on the substrate diaminobenzidine to give a brown product.

Fig. 1

SCHEMATIC PRESENTATION OF MECHANISM OF PAP FOR HBSAg

## 2.1 HYPOTHESIS:

- 1) Hepatitis B infection is involved in the aetiology of hepatocellular carcinoma in Kenya.
- 2) Hepatitis B infection is involved in the aetiology of liver cirrhosis in Kenya.

## 2.2 OBJECTIVES:

This study will seek to demonstrate the presence of HBSAg and HBCAg in liver tissue samples with cirrhosis and hepatocellular carcinoma fixed in formalin and embedded in paraffin. Liver samples reported as histologically normal will serve as controls.

## 2.3 SPECIFIC OBJECTIVES:

- 1) To compare HBSAg and HBCAg positivity in hepatocellular carcinoma, cirrhosis and normal liver tissue.
- 2) To examine the level of HBCAg positivity in HBSAg positive cirrhosis and hepatocellular carcinoma.
- 3) To compare HBV components positivity in hepatocellular carcinoma with cirrhosis and that without associated cirrhosis.
- 4) To compare HBV components positivity in needle biopsies and open biopsies or autopsy specimens.

### 3. MATERIALS AND METHODS

Liver tissues processed at the Kenyatta National Hospital Department of Human Pathology in the period 1980 - 1984 were examined. Previous records were used to identify those specimens on which a diagnosis of hepatocellular carcinoma, cirrhosis or normal were made. Paraffin blocks of these tissues were retrieved from the store, cut into 5um thick sections, de-waxed and stained variously with Haematoxylin and Eosin, orcein and by immunoperoxidase techniques.

The standard Haematoxylin and Eosin staining method was used<sup>(26)</sup>. See Appendix 1. These sections were examined to confirm the previous histological diagnosis. The orcein stain according to Shikata et al<sup>(21)</sup> was used to demonstrate HBSAg - Appendix 2.

Immunoenzymatic staining kits for HBSAg and HBCAg from Dakopatts were used for immunological detection of the respective antigens. These kits are designed to demonstrate antigens primarily in formalin-fixed paraffin embedded tissues. See Appendix 3 for methodology.

#### 4. RESULTS

A total of 183 specimens were included in the study. These consisted of 108 cases of hepatocellular carcinoma, 35 cases of liver cirrhosis and 40 cases of histologically normal livers.

##### 4.1 Staining characteristics

The orcein stain showed up HBSAg as dark brown homogenous or granular intra-cytoplasmic material. The antigen assumed various forms including dense spherical bodies, linear bodies, sickled bodies and sometimes just a brown dusting. In some instances the stained material was vacuolated.

The immunoperoxidase HBSAg stain consistently identified the same antigen as the orcein stain. The antigen stained as brown homogenous or granular material in the cytoplasm against a light blue background or negative cells. This indicates that the two methods have similar sensitivity. The orcein stain was taken up by elastic tissue, red blood cells and dense nuclei or nuclear material. These could however be clearly distinguished from the HBSAg in hepatocytes.

Hepatitis B core antigen was found expressed predominantly in the nuclei of hepatocytes although variable amounts were occasionally seen in the perinuclear cytoplasm. Positive nuclei stained reddish-brown against the light blue staining cytoplasm and clear negative nuclei.

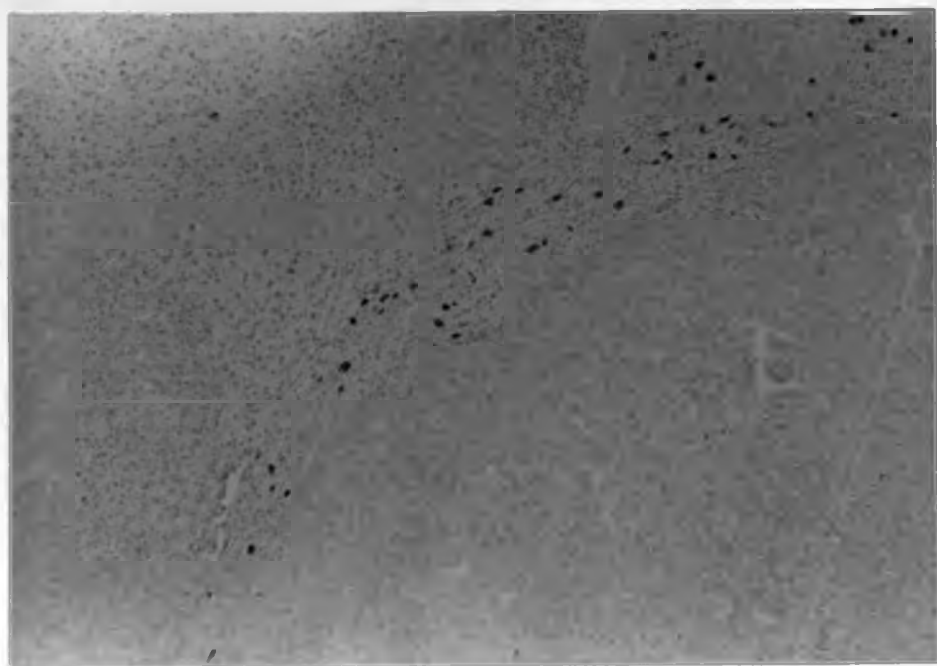
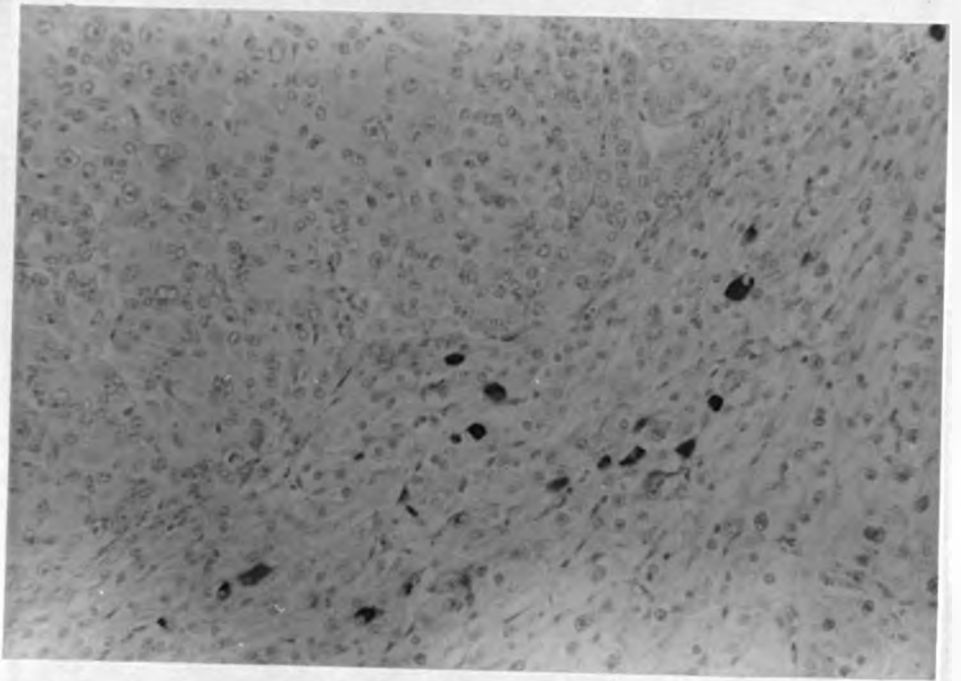


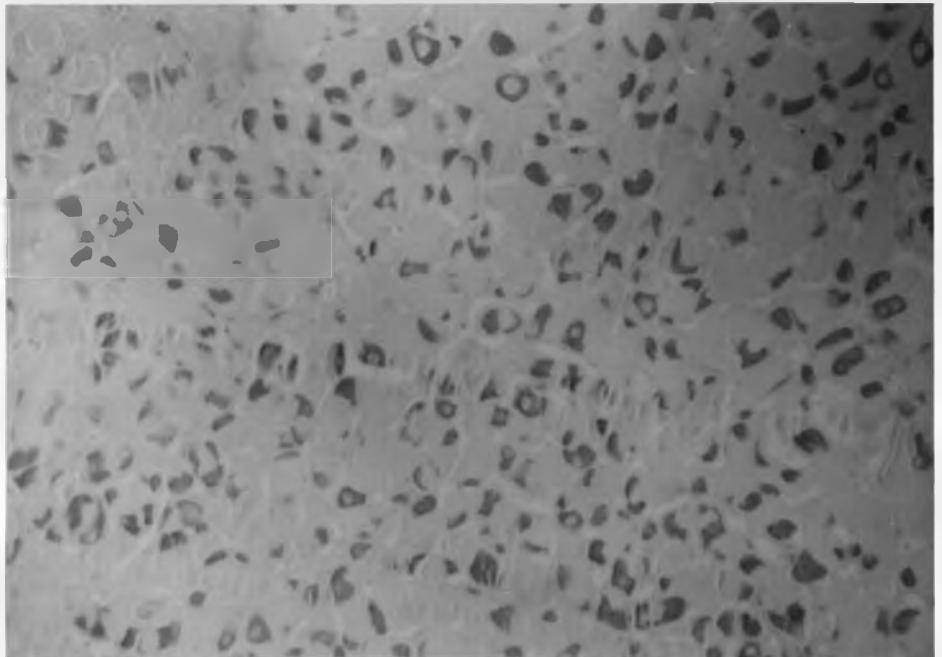
Plate 1: Immunoperoxidase stain for HBSAg  
X 200



**Plate 2: Immunoperoxidase stain for HBSAg**


**X 400**





**Plate 3: Orcein stain for HBSAg**

**x 400**



**Plate 4: Immunoperoxidase stain for HBCAg**

**X 400**

ANALYSIS OF RESULTS

The results were analysed using the Chi Square test and significance determined at 5% level of significance.

Positivity for HBV components in HCC liver biopsies with some non-neoplastic tissue and HCC liver biopsies consisting wholly of tumour tissue was examined. It can be seen from table 1 that of the 108 cases of hepatocellular carcinoma 56 consisted wholly of neoplastic tissue and no antigens were detected in these specimens. In the 52 cases with some non-neoplastic tissue antigen was detected only in the non-neoplastic parts. There were no HBV antigens in the tumour itself.

Only one of the forty control liver specimens was positive for HBSAg. None was positive for HBCAg. Hepatocellular carcinoma had a 33% HBSAg positivity rate while that for cirrhosis was 26%. This difference between HCC and cirrhosis was not statistically significant. Hepatitis B core antigen was more frequent in cirrhosis (14%) than in HCC (11.5%) but this was again not statistically significant. These findings are depicted in table 2.

Table 3 shows that Hepatitis B core antigen was present in relatively higher amounts in HBSAg positive cirrhosis (55.5%) than in HBSAg positive HCC (35%) but the difference was not statistically significant.

Hepatitis B virus component positivity in HCC with associated cirrhosis was analysed in table 4. Twenty seven (51.9%) of the 52 cases of HCC with some non-neoplastic tissue had associated cirrhosis. Seven of these were positive for HBSAg (26%) and two had HBCAg (7.4%). Twenty five of the 52 HCC cases had no associated cirrhosis. Eight of these were positive for HBSAg (32%) while four (16%) were HBCAg positive. The differences were not statistically significant.

Tables 5 and 6 compare the positivity for HBV components in needle biopsies and open biopsies or autopsy specimens with hepatocellular carcinoma and cirrhosis. A significant difference was observed in the detection of HBSAg from needle and open biopsies for both HCC and cirrhosis. This difference was not evident for the detection of HBCAg.

**TABLE 1 :**

COMPARISON OF HBV COMPONENT POSITIVITY IN HCC BIOPSIES WITH SOME  
NON-NEOPLASTIC TISSUE AND HCC BIOPSIES CONSISTING WHOLLY OF TUMOUR

HBV COMPONENT POSITIVITY	HCC WITH SOME NON-NEOPLASTIC TISSUE (n=52)	HCC WITHOUT NON-NEOPLASTIC TISSUE (ALL TUMOUR) (n=56)
HBSAg	17/52	0/56
HBCAg	6/52	0/56

TABLE 2 :

COMPARISON OF HBV COMPONENT POSITIVITY IN HCC AND CIRRHOSIS :

HBV COMPONENT POSITIVITY	HCC n=52	CIRRHOSIS n=35	$\chi^2$	P
HBSAg	17/52 (33%)	9/35 (26%)	0.486	P=0.5(not significant )
HBCAg	6/52 (11.5%)	5/35 (14%)	0.002	P=0.9(not significant)

(5% level of significance.)

TABLE 3:

COMPARISON OF HBCAg POSITIVITY IN HBSAg POSITIVE

HCC AND CIRRHOSIS :

	HBSAg POSITIVE (n=9)		$\chi^2$	P
	HCC(n=17)	CIRRHOSIS		
HBCAg	6/17 (35%)	5/9(55.5%)	0.334	0.5 P 0.6 (not significant)

(5% LEVEL OF SIGNIFICANCE)

TABLE 4:

COMPARISON OF HBV COMPONENTS POSITIVITY IN HCC WITH AND  
WITHOUT ASSOCIATED CIRRHOSIS:

HBV COMPONENT POSITIVITY	HCC WITH CIRRHOSIS (n=27)	HCC WITHOUT CIRRHOSIS (n=25)	$\chi^2$	P
HBSAg	7/27(26%)	8/25(32%)	0.36	P=0.6 (Not significant)
HBCAg	2/27(7.4%)	4/25(16%)	0.94	P=0.3 (Not significant)

TABLE 5:

COMPARISON OF POSITIVITY FOR HBV COMPONENTS IN NEEDLE BIOPSIES AND OPEN BIOPSIES OR AUTOPSY SPECIMENS WITH HEPATOCELLULAR CARCINOMA.

HBV COMPONENT POSITIVITY	NEEDLE (n=28)	OPEN (n=24)	$\chi^2$	P
HBSAg	5/28 (17.9%)	12/24 (50%)	4.7	P=0.03 (Significant)
HBCAg	2/28 (7.1%)	4/24 (12.5%)	0.4	P=0.52 (not significant)



**TABLE 6:**

**COMPARISON OF HBV POSITIVITY IN NEEDLE BIOPSIES AND  
OPEN BIOPSIES OR AUTOPSY SPECIMENS WITH CIRRHOSIS:**

HBV COMPONENT POSITIVITY	NEEDLE (n=20)	OPEN (n=16)	$\chi^2$	P
HBSAg	2/20(10%)	7/16(43.7%)	3.75	P=0.05(significant)
HBCAg	1/20(5%)	4/16(25%)	1.535	P=0.2(not significant)

## 5.1

DISCUSSION

The relationship between HCC and HBV is implicit in the world-wide epidemiological data which show a highly significant excess of HBV markers in patients with HCC when compared with normal controls. In tropical Africa and Far East Asia there is a very high incidence of both the HBV carrier status and HCC. The great excess of HBV detected in HCC, 33% and cirrhosis, 26% in contrast to 2.5% in normal liver unequivocally confirms the close and specific association between HBV and HCC and cirrhosis. A similar association has been found by other workers based in Kenya such as Bagshawe et al<sup>(27)</sup>, Bowry<sup>(28)</sup>, Greenfield<sup>(15)</sup> and Wankya<sup>(29)</sup>.

Hepatitis B core antigen was detected less frequently than HBSAg. All tissues positive for HBCAg were also positive for HBSAg.

The core antigen is believed to be an indicator of active virus replication. It has been found more frequently in association with episomal viral DNA while HBSAg alone is found when viral DNA integrates into the host genome<sup>(30)</sup>. No significant difference was noted in the level of HBCAg in HCC and cirrhosis.

In the present study 52% of HCC was associated with cirrhosis. Higher figures for HCC associated with cirrhosis have been found in Europe and America<sup>(30)</sup>. It is postulated that in areas with a high incidence of HCC the virus is acquired at birth and HCC develops without preceding cirrhosis in many cases. The high rate of HBSAg in both HCC and cirrhosis suggests that the virus is involved in the aetiology of both conditions.

Viral antigens were very randomly distributed in the non-neoplastic liver tissue. In several instances screening of one block revealed no antigen while another block from the same case showed antigen in small groups of hepatocytes. The number of positive cells varied from a few individual cells randomly dispersed in the lobules to groups of clustered positive hepatocytes. The random distribution of antigens necessitates the examination of multiple samples for each case.

This study has shown a significant difference in HBV component detection between needle and open biopsies. Similar observations have been made by Okuda et al<sup>(21)</sup> and Nayak et al<sup>(24)</sup>.

Studies from India and South East Asia detected HBSAg positivity rates of above 70%.

The lower level of HBV component positivity obtained in this study could be due to various factors:

(1) The level of 33% HBSAg positivity in HCC compares well with that of 44% obtained by Greenfield<sup>(15)</sup> by detection of HBV DNA in HCC tissue. This study was based in Kenya. These figures imply that factors other than HBV may play more significant roles in the aetiology of cirrhosis and HCC in Kenya than has been previously assumed. Aflatoxin and non-A-non-B viruses could be important factors.

(2) The quantity of tissue examined in each case: More than 50% of the samples were needle biopsies and in the majority only one paraffin block was available for examination. It has been shown by various workers that the level of HBV component positivity obtained is directly proportional to the amount of tissue examine due to the random distribution of antigens. Many studies quoted in the literature have been performed using only autopsy material from which adequate tissue could be obtained<sup>(11, 12, 24, 25)</sup>.

(3) Survival of antigen in tissue depends on the type and concentration of fixative, fixation time and the size of specimen to be fixed<sup>(26, 31)</sup>. Neutral phosphate-buffered 10% formalin is recommended and the tissue should not remain in formalin for longer than 24 hours. Rapid high temperature processing destroys antigenicity and temperatures above 60°C must be avoided. This was a retrospective study using paraffin blocks prepared in 1980-1984. The conditions of formalin preparation, duration of tissue fixation and processing were not standardized. It is therefore likely that some antigenicity may have been lost during fixation with unbuffered formalin which is our standard fixative or during processing if excessively high temperatures were inadvertently used.

## 5.2

CONSTRAINTS

Several constraints were encountered during the course of this study.

Many workers have shown that a sizable amount of tissue needs to be examined before the HBV status of the specimen in question can be determined<sup>(11,12,22-26)</sup>. In this study only one paraffin block was available for most cases and this may not have been representative of the whole liver. Some blocks consisted wholly of neoplastic tissue and could not be included in the analysis of results.

This being a retrospective study the conditions of tissue fixation and processing were not standardized and some antigens may have been lost or altered.

Reagents for the immunoperoxidase method are very expensive so it was not possible to test all the samples by this method. It was however observed that the less expensive orcein stain is as sensitive as the immunoperoxidase stain in detection of HBSAg. Unfortunately there is no substitute for detection of HBCAg.

## 5.3

AETIOLOGY OF HCC

Latest evidence from both human and animal studies suggests that HCC results from an interaction of initiating (genotoxic) and promoting (epigenetic) factors in a genetically susceptible host. Hepatitis B virus may initiate a carcinogenic process early in life by promotional insertion, turning on a cellular oncogene, to form stage I cells which are held in a non-proliferative state by inhibiting chaperones produced by adjacent normal cells. Aflatoxin or other promoting factors like alcohol, tobacco and nitrosamines may then convert the initiated stage I cells to stage II cells through inhibition of intercellular communication. Stage III cells are then activated to produce clones of promoter independent HCC cells, stage IV. Mutation of chaperone receptor genes, alcohol, tobacco and hepatotropic viruses may serve as activators. Certain factors like age at exposure to antigen, immune status, hormonal status and genetic make-up play an important but as yet unspecified role<sup>(30,32,33)</sup>.

Chemical carcinogens have been observed to cause HCC in protein deficient experimental animals without an intervening cirrhosis. Protein deficiency may be synergistic in promoting HCC in man probably through alterations of immune mechanisms<sup>(32)</sup>. This may further account for the high incidence of this tumour in the developing countries.

The antigens of HBV have consistently been found in the non-tumourous liver of patients with HCC but hardly any is seen in the tumour itself. It is possible that viral replication becomes increasingly defective during neoplastic transformation with eventual loss of viral antigens. It has also been observed that positivity for HBV decreases as the patients age increases suggesting an elimination of the viral antigens with time<sup>(27)</sup>.

In some geographical areas the incidence rates of HBV infection and HCC do not coincide<sup>(34,35,36)</sup>. This suggests that some HCC cases are not HBV related. Other hepatotropic viruses like Non A Non B hepatitis viruses may act as initiators. Exposure to aflatoxin in early life may also initiate carcinogenesis.

Aflatoxin is a metabolic product of the mould Aspergillus flavus a common food spoilage fungus in hot humid environments. Several studies have examined the correlation between aflatoxin and HCC (31-41). In all a definite relationship between aflatoxin intake and the incidence of HCC was noted. Aflatoxin B1 has been found in the livers of a high proportion of HCC patients and not in controls from the same locality. The metabolites of aflatoxin are carcinogenic and are normally detoxified in the liver by glutathion conjugation. There is genetic variation in the degree of aflatoxin metabolite binding and inactivation. Eighty per cent of Africans are slow inactivators of Isoniazid and debrisoquin and may also be slow inactivators of aflatoxin metabolites. They would therefore be exposed to the carcinogenic effects of epoxides for prolonged periods of time. This may partly explain the high incidence of HCC in Africa.

Certain chemicals such as N-Nitroso compounds used in laundries and dry cleaners and organochlorine pesticides have been found to cause hepatocellular carcinoma in animals but their role in human HCC is not yet defined<sup>(33)</sup>.

#### 5.4 PREVENTION OF HBV ASSOCIATED HCC AND LIVER CIRRHOSIS

No effort should be spared in the study and evaluation of factors involved in the causation of cirrhosis and HCC. Infection with HBV at an early age may lead to a persistent carrier state which greatly increases the risk of HCC and cirrhosis as the body is unable to eliminate the virus. Active immunisation of infants in high incidence areas and high risk groups in low incidence areas would be quite effective in controlling the infection. In view of the current high costs of the vaccine it may be necessary to select only the infants of HBV positive mothers for immunization. However facilities to screen all mothers for HBV nationwide may prove to be expensive too. Careful planning is called for before any HBV immunization strategy is implemented.

Screening of donated blood is now routine and prevents transmission of HBV through blood and its products.

Improved farming and food storage methods would reduce contamination with aflatoxin. Efforts may be concentrated on regions with particularly high levels of aflatoxin in food<sup>(33)</sup>. High aflatoxin levels may be related to climate and altitude. People in high incidence areas should be advised to avoid alcohol and tobacco which enhance the carcinogenic effects of HBV and aflatoxin.

6. CONCLUSIONS

The significantly high rates of HBSAg in HCC and cirrhosis in contrast to low rates in normal liver support the hypothesis that HBV is involved in the causation of HCC and liver cirrhosis.

Hepatitis B core antigen was not detected as frequently as HBSAg in HCC and cirrhosis but was totally absent from normal liver samples. About half the cases of HCC had associated cirrhosis while the other half had no detectable cirrhosis. The rate of HBV components positivity was similar in both groups suggesting that HBV was equally responsible for the aetiology of HCC whether associated with cirrhosis or not. Some infected persons may proceed directly to HCC without an intervening stage of cirrhosis. This is thought to occur most often when HBV is acquired at birth or in infancy.

The importance of biopsy size in a study of this nature is clearly brought out. Open biopsies provide more tissue and thus improve the chances of detection of the randomly distributed antigens. Since no antigen is detectable in the tumour itself all samples examined should include some non-neoplastic tissue.



## 7. RECOMMENDATIONS

Hepatocellular carcinoma and liver cirrhosis are common diseases in Kenya for which no cure is available. Morbidity and mortality from these two conditions are very high. Every effort should therefore be expended towards their prevention.

Vaccines for immunization against HBV have recently been developed<sup>(35)</sup>. Immunization of persons at high risk such as infants, health personnel and dialysis patients should be advocated.

Future research should be directed towards the production of a cheaper vaccine suitable for the developing countries where the incidence of HBV is highest. Factors that may be involved in the aetiology of HCC and cirrhosis either independently or in association with HBV should be evaluated to determine their contribution to these diseases in Kenya and other high incidence countries.

8.1

APPENDIX 1HAEMATOXYLIN AND EOSIN STAINING METHOD (Standard)

1. De-wax the sections in two changes of xylene.
2. Remove xylene by dipping sections in two changes of absolute alcohol. One minute in each bath is sufficient. Pass sections through 90% and 70% alcohol to avoid the possibility of diffusion currents causing damage and perhaps detachment of the sections.
3. Wash the sections in tap water to dehydrate
4. Stain in Cole's haematoxylin for 10 minutes.
5. Wash well in running tap water for 2-3 minutes.
6. Differentiate in 1% hydrochloric acid in 70% alcohol for a few seconds. (three dips).
7. Wash in tap water.
8. Blue in Scots tap water for 30 seconds.
9. Stain in 1 per cent eosin for 5 minutes.
10. Wash off surplus stain in water.
11. Dehydrate in alcohol, clear in xylene and mount in Distrin Phthalate xylene.

8.2

APPENDIX 2ORCEIN STAIN FOR HBSAg

Oxidation before staining reduces the stainability of the cytoplasm and nucleus thus giving a better contrast for the orcein positive areas.

A: Oxidation

1. Sections of about 5 um thickness are placed in 0.3% potassium permanganate solution with 0.015 ml sulfuric acid for 5 minutes.
2. The sections are then placed in 1.5% oxalic acid until colourless.
3. Place in 70% alcohol for 5 minutes.

B: Staining

1. 1 g orcein is dissolved in 100 ml of 70% alcohol, pH is adjusted to 1-2 with hydrochloric acid. The sections are placed in this solution for 4-6 hours.
2. Differentiate in absolute alcohol.
3. Clear in xylene then mount using Distrin Phthalate xylene (DPx).

8.3

APPENDIX 3IMMUNOPEROXIDASE STAINING TECHNIQUE (31)

- A. Removal of paraffin and rehydration of tissues
- a) Place sections in an oven  $56^{\circ}$ - $60^{\circ}$ C for 30 minutes.
  - b) Transfer slide immediately into a xylene bath and incubate for 3 minutes. Repeat once.
  - c) Shake off excess liquid and place slides in fresh absolute ethanol for 3 minutes. Repeat once.
  - d) Shake off excess liquid and place slides in 95% ethanol for 3 minutes. Repeat once.  
Rinse slides in gently running tap water for 30 seconds then commence staining procedure.
- B. Staining procedure
- i) Wipe excess liquid from slides, place on a flat surface. Apply 3% hydrogen peroxide solution. This suppresses endogenous peroxidase activity. Incubate for 5 minutes, at room temperature. Rinse with distilled water and place the slides in 0.05M Tris buffer (pH.6) bath for 5 minutes.
  - ii) Wipe off excess liquid. Cover slide with blocking serum and incubate for 20 minutes at room temperature. This serum quenches non-specific protein binding to certain tissue elements. Tap off excess serum.
  - iii) Divide slides marked for different antigens into groups and apply antibody to target antigen (HBSAg of HBCAg) to test slides. Negative control reagent (lacks specific antibody) is added to negative control slides. Incubate for 20 minutes. Rinse gently with Tris buffer then place in Tris buffer bath for 5-20 minutes.
  - iv) Wipe off excess liquid cover slides with link antibody (antibody to primary antibody). Incubate for 20 minutes. Rinse gently with Tris buffer then place in a Tris buffer water bath for 5-10 minutes.

- v) Wipe off excess liquid. Cover slides with Peroxidase anti-peroxidase (PAP) and incubate for 20 minutes. Because the antibody of the PAP reagent is from the same species of animal as the primary antibody, they will be united by the link antibody at the site of the tissue antigen.  
Rinse in buffer, place in buffer bath for 5-20 minutes.
- vi) Cover slides with freshly prepared Diaminobenzene (DAB).
- vii) Incubate at room temperature for 1.2 hours.  
Rinse gently with distilled water.

C. Counterstaining

- i) Place slides in Meyers haematoxylin x 3 min  
wash in running tap water.
- ii) Differentiate in 1% acid alcohol  
wash in running tap water
- iii) Blue in Scots tap water  
Wash in running tap water
- iv) Dehydrate in graded alcohol  
clear in xylol  
mount using Distrin Phthalate xylene (DPX).

## REFERENCES

1. WHO Technical Report Series 691 (1983).  
Prevention of liver cancer.
2. London, W.T.  
Hepatitis B virus and primary hepatocellular carcinoma  
Advances in Viral Oncology 3:325-341 (1983)
3. Prince A.M. et al  
A case/control study of the association between  
primary liver cancer and hepatitis B infection in  
Senegal.  
Int. J. Cancer 16:376-383 (1975)
4. M.S.R. Hutt  
Epidemiology of human primary liver cancer.  
IARC (1) Liver Cancer 21-29 (1963)
5. Kung'u A  
National Cancer Registry, 1968-1978 (Kenya)  
Cancer Occurrence in developing countries  
IARC (75) (1986).
6. B.S. Blumberg.  
A new antigen in leukaemia sera  
J. Amer. Med. Assoc. 191: 541-546 (1965)
7. Beasley, Hwang, Lin and Chien  
Hepatocellular carcinoma and hepatitis B virus.  
A prospective study of 22 fof men in Taiwan.  
Lancet II, 1129-1133 (1981).
8. Kubo, Y. et al  
Detection of hepatocellular carcinoma during  
a clinical follow up of chronic liver disease.  
Gastroenterology 74: 578-582 (1978)
9. Anthony, P.P. et al  
Hepatitis-associated antigen and antibody in  
Uganda: Correlation of serological testing with  
histopathology.  
Br. Med. J. 1: 403-406 (1972).

10. Brechot et al  
State of hepatitis B virus DNA in liver diseases.  
Hepatology 2: 275-345 (1982 6)
11. Shafritz, D.A.  
Hepatitis B virus DNA molecules in the liver of  
HBSAg carriers.  
Hepatology, 2: 355 - 415 (1982)
12. Hino et al  
Detection of hepatitis B virus DNA in hepatocellular  
carcinomas in Japan  
Hepatology 4: 90-95 (1984)
13. Pierre Tiollais et al  
The hepatitis B virus  
Nature Vol. 317, 10, 489-495 (1985)
14. Bowry, T.R., Shañ, M.V., Ahmed, Z.  
Hepatitis B core antibody in volunteer blood donors  
in Kenya  
E.A.M.J. Vol. 58: 570-574 (1981)
15. Greenfield, C.  
Hepatitis B virus & Liver disease in Kenya  
Thesis for PHD, Medical Library, University  
of Nairobi.
16. Gibson, J.B., Wu, P.C. et al  
Hepatitis B surface antigen, hepatocellular  
carcinoma and cirrhosis in Hong Kong.  
Br. J. Cancer 42: 370 - 377 (1980).
17. Gerber M.A.; Hadziyanis, S. et al  
Incidence and nature of cytoplasmic hepatitis B  
antigen in hepatocytes.  
Lab. Invest. 32: 251-256 (1975).
18. Sternberger, L.A. et al  
The unlabelled antibody-enzyme method of  
immunohistochemistry - preparation and properties  
of the soluble antigen - antibody complex.  
J. Histochem cytochem. 18: 315-33 (1970).

19. Angelos P; Afroudatis M.D. et al  
An Immunoperoxidase technic for the demonstration  
of HBSAg in human livers.  
Am. J. Clin. Path. 65: 533 - 539 (1975)
20. Deodhar K.P.; Tapp E et al  
Orcein staining of HBSAg in paraffin sections  
of liver biopsies  
J. Clin. Path. 28: 66-70 (1975)
21. Shikata, T.; Uzawa, T. et al  
Staining methods of Australia antigen in paraffin  
sections  
Jap. J. Exp. Med. 44: 25-36 (1974).
22. Kunio Okuda & Toshiro Nakashima  
Hepatocellular carcinoma: A review of recent studies  
and developments.  
Progress in liver disease Chap. 35 (1979).
23. Adnani, M.S.; Ali S.M.  
Patterns of Chronic Liver diseases in Kuwait.  
J. Clin. Path. 37: 549 - 554 (1984).
24. Nayak, N.C.; Asha Dhar et al  
Association of human hepatocellular carcinoma  
and cirrhosis with HBSAg and HBCAg in liver.  
Int. J. Cancer 643 - 654 (1977).
25. Nayak, N.C., Sachdeva, R.  
Localisation of HBSAg in conventional paraffin  
sections of the liver: Comparison of Immuno-  
fluorescence Immunoperoxidase and orcein staining  
methods with regard to their specificity and  
reliability as antigen marker.  
Am. J. Path. 81: 479 - 492 (1975).
26. Carleton's Histological techniques.  
Oxford Medical Publications.



27. Bagshawe, A.F.; Gacengi, F., Cameron C.H. et al  
HBsAg and liver Cancer: A population based study  
in Kenya.  
Br. J. Cancer, 31: 580 - 584 (1975).
28. Bowry, T.R. et al  
Seroepidemiology of hepatitis B in an Urban  
Population of Nairobi, Kenya.  
J. Inf. Diseases 148: 1122 (1983).
29. Wankya, B.M.; Nausen, D.P. et al  
Seroepidemiology of hepatitis A and B in  
Kenya: Population survey in Machakos.  
E.A M.J. 56: 134-137 (1979).
30. MacSween, Anthony, Schever  
Pathology of the liver.  
Churchill-Livingstone - 2nd Edition
31. Immunoenzymatic Staining Kits  
Dakopaths.
32. Ayoola et al  
HBV and Aflatoxin in hepatocellular carcinoma  
IARC 63: 169 - 174 (1984).
33. Anthony, P.P.  
Hepatocellular carcinoma: An overview.  
IARC 63: 3 - 22 (1984).
34. Kew, M.C. et al  
Hepatitis B virus status of Southern African  
blacks with hepatocellular carcinoma.  
Hepatology 3: 65 - 68 (1983)
35. Zuckerman A.J.; Harrison T.J.  
Hepatitis B virus Chronic liver disease and  
hepatocellular carcinoma.  
Postgraduate Medical J. 63: (Suppl 2) 13 - 19 (1987)

36. Skin Hoj P; Cohn J; et al  
Transmission of hepatitis B from healthy HBSAg  
positive mothers.  
B.M.J. 1, 10-11 (1976).
37. Alpert M.E.; Hutt M.S. et al  
Association between aflatoxin content of food  
and hepatoma frequency in Uganda.  
Cancer, 28: 254-260 (1971).
38. Keen P; Martin P.  
Is aflatoxin carcinogenic in man? The evidence  
in Swaziland.  
Trop. Geog. Med. 23: 44 - 53 (1971).
39. Shank, R.C.; Gordon, J.E. et al  
Dietary aflatoxin and human cancer  
Food Cosmet. Toxicol. 10: 71 - 84 (1972).
40. Peers F.G.; Linsel C.A.  
Dietary aflatoxins and liver cancer - a population  
based study in Kenya.  
Br. J. Cancer 27: 473 - 484 (1973).
41. Van Rensburg S.J. et al  
Hepatocellular carcinoma and dietary aflatoxin  
in Mozambique and Transkei.  
Br.J. Cancer 51: 713-726 (1985).