

**INCIDENCE, MANAGEMENT AND OUTCOME OF
CRANIOPHARYNGIOMA IN
KENYATTA NATIONAL HOSPITAL**

**A DISSERTATION STUDY TO BE SUBMITTED IN
PART FULFILMENT FOR THE DEGREE OF
MASTERS OF MEDICINE (GENERAL SURGERY)
UNIVERSITY OF NAIROBI**

University of NAIROBI Library



0537830 2

**INVESTIGATOR
DR. STEPHEN N. EKITELA (M.B. Ch.B.)**

**UNIVERSITY OF NAIROBI
MEDICAL LIBRARY**

DECLARATION

I Dr. Ekitela N. Stephen, hereby declare that this is my original work and has not been submitted in whole or part in any institution of learning for award of a degree.

INVESTIGATOR:

DR. EKITELA N. STEPHEN (MB. CH.B.)
COLLEGE OF HEALTH SCIENCES
UNIVERSITY OF NAIROBI
P. O. BOX 19724, 00202,
NAIROBI.

SIGN.....

DATE.....22/10/09.

SUPERVISOR:

MR. JULIUS GITHINJI KIBOI
MB. CH.B.M.MED
CONSULTANT NEUROSURGEON
LECTURER UNIVERSITY OF NAIROBI
P. O. BOX 19676,
NAIROBI.

SIGN.....

DATE.....22/10/09

DEDICATION

I dedicate this book to my family especially to my wife Miriam, my daughters Victoria, Patience and Prudence and to my son Ernest. Without their love, support, understanding and encouragement, completion of this work would not have been possible.

ACKNOWLEDGEMENT

I extend my heartfelt appreciation to my family for their moral support, patience and encouragement throughout the study.

I thank my supervisor Dr. Kiboi for his patience, guidance and valuable critique.

I also extend my thanks to Dr. Ekutan Christopher for his guidance in Data Analysis.

My appreciation to the neurosurgical/general surgical wards, clinics and records department for facilitating collection of data for the study.

Thank you all.

TABLE OF CONTENTS

DECLARATION.....	i
DEDICATION.....	ii
ACKNOWLEDGEMENT.....	iii
TABLE OF CONTENTS.....	iv.
LIST OF TABLES.....	vi.
LIST OF FIGURES.....	vii.
LIST OF ABBREVIATIONS.....	viii
ABSTRACT.....	ix
1.0 INTRODUCTION.....	<u>1</u>
2.0 LITERATURE REVIEW.....	3
2.1 HISTORICAL REVIEW.....	3
2.2 PATHOPHYSIOLOGY.....	4
2.3 CLINICAL PRESENTATION.....	8
2.4 INVESTIGATIONS.....	11
2.5 TREATMENT.....	15
2.6 PROGNOSIS AND LONG TERM OUTCOME.....	22
2.7 FOLLOW-UP.....	31
3.0 STUDY RATIONALE AND JUSTIFICATION.....	35
3.1 OBJECTIVES.....	36

3.2 STUDY METHODOLOGY.....37

LIST OF TABLES

4.0 RESULTS.....40.

5.0 DISCUSSION.....59

6.0 CONCLUSION.....65

7.0 RECOMMENDATIONS.....66

8.0 REFERENCES.....67

9.0 APPENDICES.....72

LIST OF TABLES

Table 1: Demographic Characteristics.....42
Table 2: Laboratory Investigations.....45
Table 3: other laboratory investigations.....46
Table 4: Radiological Investigations.....47.
Table 5: Treatment Modalities.....49

LIST OF FIGURES

Figure 1: Proportion of Craniopharyngiomas to other brain tumours treated at KNH.	40
Figure 2: Number of all brain tumours and craniopharyngiomas treated at KNH.....	41
Figure 3: Age distribution of craniopharyngiomas.....	42
Figure 4: Presenting Complains.....	43
Figure 5: Physical Examination Findings.....	44
Figure 6: Distribution of visual disturbances.....	44
Figure 7: radiological site of the lesions.....	48
Figure 8: Complications after surgery.....	51
Figure 9: Outcome in relation to all types of treatment.....	52
Figure 10A: Outcome in male patients.....	52
Figure 10B: Outcome in female patients.....	52
Figure 11A: Outcome in patients 18 years and below.....	53
Figure 11B: Outcome in patients above 18 years.....	53
Figure 12: Outcome in patients with/with out headache.....	53
Figure 13: Outcome in patients with/with out vomiting.....	54
Figure 14: Outcome in patients with/with out visual disturbances.....	54
Figure 15: Outcome in relation to prolactin levels.....	55
Figure 16: Outcome in relation to triiodothyronine levels.....	55
Figure 17: Outcome in relation to cortisol levels.....	56
Figure 18: Outcome in relation to site of the lesion.....	56
Figure 19A: Outcome in relation to surgery alone.....	57
Figure 19B: Outcome in relation to surgery and radiotherapy.....	57
Figure 20: Outcome in relation to type of surgery.....	57
Figure 21: Outcome in relation to preoperative hospital stay.....	58
Figure 22: Outcome in relation to arm of the study (retrospective/ prospective).....	58

LIST OF ABBREVIATIONS

ACTH	Adreno-corticotrophic Hormone
CBTRUS	Central Brain Tumour Registry of the US
CSF	Cerebrospinal fluid
CT	Computerized Tomography
CTA	Computerized Tomography Angiography
DNA	Deoxyribonucleic Acid
ER	Estrogen Receptors
ETV	Endoscopic third Ventriculostomy
FLAIR	Fluid Attenuated Inversion Recovery
FSH	Follicle Stimulating Hormone
GH	Growth Hormone
IGF	Insulin Growth Factor
IL	Interleukin
IQ	Intelligence Quotient
KNH	Kenyatta National Hospital
LH	Luteinizing Hormone
MRA	Magnetic Resonance Angiography
MRI	Magnetic Resource Imaging
PR	Progesterone receptors
PRL	Prolactin
RT	Radiotherapy
TNF	Tumour Necrotic Factor
TSH	Thyroid Stimulating Hormone
USA	United States of America
VP	Ventriculo-peritoneal
WHO	World Health Organization

ABSTRACT

BACKGROUND

Craniopharyngiomas are benign intracranial tumours with a bimodal distribution, with peak incidence in children aged 5-14 years and older adults aged 65-74 years. There is no clear consensus reached with regards to its treatment and no reliable criteria for accurately predicting the clinical outcome of these tumours. This study focused on the presentation, management and outcome of patients with craniopharyngiomas.

METHODOLOGY

This was a combined retrospective and prospective study for patients admitted at KNH with a confirmed diagnosis of craniopharyngiomas. The study covered the period January 2003 to December 2008 and a follow up of three-six months at the Neurosurgery clinic was undertaken. The retrospective part of the study was from January 2003 to October 2007 while the prospective was from November 2007 to December 2008. The following data was entered into a standardized questionnaire: - demographics, clinical presentation, management and outcome.

Data was processed using appropriate analytical packages including SPSS, Chi square and descriptive statistics such as median, mean and frequency distribution was used to analyze data. Results are presented in charts, graphs and tables followed by a discussion. Conclusions and recommendations made there after.

RESULTS

There were 20 males and 21 females all totaling to 41. Majority (68.3%) were in the age bracket 0-19 years. The incidence of craniopharyngioma at Kenyatta National Hospital is 7.1%. majority of patients presented with headache and visual disturbances, 90% and 78% respectively.

Most patients (56.1%) were dead within six months of follow-up.

CONCLUSIONS

There was no significant association between outcome with age and gender. Outcome was better in patients done biopsy/ partial resection, patients who had radiotherapy in addition to surgery although not statistically significant.

Only 42.5% of the patients had radiotherapy in addition to surgery which had a positive impact on the outcome.

There is need for patients to receive post-operative radiotherapy and adequate follow-up investigations to assist in patient rehabilitation/care.

INTRODUCTION

Craniopharyngiomas (cranio=skull, pharynx=throat, oma=tumor) are benign, slow-growing, locally invasive intracranial tumors that can generate considerable morbidity, and recurrences are often difficult to manage. Reliable morphologic criteria for accurately predicting the clinical outcome of these tumors are lacking. It has challenged the neurosurgeon and his skills for many years. These tumors have a very intricate relation with the hypothalamus, pituitary stock and optic apparatus, which have caused excessive problems regarding optimal management. In spite of its recognition in the late 1800, no clear consensus is reached with regards to its treatment. Philosophy of treatment is not only different among different surgeons but also in the span of a Surgeons career.

Computerized Tomography (CT) and Magnetic Resonance Imaging (MRI) are the examinations of choice but today the best Imaging tool is MRI.

Many people with craniopharyngiomas go on to live uncompromised or relatively uncompromised lives. This is not always the outcome. Earlier detection and better therapeutic techniques are still required and must remain a priority. Total tumour removal is still the ideal form of treatment but should be attempted in situations when all the important adjacent structures can be safeguarded. Total tumour removal should be confirmed by a three month's post operative CT scan and residual tumour should be treated with radiation therapy.

Conservative removal of tumour is done when the radiovascular structures are at danger during surgery. The aim is to evacuate the distended cyst, excise as much as is absolutely safe and decompress the optic apparatus and hypothalamus. Residual tumour is irradiated. Karavitaki et al. (1) reported the ten years survival rates of 77%-100% after partial resection and subsequent radiotherapy and 81.3%-100% after radiologically confirmed total removal. Data on the treatment option with the most favourable impact on survival are not consistent.

Most studies (1,2) suggest that post surgical follow-up should be planned in one to two weeks for all patients and patients with sub-total resections and are for radiotherapy should start radiation within three weeks of surgery.

Patients should be seen every three months for the first post surgical year, every six months in the second year and third years and yearly thereafter and should have a brain MRI/CT Scan for comparison with previous films.

In Kenyatta National Hospital, no study has been done specifically to determine the incidence, management and outcome of craniopharyngiomas hence this study aims to generate useful data to improve the management of these patients.

LITERATURE REVIEW

HISTORICAL REVIEW

Zenker, in 1857 (3), recognized a suprasellar cholesterol containing lesion at autopsy while Onanoff, in 1892, coined the term pituitary adamantinoma for these lesions and Mott and Barrett, in 1899 (4), postulated that these tumors arose from the hypophyseal duct. In 1904, Erdheim described the histologic characteristics of these tumors and pointed out the similarities between craniopharyngiomas and adamantinomas(5). Halstead, in 1909, excised a craniopharyngioma through trans-sphenoidal route. McKenzie, in 1924, termed this lesion craniopharyngeal pouch tumors. Also, the term craniopharyngioma was used by Frazier and Alpers (5) in 1931 and then by Cushing in 1932 (7). Since then, craniopharyngiomas have been found along the developmental path of Rathke's pouch from the pharynx to the floor of the sella as well as above and within the sella turcica. The other recognized names for this lesion are ameloblastoma, epidermoid tumor and craniopharyngeal fat tumor.

B. ORIGIN/CLASSIFICATION

a) Origin of Craniopharyngiomas

Three main hypotheses explain the origin of craniopharyngiomas and they complement each other and explain the craniopharyngioma spectrum. These are; -

i) Embryogenetic Theory: This theory relates to development of the adenohypophysis and transformation of the remnant ectoblastic cells of the craniopharyngeal duct and the involuted Rathke pouch. Rathke cleft together with remnants of the craniopharyngeal duct can be the site of origin of craniopharyngiomas (8).

ii) Metaplastic Theory: This theory relates to the residual squamous epithelium (derived from stomadeum and normally part of the adenohypophysis), which may undergo metaplasia (9).

iii) Mixed (Dual) Theory: This theory explains the craniopharyngiomas spectrum, attributing the adamantinomatous type to embryonic remnants and the squamous papillary type to metaplastic foci derived from mature cells of the anterior hypophysis.

b) Classification

Classification of craniopharyngioma utilizes the anatomical location, the growth pattern, the imaging findings, intra-operative findings and involvement of the surrounding adjacent structures. Various methods of classification by different authors were used like Giant and small, typical and atypical, retro, sub or pre-chiasmatic, intra, supra, para and retro sellar varieties. It was Yasargil in 1996, who categorized these tumors as Types A to F. (10)

Type A - intrasellar - infradiaphragmatic

Type B - intra and suprasellar, infra and supra diaphragmatic

Type C - supra diaphragmatic, parachiasmatic, extraventricular

Type D - intra and extra ventricular

Type E - purely intraventricular

Type F - extra dural and extra cranial

The tumours occur in suprasellar (75%), infrasellar (21%) or entirely intrasellar (4%) locations (5).

PATHOPHYSIOLOGY

The craniopharyngeal duct is the embryonal structure along which the eventual adenohypophysis and infundibulum migrate. Tumors can occur anywhere along the course of this duct from the pharynx to the sella turcica and third ventricle, which partially explains the location of the tumor (11).

The trigger for tumor growth is not clear. It extends horizontally along the path of least resistance in various directions - anteriorly into the prechiasmatic cistern and subfrontal spaces; posteriorly into the prepontine and interpeduncular cisterns, cerebellopontine angle, third ventricle, posterior fossa, and foramen magnum; and laterally toward the subtemporal spaces. It can even reach the sylvian fissure. Rare locations include extradural, extracranial e.g. nasopharyngeal, pure posterior fossa craniopharyngiomas and craniopharyngiomas extending down the cervical spine. Purely intraventricular craniopharyngioma which is very rare is usually of the squamous-papillary (metaplastic) type (12).

Vascular supply is dependent on different sources, usually all from the anterior circulation. The anterior portion of the tumor is supplied by small perforators coming off A1 (i.e., anterior cerebral artery); lateral portions receive perforators from the proximal portion of the posterior communicating artery; and the intrasellar part is supplied by branches of the intracavernous meningohypophyseal arteries(12). Craniopharyngioma rarely is supplied with blood coming from the posterior circulation, unless the anterior blood supply for the anterior hypothalamus and floor of the third ventricle is lacking. Tumor adhesion to surrounding vascular structures represents the most common cause of incomplete tumor removal. Fusiform dilatations of large surrounding vessels have been reported after attempts at radical dissection of the tumor capsule; they injure vasa vasorum, thereby weakening the adventitia. Tumor adhesion is caused by local inflammation.

Several inflammatory cytokines have been shown to be elevated in the craniopharyngioma cyst fluid when compared with CSF (12). IL-1alpha and TNF-alpha were significantly elevated but lower than 10-fold. IL-6 was greater than 50,000 times more concentrated in the cystic fluid than CSF. This supports the hypothesis that biomodulation of the cytokine profile could lead to long periods of stability and even tumor regression. IFN-alpha exerts diverse influences mainly on cytokine antagonists and soluble adhesion molecules and has been shown to play a role in the treatment of craniopharyngioma in some limited trials, both after systemic use and local, direct intracystic use (12).

Recurrences usually occur at the primary site. Ectopic and metastatic recurrences are extremely rare and have been reported after surgical removal. The two possible mechanisms of seeding are dissemination of tumor cells along the surgical paths during the procedure and migration of tumor cells through the subarachnoid space or Virchow-Robin spaces (which would explain ectopic recurrences distant from the surgical bed and within brain parenchyma) (13).

An extensive fibrosis and inflammation (which is considerably more severe with recurrent tumors than with others) are also observed. These findings may result in dense adhesion to

adjacent structures and vessels, which accounts for the difficulty in resecting craniopharyngiomas. Intimate interdigitation of the tumor tissue and encasement of the vasculature of the circle of Willis are often present. Gliosis can make the differentiation of these tumors from a primary glial tumor difficult. The tumoral interdigitation also explains why, recurrence is frequent in these tumors that are histologically benign and yet appear to have been totally resected on intraoperative visual inspection (13).

PATHOLOGY

Craniopharyngiomas average size is 3 to 4 cm in diameter, they may be encapsulated and solid but more commonly are cystic and sometimes multiloculated. More than three fourths of these tumours contain sufficient calcifications to be visualized radiographically. In their strategic location, they often encroach on the optic chiasm or cranial nerves and not infrequently bulge into the floor of the third ventricles and base of the brain. Two histologic forms can be distinguished - adamantinomatous and papillary (14).

The adamantinomatous craniopharyngioma consists of nests or cords of stratified squamous or columnar epithelium embedded in a spongy reticulum. Often the nests of squamous cells gradually merge into a peripheral layer of columnar cells. Keratin formation is seen and this form of the tumour is frequently calcified. Additional features typical of adamantinomatous craniopharyngioma include cholesterol-rich cyst contents, fibrosis and chronic inflammatory reaction. These tumours extend fingerlets of epithelium into adjacent brain, where they elicit a brisk glial reaction.

The papillary craniopharyngioma usually lacks the keratin, calcification and cyst content. The squamous cells of the solid sections of the tumour do not have the columnar sheet at the periphery and do not typically generate a spongy reticulum in the internal layers (14).

EPIDEMIOLOGY

a) Frequency:

- In the US: Data from the Central Brain Tumor Registry of the United States (CBTRUS), collected between 1990 and 1993, revealed an average of 338 cases diagnosed annually with 96 occurring in children aged 0-14 years (15).
 - Overall incidence was 0.13 per 100,000 per year.

- No variance by gender or race was found.
- Craniopharyngioma comprised 4.2% of all childhood tumors (ages 0-14 years).
- Distribution by age was bimodal, with peak incidence in children aged 5-14 years and older adults aged 65-74 years.
- **Internationally:**
 - Incidence is 0.5-2 per 100,000 per year.
 - Overall, craniopharyngioma accounts for 1-3% of intracranial tumors and 13% of suprasellar tumors.
 - In children, craniopharyngioma represents 5-10% of all tumors and 56% of sellar and suprasellar tumors.
 - No definite genetic relationship has been found and very few familial cases have been reported.
 - The relative incidence of craniopharyngiomas in comparison to other intracranial tumours in different study series are as shown below (16, 17, 18).
 - Cushing (1938) – 4.6%
 - Olivercrona – 1.7%
 - Ruberti (1989) - 4.4%
 - Mahindu Madelle (2004)– 5.8%

Race: Higher frequencies of all intracranial tumors have been reported from Africa, the Far East and Japan (19).

Sex: No gender differences have been found in population based studies (20).

Age: Age of diagnosis varies widely; cases have been reported both in fetuses and in the elderly (age as high as 70 years) (1).

CLINICAL PRESENTATION

Craniopharyngioma usually is a slow-growing tumor. Symptoms frequently develop insidiously and mostly become obvious only after the tumor attains a diameter of about 3 cm. Time interval between onset of symptoms and diagnosis ranges from 1-2 years.

- The most common presenting symptoms are headache (55-86%), endocrine dysfunction (66-90%), and visual disturbances (37-68%) (20).

- Headache is slowly progressive, dull, continuous, and positional; it becomes severe in most patients when endocrine symptoms become obvious.
- On presentation, 40% of patients have symptoms of hypothyroidism (e.g. weight gain, fatigue, cold intolerance, constipation). Almost 25% have associated signs and symptoms of adrenal failure (e.g. orthostatic hypotension, hypoglycemia, hyperkalemia, cardiac arrhythmias, lethargy, confusion, anorexia, nausea and vomiting), and 20% have diabetes insipidus (e.g., excessive fluid intake and urination).
- Eighty percent of adults complain of decreased sexual drive and almost 90% of men complain of impotence, while most women complain of amenorrhea.
- Most young patients present with growth failure and delayed puberty. Short stature is present in 23-45% and obesity in 11-18%.
- Optic pathway dysfunction on presentation is noted in 40-70% of patients. Children rarely become aware of visual problems (only 20-30%) and often present after almost complete visual damage has taken place (1,2).
- Other manifestations relate to the various connections of the hypothalamic-pituitary complex and surrounding structures. Thalamus and frontal lobes present with corresponding endocrine, autonomic, and behavioral problems (e.g. hyperphagia and obesity, psychomotor retardation, emotional immaturity, apathy, short-term memory deficits, incontinence).
- Three major clinical syndromes have been described and relate to the anatomic location of the craniopharyngioma.
 - Prechiasmal localization typically results in associated findings of optic atrophy (e.g. progressive decline of visual acuity and constriction of visual fields).
 - Retrochiasmal location commonly is associated with hydrocephalus with signs of increased intracranial pressure (e.g. papilledema).
 - Intraseptal craniopharyngioma usually manifests with headache and endocrinopathy.

Physical: Both neurologic and general examinations are indicated.

- Neurologic examination
 - Signs suggestive of increased intracranial pressure should be sought in any patient suspected of having an intracranial mass.
 - Visual field examination may reveal various patterns of visual loss (most frequently bitemporal hemianopsia) suggestive of involvement (i.e. compression) of the optic chiasma and/or tracts; visual fields should be tested further with formal testing (1, 2).

- General examination - May reveal signs relating to different endocrinopathies
 - Hypothyroidism: Signs of hypothyroidism include puffiness and non-pitting edema, slow return phase of deep tendon reflexes, long-standing effects on organ systems, hypoventilation and decrease in cardiac output, pericardial and pleural effusions, constipation, anemia (i.e. normochromic normocytic), decreased mental function, and psychiatric changes.
 - Adrenal insufficiency
 - Cortisol deficiency: This results in hypotension, which is often orthostatic. Gastrointestinal symptoms include anorexia, nausea, and vomiting; other signs and symptoms include weight loss, hypoglycemia, lethargy, confusion, psychosis, and intolerance to stress.
 - Aldosterone deficiency: Signs and symptoms include hypovolemia, decreased cardiac output, decreased renal blood flow with azotemia, fatigue, weight loss, and cardiac arrhythmias due to hyperkalemia.

DIFFERENTIALS

Other lesions in the suprasellar region that appear similar to craniopharyngiomas on CT include meningiomas, pituitary adenomas, and calcified aneurysms of the anterior circulation (21). The combination of enhancement and calcification in a cystic or partially cystic suprasellar lesion is strong evidence for a craniopharyngioma, especially in a child. Cystic tumors, large cysts of Rathke's cleft and arachnoid cysts may still be difficult to distinguish on MR imaging.

Adenoma

- In the adult is more frequent than craniopharyngioma.
- Raised PRL or ACTH galactorrhoea amenorrhoea or acromegaly and chiasmal syndrome as mass effect.
- Ballooned or cup-shaped sella reveals on skull x-ray.
- CT scan of the brain shows an homogeneously enhancing, lobulated, assymetrical lesion, microprolactinoma or ACTH-secreting adenoma most of the time cannot be detached.

Tuberculum Sellae meningioma

- Normal sella, striking contrast enhancement of a well defined tumour, rarely cystic and has hyperostosis bone destruction.

Aneurysm of the supra-clinoid carotid or terminal basilar artery

- Should be considered if the suprasellar lesion is geometrically found. It may show a ring shadow but more often has a homogeneous enhancement.

INVESTIGATIONS

- The diagnostic evaluation for craniopharyngioma includes precontrast and post-contrast CT scans and MRI, magnetic resonance angiography (MRA), complete endocrinologic and neuro-ophthalmologic evaluation with formal visual field documentation, as well as neuropsychological assessment.

a) Lab Studies:

- Endocrinologic studies
 - These should include baseline serum electrolytes, serum and urine osmolality, thyroid studies, morning and evening cortisol levels, growth hormone levels, and luteinizing and follicle-stimulating hormone levels (in adolescent and adult patients).
 - Extending the workup for various hypothalamic-releasing factors allows for differentiation between endocrine disorders of pituitary origin and those of hypothalamic origin. It also helps in correlating various neurohormonal deficits with neuropsychological deficits.

- In emergency cases, hormonal testing should be limited to diagnosing diabetes insipidus and hypoadrenalism, as both require initiation of treatment prior to surgery.
- Routine preoperative investigations should be done e.g. Full Hemogram and Erythrocyte Sedimentation Ratio, Grouping and Cross Matching.

b) Imaging Studies: -

CT and MRI are the complementary examinations of choice. Today, the best imaging tool is MRI without and with contrast enhancement.

i) Radiograph: A lateral radiogram of the skull may demonstrate calcifications in either the sella turcica or suprasellar space or it may demonstrate sellar expansion or erosion of clinoid process or dorsum sellar (21, 22).

The degree of confidence for a negative result is low because small calcifications can be missed easily.

ii) CT Scan: On CT, the adamantinomatous-type tumor appears as a predominately cystic mass with a solid component (>90%).

The solid component appears is attenuating and usually contains calcifications (>80%). The sella may be expansile, and hydrocephalus may be present, depending on the exact location of the tumor. Papillary type is usually solid, isoattenuating, and rarely calcified. Occasionally, craniopharyngioma may appear as an intraventricular, homogeneous soft-tissue mass without calcifications but possibly with hypoattenuating regions; this is observed in the papillary subtype (21, 23).

The location of the adamantinomatous subtype is characteristic because most are located in the sella or suprasellar region. Contrast enhancement is characteristic of the solid component and cyst wall (90% cases), and an enhanced study may demonstrate displacement of the A1 segment of the anterior cerebral artery. Displacement of the optic chiasm also may be observed. On CT, the cystic component of the tumor can be seen to extend anteriorly and/or laterally and typically wraps around the solid component. Conversely, the solid component characteristically extends posteriorly and laterally. The degree of confidence is high because CT is sensitive for calcifications and for visualizing the cystic nature of masses. The noncalcified, papillary variant can be missed sometimes, as

with MRI. A Rathke cleft cyst is rarely calcified, whereas more than 90% of craniopharyngiomas are calcified.

iii) **MRI:** On MRI, the more common adamantinomatous subtype appears as a predominately cystic suprasellar mass with a solid component. Characteristic calcifications may not be discernible, though gradient-echo (GRE) images may show susceptibility effects from calcified components. Cystic areas appear hyperintense on T2-weighted and fluid-attenuated inversion recovery (FLAIR) images with heterogeneous isointense-to-hypointense solid components (22). The sella may be expansile, and hydrocephalus may be present depending on the exact location of the tumor. Occasionally, craniopharyngiomas appear as intraventricular, homogeneous, soft-tissue masses without calcifications. They may contain low-signal-intensity regions; this is observed in the papillary subtype.

Contrast enhancement is characteristic and MR angiography may demonstrate displacement of the A1 segment of the anterior cerebral artery. Displacement of the optic chiasma may also be observed.

On MRI, the cystic component of the tumor can be observed to extend anteriorly and/or laterally and typically wraps around the solid component. Conversely, the solid component of the tumor characteristically extends posteriorly and laterally.

Adjacent brain parenchyma may show hyperintensity on T2-weighted or FLAIR images, which indicates edema from compression of optic chiasm and/or tracts, gliosis, or tumor invasion. Recurrence in both local tumor bed and along surgical tracts may be due to implantation of craniopharyngioma tissue. Therefore, long-term follow-up should be performed, even in patients whose primary tumor was resected completely. The degree of confidence is high. Although MRI without a GRE sequence can be insensitive for calcifications, it is sensitive for determining the fluid or soft-tissue content of a given area.

iv) **Ultra Sound:** A few case reports have described the potential use of ultrasonography with color Doppler imaging in antenatal diagnosis of fetal craniopharyngiomas (23, 24).

With the wide availability and documented accuracy of CT and MRI, ultrasonography has not been accepted as a universal tool for the evaluation of pituitary masses.

v) **Angiography:** Most of the findings relate to displacement of the cerebral vasculature secondary to mass effect. Specifically, the position of the anterior cerebral artery is well correlated with the location of the tumor. When the A1 segment of the anterior cerebral artery and the anterior communicating artery are in the usual position, the tumor is contained entirely or almost entirely within the sella. When the A1 segment and the anterior communicating artery are elevated but the basilar artery is in the usual position, the tumor protrudes anteriorly and projects between the optic nerves, deviating the chiasm posteriorly.

When the A1 segment and the anterior communicating artery are elevated and the basilar artery is displaced posteriorly, the tumor protrudes posteriorly and pushes the chiasm anteriorly. Stretching of the posterior communicating arteries also may be noted. An unreliable finding is a small, vascular blush in the region of the tumor. CTA and MRA have supplanted angiography as the primary diagnostic techniques, and angiography is now rarely needed to differentiate the tumor from an aneurysm of the anterior communicating artery.

Angiography findings are nonspecific.

Other tumors can produce similar angiographic findings.

c) Other Tests

- Neuro-ophthalmologic evaluation with formal visual field documentation
- Neuropsychological assessment.

TREATMENT

Successful management of craniopharyngiomas often requires the involvement of several specialists (neurosurgeons, oncoradiologist, endocrinologists and physiotherapists). As people adjust to their life after the initial treatment of the tumor, additional support services are also often required, and should be individually tailored to meet the specific needs of patients and their families.

By combining effective initial treatment with careful follow up, many people with craniopharyngiomas go on to live uncompromised or relatively uncompromised lives. This is not always the outcome, however, and this important fact should serve as a reminder that although significant improvement has been made in treating Craniopharyngiomas, earlier detection and better therapeutic techniques still are required, and must remain a priority of both physicians and researchers.

Essentially, 2 main management options are available for craniopharyngioma - (a) attempt at gross total resection or (b) planned limited surgery followed by radiotherapy (25, 26). Although no consensus exists on the various therapeutic modalities for craniopharyngiomas, most authors advocate that successful management is determined by the ability to maintain independent social functioning, symptomatic recurrence and survival.

Neuropsychological deficits represent the major limiting factor of independent social functioning because patients often can overcome minor neurological deficits and hormone-replecting therapies are widely available. Degree of psychological impairment correlates directly with the degree of hypothalamic injury sustained at the time of surgery.

a) Surgical Intervention

Surgical Approaches

Many surgical procedures are available for tumor resection. The appropriate choice depends on the location of the tumor and the direction in which it extends. Most authors advocate a right pterional approach. A bi-frontal approach or left frontal craniotomy is indicated if the tumor extends into the left frontal or middle fossa (27, 28, 29, 30).

Craniopharyngiomas restricted to the sella turcica are excellent candidates for a transsphenoidal approach, which has yielded excellent results. (31).

Finally the transcortical or transcallosal approach utilizing a transventricular route is recommended when the solid portion of the tumor lies within the third ventricle. As noted, this approach may need to be combined with other surgical approaches to excise the tumor completely (32).

- Gross total surgical removal is the treatment of choice (25); however, it can be associated with morbidity and mortality rates as high as 20% (excluding endocrinopathies) and 12%, respectively. Recurrence rates can be as high as 20%; a serious potential for psychosocial deficits exists in patients with hypothalamic injury. Depending upon the location of the tumor, several approaches may be utilized. Some authors propose a plan of limited surgery, with postoperative radiotherapy as the management paradigm of choice for craniopharyngioma. Goals of this approach are (a) pathologic confirmation of the tumor and (b) surgical decompression of the optic chiasma. Surgery is followed by external beam radiation, at a dose of 5400-5500cGy delivered at 180 cGy/fraction.

Surgical Complications

- Perioperative morbidity includes (a) seizures, (b) visual deficits including blindness, (c) hypothalamic injury, (d) stroke, and (e) CSF leakage.
- Endocrinopathy is common. Permanent diabetes insipidus occurs in 68-75% of adults and 80-93% of children. Replacement of 2 or more of the anterior pituitary hormones is necessary in 80-90% patients. Obesity occurs in 50% of patients (33).
- Recurrence/progression following failed gross total or subtotal resection is common and occurs in 75% of patients. Recurrence usually is identified 2-5 years following resection.
- The incidence of tumor progression after planned limited surgery and radiotherapy ranges from 12-25% and is similar to that seen with failed gross total resection and radiotherapy (4-25%) (33).

In summary: -

1. Total tumour removal is the ideal form of treatment. It should be attempted only in situations when all the important adjacent neurovascular structures can be safeguarded. At no stage should traction on the tumour or blind dissection be necessary to remove tumour. Total tumour removal should be confirmed by a 3 month post-operative CT scan. Residual tumour either large and obvious or an enhancing small component needs to be treated further with radiation therapy. Heavily calcified

residual tumour should not be radiated, but the patient should have regular clinical and radiological evaluation.

2. Radical or subtotal removal of tumour also follows the above mentioned rules. Residual tumour is treated by radiation therapy.
 3. Conservative removal of tumour is resorted to when the neurovascular structures are at danger during surgery. This has been so especially when the chiasm is prefixed and the approach has had to be made through the lamina terminals, or between the optic nerve and carotid artery or lateral to the carotid artery. The aim is to evacuate the distended cyst, excise as much as is absolutely safe and decompress the optic apparatus and hypothalamus. Residual tumour is irradiated.
 4. Significant hydrocephalus is controlled with a ventriculoperitoneal or atrial shunt.
- Other approaches that can be useful in the management of giant craniopharyngioma, especially at the time of recurrence, include
 - (a) Intermittent aspiration by stereotactic puncture or Ommaya reservoir placement.
 - (b) Intracystic injection of bleomycin
 - (c) Internal irradiation with radioisotopes.

The latter 2 treatment modalities have been reported to control the tumor cysts in 90-100% of cases. In general, the 10-year survival rate for craniopharyngiomas is 90% and the 20-year survival rate for pediatric craniopharyngiomas is approximately 60%.

b) Radiotherapy

Radiotherapy can be applied as external fractionated radiation, stereotactic radiation or brachytherapy.

i) **External fractionated radiation** -Offers dual advantage by

- (a) Allotting normal cells more time for repair
- (b) Amplifying higher cumulative effect of DNA damage in more rapidly dividing tumor cells.

Radiation, following partial resection, offers excellent long-term results (80% at 20 years). Following partial resection, results of primary irradiation are superior to those with radiation delayed until time of recurrence. Recurrence is less frequent after imaging confirmed total resection (10-30% recurrence rate), in which case radiation should be delayed (34). Target volume for craniopharyngioma is narrowly confined to tumor volume (preoperative volume plus 1.5-cm margin) and should include solid component and cyst(s);

should be limited to postoperative residual tumor in case of partial resection of large (multi) cystic craniopharyngioma, with special attention to cover cyst wall; high-energy photons are used with 2-3 stationary fields or classic coronal arc configuration. Radiotherapy target dose should be 54-56 Gy over 30 sessions (over 6 wk; Monday-Friday weekly schedule), at 1.8-2 Gy/session (i.e. per day). (33)

Dose <54 Gy has been associated with high recurrence rate (about 50%) while doses of 54 Gy or more associated with recurrence rate of only 15%. Dose >60 Gy associated with marked increase in radiologic-induced endocrine, neurologic, and vascular complications. Complications of radiotherapy include intellectual decline, radiation-induced necrosis, optic neuropathy, pituitary-hypothalamic damage, secondary malignant brain tumors; vascular abnormalities that occasionally lead to vasospasm; self-limiting, mostly asymptomatic, hemorrhages; less commonly, proximal irradiation of carotid arteries leads to development of Moyamoya disease (34).

ii) **Brachytherapy/radioisotopes**-Recommended for solitary cystic craniopharyngiomas and consists of stereotactic aspiration of cystic content, followed by instillation of beta-emitting isotope (e.g. phosphorus 32, rhenium 186, gold 198, yttrium 90). Brachytherapy is attractive because about 60% of craniopharyngiomas occur as single large cysts; early refilling is the rule, requiring intermittent aspiration either by stereotactic puncture or Ommaya reservoir.

Stereotactic radiation has been used for further treatment of residual solid tumor after brachytherapy (35).

Brachytherapy offers

(a) Advantage of high reduction in dose to normal surrounding tissues (e.g. optic chiasma, hypothalamus)

(b) An option for patients who received prior external beam radiation; brachytherapy usually results in stabilization or reduction of cyst in >90% of cases.

iii) **Stereotactic radiation**-Has been used primarily as first-line for treatment of growing or symptomatic, solid, small size craniopharyngioma (<25-30 mm in diameter). Stabilization or reduction of cystic cavity after radiosurgery is achieved in more than 60% of patients.

High-dose volume should be limited to well-circumscribed tumor; safety margin of at least 3-5 mm from optic nerve is recommended (35, 36).

Major complications include visual impairment; >30% of patients experience severe visual deterioration; <10% of patients show rapid visual loss.

c) Chemotherapy

i) Intracystic bleomycin

The intracystic instillation of the antineoplastic agent bleomycin was initially described by Takahashi *et al.* in 1985 (37). The drug is administered through an Ommaya reservoir connected to a catheter [placed in the cyst stereotactically or through craniotomy (by direct vision or transcortically under ultrasound guidance or transventricularly under ultrasound and ventriculoscopic guidance)] (38). It has been proposed that its efficacy is associated with the spatial distribution of the S-phase proliferative cells in the squamous epithelial layer of the cyst wall (39).

The small number of published series (based on a limited number of patients and with variable total doses and time intervals between repeated instillations) suggest that intracystic bleomycin may be an effective therapy for some cystic tumors (37, 38). Thus, Takahashi *et al.*, during a median follow-up of 5.5 yr, found no recurrence in four children with predominantly cystic tumors treated initially by partial resection or aspiration/biopsy and followed by injection of bleomycin into the cyst (37).

Hader *et al.* reported more than a 50% decrease in tumor size in six of seven (85.7%) children with newly diagnosed cystic craniopharyngiomas offered intracystic bleomycin and observed for a mean period of 3 yr. During the follow-up, four of these children remained stable, and two underwent microsurgical removal (in one case due to persistent headaches not attributed to cyst enlargement, and in the second due to enlargement of a

second cyst (38). Less optimal results have been described by Frank *et al.* in a series of six patients; all the cysts regrew within 1 yr, with five of them requiring reoperation (40).

The administration of bleomycin may be associated with transient fever, headaches, and occasionally nausea and vomiting within the first 24hrs (41). Direct leakage, particularly from the orifices of the catheter to surrounding tissues, diffusion through the cyst wall, or high drug dose have been reported to cause various toxic (hypothalamic damage, blindness, hearing loss, ischemic attacks, peritumoral edema) or even fatal effects. Usage of special catheters with a limited number of holes, avoidance of passing the catheter through the subarachnoid space or the ventricular system, confirmation of sealed cysts, documented intracystic catheter placement, and protocols based on the volume of the tumor cyst contents may be helpful in preventing serious complications (38, 41).

The combination of intracystic instillation of bleomycin and ^{32}P may be associated with improved outcome. Jiang *et al.* (41) injected both agents in nine patients with cystic lesions; during a follow-up period of up to 24 months, six cysts almost disappeared, and the remaining three showed 57-78% regression compared with the original volume. However, a few months later, two patients suffered bilateral thalamic infarction, which in one case was fatal. The possibility of a cumulative damage by the two agents cannot be excluded.

In summary, the value of the intracystic injection of bleomycin in the tumor control or even in the delaying of potentially harmful resection and/or radiotherapy, especially in young children, as well as the optimal therapeutic protocol and the clear-cut criteria predicting the long-term outcome, remains to be established in large series of patients with appropriate follow-up. Fatal outcome has been reported with leakage, due to subsequent diffuse diencephalon and brainstem edema. Contrast CT cystography is required prior to intracavitary administration to ensure cyst wall integrity; when inconclusive, MR cystography with gadopentetate dimeglumine has been advocated.

ii) Systemic chemotherapy

The value of systemic chemotherapy in craniopharyngiomas has been investigated in a very limited number of patients. Thus, Bremer *et al.* reported a case of successful management of

a recurrent cystic tumor with the combination of vincristine, carmustine, and procarbazine (42). Lippens *et al.* after the administration of five courses of doxorubicin and lomustin in four children with multiple or very rapid recurrences followed up for 3–12 yr, achieved local control in 75% of cases (43).

d) Biologic Therapies

New systemic biologic therapies are currently under investigation with interesting results (e.g. interferon alpha-2a for progressive or recurrent craniopharyngiomas).

Jakacki *et al.* (44) in a series of 12 patients younger than 21 yr with progressive or recurrent craniopharyngiomas, showed that after 12 months of treatment with interferon α , tumor reduction of at least 25% was observed in three subjects. However, during the first weeks of therapy, six patients experienced an increase in the size of the cystic component, which was finally considered as progressive disease in half of them. Interestingly, 67% of the patients completing 1 yr of therapy without progressive disease had an increase in the size of their tumor at a median period of 11 months after discontinuation of the drug.

The cytotoxicity (predominantly hepatic, neurological, and cutaneous) requiring temporary discontinuation and/or dose reduction within the first 8 wk of therapy was significant (in up to 60% of the cases) (44). The pros and cons of this treatment modality, particularly for aggressive tumors, remain to be assessed by trials with large numbers of patients and adequate follow-up.

PROGNOSIS AND LONG TERM OUTCOME

A. Morbidity

The long-term morbidity of patients with craniopharyngiomas is substantial, and it mainly involves

- a) endocrine sequelae
- b) visual sequelae
- c) hypothalamic complications
- d) neurobehavioral and cognitive sequelae.

These complications are attributed to the damage of critical neuronal structures by the primary or recurrent tumor and/or to the adverse effects of the therapeutic interventions. Notably, the severity of the radiation-induced late toxicity (endocrine, visual, hypothalamic, neurocognitive) is associated with the total and per fraction doses, the volume of the exposed normal tissue, and the young age in childhood populations (26). It has been proposed that the use of modern high-energy machines and irradiation doses of 55 Gy or less at 1.8 Gy per fraction should minimize toxicity (45).

1. Endocrine.

Partial or complete hypopituitarism is encountered in a substantial number of patients. In series including subjects with various treatment modalities and follow-up periods, the frequency of individual hormone deficits ranges from 88–100% for GH (46), 80–95% for FSH/LH (46,47), 55–88% for ACTH (46,47), 39–95% for TSH (46,47), and 25–86% for antidiuretic hormone (46,47).

Moreover, at least three pituitary hormone deficiencies have been reported in 54–100% (47). Apart from symptomatic Diabetes Insipidus, which is probably more common in surgically treated patients, the long-term endocrine morbidity is not affected by the type of tumor therapy (46, 47). It has also been suggested that there is no significant difference in the long-term endocrine morbidity between childhood- and adult-onset diseases (46).

The phenomenon of growth without GH has been reported in some children with craniopharyngioma who show normal or even accelerated linear growth, despite their untreated GH deficiency (47). The pathophysiological mechanism has not been clarified; the obesity-associated hyperinsulinemia or the presence of hyperprolactinemia has been proposed as a factor stimulating growth by affecting serum concentrations of IGF-1 or by binding directly to the IGF-1 receptor. Finally, large observational studies support the view that GH replacement in children and adults does not increase the risk of tumor recurrence (42). Studies with appropriate control groups are required to confirm this finding.

2. Visual.

The visual outcome is compromised in a significant number of patients. Duff *et al.* found that 62.5% of 121 patients treated by surgery alone or combined with radiotherapy exhibited at least quadrantanopia during a mean observation period of 10 years (2). Karavitaki *et al.*(1) in a series of 97 patients treated with similar modalities, estimated that the cumulative probability for major visual field defects at 10-yr follow-up was 48% (1). Pereira *et al.* reported deterioration of visual fields/acuity in 36% of 54 patients treated by surgery with or without adjuvant RT and followed up for a median period of 10 years.

The visual outcome is adversely affected by the presence of visual symptoms at diagnosis (49) and by daily irradiation doses above 2 Gy; it is not significantly associated with age at diagnosis or tumor histopathological findings. Furthermore, Karavitaki *et al.* suggested that among patients treated by complete resection or partial resection followed or not by irradiation, the deterioration of vision is more common in the partial resection only group, probably as a consequence of their significantly increased recurrence rates (1).

3. Hypothalamic.

Hypothalamic damage may result in hyperphagia and uncontrollable obesity (28, 40). Disorders of thirst and water/electrolyte balance, behavioral, cognitive impairment, loss of temperature control, disorders in the sleep pattern and reduced nocturnal melatonin levels may arise (2, 45, 47).

Obesity is the most frequent manifestation of hypothalamic damage reported in 26–61% of the patients treated by surgery combined or not with radiotherapy (2, 34, 46). It results from the disruption of the mechanisms controlling satiety, hunger, and energy balance. In a study of 63 survivors of childhood craniopharyngioma, all subjects with marked obesity after surgery had evidence of significant alterations of the normal hypothalamic anatomy, with their MRI showing either complete deficiency or extensive destruction of the floor of the third ventricle (34).

Possible contributing mechanisms include lack of sensitivity to endogenous leptin, vagally mediated hyperinsulinemia, and autonomic imbalance, as well as reduced physical activity, which is exaggerated by the neurological defects, the visual failure, and the somnolence.

Interestingly, high levels of the orexigenic gastric hormone ghrelin have not been found in these patients. Hypothalamic obesity often results in devastating metabolic and psychosocial complications, necessitating provision of dietary and behavioral modifications, encouragement of regular physical activity, psychological counseling, and antiobesity drugs.

Diabetes Insipidus with an absent or impaired sense of thirst confers a significant risk of serious electrolyte imbalance and is one of the most difficult complications to manage (47, 50). De Vile et al. found this abnormality in 14% of children treated primarily by complete or subtotal tumor excision with or without irradiation; notably, all the identified subjects had other evidence of significant hypothalamic dysfunction (47).

Smith *et al.* (50) reported absence of thirst in 19% of adults with Diabetes Insipidus previously offered surgery combined or not with radiotherapy. In this group of patients, the maintenance of the osmotic balance has been shown to be precarious, with recurrent episodes of hyper- or hyponatremia contributing to morbidity and mortality (47, 50). Careful fluid balance in and out and regular weighing are important.

Factors associated with significant hypothalamic morbidity are young age at presentation in children (51), manifestations of hypothalamic disturbance at diagnosis (45), hypothalamic invasion (51), tumor height greater than 3.5 cm from the midline (45), attempts to remove adherent tumor from the region of hypothalamus (45), multiple operations for recurrence (51), and hypothalamic radiation doses greater than 51 Gy.

4. Neuropsychological and cognitive/functional outcome.

The deterioration of the neuropsychological and cognitive function in patients with craniopharyngioma contributes significantly to poor academic and work performance, compromised family and social relationships, and impaired quality of life (48, 52).

Duff *et al.* (2) in a series of 121 patients treated by surgery with or without adjuvant radiotherapy and followed up for a mean period of 10 yr, found poor outcome in 40% of subjects [the outcome was based on motor deficits, vision, dependence for activities of daily living, Karnofsky Performance Scale (assessing the ability to perform normal activity

and to do active work and the need for assistance), school and work status, and debilitating psychological or emotional problems].

Pereira *et al.* (48) in a study of 54 consecutive patients offered surgery with or without additional radiotherapy and followed up for a median interval of 10 yr, showed that 47% had psychosocial impairment (evaluated by independent living, social integration, professional occupation, and school performance) and 49% had neurological morbidity (defined as the presence of any of the following: concentration problems, personality changes, short-term memory loss, anosmia, or epilepsy).

De Vile *et al.* (45) in a series of 75 children who had surgical removal followed or not by irradiation and followed up for a mean period of 6.4 yr, demonstrated that 40% of them had IQ below 80 and 23% had severe motor disorders combined or not with epilepsy.

Karavitaki *et al.* (1) in a series of 121 patients treated by surgery with or without RT, found cumulative probabilities for permanent motor deficits, epilepsy, psychological disorders necessitating treatment, and complete dependency for basal daily activities at 10-yr follow-up of 11, 12, 15, and 9%, respectively. At the same time period, almost one fourth of the adults or children were unable to work in their previous occupation or were behind their expected school status.

Graham *et al.* (53) in a study of 40 children treated by surgery combined or not with radiotherapy, showed that the conservative surgery with adjuvant irradiation group was the one with the most consistent return to school and achievement of employment or tertiary education.

Prospective studies with formal neuropsychological testing and specific behavioral assessments before and after any intervention are needed to elucidate this issue; these data will be particularly important for the young children in whom the questions of whether delaying irradiation is a reasonable policy, and whether the neurotoxicity of the recurrent disease and the subsequent surgery is higher than the one associated with irradiation offered to prevent relapse, need to be answered. The assessment of the treatment option providing the most favorable functional outcome is difficult, because the experience of the

neurosurgeon, the recurrences, and the subsequent therapeutic interventions contribute to the final result.

The comparative evaluation of published studies is further complicated by the variable, often subjective, and not validated parameters defining the 'good' outcome. Moreover, most of them assess patients treated before the advances in neurosurgery, imaging, and radiotherapy techniques, and often they do not take into account the status of the patients at diagnosis.

Yasargil *et al.* (29) reported that 5.7% of 51 children and 5.4% of 61 adults who underwent primary microsurgical complete excision had poor outcome (severe deterioration or unchanged poor condition, totally dependent, and with major medical problems). In this study, the outcome (evaluated by deterioration of the general condition, dependence, endocrine replacement, and psychoorganic syndrome) was significantly compromised in patients with large tumors or hydrocephalus or in those who underwent second or subsequent craniotomy for recurrence or uncontrolled growth of the original tumor (29).

De Vile *et al.* (45) found that the mean morbidity scores (based on endocrine deficiencies, vision, motor disorders and epilepsy, learning difficulties, behavioral problems, IQ, hypothalamic dysfunction) were not different between children who received radiotherapy after SR and those who had complete removal (45). However, the scores of children with additional surgery for recurrence were higher than the ones after their initial surgery and higher than those of children without recurrence. They also suggest that severe hydrocephalus, occurrence of intraoperative complications (vascular or frontal lobe trauma), and young age at presentation were predictors of poor long-term outcome.

Interestingly, Duff *et al.* (2) suggested that gross total resection is associated with better clinical outcome, whereas there is no difference between patients who received or did not receive radiotherapy, children or adults, and patients diagnosed with the adamantinomatous or the papillary type. In this series, factors associated with poor outcome were lethargy, visual deterioration or papilloedema at presentation, tumor calcification and adhesiveness to surrounding neurovascular structures, as well as hydrocephalus. Weiner *et al.* (54) found that the Karnofsky Performance Status was

significantly lower in patients who underwent two or more operative procedures, whereas age or tumor histopathological findings could not predict this status .

Finally, Karavitaki *et al.* (1) found no difference in the cumulative probability of morbidities not present at diagnosis (hyperphagia/obesity, severe motor disorders, epilepsy, complete dependency for basal daily activities, and deterioration of work or school status) among patients treated by gross total resection, partial resection, or partial resection combined with radiotherapy.

5. Other.

Other rare long-term irradiation-attributed morbidities include vasculopathy and brain tumors, with reported cases of astrocytoma, meningioma, glioblastoma, and glioma.

B. Mortality

Importantly, craniopharyngiomas are associated with decreased survival; overall mortality rates of three to six times higher than that of the general population have been reported (48). The advances in neuroendocrinology, neuroradiology, microsurgery, supportive care, and radiation oncology techniques have contributed to improvements, so that in studies published during the last decade, the survival rates range between 80 and 91% at 5 yr (1,55) and between 83 and 92.7% at 10 yr (1,48,55).

Apart from those deaths directly attributed to the tumor (pressure effects to critical structures) and those related to the surgical interventions (1), the risk of cardio/cerebrovascular and respiratory mortality is enhanced. It has also been suggested that in childhood populations, the hypoadrenalism and the associated hypoglycemia, as well as the metabolic consequences of antidiuretic hormone deficiency and absent thirst, may contribute to the excessive mortality.

The data on the treatment option with the most favorable impact on survival are not consistent, and often the relevant studies lack statistical evaluations. Furthermore, the reported mortality rates are probably affected by the different therapeutic interventions for the recurrence(s) resulting in significant heterogeneity among the compared groups. Thus,

the 10-yr survival rates range from 81.3–100% after radiologically confirmed total removal (1,55), 25–86% after gross total resection or partial resection (1,55), 77–100% after partial resection and subsequent radiotherapy (1), and 81–100% after radiotherapy alone (56).

The lower limits of these rates represent data of earlier series. Selection bias in the choice of treatment, with less aggressive tumors being offered radiotherapy only, should also be taken into account. Karavitaki *et al.* found no significant difference in the 10-yr survival rates between patients treated by gross total resection (100%), partial resection alone (86%), and partial resection followed by radiotherapy (87%) (1).

The unfavorable effect of tumor recurrence on mortality is widely accepted (1), with 10-yr survival rates ranging between 29 and 70% (depending on the subsequent treatment modalities) (1). Interestingly, Jose *et al.* (57) suggests that the survival is not different among patients offered irradiation for recurrence or as adjuvant therapy after primary surgery and among those with recurrence subjected or not to salvage surgery before radiotherapy .

The impact of age at diagnosis as a prognostic factor of survival is controversial; some studies suggest better outcome in younger patients, others in older age groups, while others have found no difference between children and adults. Notably, neonates with craniopharyngioma have poor prognosis independently of tumor therapy, with death being the usual outcome (58). Pereira *et al.* (48) found that females had higher mortality but no gender differences have been confirmed (1).

The histological type and the consistency or location of the lesion (intrasellar, extrasellar, or both) have no prognostic significance (1, 59). Finally, no consistent results exist for the tumor size (59) or the presence of hydrocephalus (1, 29).

FOLLOW UP

Further Outpatient Care:

- Post-surgical follow-up should be planned in 1-2 weeks for all patients.
- Patients with subtotal resections and candidates for external beam radiation therapy should start radiation within 3 weeks of surgery. Patients with either complete resections or completed radiation should be seen every 3 months for the first post-surgical year, every 6 months for the second and third years and yearly thereafter.
- Each follow-up visit should include
 - (a) A brain MRI that should be used for comparison with previous films
 - (b) Correlation of the MRI with the clinical examination and neurocognitive testing results.

As a rule, consider neurocognitive testing for

- (a) presurgery and postsurgery patients
- (b) patients who underwent subtotal resection followed by radiation.

All patients should have neurocognitive testing whenever declining performance (e.g. school, work) is a concern or clinical examination reveals worsening neurocognitive deficits (e.g. problem solving, language, memory, apraxia).(60,61).

- In some patients, deficits encountered are related to radiation injury. These could be sorted out easily by the specific MRI findings and neurocognitive testing results. Subsequently, specific treatments can be employed. Close monitoring of endocrine symptoms, accompanied by confirmatory laboratory tests, is recommended for all patients. Most patients require several adjustments of their supplemental hormonal therapy during their postsurgical/postradiation phase and even years later.
- Aggressive preventive management of long-term multisystem morbidities is key for long-term survival. (41). A multiteam comprehensive approach is strongly recommended.
 - Panhypopituitarism was reported to be present in almost 90% of patients followed up for more than 10 years. Endocrinology long-term follow-up and monitoring is strongly recommended.
 - At 10 years, other highly prevalent morbidities are neurological (49%), psychosocial (47%), and cardiovascular (22%). Female sex is reported as an

independent predictor of increased cardiovascular, neurological, and psychosocial morbidity. Long-term follow-up should include appropriate endocrine replacement (to include estrogen in premenopausal women) and aggressive control of cardiovascular risk factors (blood pressure, weight, lipids, and glucose).

- Immunohistochemical studies and case reports caution on the possibly higher incidence of recurrence in patients receiving growth hormone and/or sex hormone replacement, as some craniopharyngiomas express IGF-1R, ER, and PRs. Close imaging follow-up (every 4-6 wk) and clinical monitoring would be indicated if sex hormone and/or growth hormone replacement is pursued. Immunohistochemical studies (IGF-1R, ER, and PR status) are valuable in allowing for recurrence risk stratification prior to initiation of replacement therapy.
- Additionally, because of the tendency for craniopharyngiomas to recur, repeat MRIs or CT scans should be obtained at least once a year for the first several years after surgery or radiation therapy.
- Because hormonal deficiencies can develop many years after radiation treatment, all individuals treated in this manner should have periodic evaluations by an endocrinologist throughout their lifetimes, not just in the immediate period after surgery.

PERFORMANCE STATUS

In medicine (oncology and other fields), **performance status** is an attempt to quantify cancer patients' general wellbeing. This measure is used to determine whether they can receive chemotherapy, whether dose adjustment is necessary, and as a measure for the required intensity of palliative care. It is also used in oncological randomized controlled trials as a measure of quality of life.

There are various scoring systems. The most generally used are the *Karnofsky score* and the *Zubrod score*, the latter being used in publications by the WHO. For children, the *Lansky score* is used. (Appendix II). Karnofsky and Lansky scores were used in this study.

3.0 STUDY RATIONALE AND JUSTIFICATION

Craniopharyngiomas account for 1-3% of intracranial tumours and there are increased numbers of patients diagnosed with craniopharyngiomas at KNH for the last few years. This could be as a result of increased awareness and availability of CT scan. There is no standardized treatment modality and standardized outcome measures. Hence the need for this study.

Apart from the work done by Madelle in 2004 who studied an all inclusive prospective study on intracranial tumors in KNH, no studies have been done specifically on craniopharyngiomas in our set up. No local study had been done to determine the presentation, modes of management and outcome in relation to craniopharyngiomas.

The study did this by reviewing the presentation, management and outcome of patients with craniopharyngiomas treated at KNH within the period January 2003 to December 2008.

3.1 OBJECTIVES

3.1.1 Main Objective

To look at the incidence, management and outcome of Craniopharyngiomas at Kenyatta National Hospital.

3.1.2 Specific Objectives

1. To determine the demographic information (data) of patients presenting with craniopharyngiomas.
2. To determine the clinical presentations and investigations carried out among patients with craniopharyngiomas treated at Kenyatta National Hospital.
3. To determine the various treatment modalities offered and their outcomes.

3.2 STUDY METHODOLOGY

3.2.1 Study Design

This is a descriptive hospital-based retrospective and prospective study to enable the researcher to get the required sample size due to the few number of patients.

3.2.2 Study Setting

The study was conducted at the neurosurgery Clinic, Neurosurgical Ward, Paediatrics, Medical Wards and casualty. Histological results were retrieved at the pathology department and patients' files were retrieved from the records departments.

3.2.3 Study Population

The cases treated from January 2003 to December 2008 at the above mentioned units with a diagnosis of craniopharyngioma were recruited to the study and cases were followed for a duration of three to six months after treatment. Records of retrospective clients were retrieved and great effort used to follow up and interview patients taking part in the study. The Karnofsky score, Lansky score, visual and motor deficits on admission; 1 week, three months and six months postoperatively were recorded. Assistance of the ophthalmologists was required to assess visual acuity.

3.2.4 Sample size

$$N = \frac{Z^2 \alpha P (1-P)}{d^2}$$

where by:

N = Sample number

P = Prevalence of craniopharyngiomas among patients admitted with brain tumors (2%)

Z = Standard errors from the mean corresponding to 95% confidence interval.

d = margin of error (absolute precision) (5%)

α = level of significance

The sample size was 30 patients .

3.2.5 Inclusion/exclusion criteria

i) Inclusion Criteria

- All patients with confirmed diagnosis and admitted with craniopharyngioma in any department during the study period within the Kenyatta National Hospital.
- Patients who gave a voluntary informed consent.

ii) Exclusion Criteria

- Patients outside the above inclusion criteria.
- Patients done operations outside Kenyatta National Hospital.

3.2.6 Data Collection Procedure

The Information was collected using a data collection sheet (questionnaire). The same questionnaire was used for both the retrospective and prospective parts of the study. Demographic data including the age, sex was collected. The presenting symptoms, signs and investigations done including laboratory and radiological prior to intervention and comorbidity factors like hypertension, diabetes and others were recorded. Pre-operative care, treatment modalities and complications after treatment were documented.

Scoring of retrospective clients as per the Karnofsky and Lansky Scores was determined from the patients' file before admission, post-operatively and findings recorded in the file during the follow-up visits were used and every effort was tried to follow up the patients at the Neurosurgical Clinic. The contacts recorded in the file were sought if the patients would have absconded to attend the follow-up clinics.

Scoring of prospective patients as per the Karnofsky and Lansky Scores was determined by the researcher on admission, one week post-operatively and three months post-operatively and the patients were followed up for a maximum period of six months.

3.2.7 Data Analysis

Version 11.1 of SPSS statistical package and excel was used for data analysis and presented in charts, graphs and tables.

Descriptive statistics for parametric and non-parametric data was performed and the data was subjected to tests of statistical significance namely the chi square test, Fischer's and Students T-Test where a P value of less than 0.05 was considered significant.

3.2.8 Ethical Aspects

1. Application was made to the Ethical and Research Committee of the Kenyatta National Hospital for permission to carry out the study at the institution and the study was commenced upon approval.
2. Patients were asked for their informed voluntary signed consent before being enrolled into the study.
3. Patients' records were handled with confidentiality.

3.2.9 STUDY LIMITATIONS

1. The duration was short for the prospective arm of the study.
2. Poor follow up of patients in the neurological clinic.

UNIVERSITY OF NAIROBI
MEDICAL LIBRARY

4.0: RESULTS

4.1: Incidence

The study assessed 41 patients who had been managed as cases of craniopharyngiomas from 2002 to 2008. Twenty nine (71%) of the study subjects were assessed prospectively and 12 (29%) were assessed retrospectively. Over the study period of 2003-2008, there were 577 tumors treated at KNH, of which 41 (7.17%) were craniopharyngiomas. Figure 1 below shows the proportion of brain tumors that were cases of craniopharyngioma treated at KNH over the period.

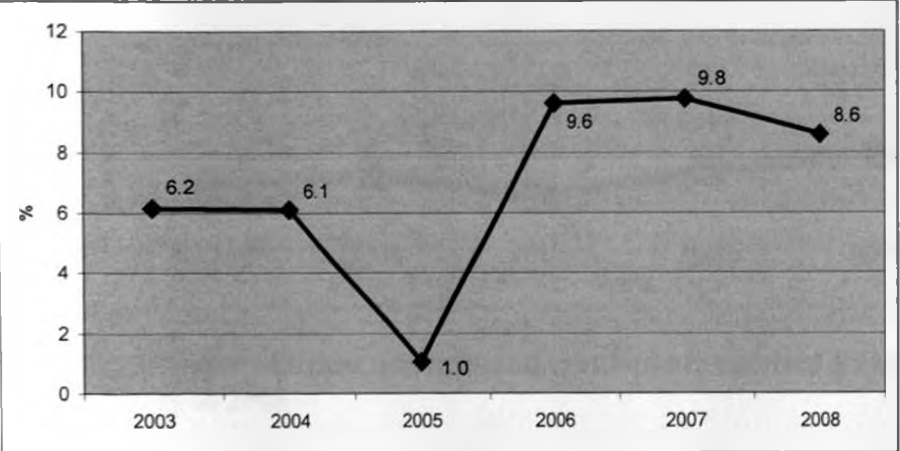


Figure 1: Proportion of tumors that were craniopharyngiomas treated at KNH between 2003-2008

There were 577 brain tumours treated at KNH between 2003 to 2008 and 41 were craniopharyngiomas as shown in Figure 2 below.

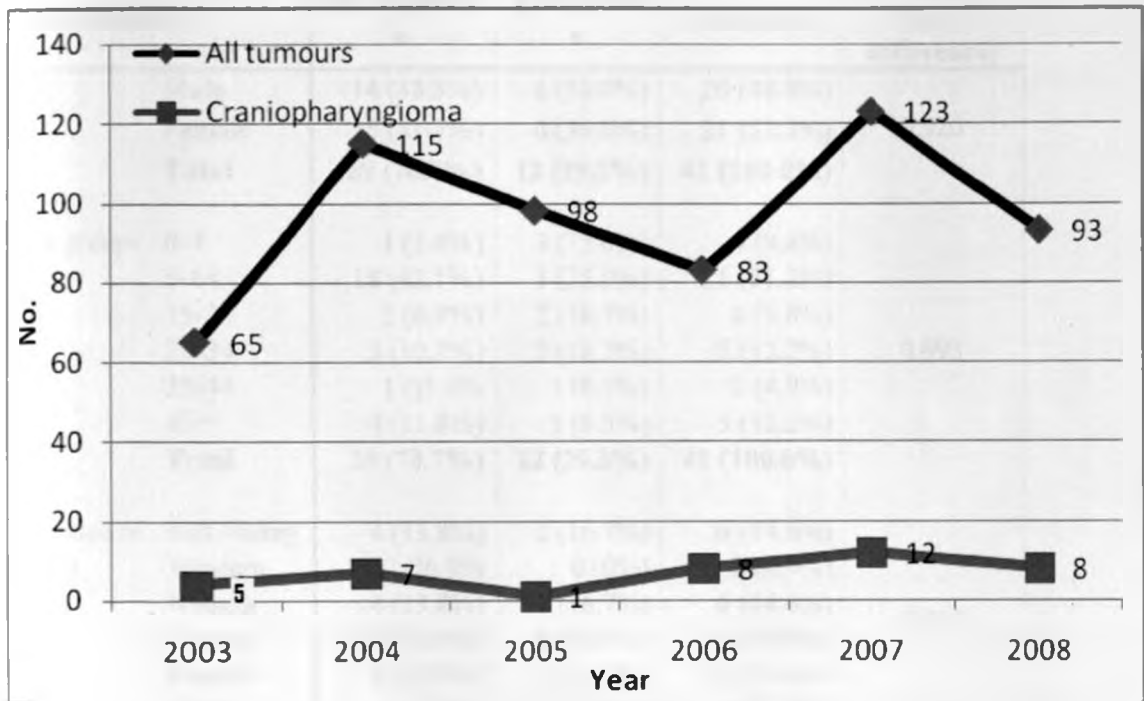


Figure 2: Number of brain tumours and craniopharyngiomas treated at KNH between 2003 to 2008

4.2: Demographics

There were 20 (48.8%) males and 21 (51.2%) females among the study subjects. The mean age was 18.3 years with a mode of 5 and a standard deviation of 15.9 years. The youngest was less than 1 year and the oldest was 59 years. As shown in Table 1 below, craniopharyngioma was commonest in the age group 5-14 years (51.2%). Most of the subjects with the tumour were from the Central Province (39%) and Eastern (24.4%).

Table 1: Demographic characteristics

Characteristic		Retrospective	Prospective	Combined	P value (of difference)
Sex	Male	14 (48.3%)	6 (50.0%)	20 (48.8%)	0.920
	Female	15 (51.7%)	6 (50.0%)	21 (51.2%)	
	Total	29 (70.7%)	12 (29.3%)	41 (100.0%)	
Age groups	0-4	1 (3.4%)	3 (25.0%)	4 (9.8%)	0.993
	5-14	18 (62.1%)	3 (25.0%)	21 (51.2%)	
	15-24	2 (6.9%)	2 (16.7%)	4 (9.8%)	
	25-34	3 (10.3%)	2 (16.7%)	5 (12.2%)	
	35-44	1 (3.4%)	1 (8.3%)	2 (4.9%)	
	45+	4 (13.8%)	1 (8.3%)	5 (12.2%)	
	Total	29 (70.7%)	12 (29.3%)	41 (100.0%)	
Province of origin	Rift Valley	4 (13.8%)	2 (16.7%)	6 (14.6%)	0.810
	Western	2 (6.9%)	0 (0%)	2 (4.9%)	
	Nyanza	4 (13.8%)	2 (16.7%)	6 (14.6%)	
	Central	10 (34.5%)	6 (50.0%)	16 (39.0%)	
	Eastern	8 (27.6%)	2 (16.7%)	10 (24.4%)	
	Coast	1 (3.4%)	0 (0%)	1 (2.4%)	
	Total	29 (70.7%)	12 (29.3%)	41 (100.0%)	

As shown in Figure 3 below, the craniophryngioma was more common in the younger population than in the older one.

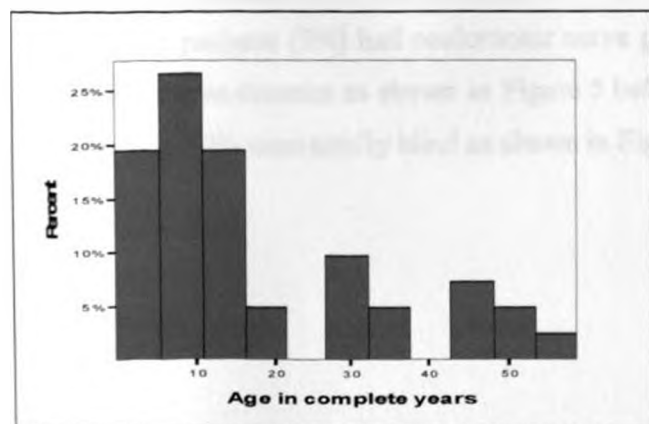


Figure 3: Age distribution (n=41)

4.3: Presenting Complains

Thirty seven patients (90%) had headache, thirty two patients (78%) had visual disturbances, twenty three patients (56%) had vomiting and ten patients (24%) had convulsions. Six patients (15%) had memory and sleep disorders, three patients of those ≥ 15 years (12.5%) had amenorrhea/sexual dysfunction, two patients (5%) had incontinence and two patients (5%) had thirst/polyuria as shown in Figure 4 below.

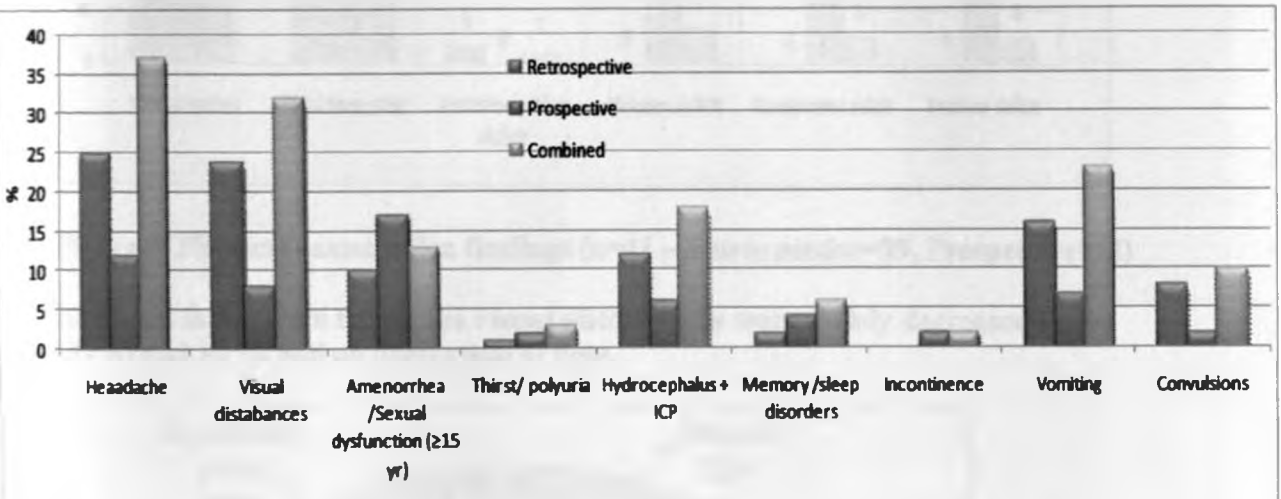


Figure 4: Presenting complains (n=41 – Retrospective=29, Prospective=12)

4.4: Physical Examination Findings

Fourteen patients (34%) had motor disorders, fourteen patients (34%) had facial nerve palsy, three patients (7%) had abducens nerve palsy, two patients (5%) had trochlear nerve palsy, two patients (5%) had oculomotor nerve palsy and one patient (2%) had vestibulo-cochlear nerve disorder as shown in Figure 5 below. 39% of patients had decreased visual aquity and 39% were totally blind as shown in Figure 6 below.

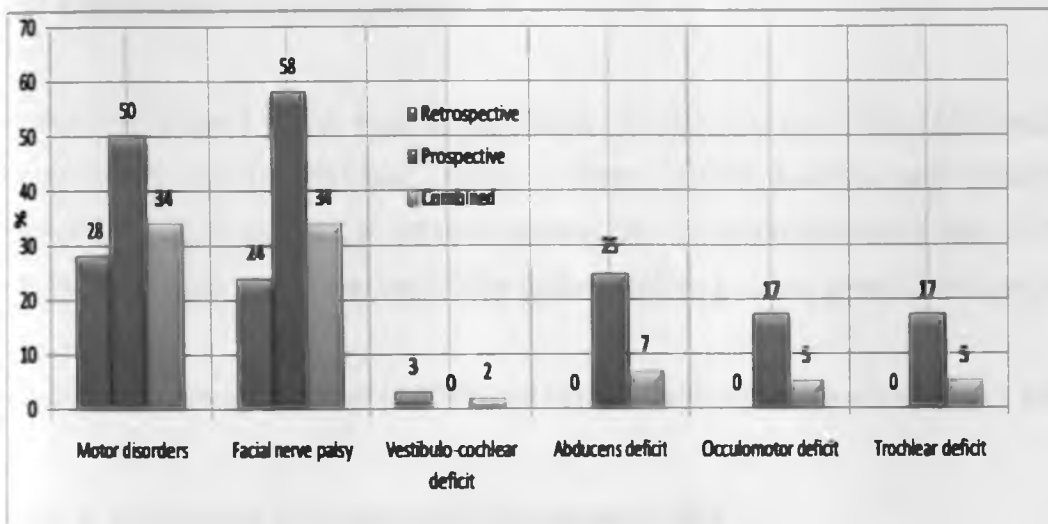


Figure 5: Physical examination findings (n=41 – Retrospective=29, Prospective=12)

As shown in Figure 6 below, the visual disturbances were mainly decreased vision (39%) and 39 % had no perception of light.

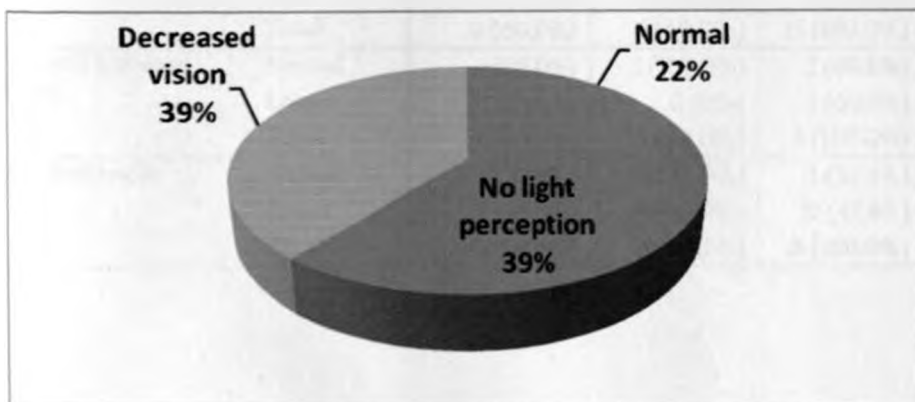


Figure 6: Distribution of Visual Findings (n=41)

4.5: Laboratory investigations

As shown in Table 2 below, Four out of fifteen (26.7%), two out of five (40%) and eleven out of twenty one (52.4%) had normal prolactin, growth hormone and cortisol levels respectively. Nine out of 15 (60.0%) patients had hyperprolactinemia and 13.3% had hypoprolactinemia while three out of five patients (60%) had low growth hormone levels.

Ten out of twenty one patients (47.6%) had hypocortisolemia as shown in table 2 below. .

Table 2: Laboratory investigations – Hormonal profile

Investigations		Retrospective	Prospective	Combined	P value (of difference)
Prolactin levels	Normal	4 (44.4%)	0 (0%)	4 (26.7%)	0.161
	Lower	1 (11.1%)	1 (16.7%)	2 (13.3%)	
	High	4 (44.4%)	5 (83.3%)	9 (60.0%)	
	Total	9 (60.0%)	6 (40.0%)	15 (100.0%)	
Growth hormone levels	Normal	1 (25.0%)	1 (100.0%)	2 (40.0%)	0.171
	Lower	3 (75.0%)	0 (0%)	3 (60.0%)	
	Total	4 (80.0%)	1 (20.0%)	5 (100.0%)	
Cortisol levels	Normal	7 (53.8%)	4 (50.0%)	11 (52.4%)	0.864
	Lower	6 (46.2%)	4 (50.0%)	10 (47.6%)	
	Total	13 (61.9%)	8 (38.1%)	21 (100.0%)	

As shown in Table 3 below, all patients had normal pre-operative hemoglobin, six patients (14.6%) had low electrolytes levels and thirty five patients (85.4%) had normal urea and electrolytes levels. Twenty two patients were done thyroid function test (TFT). Seventeen out of twenty two (77.3%) had normal TFTs and five (22.7%) of patients had hypothyroidism.

Table 3: Other laboratory investigations

Laboratory investigations		Retrospective	Prospective	Combined	P value (of difference)
Haemoglobin	10-12	7 (24.1%)	4 (33.3%)	11 (26.8%)	0.545
	12+	22 (75.9%)	8 (66.7%)	30 (73.2%)	
	Total	29 (70.7%)	12 (29.3%)	41 (100.0%)	
Urea & Electrolytes	Normal	27 (93.1%)	8 (66.7%)	35 (85.4%)	0.05
	Lower	2 (6.9%)	4 (33.3%)	6 (14.6%)	
	Total	29 (70.7%)	12 (29.3%)	41 (100.0%)	
Thyroid Function T3 Tests	Normal	11 (84.6%)	6 (66.7%)	17 (77.3%)	0.609
	Lower	2 (15.4%)	3 (33.3%)	5 (22.7%)	
	Total	13 (59.1%)	9 (40.9%)	22 (100.0%)	
T4	Normal	10 (76.9%)	7 (77.8%)	17 (77.3%)	0.962
	Lower	3 (23.1%)	2 (22.2%)	5 (22.7%)	
	Total	13 (59.1%)	9 (40.9%)	22 (100.0%)	
TSH	Normal	12 (92.3%)	5 (55.6%)	17 (77.3%)	0.025
	Lower	0 (0%)	4 (44.4%)	4 (18.2%)	
	High	1 (7.7%)	0 (0%)	1 (4.5%)	
	Total	13 (59.1%)	9 (40.9%)	22 (100.0%)	

4.6: Radiological investigations

Forty (97.6%) of the patients were done CT-Scanning and MRI was done in one patient. Twenty six (63.4%), four patients (9.8%) and eleven patients (26.8%) had suprasellar, intrasellar and intrasellar with suprasellar extension on radiological imaging as shown in Table 4 and Figure 7 below.

Table 4: Radiological examination

		Retrospective	Prospective	Combined	P value (of difference)
Radiological Test	CT scan	28 (96.6%)	12 (100.0%)	40 (97.6%)	0.515
	MRI	1 (3.4%)	0 (0%)	1 (2.4%)	
	Total	29 (70.7%)	12 (29.3%)	41 (100.0%)	
Site of lesion	Suprasellar	20 (69.0%)	6 (50.0%)	26 (63.4%)	0.103
	Intrasellar	1 (3.4%)	3 (25.0%)	4 (9.8% ())	
	Intra-suprasellar	8 (27.6%)	3 (25.0%)	11 (26.8%)	
	Total	29 (70.7%)	12 (29.3%)	41 (100.0%)	
Radiological diagnosis	Craniopharyngioma	29(100.0%)	12 (100.0%)	41(92.7%)	
	Total	29 (70.7%)	12 (29.3%)	41 (100.0%)	

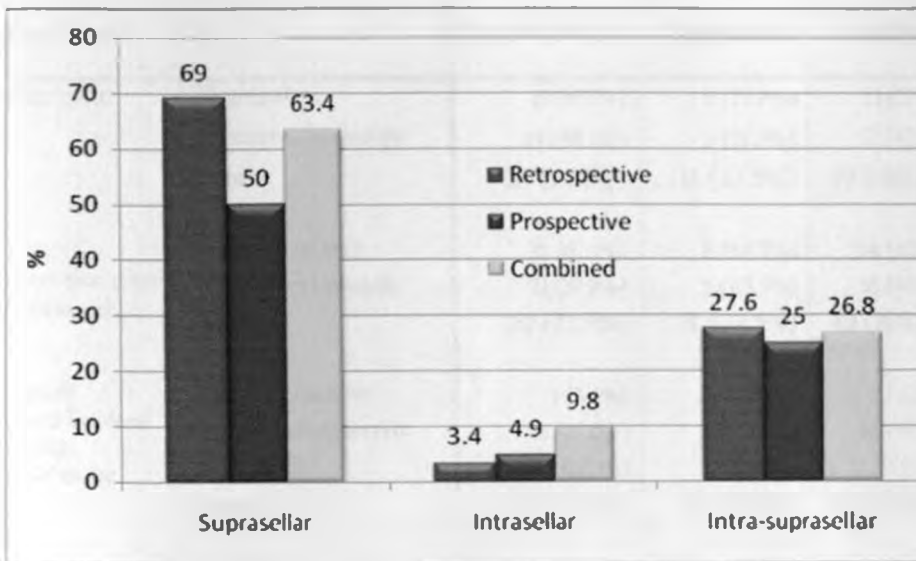


Figure 7: Site of the lesion (n=41)

4.7: Treatment

Forty patients were done craniotomies and one patient died before surgery. Twenty three (57.5%) of the patients had surgery alone and seventeen (42.5%) underwent radiotherapy in addition to surgery. Thirty six (90.0%), three (7.5%) and one (2.5%) of the patients had partial excision/decompression, biopsy only and complete excision respectively during craniotomy and 23(57.5%), underwent additional surgical procedures to relieve hydrocephalus.

Twenty patients had VP shunts and ETV was done for three patients. A total of forty eight craniotomies were done, six patients had two craniotomies and one patient had three craniotomies done due to confirmed tumour recurrence on follow-up as shown in table 5 below. Twenty four (60%) were operated within one month of admission and sixteen patients (40%) were operated more than one month after admission.

Table 5: Treatment Modalities

Treatment		Retrospective	Prospective	Combined	P value (of difference)
Treatment	Surgery alone	15 (51.7%)	8 (72.7%)	23 (57.5%)	0.230
	Surgery+ radiotherapy	14 (48.3%)	3 (27.3%)	17 (42.5%)	
	Total	29 (72.5%)	11 (27.5%)	40 (100.0%)	
Time of operation after admission	Within 1 month	18 (62.1%)	6 (54.5%)	24 (60.0%)	0.665
	More than 1 month	11 (37.9%)	5 (45.5%)	16 (40.0%)	
	Total	29 (72.5%)	11 (27.5%)	40 (100.0%)	
Type of operation done during craniotomy	Complete excision	1 (3.4%)	0 (0%)	1 (2.5%)	0.012
	Partial/decompression	28 (96.6%)	8 (72.7%)	36 (90.0%)	
	Biopsy only	0 (0%)	3 (27.3%)	3 (7.5%)	
	Total	29 (72.5%)	11 (27.5%)	40 (100.0%)	
Other surgical procedures performed	v-p shunts	14 (87.5%)	6 (85.7%)	20 (87.0%)	0.907
	Etv	2 (12.5%)	1 (14.3%)	3 (13.0%)	
	Total	16 (69.6%)	7 (30.4%)	23 (100.0%)	

4.8: Complications after surgical treatment

Forty patients were done craniotomies, no intra-operative death was reported. Thirteen patients (32.5%), seven (17.5%), nine (22.5%), seven (17.5%) and five (12.5%) had residual neurological deficits, diabetes insipidus, seizures, deteriorating neurological status and hydrocephalus respectively after surgical intervention as shown in Figure 8 below. Post-operative infections (meningitis, wound sepsis and pneumonia) occurred in seven patients (17.5%) during the follow-up period. Three patients (7.25%) had meningitis, one patient (2.0%) developed a wound infection and three patients (7.25%) developed pneumonia.

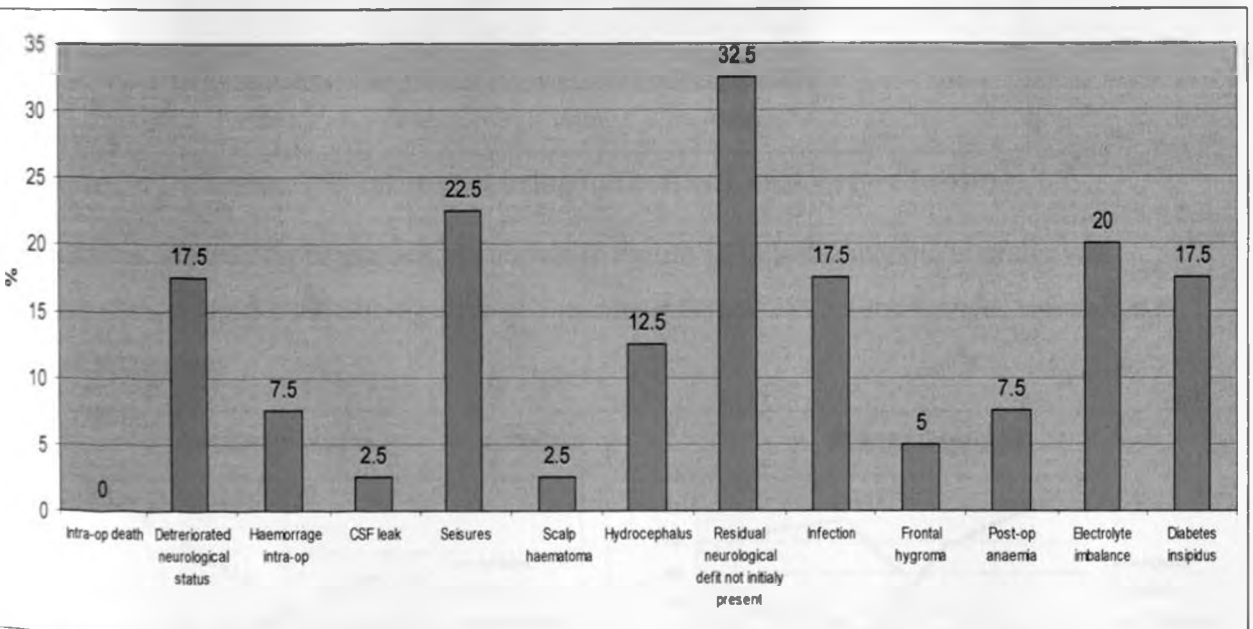


Figure 8: Complications after surgery

4.9: Outcome

Overall outcome: Twenty three (56.1%) of patients were dead, sixteen (39.0%) had a good and moderate performance and one (2.4%) had a poor performance after surgery or surgery combined with radiotherapy upon six months of follow-up as shown in Figure 9 below.

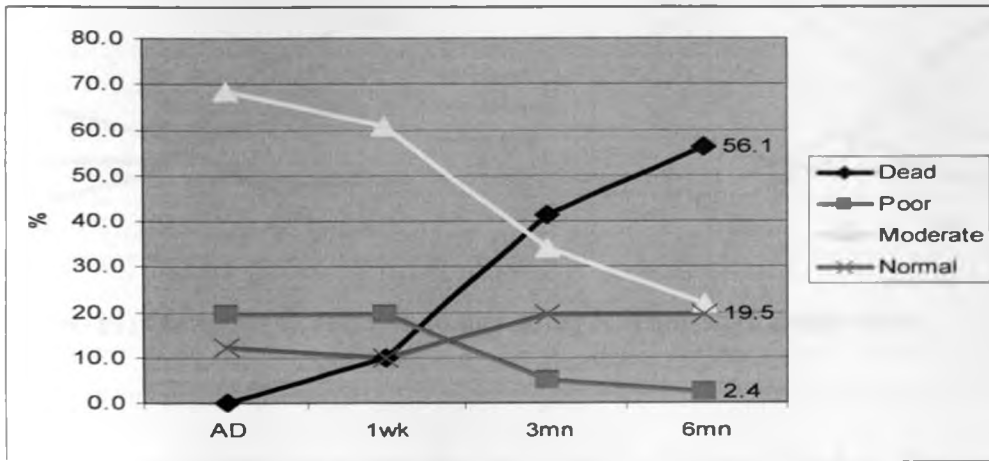


Figure 9: Outcome after treatment using Karnofsky/Lansky score (n=40)

Outcome in relation to gender: As shown in Figure 10 below, outcome in males was more favorable with 50% being alive at 6 months whereas 38% of the females were alive at the same period.

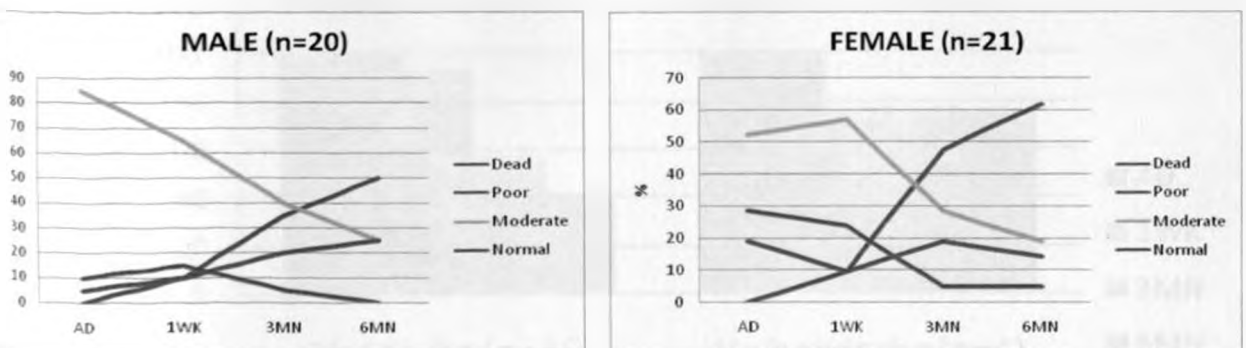


Figure 10: Outcome in relation to gender using Karnofsky/Lansky score

Outcome in relation to age: As shown in Figure 11 below, outcome in the patients aged 18 yrs and less was more favorable with 50% being alive at 6 months whereas 31% of those with more than 18 yrs being alive at the same period.

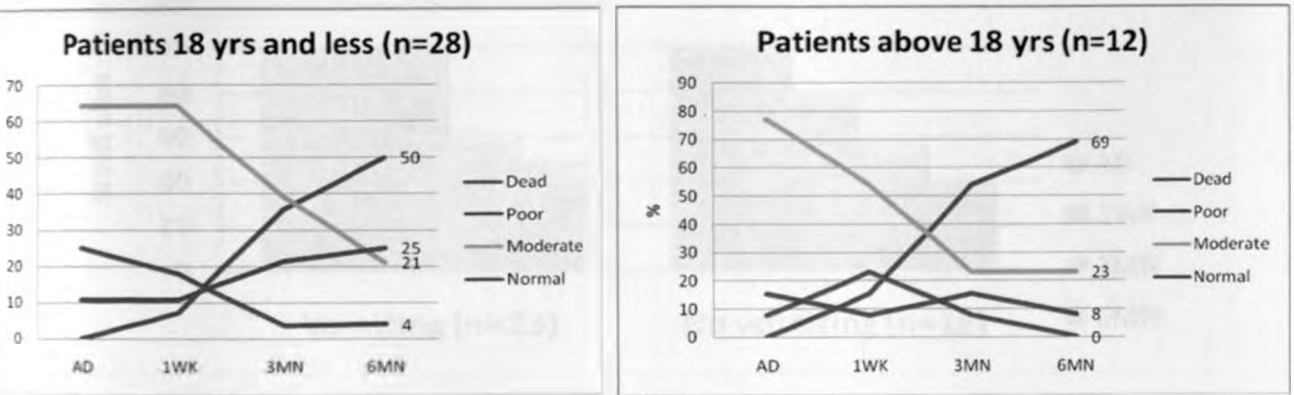


Figure 11: Outcome in relation to age using Karnofsky/Lansky score

Outcome in relation to headache: As shown in Figure 12 below. Outcome was more favourable in patients without headache with 75% being alive at 6 months whereas 41% of those with headache were alive at the same period.

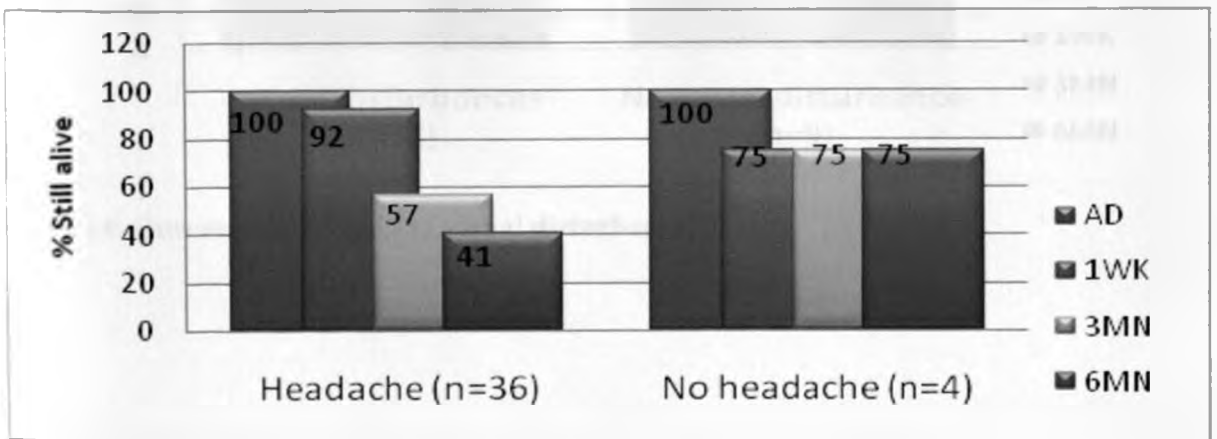


Figure 12: Outcome in relation to headache.

Outcome in relation to vomiting: As shown in Figure 13 below, outcome was more favourable in patients with vomiting with 48% being alive at 6 months compared to 39% in those without vomiting.

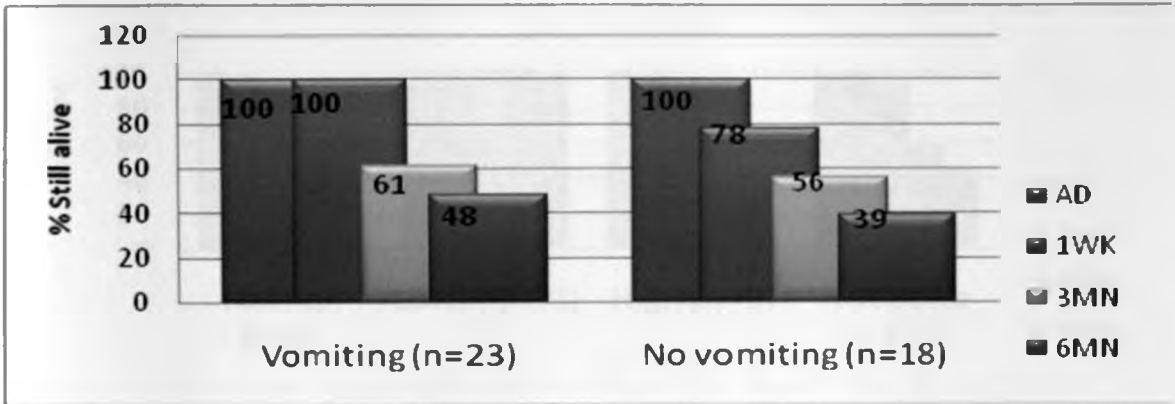


Figure 13: Outcome in relation to vomiting.

Outcome in relation to visual disturbance: As shown in Figure 14 below, outcome was better in patients with visual disturbances with 47% being alive at 6 months and only 33 % of those with out visual disturbance being alive at 6 months.

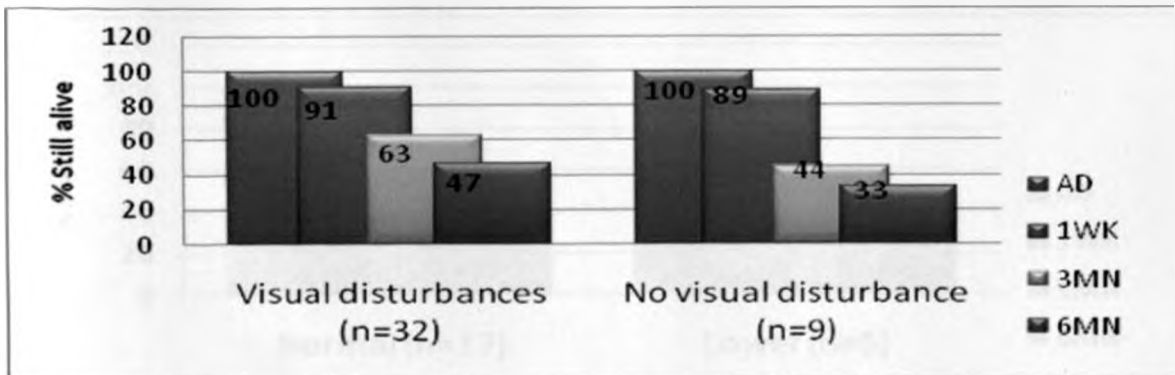


Figure 14: Outcome in relation to visual disturbance.

Outcome in relation to prolactin levels:

As shown in Figure 15 below, outcome was more favourable in patients with hypoprolactinemia and hyperprolactinemia with 100% and 44% being alive at 6 months and only 25% of patients with normal prolactin levels being alive at 6 months.

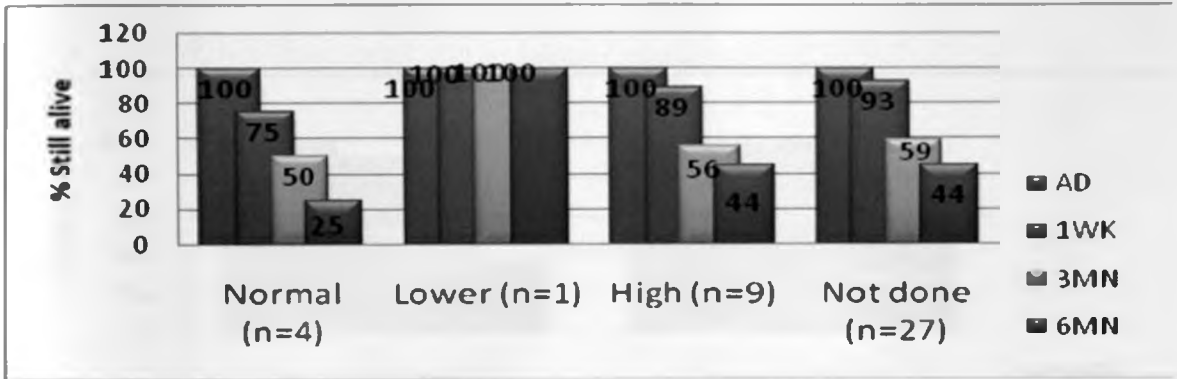


Figure 15: Outcome in relation to prolactin levels

Outcome in relation to triiodothyronine (T3) levels:

As shown in Figure 16 below, outcome was the same in patients with hypothyroidism and euthyroidism with 40% and 42% being alive at 6 months.

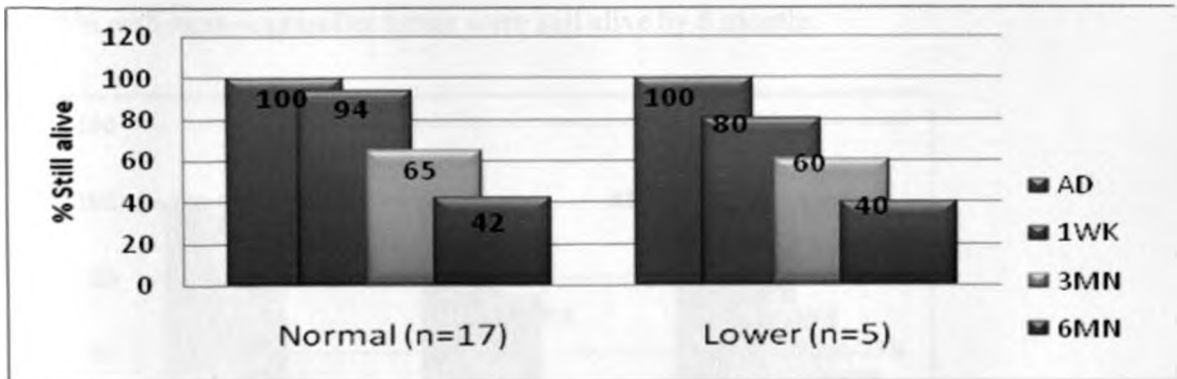


Figure 16: Outcome in relation to T3 levels.

Outcome in relation to cortisol levels: As shown in Figure 17 below, outcome was more favourable in patients with hypocortisolism with 60% being alive at 6 months whereas 36% of those with normal cortisol levels being alive at the same period.

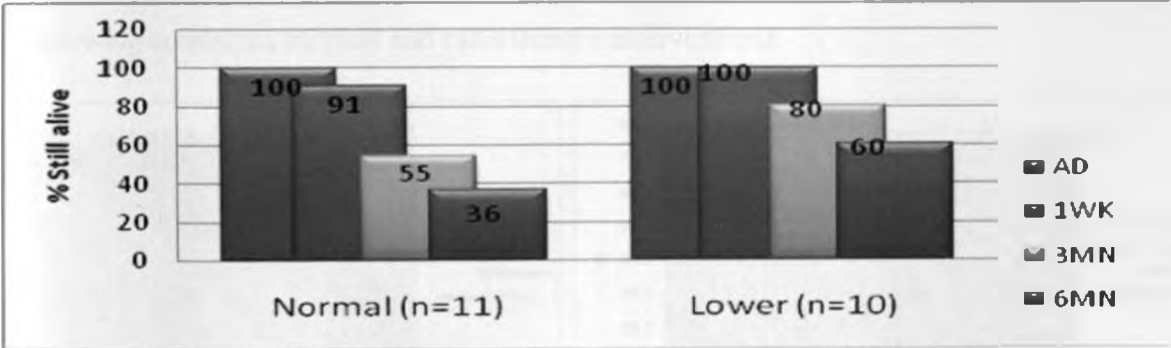


Figure 17: Outcome in relation to cortisol levels

Outcome in relation to radiological site of the lesion: As shown in Figure 18 below and using the Karnofsky/ Lansky score, 36% of patients with supraseller, 50% with intraseller and 55% with intra-supraseller tumor were still alive by 6 months.

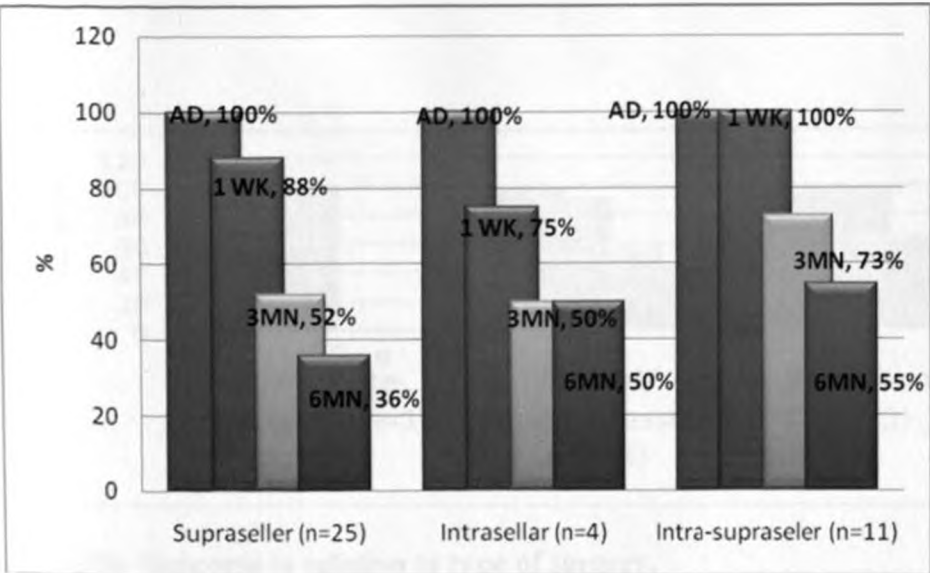


Figure 18: Outcome in relation to site of the lesion

Outcome in relation to type of treatment: As shown in Figure 19 below, 19 out of 23 (82.6%) of patients were dead, four (17.4%) had a good and moderate performance and none had a poor performance after six months of follow-up following surgical intervention alone; and 4 out of 17 (17.6%) patients were dead, twelve (76.5%) had a good and moderate performance and one (5.9%) had a poor performance after six months of follow-up following combined surgical and radiotherapy interventions.

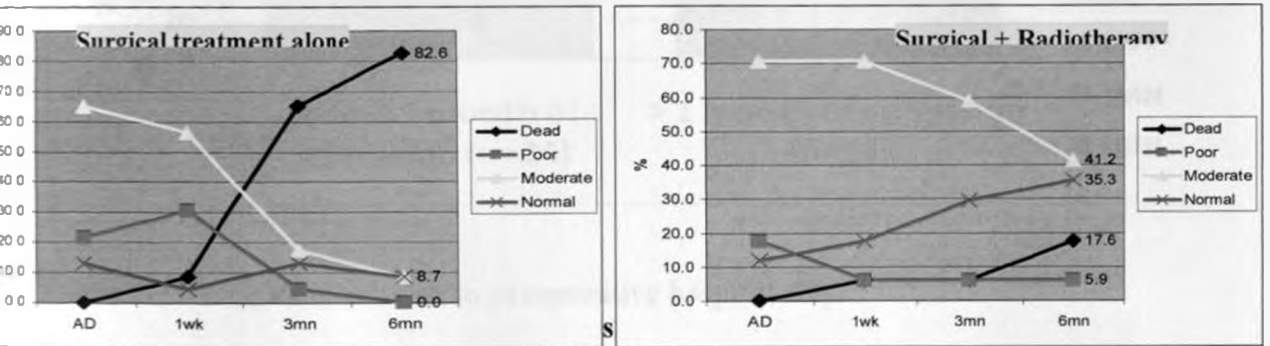


Figure 19: Outcome in relation to type of treatment

Outcome in relation to type of surgery:

As shown in Figure 20 below, outcome was more favourable in patients done biopsy only with 67% being alive at 6 months whereas 44% of those done partial excision/decompression being alive at 6 months. outcome was worse in the patient done complete excision.

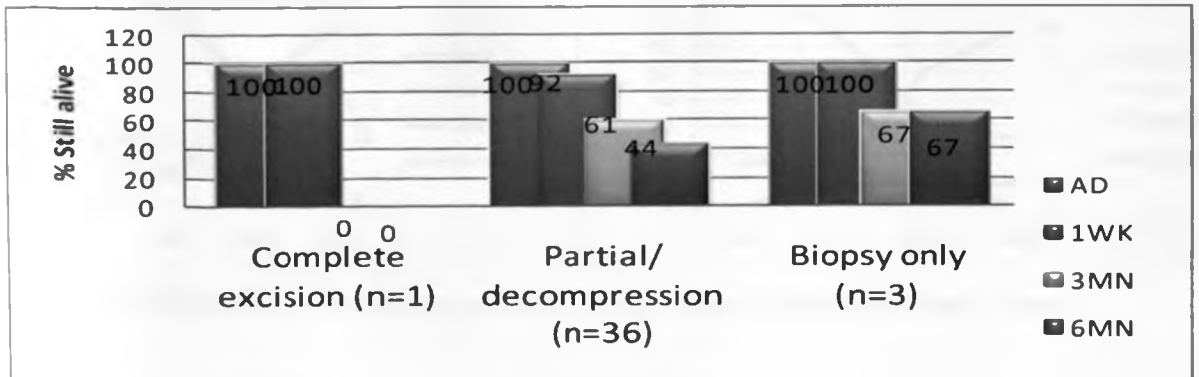


Figure 20: Outcome in relation to type of surgery.

Outcome in relation to preoperative hospital stay: As shown in Figure 21 below, outcome was the same in patients done craniotomy within one month and after one month from the date of admission with 46% and 44% being alive at 6 months respectively.

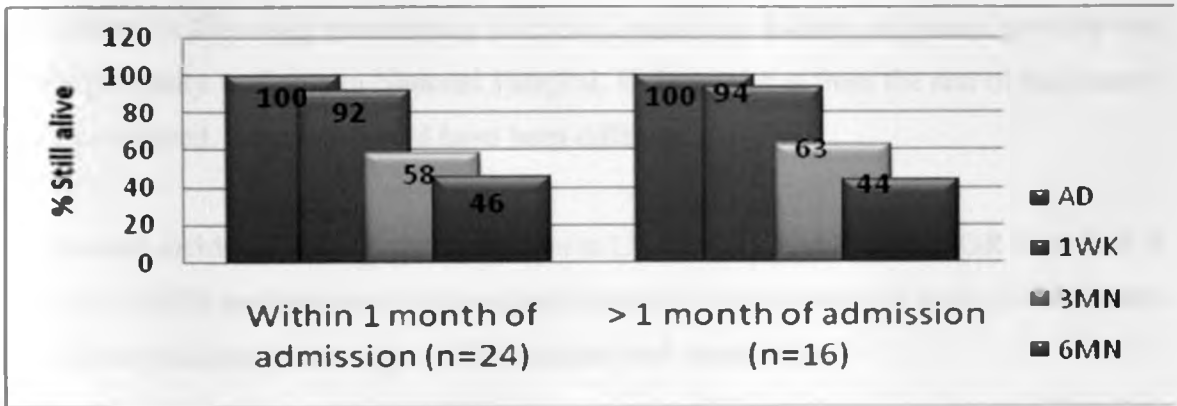


Figure 21: Outcome in relation to preoperative hospital stay.

Outcome in relation to period of study: As shown in Figure 22 below, patients studied retrospectively showed favourable response by the sixth month (48 % still alive) postoperatively compared to those studied prospectively (33% still alive)

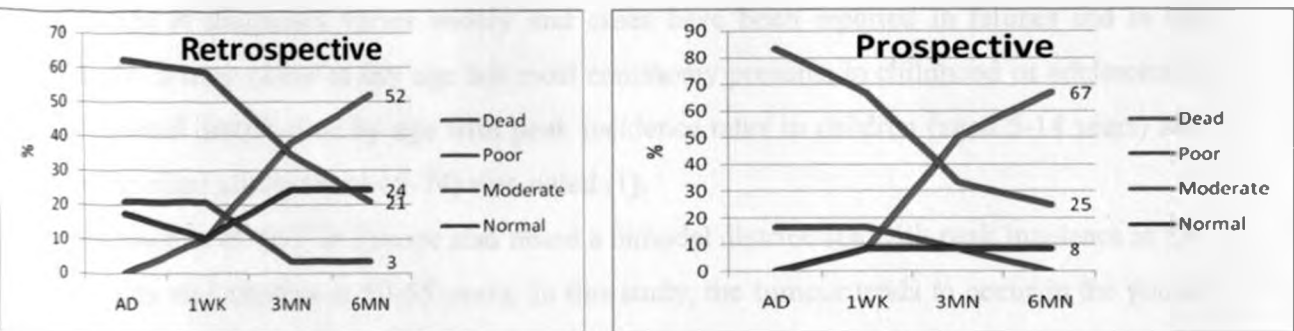


Figure 22: Outcome in relation to period of study using Karnofsky/Lansky score

5.0: DISCUSSION

In a study at KNH by Mahindu Madelle (18), the relative incidence of Craniopharyngioma was reported as 5.8 %. In this study the relative incidence is 7.1% which is different with the incidence reported by Cushing (16) and Ruberti (17) of 4.4% to 4.6%. The majority of the patients in this study were mainly from the Central and Eastern provinces probably due to the proximity to Kenyatta National Hospital. If the statistics from the rest of the country were considered, the results could have been different.

The overall incidence of craniopharyngioma in USA as reported by Bunin GR et al. (19) is 0.13 per 100,000 person years. 338 cases are expected to occur annually in the United States with ninety six cases occurring in children from 0-14 years of age.

There was no gender difference in the study subject. Bunin GR et al. (19) reported in their study that there is no variation by gender or race and Jennifer L. et al. (20) reported the same findings. Hoffman et al. (26) from the Hospital for sick children in Toronto in a study of total excision of craniopharyngioma in 50 children noted that the tumour was more common in boys than girls (56%, 44%) and this is supported by Nagpal et al. (62) and Baskin DS et al (31) (68%,32%) and (54%,36%).

The age at diagnosis varies widely and cases have been reported in fetuses and in the elderly. It may occur at any age but most commonly presents in childhood or adolescence. A bimodal distribution by age with peak incidence rates in children (aged 5-14 years) and among older adults (aged 65-74) was noted (1).

Fahlbusch et al. (63) in Europe also noted a bimodal distribution with peak incidence at 15-20 years and another at 50-55 years. In this study, the tumour tends to occur in the young age groups of 0-14 years and 15-24 years. There is no bimodal distribution noted in this study. Pat-kendall-Taylor, et al. (64) reported the peak age at onset as 15-20 years.

The most common presenting symptoms were headache (90%), visual disturbances (78%), which correspond to findings in other literature of headache (55-86%) and visual disturbances (37-68%). Honegger et al. (65) showed visual compromise in 75.0% of patients compared with 78.0% in this study. Baskin D. S et al. (31) found that considering the paediatric and adult population together, on physical examination 72% of patients have visual defects which corresponds to findings in this study whereby 78% of the patients had visual defects.

Nagpal et al. (62) found that the common presenting symptoms were headache and vomiting (48/63 -76%), diminished vision (44/63 – 70%) which corresponds to findings in this study. Other studies have reported the same (31, 66, 67, 68). Amenorrhoea/sexual dysfunction occurred in 3 out of 24 (12.5%) patients \geq 15 years which concurs with findings reported by Nagpal et al (62) of 8 out of 63 (13%) patients. Jennifer L. et al (20) found that most adult patients with craniopharyngioma present with amenorrhoea (64%), impotence or diminished libido (45%).

Facial nerve palsy occurred in 14 out of 41 (34%) of patients in this study but Nagpal et al (62) reported facial nerve palsy in 4 out of 63 patients (6.4%). This could be due to the late presentation of patients in resource poor settings and the tumour would have progressively increased in size compressing adjacent structures.

In this study Hypothyroidism (22.7%), hyperprolactinemia (60%) low growth hormone levels (60%) and hypocortisolism (47.6%) occurred in the tested population. In patients done hormonal tests, deficiency was found in 60% of patients compared to 39-43% in the literature. Hypothyroidism occurred in 22.7% of patients in this study which is comparable to published reports of 25% and hypocortisolism occurred in 47.69% of tested patients in this study which is also comparable to 50% in other studies. (20). This is due to the close anatomical relationship of the tumour with the pituitary and hypothalamus leading to compression of these structures and thus various hormonal deficiencies.

CT and MRI are the examinations of choice. Although today MRI is the imaging tool of choice almost all patients were done CT scanning. CT is available and more affordable in the resource poor settings.

Most Craniopharyngioma lesions were suprasellar or intra-sellar with suprasellar extension (90.2%) and only 9.8% were intrasellar. Craniopharyngioma lesions are located predominantly in the suprasellar area. Craniopharyngioma lesions are suprasellar (67%) and intrasellar (29%). Ten percent of craniopharyngioma lesions are purely suprasellar in a study by Jennifer et al. (20) and this is supported by Nagpal et al. (62) who reported suprasellar lesions/suprasellar extensions in 78% and only 1.6% of craniopharyngiomas were entirely intrasellar. This is related to development of the pituitary gland and the development of craniopharyngioma from the Rathke cleft and craniopharyngeal duct remnants (7).

Craniopharyngiomas are considered to be most effectively treated by a total excision (29, 69, 70, 71, 72). This is beset with many problems due to the close relationship of the tumours to the optic apparatus, carotid arteries, and the hypothalamus (70). Some tumours infiltrate into the hypothalamus (73, 68), limited space between the chiasma and the need to exert constant traction on the tumour during excision.

In this study complete excision was achieved in 1 out of 40 (2.5%), partial excision/decompression in 36 out of 40 (90.0%) and biopsy only in 3 out of 40 (7.5%). In a study by Nagpal et al. (62) Biopsy and aspiration of cyst was done in 21 out of 58 patients (36%), partial and subtotal excision in 35 out of 58 (61%), and total excision in two patients (3%), which differs from the findings of this study. There is more tendency towards biopsy and aspiration of cyst in the Nagpal et al. study (62). This illustrates the difficulty in surgical management of this condition.

Fahlbusch R et al. (63) in a study of 148 patients undergoing initial surgery, total tumour removal was accomplished in 45.7% of transcranial and 85.7% of transphenoidal procedures. Reasons for incomplete removal were attachment and/or infiltration of the hypothalamus/major calcifications and attachment to vascular structures.

17 out of 40 patients (42.5%) received radiotherapy and 23 patients (57.5%) did not receive radiotherapy due to death in the immediate post operative period, death at home/other peripheral health facilities after discharge and loss to follow-up. In Nagpal et al. study (62) 42 out of 58 (72.4%) patients received radiotherapy, which is higher than the number of patients who received radiotherapy in this study. Neurosurgical options at first surgery for craniopharyngioma included sub-total resection with radiotherapy (29%), sub-total resection alone (57%) and gross total resection alone (14%) in a study by Jennifer et al. (20).

Thomsett M.J. et al. (74) in a review of effect of treatment in 42 patients found that recurrence and mortality rates as well as neurological outcome of survivors were similar in children treated by radical excision and those treated by limited excision plus radiotherapy. The neurologic prognosis was poorest in those children who had limited excision or drainage without radiotherapy. Additional hypothalamo-pituitary dysfunction following treatment was less common in children who had limited excision plus radiotherapy than in children who had either limited excision or attempted total removal. They concluded that unless gross total tumour excision can be readily achieved, limited excision plus radiotherapy appears to be the treatment of choice for craniopharyngioma in childhood. In this study, only 1 patient (2.5%) was done total tumour removal.

In this study 56.1% of patients were dead, 39% had a moderate and good outcome and 2.4% had a poor outcome at six months of follow up. Nagpal et al. (62) at the time of the final evaluation of the 51 living patients found that 38 (74.5%) were independent, 9 (17.6%) were partially dependent, 3 (6%) were dependent. Hoffman et al. (73) at the final evaluation found that of the 46 children followed 64%, 27%, 9% had good, moderate and poor prognosis respectively which differs from the findings of this study.

In this study the outcome was more favourable in patients less than 18 years, males, patients without headache, patients with vomiting, visual disturbances, hyperprolactinemia, hypoprolactinemia and hypocortisolism. Outcome was also favourable in patients with completely intrasellar lesions, intrasellar with suprasellar extension, patients done biopsy only, partial excision/decompression and in those who received postoperative radiotherapy.

Bunin et al. (19) in USA found a five year survival rate of 80% and decreased with older age at diagnosis. Survival is higher among children and has improved in the recent years. Duff et al. (2) found that 73 of 121 patients devaluated had a good outcome of a mean follow-up period of ten years. A good outcome was associated with survival at the follow-up examination, functional vision; a katz grade of A and a karnofsky performance scale (kps) score of atleast 80.

In this study, 7 patients (17.3%) had tumour recurrence after partial excision/biopsy. This is low in comparison to findings in other studies. This could be due to the high mortality rate in this study and lack of regular postoperative ct scan/MRI to assist in early detection of recurrence..

In the study by Jennifer et al. (20) recurrence rate was 62% and the mean time to recurrence \pm 24 months. None of the patients who had gross total resection had a recurrence in contrast to the 67% who had partial excision. The cumulative rates of recurrence free survival were 57% at five years, 48% at ten years and 43% at twenty years. A similar recurrence rate (69%) with partial removal was found by Fahlbusch et al. (63).

Recent series reports indicate 81%-91% ten year recurrence free survival rate after sub-total tumour removal followed by radiotherapy with 46%-58% of the survivors living a normal independent life (75).

6.0: CONCLUSIONS

- 7.1% of brain tumours treated at KNH between 2003 and 2008 were craniopharyngiomas. Craniopharyngiomas are common in patients less than 20 years (68.3%). Majority of patients were from Central (39.0%) and Eastern (24.4%) provinces. The commonest presenting complains were headache (90%), visual disturbances (78%), vomiting (56%) and convulsions (24%). The commonest physical examination findings were decreased visual acuity/no light perception (78%), facial nerve palsy (34%) and motor disorders (34%).
- Only 53.7% of the patients had any tests for hypothalamo-pituitary axis function pre-operatively and post-operatively. 60 % had hyperprolactinemia, 60% had low growth hormone levels, 47.6 % had hypocortisolism and 22.7% had hypothyroidism. Most patients (97.6%) were done head CT scan. 63.4 % had purely suprasellar lesions and 26.8 % had intrasellar with suprasellar extension.
- Seventeen (42.5%) of the patients underwent radiotherapy in addition to surgery. 36 (90.0%) were done partial excision/decompression and 57.5 % had v-p shunts and ETV shunts inserted in addition to definitive surgery. 60 % of patients were done craniotomy within one month of admission.
- . Post-operatively 32.5% patients had neurological deficits, 22.5 % had seizures, 17.5 % had diabetes insipidus, 17.5 % had deteriorating neurological status and 17.5 % had various types of infections.
- Outcome after intervention was more favourable to those who underwent radiotherapy in addition to the surgical treatment and in patients aged 18 years and less than in older patients, in males than females and patients with out headache although not statistically significant. Outcome was also more favourable in patients done biopsy only ,partial excision/decompression, patients with visual disturbances, vomiting, hypocortisolism, hyperprolactinemia and hypoprolactinemia.
- Prognosis of the craniopharyngioma even with intervention was poor. Twenty three (56.1%) patients were dead upon six months of follow-up.

- **7.0 : RECOMMENDATIONS.**

- There is need for introduction of CT/MRI scans in referral centres including provincial hospitals to increase access to early diagnosis of patients with craniopharyngiomas and other brain tumours. Radiotherapy needs to be made compulsory for all patients since it improves the outcome of treatment
- The Government should provide Bio-chemical/hormonal testing kits in referral centres and subsidize on the costs to enable patients and clinicians have a good follow-up and hormone supplementation done. This can lead to an improved outcome. All patients with craniopharyngioma should be considered for hormonal profiles/CT and MRI's pre-operatively and post-operatively at definite periods to assist in follow-up and improved outcome
- The Government should set up more neurosurgery units and train more neurosurgeons in the country to reduce the burden at the Kenyatta National Hospital Neurosurgery unit. The Government should set up more radiotherapy units at the referral centres to reduce the burden at the Kenyatta National Hospital radiotherapy unit and also enable patients to receive radiotherapy promptly.
- There is a need to do a prospective study over prolonged period of time approximately five to ten years to determine the true outcome of craniopharyngioma in our set up..

8.0 REFERENCES

1. Karavitaki, N., Brufani, C., Warner, J. T. et al. Craniopharyngiomas in children and adults: systematic analysis of 121 cases with long-term follow-up. *Clin Endocrinol (Oxf)* 2005; 62:397-409.
2. Duff, J. M., Meyer, F. B., Ilstrup, D. M. et al. Long-term outcomes for surgically resected craniopharyngiomas. *Neurosurgery* 2000; 46:291-305.
3. Sanford, R. A., Muhlbauer, M. S. Craniopharyngioma in children. *Neurol. Clin.* 1991; 9:(2 Suppl):453-465.
4. Mott, F. W., Barret, J. O. W. Three cases of tumor of the third ventricle. *Arch Neurol* 1899; 1:417-440.
5. Erdheim J: Uber hypophysengangsyeshwulste und Hirncholesteatome. *Sitzungs Akad Wissensch* 113:537-726, 1904.
6. Frazier, C. H., Alpers, B. J. Adamantinoma of the Craniopharyngioma duct. *Arch Neurol Psych* 1931; 26:905-965.
7. Cushing, H. The Craniopharyngioma. *Intracranial Tumors. Notes upon a series of Two Thousand Verified Cases with Surgical Mortality Percentages Pertaining Thereto.* Springfield, IL: Charles C Thomas, 1932; 93-98
8. Golgberg, G.M., Eshbaught, D.E. Squamous cell nests of the pituitary gland as related to the origin of Craniopharyngiomas: a study of their presence in the new born and infants upto age four. *Arch Pathol.* 1960; 70:293-299.
9. Hunter, I.J. Squamous metaplasia of cells of the anterior pituitary gland. *J. Pathol bacteriol.* 1955; 69:141-145.
10. Carmel, P. W. Craniopharyngiomas. In Wilkins RH, Rengachary SS (eds) : *Neurosurgery* New York, McGraw-Hill, 1996; 1389-1400
11. Meuric, S., Brauner, R., Trivin, C. Influence of tumor location on the presentation and evolution of craniopharyngiomas. *J Neurosurg* 2005 ; 103:(5 Suppl): 421-6.
12. Mori, M., Takeshima, H., Kuratsu, J. Expression of interleukin-6 in human craniopharyngiomas: a possible inducer of tumor-associated inflammation. *Int J Mol Med* 2004; 14(4): 505-9.
13. Sweet WH (eds): *Craniopharyngiomas. Operative Neurosurgical Techniques, Indications, Methods, and Results. Ed 2, Vol. I.* Orlando, FL: Grune and Stratton, 1988, pp. 291-325
14. Robins, S. L., Cotran, R. S., Kumar, V. *Robbins pathological basis of disease: W.B. Saunders Company* 6th Edition 1999; pg. 1129.
15. Sanford, R. A. Craniopharyngioma: results of survey of the American Society of Pediatric Neurosurgery. *Pediatr Neurosurg* 1994; 21(Suppl 1): 39-43.
16. Cushing, H., Eisenhardt, L. (1938) Meningiomas, their classification, regional behaviour, life history, and surgical results. Springfield III. Charles C. Thomas.
17. Ruberti, R. F. (1989) Tumours of the central nervous system in the African. *Afri. J. Neurol. Sci.* 8:24-29
18. Madele Mahindu: A 10-month prospective study on surgically managed intracranial tumours at the Kenyatta National hospital. 2004 M. MED (Surgery) Thesis.
19. Bunin GR, Witman PA, Preston-Martin S et al. 1998 The Descriptive epidemiology of craniopharyngioma. *J. Neurosurg.* 89:547-551.
20. Jennifer L. Shin, Sylvia L. Asa, Linda J. Woodhouse et al. Cystic lesions of the pituitary: clinicopathological features distinguishing craniopharyngioma, Rathke's Cleft Cyst and Arachnoid cyst.

21. Brant, W., Helms, C. Fundamentals of Diagnostic Radiology. 1994: 130-2.
22. Smith, K. A., Kraus, G. E., Johnson, B. A., et al: Giant posterior communicating artery aneurysm presenting as third ventricular mass with obstructive hydrocephalus. J Neurosurg, in press.
23. Harwood-Nash, D. C. Neuroimaging of childhood craniopharyngioma. *Pediatr Neurosurg* 1994; 21(suppl 1): 2-10.
24. Rienstein, S., Adams, E. F., Pilzer, D. Comparative genomic hybridization analysis of craniopharyngiomas. *J Neurosurg* 2003; 98(1): 162-4.
25. Yoshimoto M, de Toledo, S. R., da Silva, N. S. Comparative genomic hybridization analysis of pediatric adamantinomatous craniopharyngiomas and a review of the literature. *J Neurosurg* 2004 ; 101(1 Suppl): 85-90.
26. Hoffman, H. J., De Silva, M., Humphreys, R. P. Aggressive surgical management of craniopharyngiomas in children. *J Neurosurg* 1992; 76(1): 47-52.
27. Regine, W. F., Kramer, S. Pediatric craniopharyngiomas: long term results of combined treatment with surgery and radiation. *Int J Radiat Oncol Biol Phys* 1992; 24(4): 611-7.
28. Behari, S., Banerji, D., Mishra, A. Intrinsic third ventricular craniopharyngiomas: report on six cases and a review of the literature. *Surg Neurol* 2003; 60(3): 245-52.
29. Yasargil, M. G., Curcic, M., Kis, M. et al. Total removal of Craniopharyngiomas. Approaches and long-term results in 144 patients. *J Neurosurg*, 1990; 73:3-11.
30. King, T. T. Removal of intraventricular craniopharyngiomas through the lamina terminalis. *Acta Neurochir* 1979;45: 277-286.
31. Baskin, D. S., Wilson, C. B. Surgical management of Craniopharyngiomas. A review of 74 cases. *J Neurosurg* 1986;65:22-27.
32. Fukushima, T., Hirakawa, K., Kimura, M. Intraventricular craniopharyngioma: its characteristics in magnetic resonance imaging and successful total removal. *Surg Neurol* 1990 33(1): 22-7.
33. Curtis, J., Daneman, D., Hoffman, H. J. The endocrine outcome after surgical removal of craniopharyngiomas. *Pediatr Neurosurg* 1994; 21(Suppl 1):24-7.
34. Sneed, P. K., Albright, N. W., Wara, W. M. Fetal dose estimates for radiotherapy of brain tumors during pregnancy. *Int J Radiat Oncol Biol Phys* 1995; 32(3 Suppl):823-30.
35. Bergman, W. C., Tse, V., Schulz, R. A. An improved stereotactic technique for cyst cannulation. *Stud Health Technol Inform* 1999; 62:45-8.
36. Voges, J., Sturm, V., Lehrke, R. Cystic craniopharyngioma: long-term results after intracavitary irradiation with stereotactically applied colloidal beta-emitting radioactive sources. *Neurosurgery* 1997 ;40(2 Suppl):263-9; discussion 269-70.
37. Takahashi, H., Nakazawa, S., Shimura, T. Evaluation of postoperative injection of bleomycin for craniopharyngioma in children. *J Neurosurg* 1985, 62:120-127.
38. Hader, W. J., Steinbok, P., Hukin, J. et al. Intratumoral therapy with bleomycin for cystic craniopharyngiomas in children. *Pediatr Neurosurg*, 2000; 33:211-218.
39. Broggi, G., Franzini, A., Cajola, L. et al. Cell kinetic investigations in craniopharyngioma: preliminary results and considerations. *Pediatr Neurosurg* 1994; 21:21-23.
40. Frank, F., Fabrizi, A. P., Frank, G. et al. Stereotactic management of craniopharyngiomas. *Stereotact Funct Neurosurg* 1995; 65:176-183.

41. Jiang, R., Liu, Z., Jhu, C. Preliminary exploration of the clinical effect of bleomycin on craniopharyngiomas. *Stereotact Funct Neurosurg* 2002; 78:84-94.
42. Bremer, A. M., Nguyen, T. Q., Balsys, R. Therapeutic benefits of combination chemotherapy with vincristine, BCNU, and procarazine on recurrent cystic craniopharyngioma. A case report. *J Neurooncol* 1984, 2:47-51.
43. Lippens, R. J., Rotteveel, J. J., Otten, B. J. et al. Chemotherapy with adriamycin (doxorubicin) and CCNU (lomustine) in four children with recurrent craniopharyngioma. *Eur J Paediatr Neurol* 1998; 2:263-268.
44. Jakacki, R. I., Cohen, B. H., Jamison, C. et al. Phase II evaluation of interferon- α -2a for progressive recurrent craniopharyngiomas. *J Neurosurg* 2000; 92:250-260
45. De Vile, C. J., Grant, D. B., Kendall, B. E. et al. Management of childhood craniopharyngioma: can the morbidity of radical surgery be predicted? *J Neurosurg* 1996; 85:73-81.
46. De Vile, C. J., Grant, D. B., Hayward, R. D. et al. Growth and endocrine sequelae of craniopharyngioma. *Arch Dis Child* 1996; 75:108-114.
47. Abs, R., Bengtsson, B-A., Hernberg-Stahl, E. et al. GH replacement in 1034 growth hormone deficient hypopituitary adults: demographic and clinical characteristics, dosing and safety. *Clin Endocrinol (Oxf)* 1999; 50:703-713.
48. Pereira, A. M., Schmid, E. M., Schutte, P. J. et al. High prevalence of long-term cardiovascular, neurological and psychosocial morbidity after treatment for craniopharyngiomas. *Clin Endocrinol (Oxf)* 2005; 62:197-204.
49. Abrams, L. S., Repka, M. X. Visual outcome of craniopharyngioma in children. *J Pediatr Ophthalmol Strabismus* 1997; 34:223-224.
50. Smith, D., Finucane, F., Phillips, J. et al. Abnormal regulation of thirst and vasopressin secretion following surgery for craniopharyngioma. *Clin Endocrinol (Oxf)* 2004; 61:273-279.
51. Poretti, A., Grotzer, M. A., Ribi, K. et al. Outcome of craniopharyngioma in children: long-term complications and quality of life. *Dev Med Child Neurol* 2004; 46:220-229.
52. Cavazzuti, V., Fischer, E. G., Welch, K. et al. Neurological and psychophysiological sequelae following different treatments of craniopharyngioma in children. *J Neurosurg* 1983; 59:409-417.
53. Graham, P., Gattamaneni, H. R., Birch, J. Pediatric craniopharyngiomas: regional review. *Br J Neurosurg* 1992; 6:187-194.
54. Weiner, H. L., Wisoff, J. H., Rosenberg, M. E. et al. Craniopharyngiomas: a clinicopathological analysis of factors predictive of recurrence and functional outcome. *Neurosurgery* 1994; 35:1001-1011.
55. Van Effenterre, R., Boch, A. L. Craniopharyngioma in adults and children. *J Neurosurg* 2002; 97:3-11.
56. Hetelekidis, S., Barnes, P. D., Tao, M. L. et al. 20-year experience in childhood craniopharyngioma. *Int J Radiat Oncol Biol Phys* 1993; 27:189-195.
57. Jose, C. C., Rajan, B., Ashley, S. et al. Radiotherapy for the treatment of recurrent craniopharyngioma. *Clin Oncol (R Coll Radiol)* 1992; 4:287-289.
58. Arai, T., Ohno, K., Takada, Y. et al. Neonatal craniopharyngioma and inference of tumour inception time: case report and review of the literature. *Surg Neurol* 2003; 60:254-259.

59. Wen, B. C., Hussey, D. H., Staples, J. et al. A comparison of the roles of surgery and radiation therapy in the management of craniopharyngiomas. *Int J Radiat Oncol Biol Phys* 1989; 16:17-24.
60. Sands, S. A., Milner, J. S., Goldberg, J. Quality of life and behavioral follow-up study of pediatric survivors of craniopharyngioma. *J Neurosurg* 2005; 103(4 Suppl):302-11.
61. Waber, D. P., Pomeroy, S. L., Chiverton, A. M. Everyday cognitive function after craniopharyngioma in childhood. *Pediatr Neurol* 2006; 34(1): 13-9.
62. Nagpal RD. Craniopharyngioma: treatment by conservative surgery and radiation therapy. *J. Postgrad. Med.* 1992.
63. Fahlbusch R, Paulus W, Huk W et al. 1999 Surgical treatment of craniopharyngiomas. Experience with 168 patients. *J Neurosurg.* 90:237-250.
64. Pat Kendall Taylor, Peter J Jonsson, Roger Abs, et al: The Clinical metabolic and Endocrine features and the quality of life in adults with childhood-onset craniopharyngioma compared with adult-onset craniopharyngioma. *European Journal of Endocrinology*, Vol 152, Issue 4,
65. Honeggar J, Fahlbusch R. 1999 surgical treatment of craniopharyngiomas: endocrinological results. *J Neurosurg.* 90:251-2557-567.
66. Crotty TB, Young WF, Davis DH et al. 1995 Papillary craniopharyngioma: a clinicopathological study of 48 cases. *J Neurosurg.* 83:206-214.
67. Crane TB, Hepler RS, Hallinan JM. 1982 Clinical manifestations and radiological findings in craniopharyngiomas in adults. *Am J Ophthalmol.* 94:220-228.
68. Carmel PW. Brain tumours of disordered embryogenesis. In: Youmans JR, editor. *Neurological Surgery*, 3rd ed. Philadelphia: WB Saunders;1990:3223-3249.
69. Laws ER. Transsphenoidal microsurgery in the management of craniopharyngioma. *J Neurosurg* 1980; 52:661-666.
70. McLone DG, Raimondi AJ, Naidich TP. craniopharyngiomas. *Child's Brain* 1982; 33:533-556.
71. Tadanori T. Management of craniopharyngiomas in children. *Pediatr Neurosci* 1988; 14:204-211.
72. Ushio Y, Arita N, Yoshimine T, Nagatani M, Mogami H. Glioblastoma after radiotherapy for craniopharyngioma. Case Report. *Neurosurgery.* 1987; 22:33-38.
73. Hoffman HJ, Hendrick EC, Humphreys RP, Buncic JR, Armstrong DL, Jenkin RDT. Management of craniopharyngioma in children. *J Neurosurg* 1977; 47: 218-227.
74. Thomsett MJ, Kaplan SL, Grumbach MM et al: 1980 Endocrine and neurologic outcome in childhood craniopharyngioma: review of effect of treatment in 42 patients, *J Pediatr.* 97:728-735.
75. Rajan B, Ashley S, Gorman C, et al. Craniopharyngioma – long term results following limited surgery and radiotherapy. *Radiother Oncol* 1993;26:1-10.

9.0 APPENDICES

APPENDIX I: DATA COLLECTION SHEET

A. DEMOGRAPHIC DATA

Inpatient No.:

Study No.:

Date of Admission:..... Date of Discharge.....

1. Alive [] 2. Dead []

Age: 1. 0 – 9 yrs.....

4. 30 – 39 yrs.....

2. 10 –19 yrs.....

5. 40 – 49yrs.....

3. 20 – 29 yrs.....

6. 50 – 59 yrs

7. >60yrs.....

Sex: 1. Male.....

2. Female.....

Province of origin:.....

B. CLINICAL PRESENTATION

Presenting Symptoms

Duration (Months)

- Headache.....
- Visual disturbances.....
- Excessive thirst and polyuria.....
- Amenorrhea/impotence/decreased sexual drive.....
- Hydrocephalus with increased ICP.....
- Memory deficits.....
- Incontinence
- Vomiting.....
- Convulsions
- Hyperphagia.....
- Others

Presenting Signs

a) General Examination

Palor Present [] Absent []

Edema Present [] Absent []

b) Ophthalmologic Assessment

Visual acuity:.....

c) Other lateralizing signs

Other cranial nerve lesions:.....

Hemiplegia:.....

Hemiparesis:.....

Others:.....

C. INVESTIGATIONS

a) Laboratory Investigations

Hemoglobin (g/dl):.....

Urea and electrolytes: Normal Yes: [] No: []

(If no specify).....

Thyroid Function tests Normal Yes [] No []

(If no specify).....

Aldosterone levels:

Growth Hormone levels:.....

Antidiuretic hormone levels:.....

Other Tests (specify).....

(ii) Radiological Investigations done and their findings

▪ CT Scan:.....

.....

▪ MRI/MRA:.....

.....

▪ Skull x-ray:.....

▪ Ultrasound Scan:.....

▪ Four vessel angiography:.....

▪ Others.....

Tumour Localization (radiological)

.....

H. Co-morbidity factors

- | | | |
|-----------------------|---------|--------|
| None | Yes [] | No [] |
| Hypertension | Yes [] | No [] |
| Diabetes | Yes [] | No [] |
| Asthma | Yes [] | No [] |
| Others (Specify)..... | | |
| | | |
| | | |

D. PRE-OPERATIVE CARE

- a) Pre-operative hospital stay (days):.....
- b) Steroids administered yes [] No []
- c) Anti convulsants used yes [] No []
- d) Prophylactic antibiotics yes [] No []
- e) ASA classification:.....
- f) Pre-operative shaving:.....

E. TREATMENT MODALITY

- Surgery- complete excision []
 - Near total []
 - Biopsy only []
- Intra-operative time period in hours and minutes:.....
- Surgery alone.....
- Surgery radiotherapy.....
- Surgery +chemotherapy.....
- Surgery + radiotherapy + chemotherapy.....

COMPLICATIONS

(i) Immediate Complication

- | | | |
|-------------------|---------|--------|
| a) None | Yes [] | No [] |
| b) Intra-op death | Yes [] | No [] |

- c) Deteriorated Neurological status Yes [] No []
- d) Hemorrhage Intra-op Yes [] No []
- (ii) Intermediate
 - a) CSF leak Yes [] No []
 - b) Wound Sepsis Yes [] No []
 - c) Post op Meningitis Yes [] No []
 - d) Seizures Yes [] No []
 - e) Scalp Haematoma Yes [] No []
 - f) Hydrocephalus Yes [] No []
 - g) Residual neurological deficit not initially present. Yes [] No []

(iii) Other complications (mention)

Tumour Histology (mention).....

.....

G. Scoring

Outcome	On admission	1wk Post OP	3mths Post OP	6mths Post OP
Karnofsky Score (adults)				
Lansky Score (children)				
Motor Deficits				
Visual Deficits				

APPENDIX II: PERFORMANCE STATUS

a) Karnofsky scoring

The Karnofsky score runs from 100 to 0, where 100 is 'perfect' health and 0 is death. Although the score has been described with intervals of 10, a practitioner may choose decimals if he or she feels a patient's situation holds somewhere between two marks. It is named after Dr David A. Karnofsky, who described the scale with Dr Joseph H. Burchenal in 1949.

- 100% - normal, no complaints, no signs of disease
- 90% - capable of normal activity, few symptoms or signs of disease
- 80% - normal activity with some difficulty, some symptoms or signs
- 70% - caring for self, not capable of normal activity or work
- 60% - requiring some help, can take care of most personal requirements
- 50% - requires help often, requires frequent medical care
- 40% - disabled, requires special care and help
- 30% - severely disabled, hospital admission indicated but no risk of death
- 20% - very ill, urgently requiring admission, requires supportive measures or treatment
- 10% - moribund, rapidly progressive fatal disease processes
- 0% - death.
- Good outcome: 70 – 100%
- Moderate outcome: 40 – 60%
- Poor outcome: 0 – 30%

b) ECOG/WHO/Zubrod score

The ECOG (Easten Cooperative Oncology Group) score (published by Oken *et al* in 1982), also called the WHO or Zubrod score (after C. Gordon Zubrod), runs from 0 to 5, with 0 denoting perfect health and 5 deaths:

- 0 - Asymptomatic
- 1 - Symptomatic but completely ambulant
- 2 - Symptomatic, <50% in bed during the day
- 3 - Symptomatic, >50% in bed, but not bedbound

- 4 - Bedbound.
- 5 - Death

c) Lansky score

Children, who might have more trouble expressing their experienced quality of life, require a somewhat more observational scoring system suggested and validated by Lansky *et al* in 1987:

- 100 - fully active, normal
- 90 - minor restrictions in strenuous physical activity
- 80 - active, but gets tired more quickly
- 70 - greater restriction of play *and* less time spent in play activity
- 60 - up and around, but active play minimal; keeps busy by being involved in quieter activities
- 50 - lying around much of the day, but gets dressed; no active playing participates in all quiet play and activities
- 40 - mainly in bed; participates in quiet activities
- 30 - bedbound; needing assistance even for quiet play
- 20 - sleeping often; play entirely limited to very passive activities
- 10 - doesn't play; does not get out of bed
- 0 - unresponsive
 - Good outcome: 70 - 100%
 - Moderate outcome: 40 - 60%
 - Poor outcome: 0 - 30%

APPENDIX III: CONSENT FORM

STUDY ON INCIDENCE, MANAGEMENT AND OUTCOME OF CRANIAOPHARYNGIOMA AT KENYATTA NATIONAL HOSPITAL.

CONSENT EXPLANATION

My name is Dr. Ekitela. I am carrying out a research on Craniopharyngiomas managed at the Kenyatta National Hospital during the period 1st January 2003 to 31st December 2008. This study will enable us to know more about Craniopharyngiomas and how we treat them here at Kenyatta National Hospital. Through this study, we will be in a better position to offer treatment to others who may be similarly afflicted. All the information gathered shall be used solely for the purposes of medical research. You are under no obligation to either accept or refuse to be enrolled in this study, and your decision shall in no way affect any treatment you may receive in this institution.

You will be enrolled upon giving consent and allocated a study number. You will undergo normal history taking, physical examination, and investigations needed as per your condition and information collected from these as to your complaints, period of time you have had them, and whether you were referred or not. Results of investigations and physical examination findings will be documented.

You will then undergo the standard surgery for your condition, operating time and any intra-operative complications will be recorded. Post-operatively, you will be examined as usual and monitored for any complications arising directly from your surgery or related to it.

Apart from the normal risks any patient undergoing surgery for this condition faces, there are no extra risks you are exposed to in the study. Only data shall be collected about you, your condition, your operation and the immediate post-operative period up-to your discharge. The histology report on your tumour will be documented and only your study number, which will not even appear in the final report, will identify you.

Please feel free to ask any questions that may not be clear to you or may arise from my explanation above.

Sign the consent form below if you wish for yourself or your dependant to be part of this study.

Thank you.

Dr. Ekitela S. N.

Box 4673, Nyayo Stadium, Nairobi

Telephone 0726-507840.

CONSENT FORM

I _____ of _____ do hereby

agree for myself/my dependant to be enrolled in the study on craniopharyngioma tumours.

I understand and agree with all the above, all the information gathered shall be confidential and used solely for medical research, I am under no obligation to accept or refuse to be part of this study, and that my decision shall in no way affect any treatment I may receive in this institution.

Signature: _____

Date: _____

CHETI CHA KUKUBALI

Mimi _____ wa _____

Nakubali mwenyewe/mtegemea wangu kuhusishwa kwa utafiti kuhusu sarakasi ya ubongo. Nimeelewa na kukubaliana na yote niliyoelezewa, matokeo yatatumwa tu kwa minajili ya utafiti wa sayansi ya matibabu na yatakuwa ya kibinafsi.

Naweza kukataa au kukubali na uamuzi wangu hautadhuru au kunizuhia kupata matibabu ninayopasa kupata katika hospitali hii.

Sahihi: _____

Tarehe: _____

UNIVERSITY OF NAIROBI
MEDICAL LIBRARY



KENYATTA NATIONAL HOSPITAL

Hospital Rd. along, Ngong Rd.
P.O. Box 20723-00202, Nairobi.

Tel: 2726300-9

Fax: 725272

Telegrams: MEDSUP, Nairobi.

Email: knhadmin@knh.or.ke

Ref: KNH-ERC/ 01/ 402

20th May, 2008

Dr. Stephen E. Ekitela
Dept. of Surgery
School of Medicine
UNIVERSITY OF NAIROBI

Dear Dr. Ekitela

**REVISED RESEARCH PROPOSAL: "INCIDENCE, MANAGEMENT AND OUTCOME OF
CRANIPHARYNGIOMA IN KENYATTA NATIONAL HOSPITAL"** (P354/11/2007)

This is to inform you that the Kenyatta National Hospital Ethics and Research Committee has reviewed and approved your above revised research proposal for the period 20th May, 2008 – 19th May, 2009.

You will be required to request for a renewal of the approval if you intend to continue with the study beyond the deadline given. Clearance for export of biological specimen must also be obtained from KNH-ERC for each batch.

On behalf of the Committee, I wish you fruitful research and look forward to receiving a summary of the research findings upon completion of the study.

This information will form part of database that will be consulted in future when processing related research study so as to minimize chances of study duplication.

Yours sincerely

PROF A N GUANTAI
SECRETARY, KNH-ERC

c.c. Prof. K.M. Bhatt, Chairperson, KNH-ERC
The Deputy Director CS, KNH
The Dean, School of Medicine, UoN
Supervisor: Mr. Julius Githinji Kiboi, Dept. of Surgery, UoN