

A STUDY OF RADIOLOGICAL FEATURES
AS SEEN ON A
CHEST RADIOGRAPH OF A PATIENT
WITH BOTH
HUMAN IMMUNODEFICIENCY VIRUS INFECTION
AND
PULMONARY TUBERCULOSIS I (

A dissertation submitted in
part-fulfilment for the degree of:-

MASTER OF MEDICINE
in
DIAGNOSTIC RADIOLOGY
UNIVERSITY OF NAIROBI

by

DR. J. M. RUIRU, MB, ChB. (NAIROBI)

JULY 1991

University of NAIROBI library
•if
0390119 6

DECLARATION

Candidate:

This dissertation is my original work and has not been presented for a degree in any other University.

Signed:



DR. J.M. RUIRU, (MB,ChB) (NRB)

Supervisor:

This dissertation has been submitted for examination with my approval as University Supervisor

Signed:

DR. M.S. W\LIK, (M.B.B.S., D.M.R.D.)
CONSULTANT RADIOLOGIST,
CHAIRMAN,
RADIOLOGY DEPARTMENT,
THE AGA KHAN HOSPITAL, NAIROBI,
PART-TIME LECTURER,
UNIVERSITY OF NAIROBI.

TABLE OF CONTENTS:

| | <u>PAGE</u> |
|--------------------------|-------------|
| 1. DECLARATION | (i) |
| 2. CONTENTS | (ii) |
| 3. TITLE | (iii) |
| 4. AIMS | (iv) |
| 5. SUMMARY | 1 |
| 6. INTRODUCTION | 2 |
| 7. MATERIALS AND METHODS | 6 |
| 8. SAMPLE RADIOGRAPHS | 17 |
| 9. RESULTS | 26 |
| 10. DISCUSSION | 37 |
| 11. References | 42 |
| 12. Acknowledgements | 46 |

V X

TITLE

A STUDY OF RADIOLOGICAL FEATURES
AS SEEN ON A
CHEST RADIOGRAPH OF A PATIENT
WITH BOTH
HUMAN IMMUNODEFICIENCY VIRUS INFECTION
AND
PULMONARY TUBERCULOSIS

AIMS

- 1) Determine any differences in Radiological pattern as seen on chest radiographs of seropositive HIV/PTB patients compared with seronegative HIV/PTB patients.

- 2) Find out whether chest radiographs can be of use in the diagnosis of human immunodeficiency virus infection amongst pulmonary tuberculosis patients and the vice versa.

SUMMARY

This study was done at the Aga Khan Hospital, Nairobi and Kiambu Hospital.

In the period of study 160 patients were seen to have AFB positive sputums or gastric aspirates. Out of this number 72 Radiographs of the chest were analysed.

The presence of upper zone disease (HIV^{+ve} (35%), HIV^{~ve} || (72%), cavitation (HIV^{+ve} (20%), HIV^{~ve} || (56%) and normal mediastenum width (HIV^{+ve} (35%), HIV^{~ve} ^ (14%) were found to indicate absence of HIV infection while the reverse is also true. The absence of upper region involvement, lack of cavitation, enlarged mediastenum and normally positioned hilum were found to have a positive predictive values of $\frac{18}{j^{\wedge}}$ 90%. However mediastenum enlargement, lower and midzon disease and lack of cavitation when taken together were found not to be significantly different in the two groups (HIV⁺ and HIV⁻). Therefore the involvement of the upper zone is very important in trying to differentiate the two. I therefore suggest that in the absence of HIV testing facilities the above features may be useful in identifying HIV infection among pulmonary tuberculosis patients.

INTRODUCTION

Mycobacterium tuberculosis infection is a common problem in the developing world and is responsible for a lot of mortality and morbidity. It has been found that upto 80% of the African population at 25 years are sensitized to mycobacteria (20). In Kenya a study done in 1951 showed that upto 90% of the adult population was sensitized to mycobacteria without prior immunisation. (10). This infection in Kenya seems to have been brought by Arab traders around 1903 (10). Initially the infection was only found in urban centres but soon it spread to rural areas (10).

The use of x-rays in the diagnosis of pulmonary tuberculosis was first reported on 15th February 1896 (13). This is only one year after the discovery of x-rays by William Conrad Roentgen (23). In 1901 a chest physician Dr. Lawson MD, described the features you expect to find on fluoroscopy or on an x-ray plate of a patient with pulmonary tuberculosis (14). By 1930 x-rays were routinely used for diagnosis of pulmonary tuberculosis (23). Today in Kenya the use of chest radiographs in the diagnosis of pulmonary tuberculosis is that of an accessory tool rather than a gold standard (6). In all PTB patients positive sputum cultures or lymph node aspirates are required before confirming the diagnosis of active disease (6).

Recently the incidence of pulmonary tuberculosis has been increasing gradually in Kenya, this is found to correspond to the case finding rate of AIDS (Acquired Immunodeficiency Syndrome) patients. Between 1988 and 1989 the PTB case reports increased with 18% (16). The Aids patients increased from 3188 to 6004 in the period of December 1988 - June 1989 (15). There is a definite association between the Aids Syndrome and pulmonary mycobacteria infection (18). It is not clear which comes before the other but it is true that the diagnosis of Aids is occasionally made months after that of mycobacteria infection (5). In one study in florida 59% of the Aids patients were found to have the Aids syndrome, one month after the diagnosis of mycobacteria infection (5).

Human immunodeficiency virus infection has been associated with the development of acquired immunodeficiency syndrome. The increasing viral burden of HIV virus in CD⁺T cells (includes T lymphocytes and mononuclear cells) has been associated with decreasing clinical state and increasing immunosuppression (24). This problem of Aids was first described in 1981 in U.S.A and subsequently in Europe (15). In 1986 a study was done in Nairobi which showed that HIV infection was spread by heterosexual sexual contact and had an incidence of 2% seropositivity in the general population.

The Diagnosis of Aids is a clinical one based on the Bengal Criteria (11). Unfortunately when the same is applied to a pulmonary tuberculosis patient, the patient may satisfy the criteria for diagnosis with or without HIV infection. Therefore some pulmonary tuberculosis patients risk being diagnosed as Aids patients alone and therefore be denied treatment for the PTB (1).

Before the HIV infection era, the radiological features on a chest x-ray were divided into those of primary and those of post primary infection (20). Primary infection is normally a disease of childhood (20) but may occur in adults. The radiographic features include hilar and perihilar lymph node enlargement with or without peripheral opacities. Pleural effusion and Millitary spread are also common in the primary disease.

Post primary infection usually occur five or so years after the primary infection. The radiological features include involvement of the Apical region of both upper and lower lobes. Cavitation, fibrosis, pleural effusion and pneumothorax are also features of the same.

Millitary spread and lymph node enlargement are not features of post primary infection (20).

In comparison the Aids (HIV) patient who happens to have pulmonary tuberculosis (post-primary infection) is found elsewhere to present differently (21). Studies done in Zambia have shown that the HIV/PTB patient shows less upper zone involvement, less cavitation and less involvement of the pleura and pericardium (1). Here in Kenya larger studies are being done at the infectious disease hospital (8). It is hoped that the chest radiograph will not only be useful in the diagnosis of pulmonary tuberculosis but also in isolating the HIV/PTB patients.

MATERIALS AND METHODS

This is mainly a retrospective study which covers the periods between January 1988 and August 1990. January 1988 is the time both hospitals started routine testing for HIV infection in all pulmonary tuberculosis patients.

The study started in the laboratory where I got all AFB culture positive inpatient and outpatient numbers. All this numbers were noted and the files were looked for from the record departments. From the files I noted the name, age, and human immunodeficiency virus tests done. The significant human immunodeficiency virus tests were Elisa and Westernblot. A patient was considered positive if both were positive. This study also excluded children below 12 years who were likely to have primary tuberculosis. Also from the files I got the x-ray numbers. With the x-ray numbers I was able to get the x-ray films from the x-ray departments. All this information was recorded on a record note book as shown in the sample page.

| SERIAL No. | NAME OF PATIENT LAB No. OF AFB POSITIVE CULTURE | IP No. HOSPITAL | ELISA | ¹ WESTERN BLOT | X-RAY No. |
|------------|---|----------------------|----------|---------------------------|-----------|
| 74 | Name Age Sex Lab Result No. | Hospital 0 9 8419 | Positive | Positive | 2594/88 |
| 75 | Name Age Sex Lab Result No. | Hospital 222393 | Negative | | 6216/88 |

From the above information the x-ray films were looked for from the x-ray departments.

FILM QUALITY ASSESSMENT

- A) The film of study is a posterior anterior chest film. In cases of repeat films the first film was the one assessed unless found unacceptable.
- B) All films which qualified for pathological analysis had to be:-
- i) Good inspirative films i.e. the level of the (Rt) hemidiaphragm should be between 5th and 6th anterior interspace.
 - ii) Show good tissue penetrative - This means that the first 4 thoracic vertebra and intervertebral spaces should be seen. Low Kv technique with xray film taken at Kv of 60-80 were acceptable.
- C) No magnified views of the chest radiographs were analysed. However it was difficult to assess minimal magnification that may result from technical errors. Both hospitals however did the chest radiographs using a standard 6ft tube film distance.
- D) Films analysed were all double imulsion films taken in double screened cassettes.
- E) Film faults were only accepted provided they did not affect vital image quality. The faults varied from technical to clerical faults.

Un acceptable films were not analysed and are not included in the study. No more than five films were analysed per day to reduce fatigue and misreporting. I did all the analysis myself and no previous reports were available in all the radiographs.

The analysis was according to the Questionnaire. The Questionnaire were completely filled and filed.

Sample provided.

QUESTIONNAIRE

Name: IP/No. X-ray No
Age: Sex:
HIV W My. Tuberculosis Positive Negative
Culture

ROENTGEN'S FINDINGS

Soft tissues 1 for 2
Ribs

Vertebra

Hemidiaphragm Rt Lt

Hilum

Cavities

Opacities

Homogeneous

Un

Trachea

Pleural reaction Yes = No. 2
M

Calcification Enlarged 1-Not 2

Diaphragm Present 1 absent 2

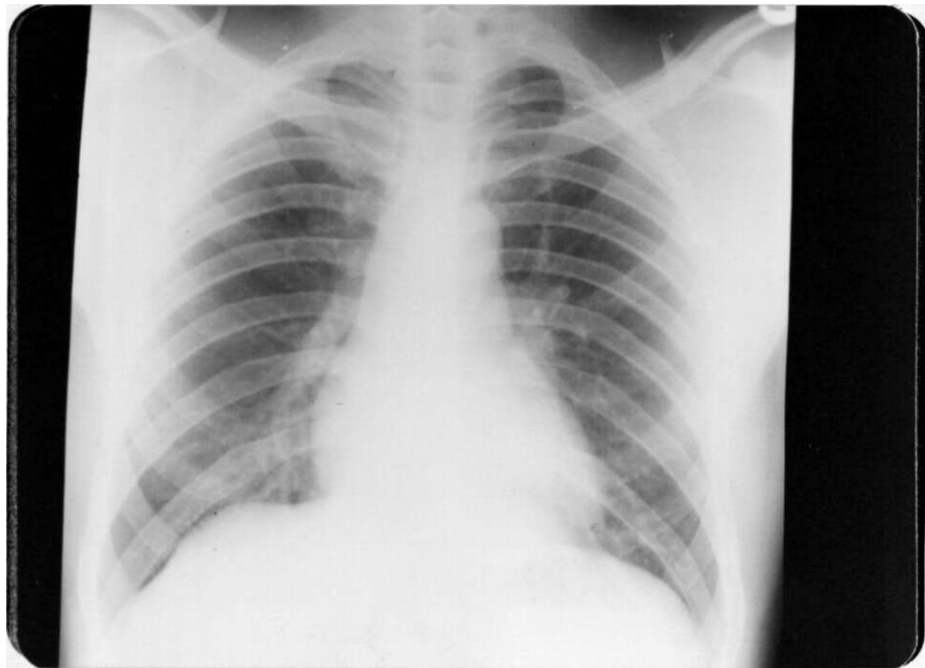
Emphysematous changes

• r.ov.rothorax Yes 1 No. 2

* a :/Alive

NORMAL STANDARD CHEST X-RAY

PA OF ACCEPTABLE QUALITY




PATHOLOGICAL ANALYSIS

- A) Soft tissues: This was assessed by measuring the soft tissues at the level of the 5th rib laterally. Measurement of less than 5mm was taken as evidence of wasting (27).

Code 1 Normal

2 Wasted



5th rib

Distance
measured

- B) Rid and Vertebrae
- Rib were assessed for crowding, lytic lesions and any other abnormalities.
 - Vertebrae and spine was assessed for kyphosis/scoliosis as seen in the PA film, reduction in vertebral height or intervertebral disc space narrowing.

If any of the above was found present a code of 1 was given, if none was observed a code of 2 was given.

HEMIDIAPHRAGM

n

Elevation of the diaphragm was taken on a level of 3cm of one above the other. This was measured out mid clavicular line.

Code 1 Normal 2 Elevated

HILUM

The hilum was taken as the point at which the relatively large upper lobe vein meets the shadows of the basal artery. This corresponds with the sex rib in the laterally. On the (Lt) side the point was allowed to be at most 1.5cm lower.

Code 1 Not elevated

2 Elevated

CAVITIES

This was taken as a focus of increased density whose central portion has been replaced by air (20) • No categorisation of the cavities was made i.e. Number, size, film level, wall thickness etc. Except for the site of the cavity. The lung fields are divided as follows for description.

| | |
|------------|---|
| Upper zone | |
| Mid zone | Lower border of the anterior end of 2nd costal cartilage |
| Lower zone | Lower border of the 4th costal cartilage |

The cavities were described according to where they were found.

OPACITIES

Opacities were divided into:-

- 1) Homogeneous opacities with airbronchogram.
- 2) Homogeneous opacities without airbronchogram
- 3) Patchy opacities with ill defined margins
- 4) Millitary (Nodules) shadows - tiny (1-2mm) discrete patches.

The opacities were also categorised according to the area affected as above i.e. upper, mid and lower zone.

TRACHEA

Any shift of the trachea's medial wall more than 3mm from the outer margin of the nearest pedicle was considered as equivalent to shift. The width of the trachea was not taken into account.

Code 1 shift

2 shift

PLEURAL REACTION

No attempt was made to differentiate between pleural thickening and pleural effusion. Any thickening of pleural was taken as a reaction. Note: That normally you should not be able to see the pleura thickening on the chest film.

Code 1 Reaction present

2 No reaction seen.

CALCIFICATION

This included calcification seen around the region of hilar and bronchopulmonary lymph nodes. Pericardial calcification was also noted.

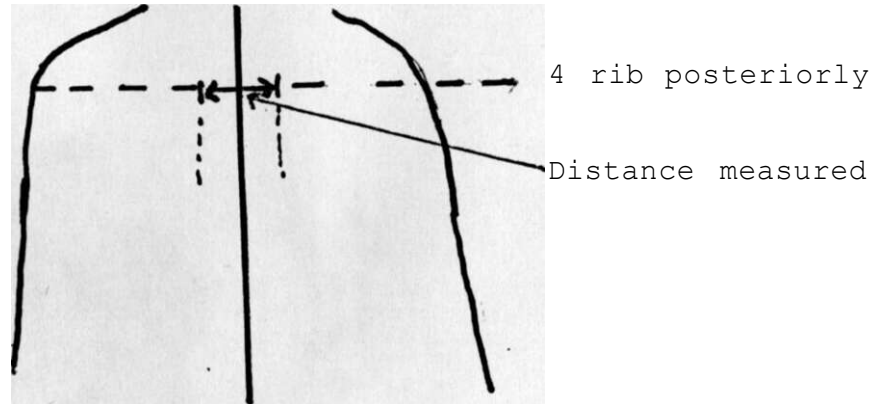
Pleural calcification and costochondral calcification were excluded.

Code 1 Calcification present

2 Calcification absent.

MEDIASTINUM

This is assessment superior mediastinum, taken at the level of the 4th posterior rib. It was considered enlarged if greater than 8cm in width ().



Code 1 Enlarged
2 Not Enlarged

BRONCHIECTATIC CHANGES

When thickening of bronchi and cystic changes were noted, or a honey comb pattern, the region was considered to have features of bronchiectasis. No categorisation of site was done.

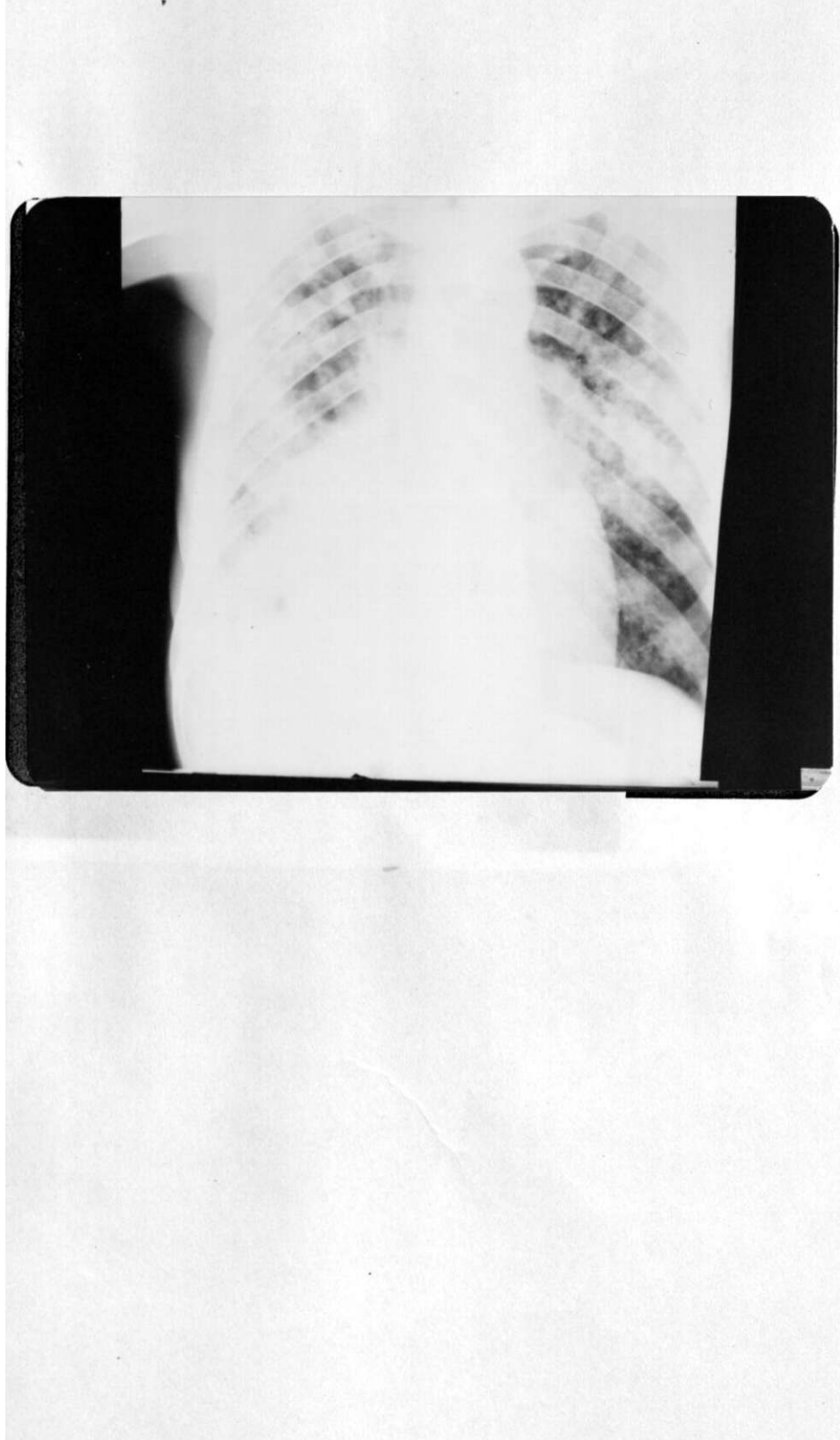
Code 1 - present
2 - Absent

PNEUMOTHORAX

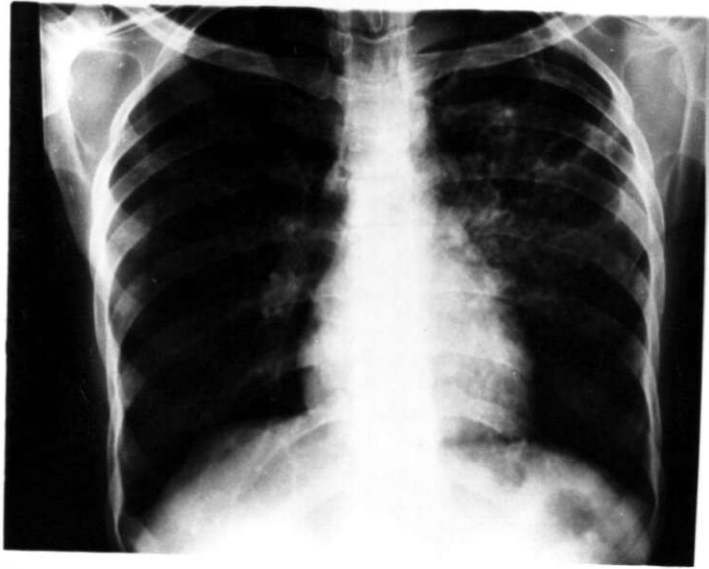This was taken as reflection of visceral pleura by air with or without loss of volume in the lungs.

Code 1 - Present
2 - Absent

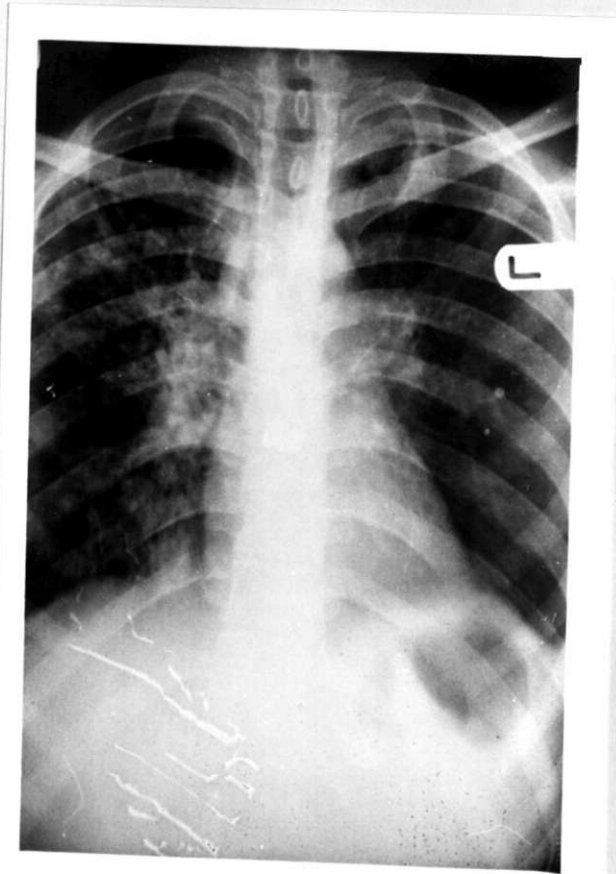
RADIOGRAPH WITH SOFT TISSUE REDUCTION (HIV⁺)



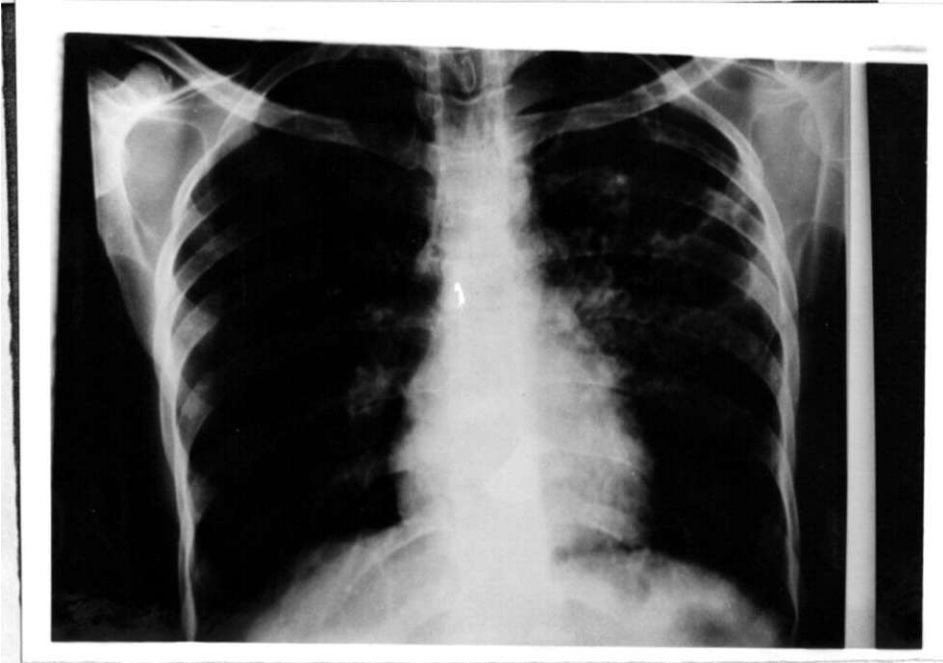
RADIOGRAPH WITH BILLATERAL DISEASE (HIV~^{VE})



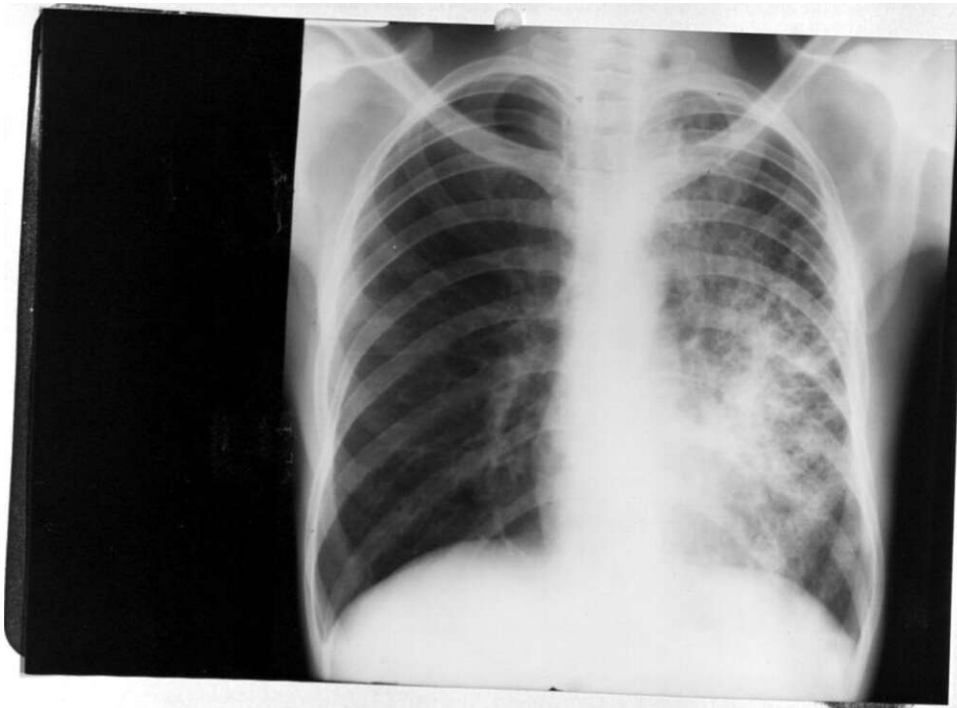
RADIOGRAPH WITH BILLATERAL DISEASE (HIV^{+ve})



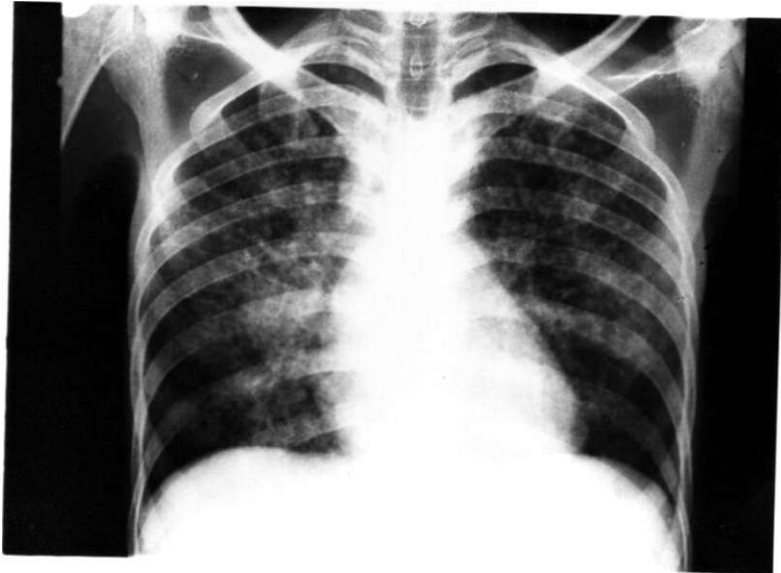
RADIOGRAPH SHOWING LUNG CAVITIES (HIV ^ve)



HOMOGENEOUS OPAPTTV CHIV"

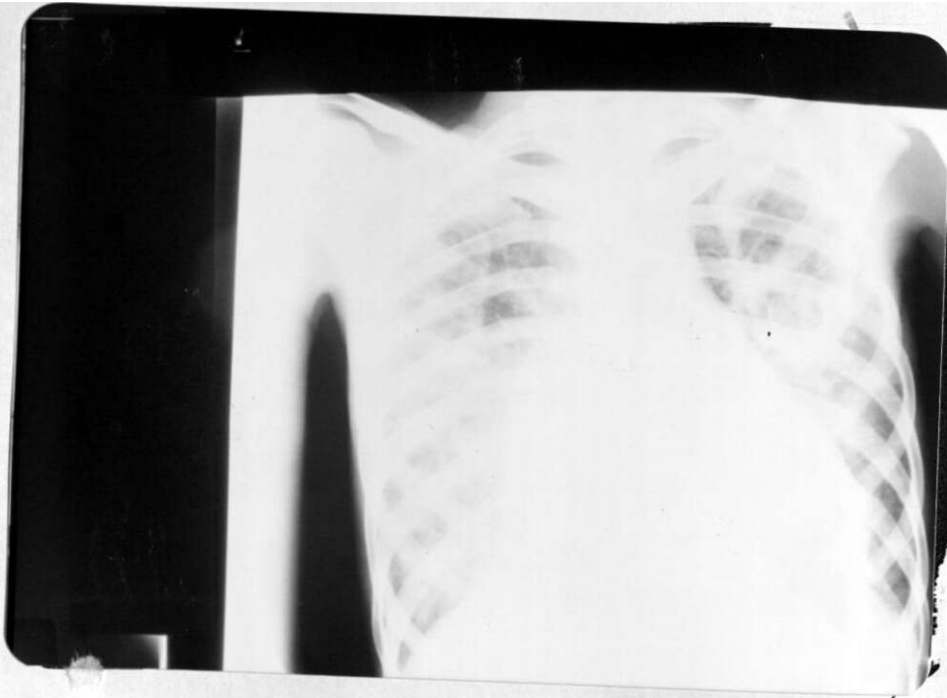


RADIOGRAPH WITH MILLIARY SHADOWS (HIV⁺VE)

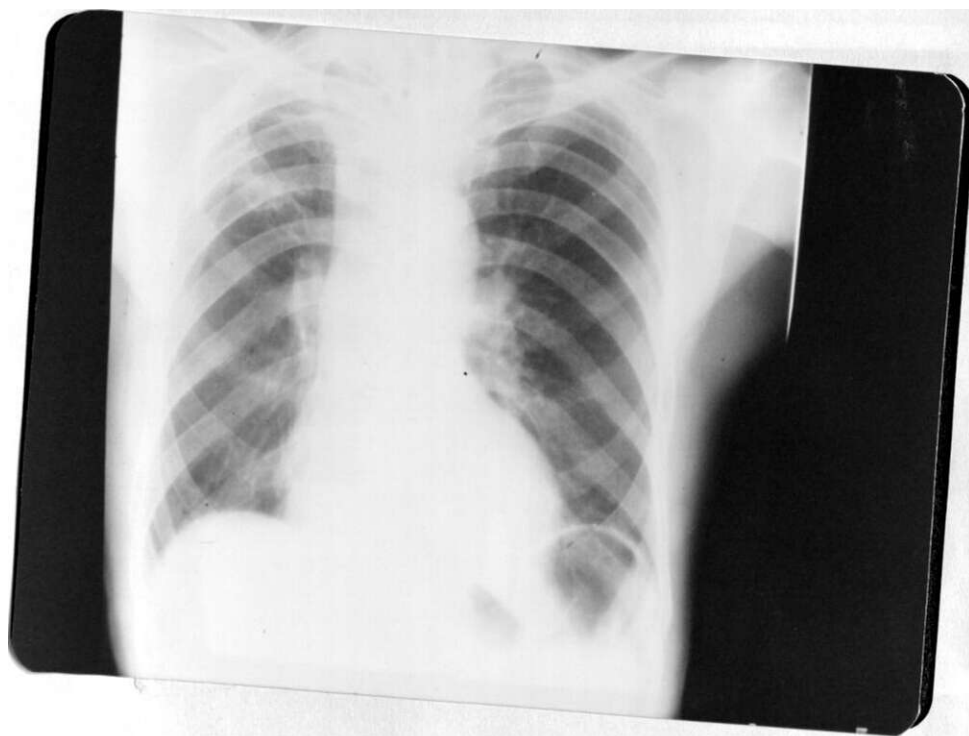


t

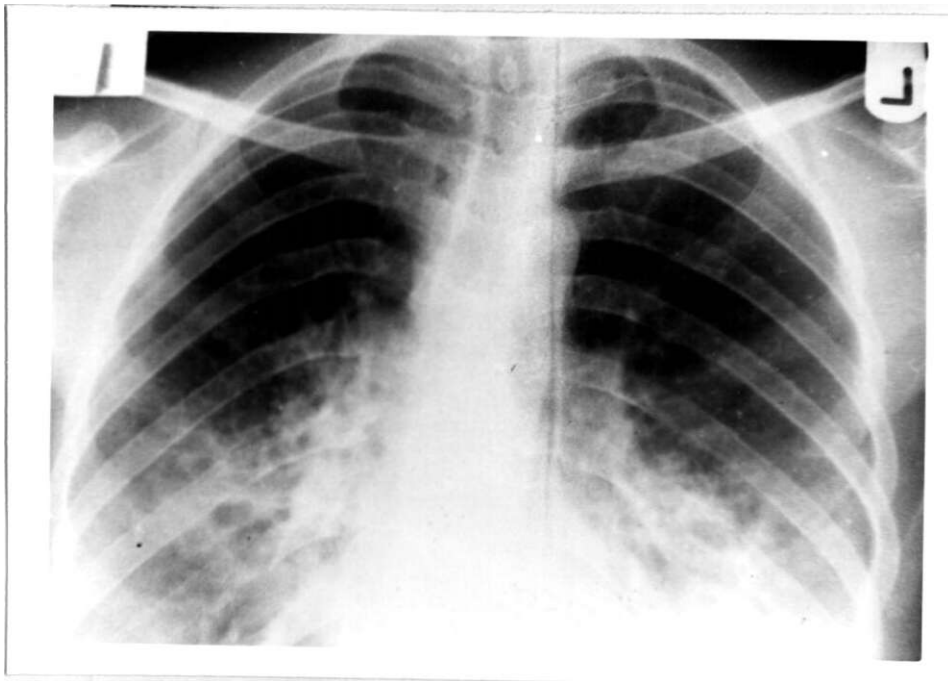
RADIOGRAPH WITH MEDIASTINAL ENLARGED (HIV^{+VE})



RADIOGRAPH WITH PTB (HIV~^{VE})



RADIOGRAPH OF HIV/PTB PATIENT



RESULTS

Total number of acid fast bacillin culture proven cases with the period of study.

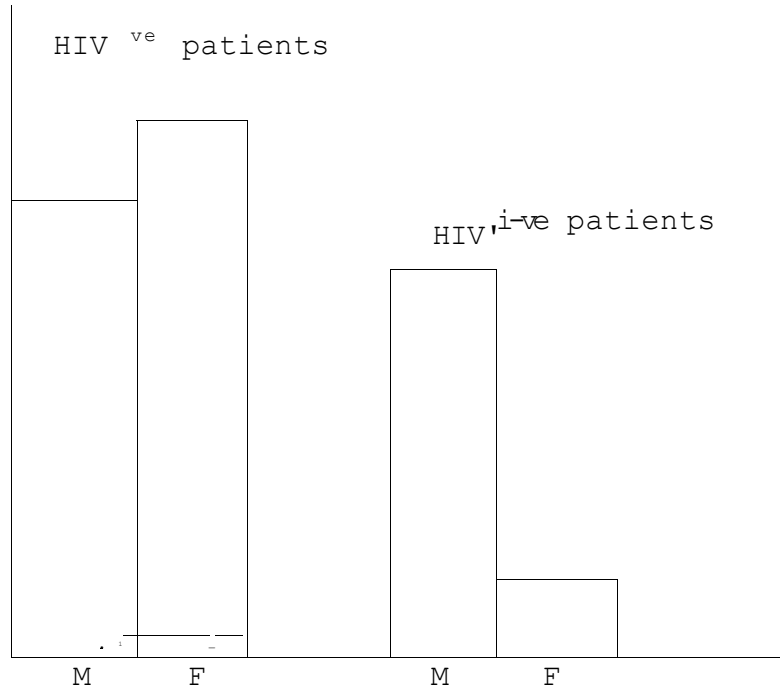
Aga Khan = 110

Kiambu = 50

Number of films eventually isolated for study.

Aga Khan = 70 = 60%

Kiambu = 30 = 60%



Total Number of films analysed = 72

Upper Zone Involvement

| | No | Percentage | | |
|---------|----|------------|--------|-----------------------|
| HIV +ve | 7 | 35% | | |
| HIV -ve | 36 | 72% | | |
| | | | S.E.D. | 95% Confidence Limits |
| | | | 12% | 13% - 61% |

Positive predictive value

HIV -ve (Presence of upper region involvement)

$$= \frac{70\% (36)}{52}$$

HIV +ve (absence of upper region involvement)

$$= \frac{65\% (13)}{20}$$

Cavities Presence

| | No. | Percentage | | |
|---------|-----|------------|--------|--------------------------|
| HIV +ve | 4 | 20% | | |
| HIV -ve | 28 | 56% | | |
| | | | S.E.D. | 95% Confidence Limits |
| | | | 11% | 4% - 48% |

Positive predictive value

HIV +ve (Absence of cavity.

$$= \frac{16}{20} = 80\%.$$

HIV -ve (Presence of cavities.

$$= \frac{28}{52} = 56\%.$$

Pleural Reaction

| | No. | Percentage | | |
|---------|-----|------------|--------|--------------------------|
| HIV +ve | 3 | 15% | | |
| HIV -ve | 21 | 42% | | |
| | | | S.E.D. | 95% Confidence Limits |
| | | | 11% | 6% - 28% |

Result: Difference not significant

Positive predictive value.

HIV +ve (No pleural reaction)

$$= \frac{17}{20} = 85\%$$

Positive predictive value

HIV -ve (Pleural reaction present)

$$= 42\%$$

Billateral Disease of Mid + Lower Zones

| | No. | Percentate | | |
|---------|-----|------------|--------|--------------------------|
| HIV +ve | 8 | 40% | | |
| HIV -ve | 4 | 8% | | |
| | | | S.E.D. | 95% Confidence Limits |
| | | | 12% | 8% - 56% |

Result: Significant difference in the two samples

Positive predictive value

HIV +ve (Presence of)

$$= \frac{8}{20} = 40\%$$

HIV -ve (Absence of)

Mediastinal Enlargement

| | No | Percentage | | |
|---------|----|------------|--------|--------------------------|
| HIV +ve | 7 | 35% | | |
| HIV -ve | 7 | 14% | | |
| | | | S.E.D. | 95% Confidence Limits |
| | | | 12.5 | 0 - 46% |

Result: No significant difference in the two samples.

Positive predictive value

HIV +ve (for presence mediastinal enlargement)

$$= \frac{7}{20} = 35\%$$

Positive predictive value

HIV -ve (absence of mediastinal enlargement)

$$= \frac{45}{52} = 86\%$$

Presence of

- a) Upper region involvement
- b) Cavity formation
- c) Normal size mediastinum
- d) Elevation of hilum

| | No | Percentage | | |
|---------|----|------------|-------|--------------------------|
| HIV +ve | 30 | 60% | | |
| HIV -ve | 2 | 10% | | |
| | | | S.E.D | 95% Confidence Limits |
| | | | 93 | 31% - 69% |

Result: Significant

Positive predictive value

(with all the above)

$$\text{HIV -ve} = \frac{30}{52} = 60\%$$

Positive predictive value (absence of all the above)

$$\text{HIV +ve} = \frac{18}{20} = 90\%$$

Presence of

- (a) Mediastinum enlargement
- (b) Middle and lower zone disease only
- (c) Absence of cavity.

| | No | Percentage | | |
|---------|----|------------|-------|--------------------------|
| HIV +ve | 5 | 25% | | |
| HIV -ve | 10 | 10% | | |
| | | | S.E.D | 95% Confidence Limits |
| | | | 10.2 | 0 - 37% |

Result: No significant difference in the two samples

Position predictive value

HIV +ve (Present of all the above)

$$= \frac{5}{20} = 25\%$$

Position predictive value (absence of all the above)

$$= \frac{42}{52}$$

$$= 60\%$$

| LESION | No. | PERCENTAGE | S.E.D. | CONFIDENCE LIMITS | LEVEL OF SIGNIFICANCE |
|--|-----|------------|--------|-------------------|-----------------------|
| Normal chest HIV +ve | 3 | 15% | 9 | 0 - 14% | Not Significant |
| HIV -ve | 10 | 20% | | | |
| Soft tissue reduction HIV +ve | 4 | 20% | 10 | 0 - 12% | Not Significant |
| HIV -ve | 9 | 18% | | | |
| Vertebral and Rib involvement HIV +ve | 4 | 10% | 8 | 0 - 10% | Not Significant |
| HIV -ve | 10 | 12% | | | |
| Hemidiaphragm Elevation HIV +ve | 4 | 8 | 9 | 9 - 26% | Not Significant |
| HIV -ve | 3 | 25 | | | |
| Hilum Elevation HIV +ve | 7 | 35% | 9 | 1 - 19% | Not Significant |
| HIV -ve | 21 | 45% | | | |

}

| LESION | No. | PERCENTAGE | S.E.D. | CONFIDENCE LIMITS | LEVEL OF SIGNIFICANT |
|-------------------------------|---------------|------------|--------|-------------------|----------------------|
| Entire Hemithorax Involvement | HIV fve 2 | 10% | 7 | 0 - 18% | Not Significant |
| | HIV -ve 3 | 6% | | | |
| Bronchogenic spread | HIV +ve 10 | 50% | 14 | 0 - 32% | Not Significant |
| | HIV -ve 27 | 54 | | | |
| Calcification | HIV +ve 0 | 0% | 4 | 0 - 16% | Not Significant |
| | HIV -ve 4 | 3% | | | |
| Pneumothorax | HIV +ve 2 | 10% | 6.5 | 0 - 23% | Not Significant |
| | HIV -ve 0 | 0% | | | |

C
ZTM
*
>
O
V°
F
N
50
H

CONCLUSION

While it remains true that the diagnosis of Pulmonary tuberculosis is by isolation of acid fast bacilli in sputum, or lymph biopsy, the presence of upper region involvement, cavitation and hilum elevation on a chest radiograph means that the patient is unlikely to have human immunodeficiency virus infection in addition to the pulmonary tuberculosis.

DISCUSSION

The radiographic features seen on a chest radiograph in a pulmonary tuberculosis patient of African origin has been known to be different from those seen in the western world (20).

However involvement of the upper zones by lflllbq.fr pneumonia has been found to be more common than that of any other zone in the lungs (20). Before the advent of human immunodeficiency virus testing, a study done in England reported upper zone involvement to be found in 84% of pulmonary tuberculosis patients. Here in Kenya, Dr. Haynes in 1951 found that 33% of pulmonary tuberculosis patients had involvement of the upper zones (10). This study shows that among the HIV^{-ve} patients 72% had upper zone involvement compared with only 35% among the HIV^{+ve} patients. This difference is found to be more than 2 S.E.D. which makes it significant. A similar study done in Zambia confirms the above. (HIV^{+ve} 69% HIV^{-ve} 92%) (1). It was also found to be the same in American patients (21).

Cavity formation has for a long time been considered to be the hallmark of post primary tuberculosis (4). They have been used to indicate the presence of disease (PTB) and the response to treatment (3). The presence of cavities has been associated with

active disease and decreasing size is associated with progressive healing. This study shows that only 20% of the HIV patients showed cavity formation compared with 56% of the HIV^{ve} patients. The difference is more than two standard error of difference range. In another pilot project for an ongoing study on the same subject done at the infectious disease hospital in Nairobi, found cavities is 51% of HIV^{ve} patients (8). The same was found in Zambia where 48% of HIV patients had cavities compared with 68% of HIV^{-ve} patients (1).

The presence of mediastinal enlargement in primary tuberculosis has been associated with enlarged lymph nodes (22). This study shows that there is more mediastinal enlargement amongst HIV^{ve} patients (35%) compared with HIV^{-ve} patients (14%). Although this difference is found to be within 2 S.E.D. and therefore not significant, the same observation of difference was found in the pilot project at I.D.H. (HIV^{+ve} 32% HIV^{-ve} 15%) (8). Dr. Pitchenick also reported the tendency to have more mediastinal enlargement among the HIV /PTB patients (21). The presence of mediastinal enlargement in human immunodeficiency virus patients has also been associated with development of kaposi sarcoma and lymphomas (19). However in our environment postmortems on pulmonary tuberculosis HIV are rarely done. I therefore cannot be certain that the lymph node enlargement seen in this patients is due to mycobacteria infiltration. Kaposi sarcoma, lymphomatus infiltration

and pneumocystitis carine infection have been shown to give a similar picture (19).

Pleural reaction in the form of pleural fluid or thickening are features of both primary and secondary pulmonary tuberculosis (20). this study shows that among the radiographs analysed only 15% of the HIV⁺VP⁺/PTB had any reaction. The HIV⁻VP⁻/PTB patients had reaction observed in 42%. This difference is however within the 2 S.E.D. range therefore not significant. The studies in Zambia even though seem to confirm the difference, where they found that among the HIV⁺VP⁺/PTB patients pleural reaction and pericardial disease was under represented.

\

Fibrosis and loss of volume has been associated with post primary tuberculosis. They are shown on a radiograph by trachea shift, hilum elevation and the orientation of blood vessels (pulmonary). This study shows that HIV⁺VP⁺/PTB patients have less of both (trachea shift 8.2%. Hilum shift 11% compared with HIV⁻VP⁻/PTB patients (trachea shift 29.2% hilum elevation 27.4%). This difference are both found to be significant. Previous studies did not comment on the above.

Calcification as seen on a chest radiograph of a pulmonary tuberculosis patient is mainly in the pulmonary or mediastinal lymph nodes. The presence of calcification has been associated with healing of an

infection focus (3). This study shows that such calcification is underpresented among the HIV^{+ve}/PTB patients where no patient was observed to have calcification. This may mean that HIV^{+ve}/PTB have no ability to heal following the infection.

All other features analysed showed no significant difference between the two groups. Therefore one has to analyse the chest radiograph closely to pick the differences.

Finally it is known that the spread of mycobacteria organisms is mainly by lymphatics. This happens without inhibition in the primary disease and therefore you have hilar lymph node enlargement (3). There is normally minimal pulmonary tissue damage in primary disease. In the post primary disease spread by lymphatics is inhibited by a delayed cell mediated type of hypersensitivity (3). This same process is responsible for the pulmonary damage seen in the lungs. In HIV patients, the amount of delayed hypersensitivity reaction is reduced as a result of decrease in the CD⁺T cells (24). This decreased body's ability to fight the organisms means we have less pulmonary tissue damage with enlarged hilar and mediastinal lymph nodes.

However one should bear in mind that this patients are susceptible to multiple infections and some of the features we see may be due to other infections e.g. pneumocystitis carinii, kaposis etc.

REFERENCES

1. Allison M. Elliot
Impact of human immunodeficiency virus infection.
British Medical Journal 301 Sept. 1990, 412-415.

2. Amodio J.B
Paediatric Aids
Seminar in Roentgenology volume xxii No. 1
Jan. 1987 p.ii. 66-76.

3. Anderson J.R.
Muir's text book of pathology
10th edition, pages 173 - 180.

4. Cahen J.R.
Air flow levels in cavitary pulmonary tuberculosis
Radiology May 1978, 129, 315 - 316.

CDC tuberculosis and acquired, immunodeficiency
syndrome florida
MMW Vol. 1986, 35, 587 - 90.

6. Consultation with clinical officer incharge
NTP programme, Kiambu district on 7th November 1990.

7. *Fraser and Pare*
Diagnosis of diseases of the chest
Vol. 1₃ Second edition₃ pages 186 - 519.

8. *Gathua S.*
Cohort study of human immunodeficiency virus
infected tuberculosis patient.
Basel in radiological features
(un published pilot study for ongoing large study)

9. *George Simon.*
Anterior view of the chest radiograph.
Criteria for normality derived from a basic
analysis of shadows.
Clinical Radiology 1975, 26₃ 429 - 437.

10. *Haynes W.C.*
Tuberculosis in Kenya 1951
Protectorate of Kenya, Page 105 - 126.

11. *Kamiri*
Aids diagnosis clinical criteria
Seminar in Nyeri Dec. 1989.

12. *Koech*
Human immunodeficiency virus infection in Nairobi
New England journal of medicine 1986₃ 314 - 414

13. *Lancet* 1 432; *The new photo*
Feb. 1896.

14. *Lawson D.*
Roentgen rays in the diagnosis of lung diseases
Lancet 25 July 1901

15. *Mulandi*
Aids in Kenya
Seminar in Nyeri Dec. 1989.

16. *National tuberculosis leprosy programme annual*
report 1989.

17. *Naidich P. David*
Radiographic manifestation of pulmonary diseases
in acquired immunodeficiency syndrome
Seminar in Roentgenology vol. XXII No. 1
Jan 1987, p.p. 14 - 30.

18. *Ndinya*
Optimistic infection in aids patients in Kenya
Seminar in Nyeri Dec. 89.

19. *Nybera David*
Aids - Related kaposi sarcoma and lymphoma
Seminar in Roentgenology Vol. XXII No. 1
Jan. 1987, pp. 54 - 65.

20. Palmer
Tropical Radiology, pages 255 - 275

21. Pitchenick A.E.
Radiological appearances of tuberculosis in patients with aids and pre-aids.
American respiration diseases, 1985₃ 131 (393-6)

22. Paul and Juhls
Essentials of Roentgen interpretation
Fourth edition₃ chapter 25_s pages 879 - 881.

23. R.Y. Keers
Tuberculosis. A journey down the century.
Advent of Radiology₃ pages 96 - 98.

24. Schittman
Significance of human immunodeficiency virus infection
Annals journal of internal medicine, 15 sept. 1990.

25. Sutton
Textbook of Radiology
pages 452 - 6.

ACKNOWLEDGEMENTS:

I sincerely wish to express my words of thanks to the following:-

Dr. Malik, my supervisor, who is also the Chairman, department of Radiology in Aga Khan hospital for his valuable, constant guidance, advice and suggestions provided throughout the preparation of this dissertation. I would also like to thank Dr. Maroo for reading through (my draft and for the constructive criticisms.

All the staff of departments of Pathology, Medical records and Radiology department of the Aga Khan hospital and Kiambu hospital. Special thanks to Dr. Radia and Dr. Baraza.

To my wife and children, thank you very much for your patience and understanding.

Lastly but not least to Mrs. Joyceline Nderitu for the tremendous secretarial work done despite my very bad handwriting.