

Computed tomographic evaluation of the odontoid process for two-screw fixation in type-II fracture: a Malaysian perspective

MI Yusof, AH Yusof

Department of Orthopaedics, School of Medical Science USM, Kelantan, Malaysia

MS Abdullah

Department of Radiology, School of Medical Science USM, Kelantan, Malaysia

TMAR Hussin

Department of Community Medicine, School of Medical Science USM, Kelantan, Malaysia

ABSTRACT

Purposes. To measure the diameter of the odontoid process in a Malaysian population using computed tomographic (CT) scan and determine the feasibility of treating type-II odontoid fractures using 2 cortical screws.

Methods. CT images of the odontoid process of 85 patients aged 18 to 80 years were analysed; 69 (81%) were male (mean age, 44 years) and 16 (19%) were female (mean age, 48 years). Both anteroposterior (AP) and transverse diameters of the odontoid process were measured via axial CT images at 3 different levels: the base of the odontoid process and 1.2 mm and 2.4 mm above the base.

Results. The mean AP and transverse diameters of the odontoid process in men were 11.3 (range, 10.0–12.6; standard deviation [SD], 0.7) mm and 10.2 (range, 8.5–12.3; SD, 0.8) mm respectively, whereas in women were 10.9 (range, 9.4–13.2; SD, 0.8) mm

and 10.1 (range, 7.9–11.6; SD, 0.9) mm respectively. The difference in corresponding mean dimensions between men and women was not statistically significant. The mean AP diameter was significantly larger than the mean transverse diameter. At the base and 1.2 mm and 2.4 mm above the base, the respective transverse diameters of 4 (5%), 13 (15%), and 24 (28%) of the patients were <9.0 mm. None had an odontoid AP diameter of <9.0 mm at any level.

Conclusion. Two 3.5-mm cortical screws appear too big for fixation in one third of our sample presenting with type-II odontoid fracture. Fixation by two 2.7-mm screws is recommended for Malaysians and other Asian populations.

Key words: Asian continental ancestry group; bone screws; fracture fixation, internal; odontoid process

INTRODUCTION

Anterior screw fixation for type-II odontoid fracture

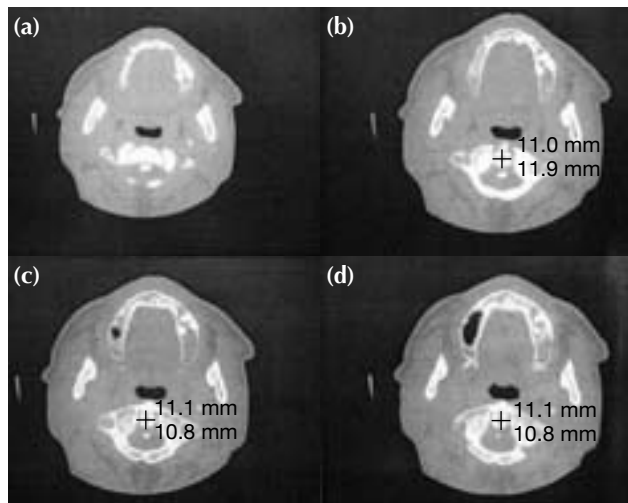


Figure 1 Axial computed tomographic scan sections at (a) the true base of odontoid process where the outer diameter is not well-delineated. Measurements are taken at (b) the base where the outer diameter is well-delineated, and at (c) 1.2 mm and (d) 2.4 mm above the base.

is the treatment of choice in selected patients.¹ It has a high union rate and preserves C1-C2 mobility. Fixation by 2 cortical screws is generally better than by one, especially for rotational stability; however insertion of 2 screws is difficult, even risky in certain patients. It is unsuitable for patients with an odontoid diameter of <9.0 mm.² The diameter of the odontoid process of Asians has not been reported and is likely to be smaller than that of Caucasians. Therefore, it may need to modify the method of screw fixation and/or the screw sizes to accommodate odontoid morphology. We aimed to measure the diameter of the odontoid process in a Malaysian population using computed tomography (CT) and determine the feasibility of treatment with 2 cortical screws in type-II odontoid fractures.

MATERIALS AND METHDOS

Anteroposterior (AP) and transverse diameters of the odontoid process were measured for adult patients admitted to our institution between January 2003 and April 2004 with head injuries that were being assessed for upper cervical fracture. CT scans of the odontoid process were performed using a General Electric CT scanner (GE Medical Systems, Milwaukee [WI], US). Patients who had C1 or C2 fractures were excluded. CT cuts were made at 1.2-mm intervals. The diameters of the odontoid process referred to the outer diameter

of the bone and were measured at 3 levels: at the base and 1.2 mm and 2.4 mm above the base. All measurements were perpendicular to the long axis of the odontoid process, corresponding to the level of type-II odontoid fractures (Fig. 1) The base diameter was defined as the lowest level with the most well-delineated axial CT image of the odontoid process. Statistical analysis was performed using Statistical Package for the Social Sciences (version 11.0; SPSS inc, Chicago [IL], US).

RESULTS

Measurements from 85 patients aged 18 to 80 years were available; 79 (93%) were Malay, 5 (6%) were Chinese, and 1 (1%) was Indian. 69 (81%) were male with a mean age of 44 years and 16 (19%) were female and had a mean age of 48 years.

The mean AP and transverse diameters of the odontoid process in men were 11.3 (range, 10.0–12.6; standard deviation [SD], 0.69) mm and 10.2 (range, 8.5–12.3; SD, 0.84) mm, respectively, whereas in women were 10.9 (range, 9.4–13.2; SD, 0.8) mm and 10.1 (range, 7.9–11.6; SD, 0.9) mm, respectively. The difference in corresponding mean dimensions between men and women was not statistically significant, and therefore odontoid diameters of both men and women were considered together for subsequent analysis. Tables 1 and 2 outline all AP and transverse diameter measurements taken at the 3 different levels. The mean AP diameter was significantly larger than the mean transverse diameter ($p < 0.001$).

29 (34%) of the patients had at least one level of odontoid transverse diameter being <9.0 mm: 4 (5%) at the base, 13 (15%) at 1.2 mm above the base, and 24 (28%) at 2.4 mm above the base. Nonetheless, none of them had an odontoid AP diameter of <9.0 mm at any level and the mean AP and transverse diameters were >9.0 mm (Table 3).

DISCUSSION

Severe head injury is usually associated with upper cervical spine fractures.³ It has been our practice to extend the CT scanning down to C1 and C2 levels, to rule out possible upper cervical spine injuries.

Anterior screw fixation is the treatment of choice for type-II and cephalad type-III odontoid fractures.⁴ It is effective in the treatment of fresh fractures⁵ and in selected cases of odontoid nonunion.⁶ The anterior approach also provides better outcomes than posterior cervical fusion.⁷

Table 1
Anteroposterior and transverse diameters of the odontoid process at 3 different levels in patients with at least one measurement <9.0 mm

Patient No.	Sex	Age (years)	Anteroposterior diameter (mm)			Transverse diameter (mm)		
			Base	1.2 mm above base	2.4 mm above base	Base	1.2 mm above base	2.4 mm above base
1	F	61	9.8	9.4	9.0	10.2	8.6	7.8
2	M	20	11.5	11.3	10.6	12.2	10.2	8.7
3	M	20	11.2	10.9	10.9	11.2	9.4	8.8
4	F	59	10.0	10.5	10.5	10.9	9.1	8.1
5	F	50	11.4	11.0	11.0	11.0	9.2	8.8
6	F	78	10.4	10.7	10.2	11.6	8.3	8.8
7	M	54	11.7	10.7	10.2	11.3	10.0	8.7
8	F	56	11.2	10.8	10.6	10.1	9.7	8.2
9	M	64	11.1	10.1	10.2	9.6	8.2	8.2
10	M	64	12.6	12.2	12.2	8.7	9.2	9.8
11	F	22	11.6	10.9	11.2	10.2	10.4	8.8
12	M	64	12.1	11.6	11.6	9.8	8.9	8.6
13	M	23	11.8	10.5	10.1	11.3	9.7	8.8
14	M	54	11.3	11.3	11.3	11.3	10.0	8.6
15	M	18	11.4	11.0	11.0	10.7	9.7	8.8
16	M	42	9.8	10.2	10.7	8.8	8.7	8.3
17	M	22	11.7	11.7	12.2	10.2	9.3	8.3
18	M	43	12.2	12.1	12.1	11.8	9.3	8.4
19	M	18	10.0	10.7	10.3	9.2	8.1	8.5
20	M	18	10.5	10.5	10.8	9.1	8.3	8.0
21	M	78	10.1	10.5	10.7	10.1	8.3	7.9
22	F	68	11.2	10.6	10.7	7.8	8.3	7.8
23	M	45	9.9	10.4	10.8	10.4	9.6	8.3
24	M	23	9.8	10.3	10.0	9.5	8.5	8.0
25	M	64	11.6	11.6	10.8	9.1	8.6	9.6
26	M	25	11.6	11.6	11.1	9.2	8.6	9.4
27	M	71	11.1	11.2	11.2	8.8	9.3	10.2
28	M	49	11.7	9.7	9.7	11.2	8.8	9.3
29	M	42	11.9	12.2	12.2	10.2	9.3	8.6

Odontoid diameters of some non-Caucasians may not be large enough to accommodate 2 cortical screws; introducing two 3.5-mm screws can therefore be dangerous. Many studies have shown the difference of spinal morphology in Caucasians and Asians.⁸ The minimal outer diameter of the odontoid process for the placement of two 3.5-mm cortical screws with tapping is reported to be 9.0 mm.² Approximately 95% of the western population has an odontoid diameter of at least 9.0 mm.² Patients with an odontoid diameter of <9.0 mm are unsuitable for 2-screw fixation.

Although the inner diameter may better reflect the feasibility of 2-screw fixation, the outer diameter of the odontoid process was used because the inner diameter may increase with tapping, and the screw threads can be partly embedded in the cortex. The inner diameter of the odontoid process can be very narrow with corresponding thick irregular cortices.

Measurements were made at 1.2 mm and 2.4 mm above the base of the odontoid process where type-II fractures are most common and probably constitute the odontoid waist. The narrowest diameter of the odontoid process is reportedly at 3.0 mm above the base.² In the present study, the transverse diameter at 2.4 mm above the base was the smallest in 77% of the odontoid processes measured, which may represent the odontoid waist. In 18% of our patients the smallest diameter was located below this level.

Different screw-fixation methods may be indicated depending on odontoid morphology. About one third of our samples were not suitable for the insertion of two 3.5-mm screws for the treatment of type-II odontoid fracture; 34% of them had at least one level of transverse diameter being <9.0 mm, too small to accommodate two 3.5-mm cortical screws. Nonetheless, their AP diameters were >9.0 mm and

Table 2
Anteroposterior and transverse diameters of the odontoid processes at 3 different levels in patients with all measurements ≥ 9.0 mm

Patient No.	Sex	Age (years)	Anteroposterior diameter (mm)			Transverse diameter (mm)		
			Base	1.2 mm above base	2.4 mm above base	Base	1.2 mm above base	2.4 mm above base
1	M	64	12.1	12.8	12.8	12.4	10.8	10.1
2	M	80	12.1	11.2	11.8	11.2	10.0	9.3
3	M	34	12.7	12.2	11.2	12.7	10.7	10.3
4	M	70	11.1	11.9	12.1	12.4	10.9	9.0
5	M	52	11.9	9.2	9.0	12.2	12.4	12.4
6	M	64	12.1	12.4	12.4	12.1	10.4	9.3
7	M	23	11.9	11.9	12.0	11.3	10.4	9.8
8	M	34	11.0	10.8	11.0	12.6	9.7	10.8
9	M	33	12.1	11.8	12.3	12.2	10.7	10.7
10	F	36	11.4	10.8	10.8	12.9	11.4	10.3
11	M	37	11.6	12.4	11.7	11.8	10.2	9.2
12	F	29	11.2	10.9	10.3	12.5	10.0	10.6
13	M	42	11.4	10.8	11.2	12.0	9.6	9.0
14	M	20	11.3	10.5	10.2	12.9	10.6	10.6
15	M	71	12.3	10.8	10.5	12.3	11.2	9.3
16	M	49	10.3	11.2	11.2	12.2	10.3	9.3
17	M	30	11.2	11.6	12.7	11.7	10.8	10.3
18	M	18	11.9	12.2	11.2	11.9	10.1	9.4
19	M	20	11.1	11.0	11.8	11.8	10.6	9.8
20	F	38	10.3	10.7	11.6	9.8	9.4	10.3
21	M	49	9.8	11.0	10.7	12.1	11.6	11.3
22	M	21	12.5	12.2	11.5	11.8	10.8	9.8
23	M	18	11.0	10.6	10.6	12.2	10.7	9.4
24	M	48	12.0	12.0	12.6	12.3	11.0	9.7
25	M	61	12.7	12.7	12.2	11.7	10.3	10.3
26	M	19	11.9	11.8	11.9	11.9	11.6	9.8
27	M	60	10.8	11.8	11.8	12.1	10.8	11.9
28	M	66	10.2	10.2	10.7	11.1	10.7	9.4
29	M	44	12.4	11.4	11.4	11.9	10.5	9.4
30	M	73	12.3	11.7	11.3	11.4	9.8	10.1
31	F	32	10.9	9.7	10.1	10.5	10.3	10.1
32	F	54	11.7	11.4	10.5	13.0	11.5	10.3
33	M	40	10.2	10.5	10.5	10.2	9.9	9.9
34	F	34	12.7	13.2	13.7	10.2	10.7	11.2
35	M	26	10.2	10.8	10.3	10.6	9.7	10.2
36	M	70	13.2	12.2	12.2	10.8	11.2	10.3
37	M	31	11.0	10.6	10.1	10.1	10.8	9.6
38	M	54	10.6	11.1	10.6	10.6	9.6	9.2
39	M	29	12.0	11.7	11.7	12.4	11.7	10.6
40	F	60	11.5	11.5	11.2	11.9	11.5	9.8
41	M	22	11.3	10.5	10.0	11.3	9.7	9.0
42	M	18	12.1	12.1	11.6	11.6	10.7	10.1
43	M	57	11.8	11.9	12.8	11.1	9.3	9.3
44	M	33	12.3	11.8	11.8	10.8	9.9	9.7
45	M	64	12.1	11.3	11.3	10.2	9.0	9.1
46	M	42	11.6	11.2	11.2	12.0	9.9	9.6
47	M	64	12.4	11.8	12.1	11.4	10.8	9.7
48	M	61	11.5	10.8	11.2	9.2	9.2	9.2
49	M	24	11.1	11.6	11.6	10.6	9.1	9.1
50	M	24	11.7	11.4	11.4	10.4	9.8	9.1
51	M	59	11.1	11.1	10.5	11.1	10.1	9.1
52	M	63	11.8	11.1	11.4	10.8	9.9	9.3
53	F	23	12.6	11.5	11.2	12.2	9.8	9.7
54	M	22	11.6	12.0	12.2	11.4	11.4	11.2
55	F	75	11.4	10.7	10.3	10.6	10.0	9.6
56	M	76	10.8	10.1	10.5	11.0	10.1	10.1

Table 3
Mean anteroposterior and transverse diameters of the odontoid process in all 85 patients

Odontoid diameter	Mean (range) [mm]	No. of patients with odontoid diameter of <9.0 mm
Anteroposterior diameter		
At base	11.4 (9.8–13.2)	0 (0%)
1.2 mm above base	11.2 (9.2–13.2)	0 (0%)
2.4 mm above base	11.1 (9.0–13.7)	0 (0%)
Transverse diameter		
At base	11.1 (7.8–13.0)	4 (5%)
1.2 mm above base	9.9 (8.1–12.4)	13 (15%)
2.4 mm above base	9.4 (7.8–12.4)	24 (28%)

larger than transverse diameters. Thus, if the 2-screw fixation is preferred, the orientation of the screws should be modified.

An alternative is to use 2 screws of smaller diameter or a single screw of similar diameter. Two-screw fixation offers better stability in rotation and extension loading compared to one-screw fixation,⁹ though there is no significant difference in the union rates achieved.¹⁰ Two 2.7-mm cortical screws can provide adequate stability for fixation of type-II odontoid fractures; no evidence of nonunion and major complications was encountered.¹¹ For two 2.7-mm screws fixation, the minimum odontoid diameter required is about 7.4 mm, considering that each screw requires at least a 0.5-mm rim of bone around the screw² (Fig. 2). Smaller odontoid processes can accommodate such screws. All measurements in our patients were >7.4 mm and they may benefit from this fixation technique with less risk of neurological injury, in contrast to only about two thirds for whom 3.5-mm screws could be safely inserted.

A single 4.5-mm cannulated Herbert screw is adequate for fixation of type-II odontoid fractures and less technically demanding.¹² The loading to failure was not significantly different between the one- and 2-screw techniques, although the latter did provide increased stiffness in extension loading.⁹ The union rates of either technique was not significantly different.¹⁰

Body height or weight do not significantly correlate with the odontoid process dimensions.¹³ Our

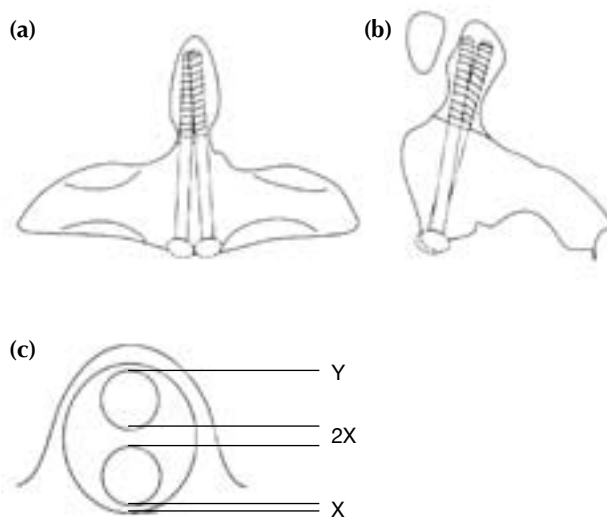


Figure 2 (a) Anteroposterior, (b) lateral, and (c) axial views of the odontoid process showing the configuration of the 2-screw fixation. The screws are negotiated through the narrow odontoid waist and positioned in the anteroposterior diameter of the odontoid process. X represents the minimum bone rim required (0.5 mm) and Y the screw diameter.

study did not show any statistically significant difference in diameters between male and female patients, probably because the number of females was too small for comparison.

Two-screw fixation for odontoid fractures may result in severe complications. Preoperative CT study along with careful surgical technique is mandatory, and contraindications should always be respected.⁴

CONCLUSION

Odontoid diameter, bone quality, and the surgeon's experience are equally important for the success of the two 3.5-mm cortical screw fixation technique for type-II odontoid fractures. Although applicable in >95% of Caucasian patients, the screws appear too big for one third of the Malaysian population. We recommend the use of two 2.7-mm screws for our Malaysian population. This recommendation may also apply to other Asian populations. Preoperative study of the odontoid diameter is mandatory to determine the safety and feasibility of this technique.

REFERENCES

1. Anderson LD, D'Alonzo RT. Fractures of the odontoid process of the axis. *J Bone Joint Surg Am* 1974;56:1663–74.
2. Nucci RC, Seigal S, Merola AA, Gorup J, Mroczek KJ, Dryer J, et al. Computed tomographic evaluation of the normal adult odontoid. Implications for internal fixation. *Spine* 1995;20:264–70.
3. Bohlman HH. Acute fractures and dislocations of the cervical spine. An analysis of three hundred hospitalized patients and review of the literature. *J Bone Joint Surg Am* 1979;61:1119–42.
4. Jeanneret B, Vernet O, Frei S, Magerl F. Atlantoaxial mobility after screw fixation of the odontoid: a computed tomographic study. *J Spinal Disord* 1991;4:203–11.
5. Henry AD, Bohly J, Grosse A. Fixation of odontoid fractures by an anterior screw. *J Bone Joint Surg Br* 1999;81:472–7.
6. Esses SI, Bednar DA. Screw fixation of odontoid fractures and nonunions. *Spine* 1991;16(10 Suppl):S483–5.
7. McLain RF. Salvage of a malpositioned anterior odontoid screw. *Spine* 2001;26:2381–4.
8. Chadha M, Balain B, Maini L, Dhaon BK. Pedicle morphology of the lower thoracic, lumbar, and S1 vertebrae: an Indian perspective. *Spine* 2003;28:744–9.
9. Sasso R, Doherty BJ, Crawford MJ, Heggeness MH. Biomechanics of odontoid fracture fixation. Comparison of the one- and two-screw technique. *Spine* 1993;18:1950–3.
10. Jenkins JD, Coric D, Branch CL Jr. A clinical comparison of one- and two-screw odontoid fixation. *J Neurosurg* 1998;89:366–70.
11. El Saghir H, Bohm H. Anderson type II fracture of the odontoid process: results of anterior screw fixation. *J Spinal Disord* 2000;13:527–31.
12. McBride AD, Mukherjee DP, Kruse RN, Albright JA. Anterior screw fixation of type II odontoid fractures. A biomechanical study. *Spine* 1995;20:1855–60.
13. Schaffler MB, Alson MD, Heller JG, Garfin SR. Morphology of the dens. A quantitative study. *Spine* 1992;17:738–43.