


THE PATTERN OF MRI FINDINGS IN PATIENTS WITH SHOULDER PAIN AT THREE IMAGING CENTRES IN NAIROBI.

DISSERTATION SUBMITTED AS PART FULLFILMENT FOR THE DEGREE OF MASTERS IN DIAGNOSTIC IMAGING AND RADIATION MEDICINE OF THE UNIVERSITY OF NAIROBI.

BY



DR LAWRENCE MUGAMBI M'ARITHI, MBChB, (NBI).


2009

UNIVERSITY OF NAIROBI
MEDICAL LIBRARY

DECLARATION.

Candidate:

This dissertation is my original work and has not been presented for a degree in any university.


Signed.....

Date.....18/02/2009

DR. LAWRENCE MUGAMBI M'ARITHI, MBChB(NBI).

Supervisor:

This dissertation has been submitted for examination with my approval.

Signed.....

Date.....02/03/2009

DR CALLEN K. ONYAMBU MBChB (NBI).

MMED Diagnostic Radiology (NBI).

Lecturer,

Department of Diagnostic Imaging and Radiation Medicine.

University of Nairobi.

ACKNOWLEDGEMENT

This study has been possible with the assistance of a number of people to whom I would like to express my sincere gratitude.

I am indebted to my supervisor Dr Callen K. Onyambu for her continued guidance, suggestions, comments and encouragement throughout the study period.

I thank the management of Nairobi hospital and Dr Odhiambo of Plaza Imaging Solutions for allowing me to conduct the study at their private imaging centres.

I would also like to thank my brother Patrick Kinoti M'Arithi for his immense material support.

Finally I owe special thanks to my family for their encouragement, perseverance and moral support. Alice my wife, Renee, Janet and Ian I am grateful to you all.

TABLE OF CONTENTS

	Page
TITLE:	1
DECLARATION:	2
ACKNOWLEDGEMENT:.....	3
TABLE OF CONTENTS:.....	4
ABBREVIATIONS:	5
COLLABORATING INSTITUTIONS:.....	6
ABSTRACT:	7
INTRODUCTION AND LITERATURE REVIEW:.....	8
STUDY OBJECTIVE:	17
STUDY JUSTIFICATION:.....	17
ETHICAL CONSIDERATION:.....	18
STUDY METHODOLOGY:.....	18
STUDY LIMITATION.....	19
RESULTS:.....	20
DISCUSSION:.....	35
CONCLUSION.....	39
RECOMMENDATIONS.....	30
REFERENCES:.....	41
APPENDICES	
A (DATA COLLECTION FORM):.....	45
APPENDIX B (PATIENT'S CONSENT FORM -ENGLISH):.....	49
APPENDIX C (PATIENT'S CONSENT FORM-KISWAHILI):.....	50

ABBREVIATIONS.

MRI	Magnetic resonance imaging
T ₁ W	T 1 weighted image
ACJ	Acromio-clavicular joint
KNH	Kenyatta National Hospital
NH	Nairobi Hospital
PIS	Plaza Imaging Solutions
PDW	Proton density weighted image
T ₂ W	T ₂ Weighted image
CT	Computer Tomography
US	Ultrasound
UON	University of Nairobi
USA	United States of America
FLAIR	Fluid attenuated inversion recovery
MRA	Magnetic resonance arthrography
ADC	Apparent diffusion coefficient

COLLABORATING INSTITUTIONS.

This study was done in three main diagnostic centers in Nairobi. They serve as main diagnostic referral centers.

Two hospitals and one private centre will be included in this study.

1. Kenyatta National Hospital.

P.O Box 20723 (00202) KNH, Nairobi.

Telephone numbers 2726300-19, 2726450-9 and 2726550-9

2. The Nairobi Hospital.

P.O Box 30026 (00100) G.P.O, Nairobi.

Telephone numbers 2845000/2846000

3. Plaza Imaging Solutions.

P.O Box 352 (00202) KNH, Nairobi.

Telephone numbers 2711611/2711599.

ABSTRACT

Introduction.

Shoulder pain is a common reason for visiting a physician. It is the third most common cause of musculoskeletal disorder after low backache and cervical pain in USA. No data are available about our local population MRI findings of patients with shoulder pain despite having an MRI machine in our country since 1996.

Objective.

This study was designed to establish the pattern of the findings seen at MR imaging among patients with shoulder pain at three imaging centers in Nairobi.

Study design.

This was a prospective cross sectional descriptive study.

Study Methodology.

The study was conducted for a period of six months between the months of June 2008 and the month of December 2008. 70 patients referred for MR imaging were scanned at the three imaging centers. The date of scanning, age, sex and referring clinician were documented. The MR findings were documented. The data was eventually analyzed using computer software.

Results

There were 38 (54.3%) male and 32(45.7%) female patients scanned. The age ranged from 20 to 86years. The mean age was 48.0 years. The 46 - 60years had the most lesions. Patients below 30years were 9(12.9%) and over 30years were 61(87.1%). A total of 120 lesions were seen. The right shoulder had most pathology with 104(86.7%) lesions. The commonest lesion was tendinosis with 34(28.3%) lesions and was seen more on the right shoulder. Rotator cuff tears were 20 (16.7%) and mostly involved the supraspinatus tendon. Degenerative disease lesions were 13 (10.8%).

Conclusion. The right shoulder had more pathology compared to the left. Tendinosis of the supraspinatus tendon was the commonest pathology. In rotator cuff tears, supraspinatus tendon was more frequently involved.

INTRODUCTION AND LITERATURE REVIEW.

Shoulder pain is a common complaint in medical practice and leads to significant disability⁽³⁾. A compromised shoulder due to pain, stiffness or weakness causes substantial disability and affects the person's ability to carry out daily activities. This not only reflects on the person's occupation but also on his social life. In USA, it is the third commonest cause of musculoskeletal disorder after low backache and cervical pain and it is estimated to affect 7-25% of the population. The annual incidence is estimated to be 10 per 1000 population. This peaks to 25 per 1000 population in 42- 46 year age group and 21% of people over 70 years have shoulder pain⁽¹⁾. Self reported prevalence of shoulder pain is estimated to be 16-26 %⁽⁴⁾. Women seem to have more shoulder problems than men but the frequency in both sexes increases with age.

Clinical examination alone is not adequate in identifying the cause of pain, thus various imaging modalities are employed to increase the accuracy of identifying the source of the pain. Plain radiography, arthroscopy, contrast arthrography, Ultrasonography, computer tomography and Magnetic resonance (MRI) are the diagnostic modalities used. Since the commonest cause of shoulder pain is related to soft tissue rather than osseous lesions, MRI is an excellent modality in depicting shoulder pathology. It has an excellent soft tissue contrast and its multiplanar capabilities make it a superior tool in shoulder imaging.

Bongers, in a British medical journal editorial stated that the prevalence of shoulder pain is estimated to be between 20-50% in several countries. And 40-50% of these patients report a persistency or recurrence of pain a year after the first consultation with a physician⁽¹⁾.

In another article **Mitchell et al**, found a self-reported prevalence of shoulder pain to be between 16-26% and certain occupations involving physical work such construction work are associated with an increase in shoulder disorder. They also found and concluded that psychosocial factors do influence the level of the symptoms and disability of those affected⁽⁴⁾.

Pope et al, did a survey on self-reported shoulder pain involving 312 persons in South Manchester UK and found that the prevalence in that month was 31-48 %⁽⁵⁾. In this survey, they found that there was a considerable overlap between pain experienced at different anatomical sites and concluded that estimating the global burden of musculoskeletal complaints by extrapolation is likely to be an overestimate of shoulder disorders.

A review of eighteen studies on the prevalence and incidence of the shoulder disorders by **Luime et al**, found that the prevalence varied from 6.9-26%. It was 18.6-31.0% for one month, 4.7-46.0% for one year and life time prevalence was 6.7-66.7 %⁽⁶⁾. Thus the prevalence and incidence from various countries varied greatly.

Grooten,⁽⁷⁾ in his thesis appreciated the problem of varying incidences of shoulder pain reported from various countries and noted that it is meaningless to compare incidences in different studies without uniform outcome measures because of:

- i. Differences in calculations between the studies.
- ii. Incidence depends on the study population, the proportion of males and females, age and the profession of the subjects.
- iii. Most of the studies had different follow- up periods.

Thus the incidences of shoulder pain varied in different countries.

A study by **Michelle et al**, found that the commonest site of reported musculoskeletal disorder was the back 23% followed by the knee 19%. Shoulder disorder was the third commonest at 16%. The frequency of musculoskeletal disorders and the prevalence of the physical disability increase with age and were more prevalent in people of lower socio-economic status. It is estimated that 15% of the general practitioners' consultation is related to musculoskeletal disorders. This could be higher in our society due to our low socio-economic status. Thus appreciating the magnitude of musculoskeletal disorders, its incidence and prevalence within a society and providing appropriate facilities for management will go a long way in relieving the burden of managing advanced cases which might require a prosthesis⁽⁸⁾.

The burden of taking care of the musculoskeletal problem is enormous to the society in terms of lost man-hours, direct hospital bills and workers compensation. This has a tremendous strain to a nation's economy.

Hanssen et al, quoted an estimate of the cost of health services for diagnosis and treatment, absence from work and disability pension from the three commonest causes of musculoskeletal disorders (back, neck and shoulder) to be 30 billion Swedish Kroner in Sweden in 1995⁽⁹⁾.

Rosecrance et al, in a review article found that the cost of workers compensation for low back pain and upper extremity pain in the United State of America was estimated to be \$13 billion in 1995⁽²⁾. This was in terms of compensation and direct bills for their treatment. A Swedish insurance data showed that 18% of all disability claims from musculoskeletal disorders was spent on neck and shoulder disorders. If other expenses such as lost wages, lost production, cost of recruiting, training and replacement, rehabilitation of those affected are evaluated, then the cost to the nation's economy becomes much greater. In a country like ours, this is a great drain of our resources which could be utilized in priority sectors. However there is no available data so that such estimate can be made for our country.

Krief and Huguet, in a study involving 1079 patients found that 916 (85%) had right hand dominance and 669(62%) presented with pain on the right shoulder⁽¹⁰⁾. Majority of the population are right-handed thus disability related to the right shoulder would affect a relatively bigger proportion of the general population.

Malhi and Kahn, in their study in correlating the clinical diagnosis and arthroscopic findings among 130 patients, among them 15 had plain radiographs and 9 showed features of impingement. Six radiographs were normal. Five out of the 6 normal radiographs showed impingement at arthroscopy. In this study, plain radiography identified only 60% of the impingement. Clinical diagnosis detected 80% of the cases preoperatively⁽¹¹⁾. This shows the low pick-up rate of plain radiography in detecting the etiology of shoulder pain.

Vick et al, found that ultrasound was 67% sensitive and 93% specific in the diagnosis of rotator cuff tears⁽¹²⁾. The advantages of Ultrasonography are its availability, usage in interventional procedures, in patients with metallic prosthesis, in claustrophobic patients and has no radiation to the patient. However it has limitation in sonographically inaccessible areas like the bone, labral cartilage and deep parts of the ligaments.

In patients who have had previous surgery, the distortion of tissue planes makes ultrasound an inferior imaging modality. This calls for a superior imaging modality and MRI is the most appropriate.

Chandnani et al, compared conventional MR imaging, MR arthrography, and CT arthrography to determine the sensitivity of each technique in detecting glenoid labral tears and in determining whether the labrum is detached or degenerated in 30 patients. At surgery, labral tears were found in 28 patients; a detached fragment was found in 26 patients. The labrum was found to be degenerated in 18 patients. A labral tear was detected on MR images in 93%, 96% on MR arthrogram and 73% on CT arthrogram. A detached labral fragment was detected on MR images in 46%, 96% on MR arthrogram, and 52% on CT arthrogram. Labral degeneration was detected on MR images 11%, 56% on MR arthrogram and 24% on CT arthrogram. MR arthrography offered the best visualization of the inferior part of the labrum and the inferior glenohumeral ligament. MR imaging and MR arthrography also enabled direct visualization of rotator cuff disease and other unsuspected associated abnormalities⁽¹³⁾.

A study in America by **Nelson et al**, involving 21 patients compared Ultrasonography, MR imaging, CT and operative findings found that MR was the most useful modality for establishing the etiology due to disease in rotator cuff tears, instability associated with abnormality of the glenoid labrum, subacromial impingement, stenosis of the coracoacromial arch and osteoarthritis of either glenohumeral or acromio-clavicular joint. MR was better than either ultrasound or CT in identifying partial thickness tears of the rotator cuff⁽¹⁴⁾.

A study of 91 patients and 15 asymptomatic volunteers by **Iannotti et al**, showed that MRI was 100% sensitive and 95% specific in diagnosis of complete rotator cuff tears and in differentiating tendinosis from degenerative changes it was 82% sensitive and 85% specific. The same study showed that it had 93% sensitivity and 87% specificity in demonstrating a normal and an affected tendon. The sensitivity and specificity of MRI in picking labral tears associated with glenohumeral instability was 88% and 93% respectively⁽¹⁵⁾.

Zlakin et al, compared shoulder MR imaging and surgical findings in 160 patients. He found that MR, in picking rotator cuff tears had sensitivity and specificity of 90% and 98%, for labral

tears, it had a sensitivity and specificity of 55% and 100% respectively. Thus there was a good correlation between MR imaging and surgical findings⁽¹⁶⁾.

Frank et al, using a 0.2 Tesla extremity MR system compared MR imaging findings with surgical findings in 47 patients. they found that specificity and sensitivity of picking up a rotator cuff lesion was 89 % and 100% , for labral tears was 89% and 95%⁽¹⁷⁾.

Jhankaria et al, in a study involving 22 male patients aged 16-50 years, compared MR Arthrogram and arthroscopic findings. MRA detected glenoid tears in all 22 patients (100%) of which 20(91%) were anteroinferior tears. The rest had superior and an inferior labral abnormality. Arthroscopy detected anterior inferior labral tears in 21(95%). The rest had a superior and inferior labral abnormality. Overall sensitivity and specificity of MRA in this study was 90% and 100%. However, MR missed loose bodies which were found at arthroscopy⁽¹⁸⁾.

Zanneti et al, in their study compared decisions made by the surgeons before and after MR imaging in 73 cases and noted changes of therapeutic decision after MR imaging in 36 of the 73 patients (49%). In 23 patients, more invasive therapeutic procedures were initiated after MR imaging and a more conservative treatment was implemented for 13 patients. He concluded that MRI of the shoulder has a major effect on diagnostic thinking and therapeutic decisions by orthopedic surgeons⁽¹⁹⁾.

These studies show that MRI is an excellent reliable imaging tool for shoulder pathology. Its accuracy has led to improvement in management of the shoulder pathology. Regarding the Kenyan situation, no data on our local population on shoulder pain and MRI findings are available despite having an MRI machine in our country since 1996

ANATOMY OF THE SHOULDER (GLENO-HUMERAL) JOINT.

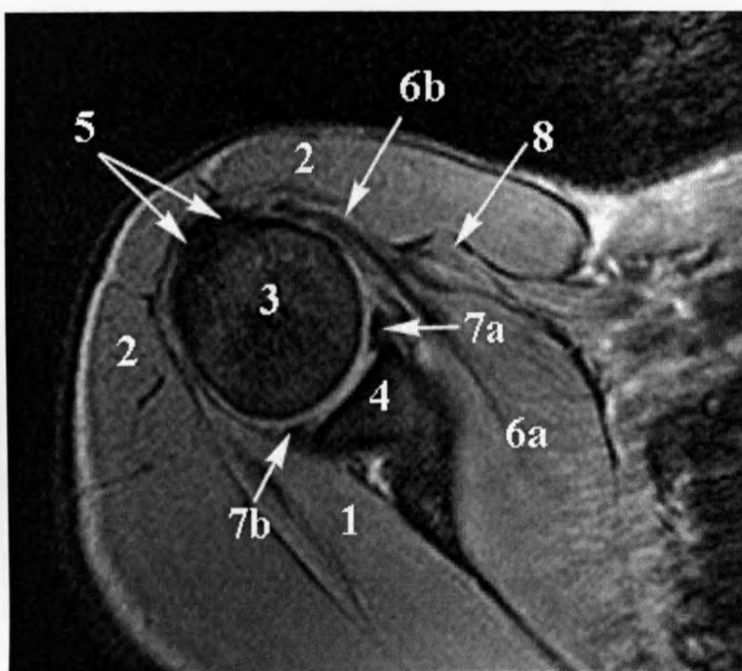
The shoulder joint is the most movable joint in the body but quite unstable owing to its anatomical structure and its wide range of movements. The stability of the joint is a function of multiple structures including the glenoid labrum and the overlying cartilage, the capsule, the rotator cuff tendons and other muscles surrounding the joint. The mechanism of a normal functional shoulder joint is anchored on four basic characteristics, the motion, strength, stability and smoothness. Thus the functional integrity of the shoulder joint is a function of many interrelated factors contributed by the osseous structures and the soft tissues. Any compromise to any of these structures leads to morbidity. This has a profound effect on the person's life.

THE ROTATOR CUFF.

Consists of four muscles and their tendons: the subscapularis, supraspinatus, infraspinatus and teres minor. The rotator interval is a triangular region formed as the supraspinatus and the subscapularis tendon course around the base of the coracoid process. Non rotator structures are several tendons, ligaments and bursa around the shoulder joint and are important in stabilizing the shoulder joint. In MRI, T₁ weighted images provide excellent anatomical details of the joint.

Image 1: T₁W axial MRI image of normal shoulder anatomy.

1:Infraspinatus 2:Deltoid 3:Humeral head 4:Glenoid 5:Biceps long head 6a:Subscapularis muscle 6b:Subscapularis tendon 7a:Anterior labrum 7b:Posterior labrum 8:Coracobrachialis and short head of biceps.



Acromio-clavicular joint (ACJ):

A synovial joint which has a fibrocartilaginous articular disc of variable size and a weak capsule which is thickened superiorly and inferiorly. The normal width of the ACJ is between 2.6mm and 4.4mm⁽²⁰⁾.

CAUSES OF SHOULDER PAIN.

Pain from the shoulder can be from the soft tissues, cartilage, osseous structures, tumors, infections or referred pain from the surrounding structures.

Soft tissues: Includes the muscles and tendons, capsule and the synovium, blood vessels and nerves. An insult to any of these structures may lead to pain and impaired shoulder function

Lesions involving the cartilage: A wide range of cartilage lesions will cause shoulder pain.

Osseous lesions: Degenerative changes of the articular bones of the shoulder joint will cause significant disability. Primary osteoarthritis of the glenohumeral joint is rare compared to other joints such as the knee and the hip. Glenohumeral osteoarthritis is usually secondary to trauma or other disorders such as calcium pyrophosphate or hydroxyapatite crystal deposition, haemophilia, acromegaly, epiphyseal dysplasia, alkaptonuria. Rotator cuff lesions are highly associated with osteoarthritis⁽³¹⁾.

The nerves supplying the shoulder may get entrapped leading to pain. The denervated muscle will lead to pain, atrophy and loss of power. Syndromes associated with nerve entrapment include the suprascapular-splenoglenoid nerve entrapment syndrome, quadrilateral space syndrome and personage-Turner syndrome.

Inflammatory lesions:

1. Non-septic arthritis: This is a fairly commonly encountered entity in clinical practice and poses a diagnostic and a therapeutical challenge. Such disorders clinically presents with non specific signs and symptoms such as pain, swelling and restricted motion. These signs and symptoms can overlap those of articular and extra-articular disorders. These disorders include gout, Milwaukee shoulder, rapidly destructive shoulder disease, amyloid arthropathy, hemophilic arthropathy, primary synovial osteochondromatosis, neuropathic arthropathy and foreign body synovitis⁽²⁹⁾.

2. Septic arthritis: A disabling disease whose delay in diagnosis will lead to disabling joint destruction. Septic arthritis can be pyogenic or non-pyogenic. Various imaging modalities are used in imaging a joint with septic arthritis. CT scanning is more sensitive than plain radiography in detecting early bone disease⁽¹⁹⁾. Abnormal findings in MRI have been described as early as 24 hrs after the onset of the infection. However distinguishing reactive and pyogenic effusion on conventional MRI is quite challenging. Diffusion weighted MRI has been tried with success in separating these two entities⁽³⁰⁾.

Referred pain: Structures around the neck may be the primary source of the pathology. Pain may be from pathology from far organs like the gallbladder and the heart as in acute myocardial infarction.

Rotator cuff pathology: These include rotator cuff tendinosis, rotator cuff tear, subacromial impingement syndrome, subacromial bursitis, subacromial-subdeltoid bursitis, calcifying tendinosis, shoulder peri arthritis and painful shoulder syndrome. The causes of rotator cuff tears are multifactorial. In this type of injury, the supraspinatus tendon is involved in most of the cases. A normal rotator cuff tendon displays a low signal in all MRI sequences. The tear site might be filled with hypertrophic synovium, granulation or fibrotic tissue leading to intermediate signal or hyperintense focus. The shape and size of the rotator cuff tear determines the choice of the surgery and its functional outcome. Fatty degeneration of an old tear would not reverse with surgery. Thus repair should be done before substantial atrophy has occurred⁽³²⁾. Tendinosis of the rotator cuff tendons commonly involves the supraspinatus tendon. On MRI it is characterized by increased intratendon signal intensity. The tendon may be of normal calibre or it may be thickened.

Tumors: They originate from the structures of the shoulder joint or they may be deposits from distant sites. They could be benign or malignant. Clinical presentations may simulate other shoulder joint lesions or sometimes they are incidental findings when imaging the shoulder. Distinguishing between a benign and a malignant tumor on MRI is challenging and every lesion warrants a biopsy⁽³³⁾. Benign tumors include cysts, myxomas, nerve sheath tumors, elastofibromas, lipomas, liposarcomas, desmoid tumors, tumoral calcinosis, osteoid osteoma and osteoblastoma. Malignant tumors may be of osseous origin, soft tissues or metastatic deposits from other sites. Tumors that have a predilection for the humeral head are chondroblastoma and clear cell chondrosarcoma. Metastases, lymphoma, chondrosarcoma and osteogenic sarcoma are the most common to affect the proximal humerus.

IMAGING MODALITIES OF THE SHOULDER JOINT.

The shoulder joint is quite unstable owing to its anatomical structure and its wide range of movements. The multidirectional stability of the joint is a function of multiple structures including the glenoid labrum and the overlying cartilage, the capsule, the rotator cuff tendons and other muscles surrounding the joint. Painful shoulder can present with or without limitation of either passive or active movements and the choice of appropriate imaging modality will depend on the suspected cause of the pain.

Plain radiography:

It is often the only imaging modality necessary in evaluating acute shoulder trauma, calcific tendinitis, arthritis and osteolysis. It is quite useful in trauma or complete chronic tear of the rotator cuff but has a poor pick up rate of etiology of shoulder pain especially in soft tissue injuries⁽²¹⁾.

Conventional arthrography:

Involves injecting iodinated contrast media, air or both. Radiographs are taken at different positions. In complete tears, contrast floods the joint and into the subacromial-subdeltoid bursa. In partial tears, the contrast is seen as a line or small filled cavities within the tendon but not into the subacromial-subdeltoid bursa. These findings are more difficult to demonstrate than when there is a complete tear. Intratendon tears and tears on the superior aspect of the tendon are not demonstrated by this technique⁽²²⁾.

Ultrasonography:

Mainly for diagnosis of rotator and non rotator cuff soft tissue lesions. It has a sensitivity of 93-100% in diagnosis of complete tears. However the pick-up rate depends on the operator. Ultrasonography has limitation in sonographically inaccessible areas like the bone, labral cartilage, deep parts of ligaments and post surgical shoulder thus other imaging modalities such as conventional magnetic resonance imaging, MR arthrography and CT remains the modalities of choice for diagnosing most non-rotator cuff disorders.

Computer tomography (CT):

Computer tomography has a role in imaging of a painful shoulder. Its ability to depict bony structures makes it important especially in evaluating suspected fractures and fracture dislocations. CT arthrography is very sensitive (100%) in depicting rotator cuff tears (allows determination of retraction of the tendon and fatty atrophy of the muscle) but in tendinosis and partial tears, its sensitivity drops to 17-43 %⁽²³⁾.

Magnetic Resonance (MRI):

MR is currently considered as the reference standard for imaging of shoulder disorders. It is a reliable non invasive imaging modality for evaluating shoulder disorder especially those related to rotator cuff and glenohumeral instability⁽²⁴⁾. MR is better than either ultrasound or CT in identifying partial thickness tears of the rotator cuff⁽²⁵⁾. Studies have shown that MRI can depict soft tissues without the need for intraarticular contrast media and can detect early ischemic necrosis, primary and secondary tumor deposits and infections of the shoulder joint. MRI has 100% sensitivity and 95% specificity in diagnosis of complete rotator cuff tears, in differentiating tendinosis from degenerative changes it has 82% sensitivity and 85% specificity. In picking up a rotator cuff tear and labral tears MR has a sensitivity and specificity of 90% and 98%, 55% and 100% respectfully. This compares quite well with surgical findings.

Plain MR has sensitivity and specificity as high as 98% and 89% respectively⁽²⁶⁾. However, an addition of contrast to the joint followed by MRA increases the sensitivity and enhances the accuracy offered by conventional MR imaging⁽²⁷⁾.

MR Arthrogram obtained using gadoteridol and those obtained using Ringers solution provided equivalent diagnostic accuracy⁽²⁸⁾. MR imaging of the shoulder gives the orthopedic surgeons the confidence in decision making. It has a major effect on diagnostic thinking and therapeutic decisions by orthopedic surgeons⁽¹⁹⁾.

Thus MRI is an excellent reliable imaging tool for shoulder pathology. Its accuracy has lead to improvement in management of the shoulder pathology. It is the imaging modality of choice in characterizing the various disorders and evaluating the extent of osseous, chondral and soft tissue involvement⁽²⁹⁾.

STUDY OBJECTIVE.

The objective of this study was to establish the MR findings among patients referred for MRI examination of the shoulder in three imaging centers in Nairobi.

1) Broad objective: To determine the pattern of MRI findings in patients presenting with shoulder pain.

2) Specific objective.

The specific objectives of this study was

1. To determine the causes of shoulder pain in those patients referred for MRI of the shoulder in three main imaging centres in Nairobi.
2. To determine the pattern of different shoulder pathology as seen at MR imaging.
3. To determine the correlation between the patients socio-demographic factors and the shoulder pathology at MR imaging.

STUDY JUSTIFICATION.

Since the introduction of MR in the imaging field in 1980's, it has emerged as an excellent imaging modality especially in the musculoskeletal system and central nervous system. Shoulder pain is a common cause of morbidity among the productive age group in our country and proper management relies heavily on accurate imaging. An accurate diagnosis will aid in proper management and in differentiating lesions which require surgical intervention from those requiring conservative management. Through MR imaging, a prognostic outcome of intervention can be predicted and this allows the surgeon to prepare the patient psychologically. No data are available about our local population on shoulder pain and MRI findings despite having an MRI machine in our country since 1996. No study has been done in our country to assess the pattern of findings in this new imaging modality among patients with shoulder pain in our local set-up. A statistical data is necessary as a baseline for future reference. The aim of this study is to provide a data base which can be used for future reference. This will improve the patients' management and health care planning nationally.

ETHICAL CONSIDERATION

Before the commencement of this study, the research proposal was submitted to the Kenyatta National hospital Ethical and Research Committee and a written approval was obtained. The copies of the approval letter were submitted to the collaborating imaging centers. Plaza Imaging Solution gave a verbal approval. Nairobi Hospital gave both verbal and a written approval. The patients name was not included in the data collection form neither are they included on the representative images. For identification purposes, only the patient's number was used. No extra investigation other than that requested by the referring clinician was performed. All this was explained to the patient during signing of the consent (Appendix B). The contact between the patient and the researcher was limited to the time of consent signing. Filling of the data form was done at the radiology reporting desk.

The results of this study will be forwarded to Kenyatta National hospital Ethical and Research Committee to assist them form a database for future reference and facilitate any possible improvement in patients care. Copies will also be forwarded to the collaborating institutions.

STUDY METHODOLOGY.

Study area:

This study was carried out in three main imaging centers in Nairobi.

1. Two major hospitals: Kenyatta National Hospital a regional referral centre and Nairobi hospital a private hospital.
2. Plaza Imaging solutions, a private imaging centre.

Study population. The study included all patients presenting with shoulder pain and referred for MR imaging by their primary physician in these imaging centers during the study period.

Study design. A prospective cross sectional descriptive study.

Sample size determination. The population consisted of patients referred for MR imaging of the shoulder at Kenyatta National hospital, Nairobi Hospital and Plaza Imaging Solutions, between June 2008 and December 2008.

The sample size was determined by the following formula by Fischer et al (1998)

$$n = \frac{z^2 p(1-p)}{d^2}$$

d². When this formula was applied at $d = 0.05$, $z = 1.96$, and $p = 6.9\%$ ⁽⁶⁾, then $n = 69$ shoulders. This figure was regarded as the minimum and was exceeded during the study duration. The actual figure of patients studied was 70. Two patients had both shoulders imaged and thus a total of 72 shoulders were imaged.

Inclusion and exclusion criteria.

Patients of all age groups with shoulder pain and referred for MR Imaging during the period between June 2008 and December 2008 were included in the study.

Those patients who declined to participate in the study or were extremely claustrophobic were excluded from the study. Only one patient declined the examination citing an unpleasant experience previously. None of the patients had a pacemaker or ferromagnetic foreign body which would have automatically excluded them from MR Imaging.

Materials and Study Procedure.

After obtaining a written consent from each patient the following protocol was used.

All the patients were scanned using a 1.5 Tesla MRI machine using a dedicated shoulder coil.

At Nairobi Hospital, a 1.5 Tesla Acheiva Philips MRI machine was used.

At both Kenyatta and Plaza Imaging Solutions, a 1.5 Tesla Intera Philips MRI machine was used.

The scanning was done in standard orthogonal planes axial, coronal, oblique coronal, Sagittal and oblique Sagittal.

T₁W, T₂W, T₁W with fat suppression, PDW and FLAIR MR Sequences were used.

In suspected labral tears, fat saturated gradient echo sequence was used.

Intravenous Gadolinium based contrast media was used depending on the clinical suspicion and findings on the non contrast images. No intraarticular contrast was used.

Data management.

All the data was recorded on a separate data collection sheet (appendix A). The data was analyzed using Statistical Package for Social Scientists (**SPSS-Version 13.0**) with the help of a biostatistician. The continuous variables were analyzed using measures of central tendency and presented as pie charts, bar graphs and tables. Where correlations for example between the age and the incidence of rotator cuff tears, the Chi-square test and p-values were used to test for association. Some of the commonest lesions will be discussed.

Study limitation.

Due to high cost of MR Imaging and the fact that shoulder pathology is more prevalent in people of low socio-economic status⁽⁸⁾, this study might have excluded majority of these patients.

A break down of the MR machine at one centre was a real inconvenience during the study period.

Results.

The total number of patients imaged was 70. Among them, 12(16.7%) were imaged at Plaza Imaging Solutions, 13(18.0%) were imaged at KNH and 47(65.3%) were imaged at Nairobi hospital. Two male patients had both shoulders imaged. MR imaging of 72 shoulders was done at the three imaging centers between June 2008 and December 2008.

Table 1: showing age distribution (n=70).

Factor	Frequency	Percentage
Age in years		
• < 30	9	12.9
• 30 – 45	17	24.3
• 46 – 60	32	45.7
• 60 +	12	17.1

Figure 1: showing sex distribution of patients from the three imaging centres (n=70).

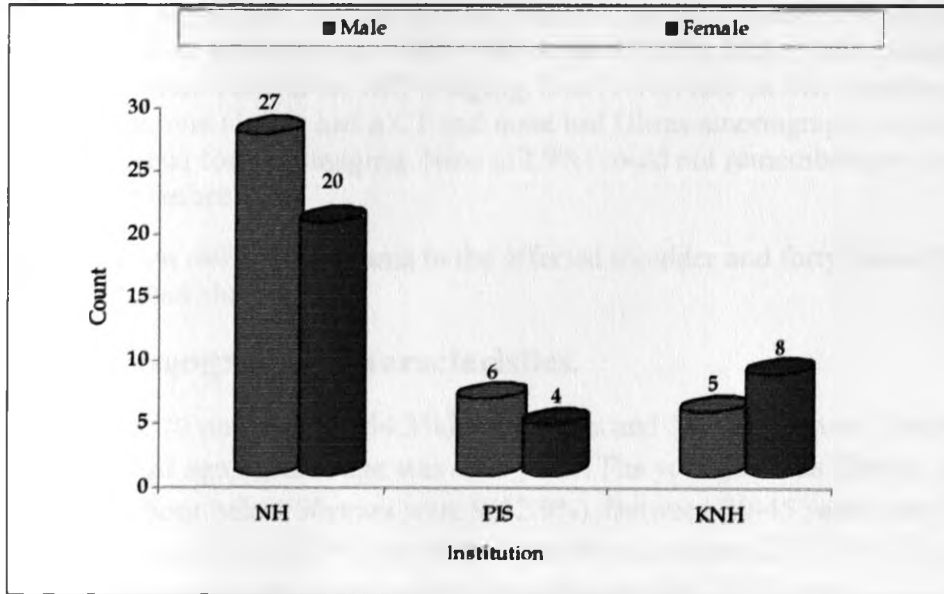


Table 2: showing distribution of referred patients (n=70).

Referring Clinician	Frequency	Percent
Orthopedic Surgeons	49	70.0
General Surgeons	8	11.4
General Practitioners	7	10.0
Others	6	8.6
Total	70	100.0

Majority of the patients were referred by orthopedic surgeons.

Others included a gastroenterologist who referred 2 patients, a radio-oncologist referred 1 patient and there were 4 self referrals.

Abnormality was detected in 71 shoulders. Only 1 shoulder had normal findings.

Previous imaging and trauma.

This information was obtained directly from the patient because few clinicians had provided this information on the requisition form. Fifty eight (83.0%) had a plain radiograph of the affected shoulder before referral for MR imaging. One (1.4%) had an MR scanning, one (1.4%) had arthrogram, one (1.4%) had a CT and none had Ultrasounonography of the affected shoulder before referral for MR imaging. Nine (12.9%) could not remember the type of examination they were done before.

Twenty eight (40%) had trauma to the affected shoulder and forty two (60%) reported no trauma to the affected shoulder.

Socio-demographic Characteristics.

Among the 70 patients, 38 (54.3%) were males and 32(45.7%) were females. The mean age was 48.0 years of age, median age was 48.0 years. The youngest was 20years and the oldest was 86years. Those below 30years were 9(12.9%). Between 30-45 years were 17(24.3%). Between 46-60years were 32 (45.7%) and those over 60 years were 12(17.1%). The age for the females ranged between 22-86 years and for the males between 20-76years.

Thirty (42.9%) had occupation involving manual work. Twenty five (35.7%) were involved in office work. Eight (11.4%) were business persons and seven (10.0%) were students.

TYPES OF LESIONS SEEN AT MR IMAGING.

A total of 120 lesions were seen and was more common on the right shoulder 104(86.7) compared to the left which had only 16(13.3) lesions. There was multiplicity of lesions in this study.

Table 3: Type of Lesions seen at MRI (n = 120).

Lesion	Right Shoulder	Left Shoulder	Total %
Tendinitis	31 (25.8)	3 (2.5)	34 (28.3)
Bursitis	11 (9.7)	1 (0.8)	12 (10.0)
Synovitis	0	2 (1.7)	2 (1.7)
Rotator Cuff Tears	19 (15.3)	1 (0.8)	20 (16.7)
Impingement Syndrome	5 (4.2)	0	5 (4.2)
Bankarts	3 (2.5)	1 (0.8)	4 (3.3)
Hill-Sachs	7 (5.8)	0	7 (5.8)
Fractures	4 (3.3)	0	4 (3.3)
Dislocations	2 (1.7)	0	2 (1.7)
Joint Effusion	3 (2.5)	6 (5.0)	9 (7.5)
Degenerative Diseases	13 (10.3)	0	13 (10.3)
Septic Arthritis	1 (0.8)	0	1 (0.8)
Benign Tumours	3 (2.5)	1 (0.8)	4 (3.3)
Malignant Tumours	1 (0.8)	1 (0.8)	2 (1.7)
Metastatic Tumours	1 (0.8)	0	1 (0.8)
TOTAL	104 (86.7)	16 (13.3)	120 (100)

Tendinosis:

Thirty four (28.3%) of this lesion were seen.

Table 4: Showing the distribution of Tendinosis (n=120).

Lesion	Frequency	Per cent
Tendinosis		
• Supraspinatus	21	17.5
• Biceps	11	9.2
• Subscapularis	2	1.67

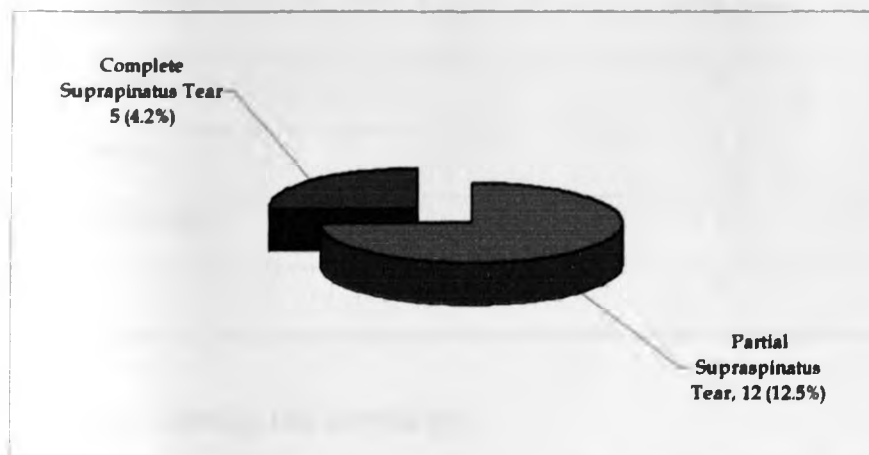
Table 5: showing distribution of tendinosis among age groups (n=120).

Age (yrs)	No of Lesions	Percent
<30	5	4.2
30-45	9	7.5
46-60	16	13.3
>60	4	3.3

Rotator cuff tears:

There were 20 (16.7%) of rotator cuff tears seen. Nineteen (15.8%) of the lesions were seen on the right and one (0.8%) lesion was seen on the left. All the rotator cuff tears were seen among those over 30years. Among the twenty tears seen, fifteen were partial and 5 were complete tears.

Figure 2: Distribution of supraspinatus tear (n = 120).



Degenerative Diseases:

13 (10.8%) of these lesions were seen and was exclusively seen on the right shoulder. This pathology was seen only in those over 30years.

Table 6: Showing association between degenerative diseases and other pathology.

Other Pathology	Degenerative, n	p-value
Tendinosis	5	0.485
Bursitis	2	0.891
Tendon Tears	4	0.790
Impingement syndrome	1	0.907
Bankart lesions	1	0.710
Hill-Sachs lesions	3	0.073

Bursitis:

Twelve 12 (10.0%) of these lesions were seen. Eleven (9.7%) were on the right and only one (0.8%) was seen on the left.

Joint Effusion:

Overall, 9 (7.5%) of this lesion was identified. There were 6 (5.0%) of the lesions on the left and 3 (2.5%) on the right.

Table 7: showing association between joint effusion and other pathology.

Other Pathology	Joint Effusion, n	p-value
Tendinosis	6	0.212
Tendon Tears	3	0.691
Bankart lesion	1	0.437
Hill-Sachs lesion	1	0.880
Fracture	2	0.020

Lesions involving the cartilage:

These are the Bankart and Hill-Sachs lesion. Eleven (9.2%) of these lesions were identified in this study. Four (3.3%) Bankart lesions were seen. Three were on the right and one was on the left shoulder. Seven (5.8%) Hill-Sachs lesions seen in this study and all were on the right shoulder. These lesions were seen only in those over 30years.

Fracture and dislocations:

Six (5.0%) of these lesions were seen in this study. Four (3.3%) were fractures and two (1.6%) were dislocations. All were in the right shoulder and were anterior dislocations. One case of recurrent dislocation was associated with a bony bankart lesion.

Benign Tumours:

A total of 4(3.3%) of benign tumors were seen in this study. Three (2.5%) were on the right shoulder and 1(0.8%) was on the left shoulder.

Table 8: showing types of Benign tumors (n=120)

Benign Tumours		
• Intramuscular cysts	2	1.6
• Labral cyst	1	0.8
• Humeral cyst	1	0.8

Table 9: Other types of Lesions seen at MRI (n= 120).

Lesion	Right Shoulder	Left Shoulder	Total
Septic Arthritis	1 (0.8%)	0	1 (0.8%)
Malignant Tumours	1 (0.8%)	1 (0.8%)	2 (1.6%)
Metastatic Tumours	1 (0.8%)	0	1 (0.8%)

ILLUSTRATIONS

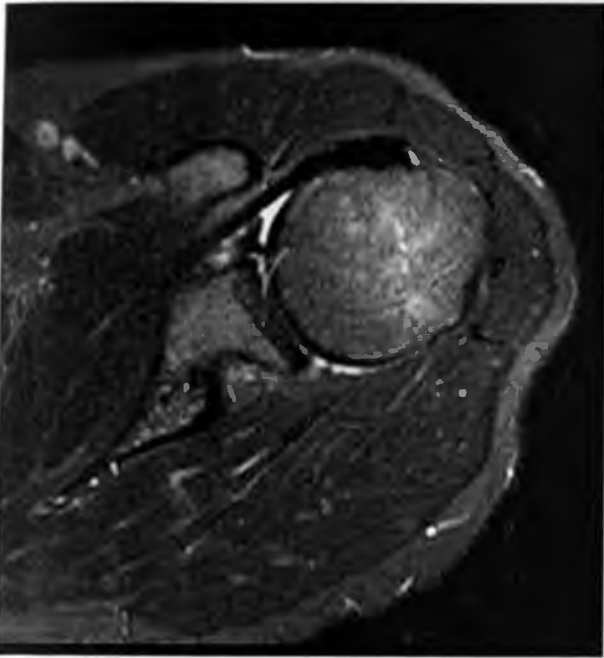

Image 1a. MR image of the left shoulder of a 28-year-old student who was referred by an orthopedic surgeon. He had recurrent shoulder dislocation. Image (a) an axial T₂WI shows a bankart bony lesion.

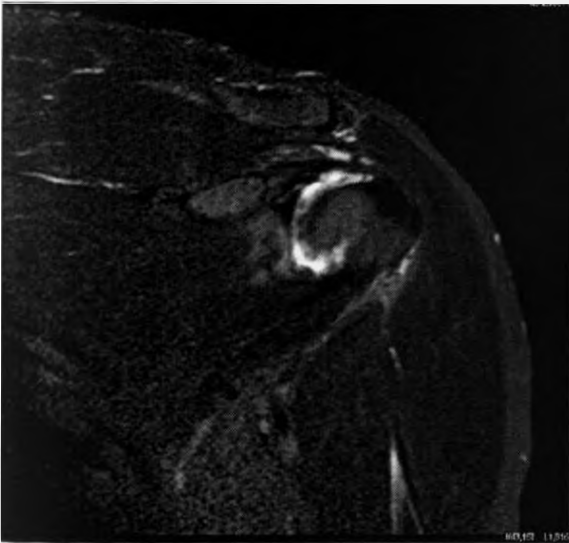


Image 1b. A T₂W fat suppressed coronal image of the same patient as above showing marked joint effusion. The rotator cuff tendon shows a hyperintense signal and a gap on this sequence, findings consistent with complete tear of the rotator cuff tendon.

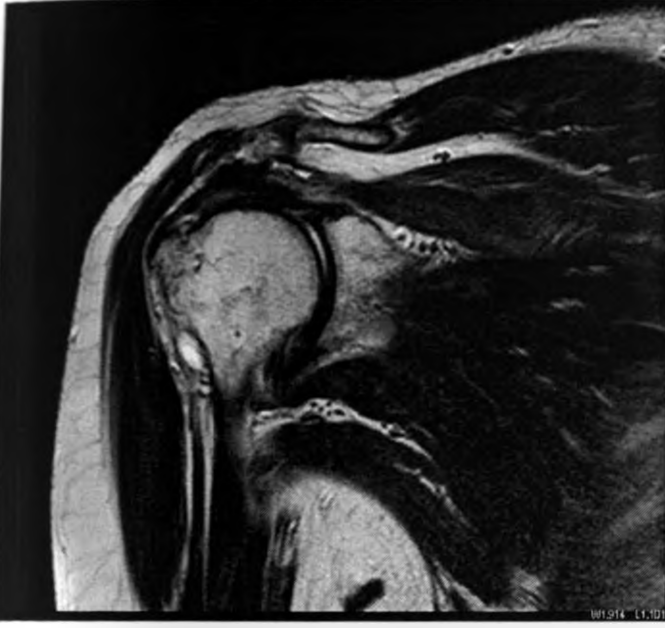

Image 2a. Coronal T₂W Image of a 43 year old female referred by an orthopedic surgeon. She had recurrent right shoulder pain. There is an inhomogeneous hyperintense signal in the supraspinatus tendon.

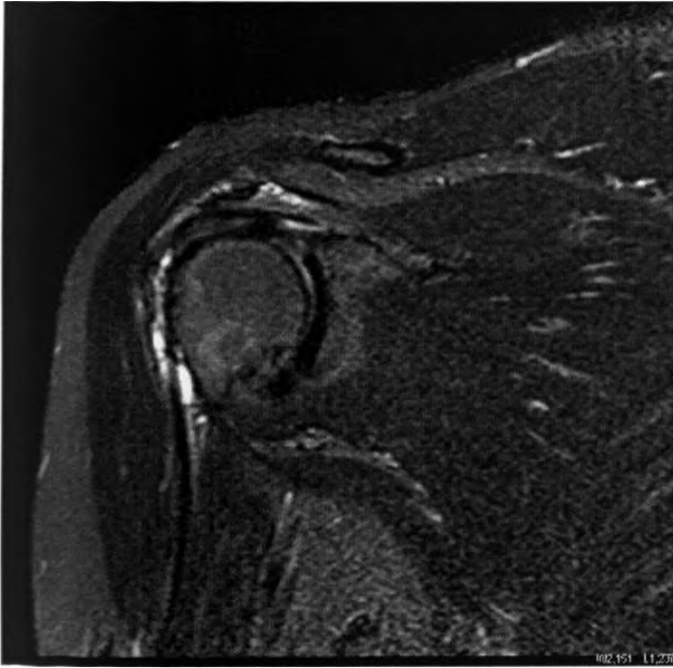


Image 2b. T₂W fat suppressed image of the same patient. The hyperintense signal in the supraspinatus tendon is more apparent. MR diagnosis of supraspinatus tendinosis was made.

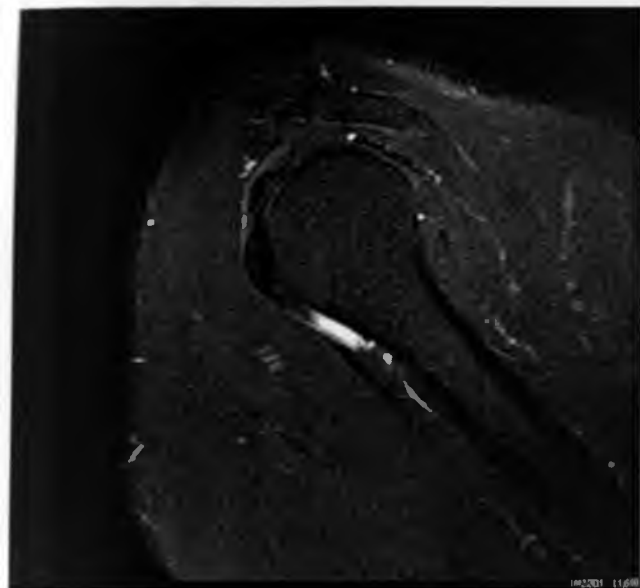


Image 3b. A coronal oblique T₂W Fat suppressed image of a 54 year old referred by orthopedic surgeon with persistent painful right shoulder. There is hyperintense signal in the biceps tendon.

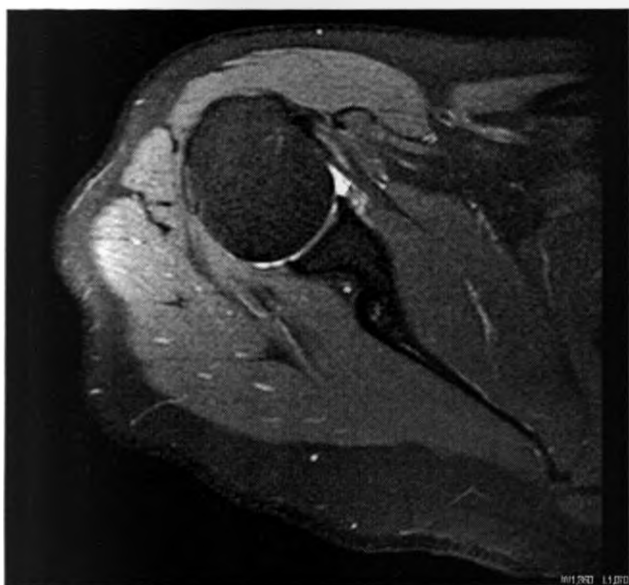


Image 3b. A PD axial image from the same patient as above. High signal intensity is noted in the rotator cuff. MR diagnosis of biceps tendinosis and partial rotator cuff tear was made.

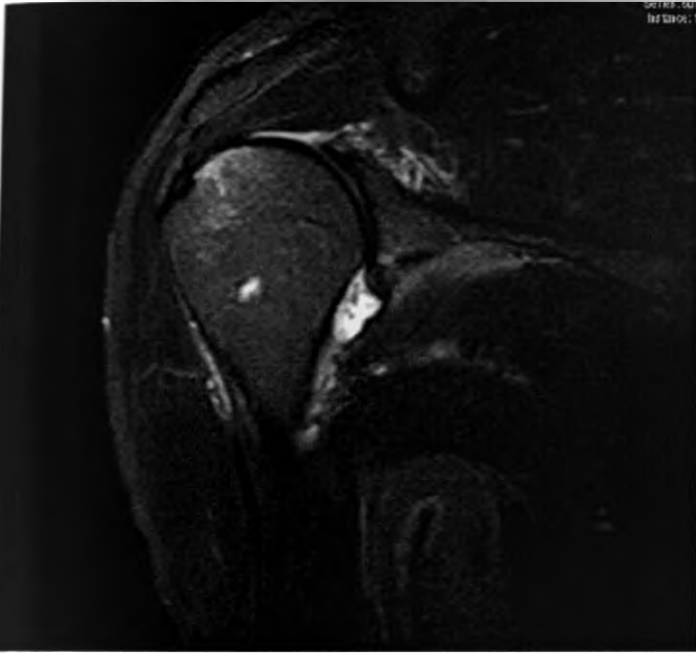


Image 4a. Coronal T₂W fat suppressed image of a 39year old man with painful swollen right shoulder. There is hyperintense inhomogeneous signal intensity at myotendinous junction. An effusion is seen.

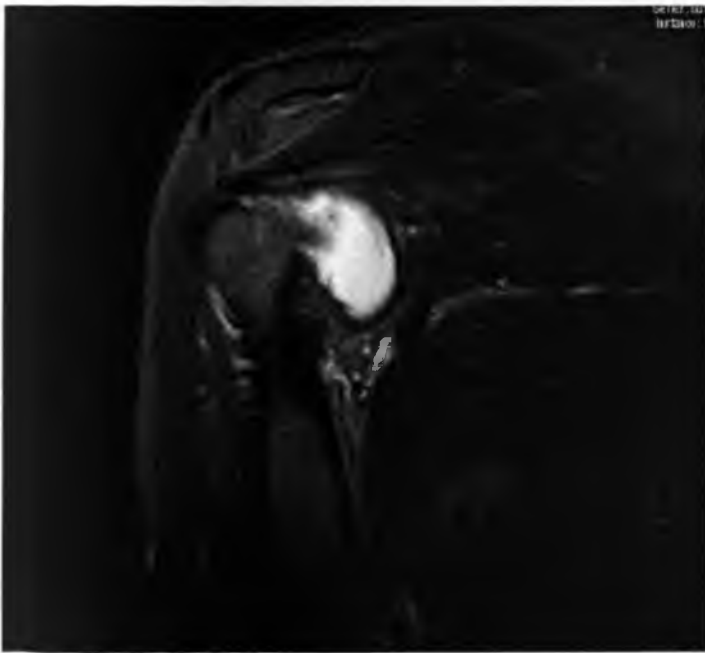

Image 4b. A more posterior scan slice showing marked effusion. A MR diagnosis of rotator cuff tendinosis with joint effusion was made.

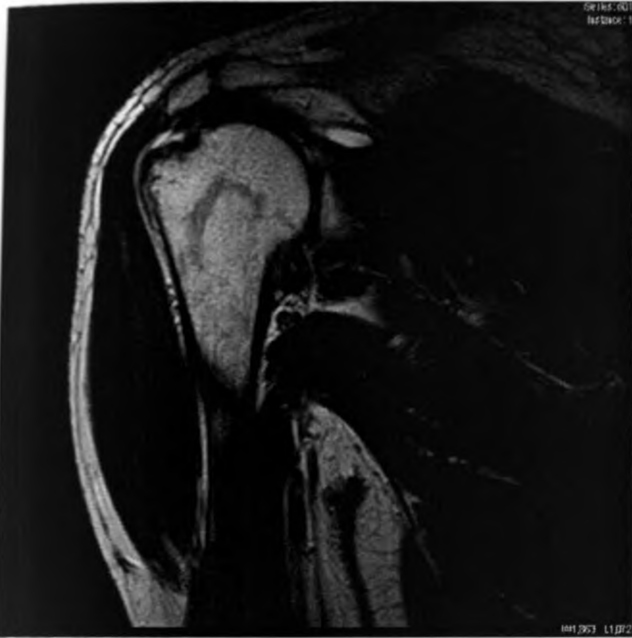

Image 5a. Coronal T₂WI of a 30year old man referred by an orthopedic surgeon with right shoulder pain. High signal intensity on the rotator cuff is seen. A cyst is seen at the myotendinous junction.

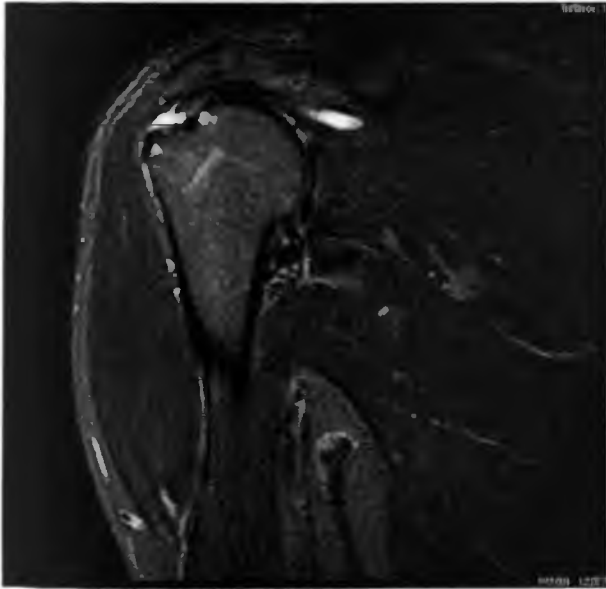

Image 5b. T₂W fat suppressed image of the same man. The signal intensity of the rotator cuff is noted. A cyst is seen at the myotendinous junction. MRI diagnosis of complete rotator cuff tear with intramuscular cyst was made.

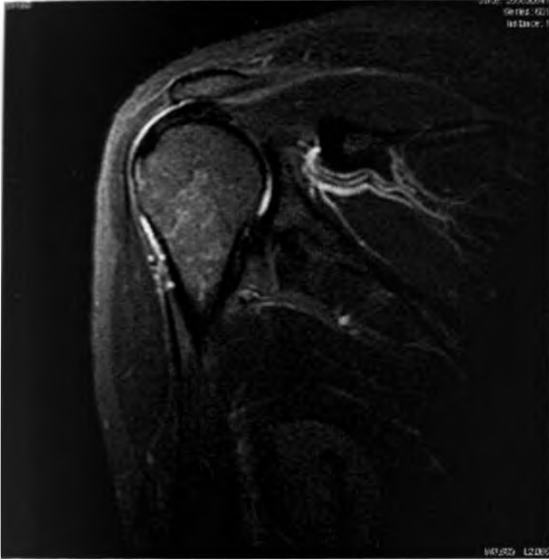

Image 6a. T₂W fat suppressed coronal image of a 50year woman with chronic right shoulder pain. The rotator cuff tendon is thickened and there are multiple intratendon focal low signal areas. Peritendon fluid is also seen.

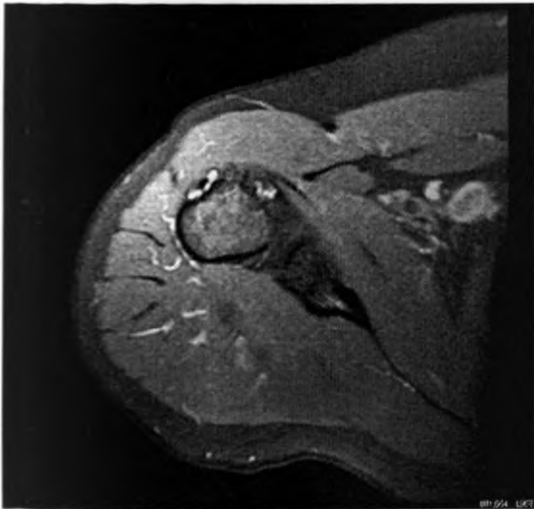

Image 6b. PD axial image of the same woman. There are multiple focal intratendon low signal areas. MR diagnosis of calcific tendinosis was made.

DISCUSSION

Demographic characteristics

In this study, a total of 70 patients were scanned. 38 (54.3%) were males and 32(45.7%) were females. The mean age was 48.0 years. The youngest was 20years and the oldest was 86years. Those between 30-45 years were 17(24.3%). Between 46-60years were 32 (45.7%) and those over 60 years were 12(17.1%).

There is a discrepancy in this study as compared to other studies. **Bongers**, in a study found that women have more self reported incidence of shoulder pain⁽¹⁾. In a community survey of identifiable symptomatic shoulder disorders in a sample of 644 people over age 70years. **Chard et al** found that shoulder disorders were more common in women (25%, versus 17% in men)⁽³⁴⁾.

In this study, the male patients were more than the females. The majority of the patients in this study were from a private hospital. A total of 70 patients were imaged and 38(54.3%) were males and 32(45.7%) were females. Those from NH a private hospital were 46 (66%), among them, 27 were males and 20 were females. PIS a private imaging centre had 11(16%) patient and among them 6 were males and 4 were females. KNH a public hospital had 13(18.9%) of which 5 were males and 8 were females. The private centers had more males than females. This could be due to the fact that the private centres attend to the population of high socio-economic status. KNH a public hospital had more females than males. The probable explanation for this is KNH, a public Hospital attended to people of mixed socio-economic background. Thus the study group from KNH may be a true representative of the general population.

Mitchell et al, in their study found that shoulder disorders were more common in lower socio-economic population and certain occupations involving physical work such construction are associated with an increase in shoulder disorder⁽⁴⁾. In this study the majority 30(42.9%) had occupations involving manual work. This number may be higher if we consider multiplicity of occupations where you may find banker doubling as a farmer during his free time which is common in our society. Since majority of our population is of lower socio-economic status, the prevalence of shoulder pathology is expected to be probably even higher than the western population. This study has not addressed this issue. Thus another study is needed to address this issue.

In conclusion, the findings in this study socio-demographic factor differ from other studies. My postulation for this is our socio-economic status and the biased sample population. The sample population in this study is not a true representative of the general population. This may explain the discrepancy in the sex distribution in the study.

Lesions seen at MR Imaging.

In this study a total of 120 lesions were seen. The commonest pathology was tendinosis. Thirty four (28.3%) of this lesion were seen and were more on the right shoulder which had thirty one (25.8%) lesions compared to the left with only three (2.5%) lesions. Tendinosis involved mainly the supraspinatus tendon. Twenty one (17.5%) lesions were seen on the supraspinatus, twelve (10.0%) were on the biceps tendon and the subscapularis tendon had 2 (1.6%) lesions. The rotator cuff tears were the 2nd most encountered lesion 20 (16.7%). This lesion was also seen mostly on the right shoulder. Nineteen (15.8%) lesions were seen on the right compared to the left which had only one (0.8%) lesion.

A study by **Krief and Huguet**, involving 1079 patients found that 916 (85%) had right hand dominance and 163 (15%) were left handed. Among them, 669 (62%) presented with pain on the right shoulder⁽¹⁰⁾. Thus majority of the population are right-handed thus disability related to right shoulder pathology would affect a relatively bigger proportion of the general population. This study compares well with western studies which have shown the right shoulder is more affected due to right handedness.

TENDINOSIS.

In this study, this was the commonest lesion seen. It accounted for 34 (28.3%) of the total lesions seen. Thirty one (25.8%) were on the right shoulder and three (2.5%) were in the left shoulder. The supraspinatus was the most involved tendon with 23 (19.2%) of the total lesions. This accounted for 67.4% of the tendinosis. Biceps had 12 (10.0%) of the total lesions accounting for 35.3% of the tendinosis and subscapularis had 2 (2.8%) of the total lesion translating to 5.9% of tendinosis. This lesion appeared as an inhomogeneous increase in intratendon signal intensity and thickened tendon on MR imaging.

Mya Lay Sein et al, using MRI graded supraspinatus tendinosis into 4 categories⁽²⁴⁾.

Grade 0: Normal.

Grade 1: Mild tendinosis

Grade 2: Moderate tendinosis.

Grade 3: Marked tendinosis

However, this grading was not done in this study. Calcific tendinosis results from deposition of calcium in or around the tendon. In this study it was seen in four shoulders. Though the pathogenesis of this condition is still debatable,⁽³⁵⁾ it was grouped together with tendinosis in this study. The MR imaging finding in this condition was low foci of intratendon or peritendinous low signal on T1W and T2W sequences.

C.W Vick et al, in their study found that tendinosis mainly affected the supraspinatus tendon. This is because of its proximity to the coracoacromial arch and poorer blood supply. This condition is more common in women than in men and usually occurs between the ages of 35 and 50 years⁽¹²⁾. In this study, out of the 34 tendinosis lesion seen, five were in those under 30 years, between 30-45 years had nine lesions. Those between 46-60 years had sixteen lesions and they

were seen in four cases among those over 60 years. Tendinosis was more common among those aged between 46-60 years with 16(13.30%) cases in this study.

In conclusion, tendinosis affected the right shoulder and was more common among those aged between 46-60 years. The supraspinatus tendon was the commonest affected tendon in this study. This correlates well with western studies.

Rotator cuff tears:

A rotator cuff tear was the third most encountered lesion in this study. It consisted of twenty (16.7%) of the total lesions seen in this study. Nineteen (95.0%) of the total rotator cuff tears were on the right shoulder and only one (5.0%) was on the left shoulder. Fifteen (75.0%) of the total were partial tears and five (25%) were complete tears. Tears involving the supraspinatus tendon were a total of 17(85.0%) and among these, 12(70.6%) were partial and 5(29.4%) were complete tears. In Western literature, subscapularis almost always occurs exclusively in association with supraspinatus tear⁽³⁸⁾. In this study, 2 cases of subscapularis tear were seen. Isolated subscapularis tear was seen in one shoulder while in the second case, there was an associated supraspinatus tear. There was no obvious explanation for this.

The causes of rotator cuff tears are multifactorial with both the intrinsic and extrinsic factors playing a role but in this type of injury, the supraspinatus tendon is involved in most of the cases. Radiographic findings are usually normal in the acute setting but MR imaging can pick these changes with a sensitivity and specificity ranging from 84% to 100% and 93% to 99% respectively^(37, 15).

The MR findings of tendon tear were increase in signal on all sequences carried out but its appearance on T₂ sequence was more specific. A Partial thickness tear manifested as a focal hyperintense signal. The retraction of the tendon was seen as a gap extending between the two tendon ends and its size is accurately measurable at MRI. This is important for preoperative planning. However, in this study, the size and shape of the tear was not documented.

Sher et al in their study of asymptomatic individuals found that the overall prevalence of tears of the rotator cuff in all age-groups was 34% and the frequency of full-thickness and partial thickness tears increased significantly with age. The increased prevalence of abnormal MRI findings consistent with rotator cuff tear in asymptomatic individuals were compatible with painless normal function and were more prevalent in individual who are over 60 years old.⁽³²⁾ Thus a potential hazard of using MRI as a basis for operation without associated clinical abnormality exists. This was not an issue in this study as all the patients were symptomatic but the surgeons should be aware of this.

SF Quinn et al, in their study evaluated one hundred symptomatic patients. They underwent both MR imaging and arthroscopy of the shoulder. They combined data for complete and partial tears of the rotator cuff. They found that MR imaging had an accuracy of 93%; sensitivity, 84%; and specificity, 97%. Seventeen of 20 complete tears and nine of 11 partial tears were properly identified with MR imaging. Two partial tears were not detected and three complete tears were incorrectly called partial tears at MR imaging. Of the two false-positive MR imaging findings, one was called a complete tear and the other, a partial tear. Fat-suppressed MR imaging has high

diagnostic accuracy in evaluating tears of the rotator cuff tendon⁽⁴⁰⁾.

Gagey N et al examined 38 symptomatic patients by MRI and then operated for a rotator cuff syndrome. They found that the correlation between the description of the cuff lesions after MRI and the surgical observations were excellent for 37 patients. In one case MRI showed a false image of tear of the supraspinatus tendon on its anterior edge. The results showed that MRI is very sensitive (0.93) and specific (0.94) for the diagnosis of rotator cuff tears.

These two studies emphasize on the high sensitivity and specificity in picking rotator cuff lesions on MR imaging. This study does not address the issue of sensitivity and specificity of MRI. Thus more studies are required to address this issue and the pick up rate of rotator cuff tears at MRI and intraoperative findings.

Lesions involving the cartilage.

These lesions involve the cartilaginous part of the glenohumeral joint. They are the Bankart and Hill-Sachs's defect. There are various subtypes of these defects. In this study, a total of 11(9.2%) of these lesions were seen. There were 4(3.3%) Bankart lesions and 3 (2.5%) were on the right shoulder and 1 was seen in the left shoulder. Seven(5.8%). Hill-Sachs lesions were seen and all were on the right shoulder. These lesions are common in those with dislocation of shoulder joint. One case of recurrent shoulder dislocation was associated with a Bankart lesion.

Parmar et al, in their study compared MR Arthrogram and Arthroscopic findings of Twenty two males patients aged 16 to 50 years with shoulder instability. They found that MRA had a sensitivity of 95% and a specificity of 100% for the detection of the antero-inferior labral tears. Sensitivity was less for superior and posterior labral tears being 60% and 50% respectively. The sensitivity of MRA for the detection of superior, middle and inferior glenohumeral ligament tear was 83%, 80% and 86% with a specificity of 100%, 71% and 93%, respectively. MRA was 100% sensitive for the detection of the rotator cuff injuries and detection of bony lesions like Hill-Sachs's and bony Bankart lesions⁽¹⁸⁾.

Thomas Magee, in his study involving one hundred and fifty symptomatic patients. They underwent conventional MRI, MRA on 3Tesla MR machine and then Arthroscopy. He found three full-thickness and nine partial-thickness supraspinatus tendon tears, seven SLAP tears, six anterior labral tears, and two posterior labral tears on MRA which had not been picked at conventional MRI. On conventional MRI, sensitivities and specificities compared with arthroscopy for anterior labral tear was 83% sensitive and 100% specific; posterior labral tear, 84% and 100%; SLAP tear, 83% and 99% respectively. On MRA, sensitivity and specificity compared with arthroscopy was anterior labral tear, 98% sensitive and 100% specific; posterior labral tear, 95% and 100%; SLAP tear, 98% and 99% respectively. Thus MRA showed a statistical improvement in sensitivity ($p < 0.05$) in anterior labral tears, and SLAP tears. MRA showed statistically significant increased sensitivity for detection of partial-thickness articular surface supraspinatus tears, anterior labral tears, and SLAP tears compared with conventional MRI at 3 Tesla⁽⁴²⁾.

Christoph A. Binkert et al, in a study involving 156 MRA used Gadoteridol and Ringers solution and compared the diagnostic accuracy. They found that MRA using Gadoteridol and those using Ringers solution provided equivalent diagnostic accuracy.

All the above studies emphasize the use of MRA to increase pick rate of labral tears. In this study there was no use of intrarticular contrast. Probably with intraarticular contrast, more lesions would have been picked. This calls for more studies to compare the pick up rate of shoulder lesions on conventional MR and MRA. This will aid in developing the appropriate protocol for shoulder imaging in our set up. Though Gadolinium based contrast media are expensive, use of Ringers solution might be an alternative but there is need for further evaluation in our setting. This will make MRA less expensive.

Degenerative Diseases

Thirteen (10.8) of total lesion were degenerative disease. All were seen on the right shoulder. Glenohumeral osteoarthritis is usually secondary to trauma or other disorders such as calcium pyrophosphate or hydroxyapatite crystal deposition, haemophilia, acromegaly, epiphyseal dysplasia and alkaptonuria. Association between osteoarthritis of the glenohumeral joint, rotator cuff diseases and the subacromial impingement syndrome has been documented. Rotator cuff lesions are highly associated with osteoarthritis. **Kernwein**, in his study found rotator cuff tear in over 90% of shoulders with osteoarthritis at arthroscopy⁽³¹⁾. In a study done by **Perteson et al**, they found evidence of rotator cuff tear in 75% of shoulders at autopsy⁽³⁸⁾. These studies show a high association of glenohumeral osteoarthritis and other pathology. In this study among those who had osteoarthritis 5 had tendinosis, 4 had tendon tears, 2 had bursitis and one had a bankart lesion. Thus there is an increase in association with other pathology in those with degenerative shoulder disease.

In conclusion characterizing osteoarthritis at imaging is important since it may simulate other lesion or their symptoms may overlap and failure to pick them will delay the appropriate management.

Joint Effusion.

Effusion in the glenohumeral cavity was encountered in 9 (7.5%) of the cases. In the right shoulder, it was seen in 3 (2.5%) cases and 6(5.0%) on the left. The presence of an effusion was associated with other lesions. It was associated with tendinosis in 6 cases (p-value of 0.212), in tendon tear was seen in 3 cases and in fractures it was seen in 2 cases (p-value of 0.020). It was found in labral tears in 2 cases. This is a non specific finding and its finding requires meticulous investigation to find out the specific pathology. It showed a low signal intensity on T1WI and high signal intensity on T2WI.

One case of septic arthritis which was seen on the right had similar MR Imaging finding on non enhanced images. Septic arthritis on MRI abnormalities can be detected as early as 24hrs as joint effusion, perisynovial edema and synovial thickening. Non septic arthritis of shoulder joint is a fairly commonly encountered entity in clinical practice and poses a diagnostic challenge. The clinical signs and symptoms can overlap those of articular and extraarticular disorders. Diffusion weighted MRI has been tried to separate the two entities with success⁽³⁰⁾. Pyogenic effusion will

appear dark on ADC map while reactive effusion will be bright on diffusion weighted imaging but this protocol was not used in this study.

Tumours.

Seven (5.8%) neoplasm were seen in this study. Four (3.3%) were benign and all were cysts seen in the labrum, humerus and supraspinatus muscle. Two were malignant a fibrosarcoma and a chondrosarcoma. This was a pathological diagnosis from the referring clinician.

One metastatic tumor was seen in a male patient proved to have cancer of prostate.

In this study, the benign tumors were a coincidental finding.

Normal MRI findings

This was seen in one female patient case. The patient had mastectomy due to ductal cancer of the left breast. The pain was on the left shoulder. This most likely was referred pain due to previous surgery within structures around the left shoulder. Pathology in the structures around the shoulder may mimic shoulder pathology thus imaging plays an important role in delineating whether the source is in the shoulder joint.

Other lesions seen at MRI (n=120).

Lesion	Right Shoulder	Left Shoulder	Total
Bursitis	11 (9.2%)	1 (0.8%)	12 (10.0%)
Impingement Syndrome	5 (4.2%)	0	5 (4.2%)
Fractures	4 (3.3%)	0	4 (3.3%)
Dislocations	2 (1.6%)	0	2 (1.6%)

Conclusion

1. Since most of the shoulder lesions are from the soft tissues, MR imaging would be the appropriate imaging modality for those presenting with shoulder pain especially in non trauma set up. In this study, 58(80.6%) of the patients initially had plain radiographs but little was picked. After MRI, among the 72 shoulders imaged, 71 were found to have pathology. Majority of the lesions involved the soft tissues. This shows that MR is a superior imaging tool especially where soft tissue lesions are suspected. MRA would increase the pick rate of these lesions. Use of Ringers solution (normal saline) would be an alternative to Gadolinium based contrast media.
2. Males were affected more than females in this study. This is contrary to western literature where the females are more affected. This could be due to discrepancies in socio-demographic factors and biased sample population in this study.
3. Those with highest incident of shoulder pathology were aged between 46 and 60 years. The incidence of shoulder pathology increases with age and this explains why this age group had more lesions. The expectation is the over 60years to have more pathology but they were few in this study compared to the 46-60year age group.
4. The right shoulder is affected more among the patients seen at the three study centres.
5. Tendinosis was the commonest lesion seen among these patients. A total of 34 (28.3) of this lesion were seen and was more on the right shoulder with 31(25.8%) lesions compared to the left which had only 3 (2.5%) lesions. Tendinosis was seen more on the supraspinatus tendon. This compares well with findings from western world.
6. Twenty (16.7%) of rotator cuff tears were seen in this study and were on the right shoulder. Supraspinatus had most of the tears with 17(14.1%) of the lesions.
7. Degenerative disease was fairly common with 13(10.8%) lesions and was seen exclusively on the right shoulder. This condition was associated with other pathologies. Majority of the people have right hand dominance and this explains why the right shoulder is affected more than the left⁽¹⁰⁾.
8. Joint effusion was a non specific findings always associated with another lesion.

Recommendations

1. Further studies to investigate the prevalence of shoulder pain in our society are needed.
2. MRA studies are needed to accurately assess the cartilaginous lesions.
3. Diffusion weighted MR imaging should be used where doubts about the distinction between pyogenic and reactive effusion exists. However more correlative studies need to be carried out to ascertain its reliability.
4. A correlative study between MRI and operative findings is needed. This will help in assessing the accuracy of MR imaging and would give the surgeon additional confidence when a decision to operate has to be reached.
5. MR imaging characterization of these lesions is important. Grading of tendinosis and measuring the gap between the tear would help the surgeon in pre-operative planning and in counseling the patient on the expected outcome.

References:

1. Paulien M. Bongers; The cost of shoulder pain at work; *BMJ*; 2001;322:64-65
2. John C. Rosecrance and Thomas M. Cook. Upper Extremity Musculoskeletal Disorders: Occupational Association and a Model for Prevention. *CEJEOM*1998; 4(3)214-231.
3. Carlo Martinoli, Stefano Bianchi, Nicolò Prato et al. US of the Shoulder: Non-Rotator Cuff Disorders, *Radiographics*. 2003; 23:381-401.
4. Caroline Mitchell, Ade Adebajo, Elaine Hay et al. Shoulder pain: diagnosis and management in primary care; *BMJ*2005; 331:1124-1128.
5. D. Pope, P. Croft, C. Pritchard and et al. Prevalence of shoulder pain in the community: the influence of case definition. *Annals Of The Rheumatic Diseases* 1997 May 56(5) 308-312.
6. Luime J.J, Koes B.W, Hendriksen I.J.M et al, Prevalence and Incidence of shoulder pain in general population; a systemic review. *Scandinavian Journal of Rheumatology* 2004; 33:73-81.
7. Wim Grooten. Work and neck/shoulder pain. Risk and Prognostic Factors. Department Of Public Health Science, Division of Occupational Medicine Karolinska Institute, SE-171-76 Stockholm Sweden.
8. Michelle Urwin, Deborah Symmons, Timothy Allison et al, Estimating the burden of musculoskeletal disorders in the community: the comperative prevalence of symptoms at different anatomical sites, and relative to social deprivation. *Annals of the rheumatic diseases* 1998 57:649-655(November).
9. Tommy Hansen and Irene Jensen. Sickness absence due to back and neck disorders. *Scandinavian Journal of Public Health* 2004; 32(Suppl 63) 109-151.
10. Olivier P. Krief and Dominique Huguet. Shoulder pain and Disability: Comparison with MRI Findings. *AJR*2006; 186:1234-1239.
11. A.M Malhi and R. Khan. Correlation between clinical diagnosis and arthroscopic findings of the shoulder. *Postgraduate Medical journal*.2005; 81:657-659.
12. C.W Vick and S.A Bell. Rotator cuff tears: Diagnosis with sonography; *American journal of Roentgenology* Volume 154. 121-123.

13. VP Chandnani, JA Gagliardi, TG Murnane et al. Glenohumeral ligaments and shoulder capsular mechanism: evaluation with MR arthrography. *Radiology*, Vol 196, 27-32.
14. MC Nelson, GP Leather, RP Nirsch, Petrone MI Freedom. Evaluation of the painful shoulder. A prospective comparison of magnetic resonance imaging, computerized tomographic arthrography, ultrasonography, and operative findings. *The Journal of Bone and Joint Surgery*, 1991; Vol 73, Issue 5: 707-716.
15. JP Iannotti, MB Zlankin, JL Esterhai et al, Magnetic resonance imaging of shoulder. Sensitivity, specificity and predictive value. *The Journal of Bone and Joint Surgery*, volume 73, issue 1 17-29.
16. Michael B. Zlakin, Carry Hoffman, Frank G Shellock. Assessment of the rotator cuff and glenoid labrum using an extreme MR system: MR results compared to surgical findings from multi center study. *Journal of Magnetic Resonance* 2004; 19:623-631.
17. Frank G. Shellock, Jack M. Bent, Hollis M et al. Evaluation of rotator cuff and glenoid labrum using a 0.2 Tesla extremity magnetic resonance (MR) System. *Journal of Magnetic Resonance Imaging* 2001; 14:733-770.
18. Pharrmar H. Jhankaria B, Maheshwari M. Singrakhia M, Shanbag S. Chwala A et al, Magnetic Resonance Arthrography in Recurrent Anterior Shoulder Instability as Compared to Arthroscopy: A Prospective Comparative Study. *Journal of Postgraduate Medicine* 2002; 48:270-274.
19. Zanetti M, Jost B, Lustenberger A et al. Clinical impact of MR arthrography of the shoulder. *Acta Radiol*. 1999 May; 40(3):296-302.
20. Athanasios Papatheodorou, Panagiotis Ellinas, Fotios Takis et al. US of Shoulder; Rotator cuff and Non-Rotator cuff Disorders. *Radiographics*. 2006:e23
21. A.M Malhi and R. Khan. Correlation between clinical diagnosis and arthroscopic findings of the shoulder. *Postgraduate Medical journal*.2005; 81:657-659.
22. Andre Roy, Thierry HM Dahan, Manon Belair et al. Rotator Cuff Disease. <http://www.eMedicine.com/>.
23. C. Charousset, L. Bellaïche, L. D. Duranthon et al, Accuracy of CT arthrography in the assessment of tears of the rotator cuff. *Journal of Bone and Joint Surgery - British Volume*, Vol 87-B, Issue 6, 824-828.

24. Mya Lay Sein, Judie Walton, James Linklater et al, Reliability of MR in assessment of supraspinatus tendinopathy. *British Journal of sports medicine*. 2007; 41:e9.
25. MC Nelson, GP Leather, RP Nirsch et al, Evaluation of the painful shoulder. A prospective comparison of magnetic resonance imaging, computerized tomographic arthrography, ultrasonography and operative findings. *The Journal of Bone and Joint Surgery*, 1991; Vol 73, Issue 5: 707-716.
26. David A. Connell, Hollis G. Potter, Thomas L et al, *American Journal of Sports Medicine* 1999;27:208-213.
27. Flannigan B, Kursunoglu Brahme, Synder S et al, MR arthrography of the shoulder: comparison with conventional MR imaging, *AJR*. 1990; 155(4):829-32.
28. Christoph A. Binkert, Marco Zanetti, Christian Gerber et al, MR Arthrography of Glenohumeral Joint. Two Concentrations of Gadoteridol versus Ringers Solution as Intraarticular Contrast Material. *Radiology* 2001; 220:219-224.
29. Jaume Llauger, Jaume Palmer, Nüría Rosón et al, Nonseptic Monoarthritis: Imaging Features with Clinical and Histopathologic Correlation. *Radiographics*. 2000; 20:S263-S278.
30. Ji Kang Park, Bong Soo Kim, Gukmyung Choi et al, Distinction of Reactive Fluid From Pyogenic Abscess By Diffusion-Weighted Imaging. *Journal of Magnetic Resonance Imaging*. 2007; 25: 859-861.
31. Kernwein G.A. Roentgenographic diagnosis of shoulder dysfunction. *JAMA* 1965; 194:1081-1085.
32. Klaus Strobel, Juerg Hodler, Dominik C. Meyer et al, Fatty Atrophy of Supraspinatus and Infraspinatus Muscles: Accuracy of US. *Radiology* 2005; 237:584-589.
33. Erin E. O'Connor, Larry B. Dixon, Terrance Peabody et al, MRI of Cystic and Soft-Tissue Masses of the Shoulder Joint. *AJR* 2004; 183:39-47.
34. M. D. Chard, R. Hazleman, B. L. Hazleman et al, Shoulder disorders in the elderly: A community survey. *American college of rheumatism* 1990; Volume 34 Issue 6. Pages 766 – 769.
35. Curtis W. Hayes and William F. Conway, Calcium Hydroxyapatite Deposition Disease. *Radiographics* 1990; 10:1031-1048.
36. O'Connell PW, Nuber GW, Mileski RA et al. The contribution of glenohumeral ligaments to anterior stability of the shoulder joint. *Am J Sports Med* 18:579–584.

37. Josh B. Moosikasuwan, Theodore T. Miller, and Brian J. Burke. Rotator Cuff Tears: Clinical, Radiographic, and US Findings. *RadioGraphics* 2005; 25:1591-1607.
38. Peterson C.J. Degenerative disease of glenohumeral joint: an anatomical study. *ACTA Orthop Scand* 1983; 54:277-288.
39. Grainger RG, Allison D.J Eds. *Diagnostic Radiology, A Text book of Medical Imaging* 4th edition. London, Churchill Livingstone 2002.
40. SF Quinn, RC Sheley, TA Demlow et al, Rotator cuff tendon tears: evaluation with fat-suppressed MR imaging with arthroscopic correlation in 100 patients. *Radiology*, Vol 195, 497-500
41. Gagey N, Desmoineaux P, Gagey O et al, MRI in the pre-operative evaluation of lesions of the rotator cuff. *J Radiol*. 1993 Jan; 74(1):39-46.
42. Thomas Magee. 3-T MRI of the Shoulder: Is MR Arthrography Necessary? *AJR* 2009; 192:86-92.
43. Christoph A. Binkert, Marco Zanetti, Christian Gerber et al. MR Arthrography of Glenohumeral Joint. Two Concentrations of Gadoteridol versus Ringers Solution as Intraarticular Contrast Material. *Radiology* 2001; 220:219-224.

APPENDICES.

APPENDIX A: Data collection form.

Age (in years)

Sex Male Female

Date of examination / /

Occupation Self-employed (specify type).....

Employed (specify type).....

Unemployed

Referring clinician:

Orthopedic Surgeon.

General Surgeon.

General Practitioner.

Others (Specify).....

Institution

Kenyatta National Hospital

Plaza Imaging Solutions

Nairobi Hospital

Past medical history

Previous trauma	Right shoulder	Left shoulder
Yes No <input type="checkbox"/> <input type="checkbox"/>		
Previous imaging Yes No <input type="checkbox"/> <input type="checkbox"/>		
Plain radiography Yes No <input type="checkbox"/> <input type="checkbox"/>		
Ultrasound Yes No <input type="checkbox"/> <input type="checkbox"/>		
MRI Yes No <input type="checkbox"/> <input type="checkbox"/>		
Arthrography Yes No <input type="checkbox"/> <input type="checkbox"/>		
CT Yes No <input type="checkbox"/> <input type="checkbox"/>		

Types of lesions seen at MRI

Soft tissue lesions

Lesion	Right shoulder	Left shoulder
Tendinitis		
Bursitis		
Frozen Shoulder		
Rotator Cuff tears		
Impingement Syndrome		

Osseous lesions

Lesion	Right shoulder	Left shoulder
Fractures		
Dislocations		
Degenerative Diseases		

Infections

Lesion	Right shoulder	left shoulder
Septic arthritis		
Osteomyelitis		
myositis		

Neoplasms

Lesion	Right shoulder	left shoulder
Benign		
Malignant		
metastasis		

UNIVERSITY OF NAIROBI
MEDICAL LIBRARY

APPENDIX B: Patient consent form.

My name is Dr Lawrence Mugambi M' Arithi, a master of medicine student in the department of Diagnostic Imaging and Radiation Medicine at the University of Nairobi. I am doing a study on the MRI findings in patient with shoulder pain. I wish to recruit you to participate. The information obtained will be handled with utmost confidentiality.

This examination has been requested by your primary doctor.

Your name will not be included, except the serial number. The results of the study will be used to improve the diagnosis and management of shoulder pain. Please note that you are not obliged to participate and you have a right to decline or withdraw from the study.

For more clarifications, you can contact me on the mobile phone number **0722612627**.

If you accept please sign below.

Signature:

Date:

I certify that the patient has understood and consented participation in the study.

Dr Lawrence Mugambi M.

Signature:

Date:

APPENDIX C: Kibali cha mgonjwa.

Jina langu ni Dr Lawrence Mugambi M'Arithi Mimi ni daktari na pia mwanafunzi katika chuo kikuu cha Nairobi. Ninafanya uchunguzi zaidi juu ya wagonjwa wenye uchungu kwa mabega. Ningeomba ruhusa yako ili tuyatumie majibu yako katika uchunguzi. Majibu yoyote ambayo tutapokea kutoka kwa uchunguzi wako ni ya siri. Jina lako halitawekwa kwenye uchunguzi wetu ila nambari ya fomu tu. Majibu ya huu uchunguzi wako na ya wengine yatasaidia kuboresha matibabu ya magonjwa ya bega humu nchini.

Tafadhali elewa kuwa siyo lazima wewe kuhusiana nasi kama hiyo siyo hisia yako.

Kwa maelezo zaidi, husiana nami kwa simu **0722612627**

Ukikubali kuhusiana nasi tafadhali weka sahihi hapa chini.

Sahihi.....

Tarehe.....

Ninakiri kwamba mgonjwa ameelewa na amekubali kuhusiana nasi katika huu uchunguzi.

Dr Lawrence Mugambi M.

Sahihi.....

Tarehe.....