

**EXTERNAL AND INTERNAL ROOT MORPHOLOGY OF SECOND  
PERMANENT MOLARS OF A KENYAN POPULATION.**

**KATOTO. A. ILICH M. (BDS, NBI) V60/72471/2008.**

**DEPARTMENT OF CONSERVATIVE AND PROSTHETIC DENTISTRY SCHOOL  
OF DENTAL SCIENCES, COLLEGE OF HEALTH SCIENCES,  
UNIVERSITY OF NAIROBI.**

**THESIS SUBMITTED IN PARTIAL FULFILMENT OF THE REQUIREMENTS FOR  
THE AWARD OF THE DEGREE OF  
MASTER OF DENTAL SURGERY IN PROSTHODONTICS  
(MDS-PROSTHODONTICS).**

**YEAR 2014.**

**DECLARATION**

I declare that this thesis is my original work and has not been presented for the award of a degree in any other university.

**Signed**----- **date:** -----.

**KATOTO ALEX ILICH MWATU (BDS, UON).**

**APPROVAL**

This thesis has been carried out under our supervision and has been submitted with our approval as University of Nairobi supervisors.

**SUPERVISORS:**

1. Dr. Susan Maina. BDS (NBI) MSc (USA), AEGD and Esthetic Dentistry (USA),

FICD, OGW.

Senior Lecturer, Department of Conservative and Prosthetic Dentistry,

School of Dental Sciences, University of Nairobi.

Signed-----Date-----.

2. Dr. Fred Otieno. BDS (NBI), MSc (UK).

Lecturer, Department of Conservative and Prosthetic Dentistry,

School of Dental Sciences, University of Nairobi.

Signed-----Date-----.

3. D. Wambeti Njiru. BDS (NBI), MDENT SCI, MFDSRCSSED.

Lecturer, Department of Oral and Maxillofacial Surgery,

School of Dental Sciences, University of Nairobi.

Signed-----Date-----.

## **DEDICATION**

This thesis is dedicated to my late sister Angelina, my mum and dad, my wife Anne and my sons Wayne, Christiano and Alex junior. Your prayers and encouragement have given me the opportunity to be where I am today.

## LIST OF TABLES

Table 1: Distribution of second permanent molars between males and females.....	24
Table 2: Number of roots in maxillary and mandibular second permanent molars.....	25
Table 3: The root length and frequency of root fusion in second permanent maxillary and mandibular second permanent molars.....	26
Table 4: The frequency of occurrence and direction of root curvature in maxillary and mandibular second permanent molars.....	27
Table 5: Root lengths of second permanent maxillary and mandibular molars.....	28
Table 6: Number of canals per root and root canal configuration of second permanent maxillary and mandibular molars.....	30

## **LIST OF FIGURES**

Figure 1: Measuring tooth length using electronic digital caliper.....	19
Figure 2: Determination of root curvature using a graph paper.....	20
Figure 3: Canal configuration type II in second permanent mandibular molar.....	21

## **ABBREVIATIONS**

MDS – Master of Dental Surgery.

BDS – Bachelor of Dental Surgery.

UON – University of Nairobi.

MSC – Master of Science.

MDENT – Master of Dentistry.

$X^2$  - Chi square.

NBI – Nairobi.

USA – United States of America.

UK – United Kingdom.

SCI – Science.

SPSS – Statistical Package for Social Sciences.

M – Mesial.

D – Distal.

ML – Mesial lingual.

MB – Mesial buccal.

DB – Distal buccal.

P – Palatal.

MB2 – Second canal in the mesio-buccal root.

## TABLE OF CONTENTS

DECLARATION .....	ii
APPROVAL .....	iii
SUPERVISORS:.....	iii
DEDICATION.....	iv
LIST OF TABLES .....	v
LIST OF FIGURES .....	vi
ABBREVIATIONS .....	vii
ACKNOWLEDGEMENTS.....	xi
ABSTRACT.....	xii
CHAPTER ONE.....	1
1.0 INTRODUCTION.....	1
1.1 LITERATURE REVIEW.....	3
1.1.1 External morphology .....	3
1.1.2 Internal morphology .....	7
1.2 RESEARCH PROBLEM .....	10
1.3 STUDY JUSTIFICATION .....	11
1.4 STUDY OBJECTIVES .....	13
1.4.1 Broad objective.....	13
1.4.2 Specific objectives .....	13
1.5 HYPOTHESIS .....	13
1.5.1 Null hypothesis .....	13
1.6 STUDY VARIABLES .....	14
CHAPTER TWO .....	15
MATERIALS AND METHODS.....	15



2.1 Study design .....	15
2.2 Study areas .....	15
2.2.1 School of Dental Sciences .....	15
2.2.2 Kenyatta National Hospital (KNH) .....	15
2.2.3 Defence Forces Memorial Hospital (DFMH).....	16
2.2.4 Mbagathi District Hospital .....	16
2.2.5 St. Mary’s Mission Hospital .....	16
2.2.6 Social Services League Clinic .....	16
2.2.7 Moi Air Base Dental Clinic .....	17
2.3 STUDY POPULATION .....	17
2.4 SAMPLE SIZE DETERMINATION.....	17
2.5 DATA COLLECTION INSTRUMENTS AND TECHNIQUES.....	18
2.5.1 Specimen collection.....	18
2.5.2 Inclusion criteria .....	18
2.5.3 Exclusion criteria.....	18
2.6 DATA COLLECTION AND INSTRUMENTS .....	19
2.6.1 External morphology .....	19
2.6.1.1 Number of roots.....	19
2.6.1.2 Tooth length.....	19
2.6.1.3 Root curvature .....	20
2.6.1.4 Internal morphology .....	20
2.7 DATA ANALYSIS AND PRESENTATION.....	21
2.8 DATA VALIDITY AND RELIABILITY .....	22
2.9 CONTROL OF ERRORS AND BIAS .....	22
2.10 ETHICAL CONSIDERATIONS .....	22
2.11 PERCEIVED BENEFITS .....	23
2.12 STUDY LIMITATIONS.....	23

2.13 ENVIRONMENTAL CONSIDERATIONS .....	23
CHAPTER THREE .....	24
RESULTS .....	24
3.1 External morphology.....	24
3.1.1 Number of roots.....	25
3.1.2 Presence and pattern of root fusion .....	26
3.1.3 Root curvature .....	26
3.2 Internal morphology .....	28
3.2.1 Number of canals per root .....	28
3.2.2 Canal configuration .....	29
CHAPTER 4 .....	31
4.0 DISCUSSION.....	31
4.1 External morphology.....	31
4.3 Internal morphology.....	35
4.5 CONCLUSIONS.....	37
4.6 RECOMENDATIONS.....	38
REFERENCES .....	39
APPENDIX 1: Consent form.....	47
APPENDIX II: Data collection form.....	48
APPENDIX III: Vertucci's classification of root canal system (1984).....	51
APPENDIX IV: Letter of approval.....	52

## **ACKNOWLEDGEMENTS**

I wish to extend my sincere and heartfelt gratitude to my supervisors, Dr. Susan Maina, Dr. Fred Otieno and Dr. Wambeti Njiru, for their guidance, patience, support, understanding and help throughout the research period.

I also wish to wholeheartedly thank Professor Gathece, the Dean, School of Dental Sciences (UON) for her encouragement, support and advice and for giving me the chance to study in this great institution.

My special thanks go to Dr. B. Kisumbi, the Chairman, Department of Conservative and Prosthetic Dentistry, School of Dental Sciences, UON for her advice, encouragement and support.

I also appreciate the kind assistance and gesture extended to me by the staff and nurses of The UON Dental Hospital Conservative and Prosthetic Dentistry clinics, my classmates; Dr. Nyaata, Dr. Ariemba, Dr. Gaichu and Dr. Ogada.

I also wish to extend special thanks to Dr. T. Dienya, Dr. B. Omondi, Dr. J Nyaga and Dr. Kassim for guiding me through the course.

Lastly my deepest gratitude to the Commander in Chief and the Chief of Defence Forces of Kenya for according me the opportunity to serve my country and for the financial support they have accorded me.

## **ABSTRACT**

**Background:** Success of endodontic treatment depends on the knowledge of the normal, and variations from the normal, of root canal configurations of teeth. There exists a racial difference of these features and the significance of these cannot be ignored when planning and carrying out root canal treatment. Second permanent molars have been widely studied among Mongoloids and Caucasians. Since minimal data of their morphology in an African population exists, it is important to establish the root canal anatomy of these teeth in an African population.

**Objective:** To determine the external and internal root morphology of second permanent molars of a Kenyan population.

**Design:** This was an in vitro descriptive cross-sectional study.

**Setting:** 121 maxillary and 189 mandibular second permanent molars were collected from male and female participants aged between 16 and 40 years, who had their teeth extracted for various reasons at major hospitals and dental clinics in Nairobi.

**Methodology:** Extracted maxillary and mandibular second permanent molars were collected from participants who had extractions done at the following facilities' minor oral surgery clinics; School of Dental Sciences, University of Nairobi, Kenyatta National Hospital, Forces Memorial Hospital, St Mary's Hospital Moi air Base, Mbagathi District Hospital and Social League. A total of 310 teeth were collected into two well labeled containers (one for male and another for female). The collected teeth were sorted into mandibular and maxillary second permanent molars using the defined inclusion and exclusion criteria. Determination of the tooth length in millimeters, number of roots, direction of root curvature and number of canals and canal configuration was done on each.

The standard clearing technique was used to study internal morphology of teeth included in the study. The findings were recorded according to Vertucci's classification (1984)<sup>1</sup>, into a data collection form for each tooth examined.

The Statistical Package for Social Sciences SPSS version 12.0 was used for data analysis. Descriptive analytical tests were carried out to explain the frequency of various variables.

**Results:** 96.7% of maxillary second permanent molars had three roots, 2.5% had two roots, 0.8% had five roots while for the mandibular second permanent molars, 93.12%, 5.29% and 1.59% had two, three and four roots respectively. There was no root fusion in 71.9% of maxillary second permanent molars, while 0.8%-14.9 % exhibited some form of root fusion. In the mandibular second permanent molars, there was no root fusion in 87.83%, while 7.41% showed fusion of the mesial (M) and distal (D) roots with 4.76% showing fusion of mesial lingual (ML), mesial buccal (MB), distal lingual (DL) and distal (D) roots. On root curvature, 58.68% of the MB roots of maxillary second permanent molars curved distally while 67.77% of DB and 61.99% of the palatal (P) roots had no curvature. The mandibular second permanent molars showed a distal curvature of the mesial root in 68.78% while the distal root had no curvature in 75.66%.

The mean root length of the MB, DB and P of the maxillary second permanent molars were  $20.65 \pm 1.77$ mm,  $21.47 \pm 1.79$ mm and  $23.18 \pm 1.65$ mm respectively while in the mandibular second permanent molars, the mean root length was  $22.19 \pm 1.71$ mm and  $23.15 \pm 1.60$ mm with standard deviations of for mesial and distal roots respectively. Males had longer mean root lengths than females and the variation was statistically significant ( $F=3.30$ ,  $p=0.01$ ).

Majority of second permanent maxillary molars had three canals with the MB, MD and P roots having one canal. A second canal was found in 31% of the MB roots. The mesial root of second permanent mandibular molars had two canals in 93.7% while the distal root had one canal in 85.7%. A second canal was found in the distal root in 14.3% of the roots.

Vertucci type I canal configuration was more prevalent in both mandibular and maxillary second permanent molars with types II, III, IV, V and VI occurring less frequently.

**Conclusions:** three roots and two roots occurred more frequently in second maxillary and mandibular molars respectively. Root fusion occurred more frequently in second permanent maxillary molars than in the second permanent mandibular molars.

The palatal and distal root of the second molars had the least incidence of curvatures.

Most of the second permanent maxillary and mandibular molars had three canals and the most frequent canal configuration was Vertucci type I.

## CHAPTER ONE

### 1.0 INTRODUCTION

Knowledge and understanding of the number of roots, patterns and root canal configurations is important in dental extractions, orthodontic and endodontic treatments. While an extraction tends to be difficult when the tooth is multi rooted, it's more difficult where these roots are curved, divergent or converge apically with a piece of bone trapped among them. Orthodontic movements are also more difficult in multi rooted teeth. The success of root canal treatment is partly dependent on the thoroughness of the chemo mechanical preparation which is in turn dependent on the root canal morphology, irrigation and the perfection of the obturation and the coronal filling.

The apical 3-5mm of a root canal system is generally regarded as a critical zone, where complete debridement is considered an important element for good prognosis in root canal treatment<sup>2,3</sup>.

Curved roots present a challenge during endodontic treatment especially where the curvature is so severe that the apical region cannot be well cleaned. Although the introduction of nickel-titanium instruments has reduced the chances of perforations and fracture of instruments inside the canals, a severely curved canal cannot be well instrumented and obturated. This is one of the contributing factors to unfavorable root canal treatment outcomes. Therefore, the study of root canal anatomy has endodontic significance<sup>3</sup> and it is important to be familiar with variations in root canal systems and characteristic features in various racial groups. This aids in location, negotiation, chemo mechanical preparation and eventual obturation of the canals during root canal treatment and retreatment.

Previous studies on root and canal morphology which have been carried out predominantly on Caucasian and Asian populations have shown variations in the number of roots, root lengths and number of canals<sup>2,4,5</sup>.

The few studies done on African populations have also shown variations<sup>6, 7, 8, 9, 10, 11</sup>. However, scanty data exist on the Kenyan population. This study is very relevant to the practice of endodontics in second permanent maxillary and mandibular molars in the Kenyan population. The aim of this study was therefore to establish the root and root canal morphology of second permanent maxillary and mandibular molars among a Kenyan population. The results will contribute in improving the prognosis of root canal treatment, provide baseline data and form a basis for further research in this field.



## **1.1 LITERATURE REVIEW**

### **INTRODUCTION**

The external and internal morphology of second permanent maxillary and mandibular molars has been widely studied among Caucasian and mongoloid populations. There exists a paucity of data on the morphology of these teeth among the African population hence the need for the current study.

#### **1.1.1 External morphology**

##### **Crown morphology**

The crowns of the maxillary second permanent molars are trapezoidal and the mandibular ones are rhomboidal, when viewed mesially or distally and are trapezoidal when viewed buccally or lingually<sup>12</sup>. While the mandibular second permanent molars have four cusps, their maxillary counterparts have been reported to have cusp of Carabelli, (a fifth cusp) on the palatal aspect of the mesio-palatal cusp with a 35% incidence<sup>6</sup>. Morphologically, the mandibular second molar resembles the first molar, except that the roots are shorter, more curved and there are more anatomical variations<sup>1</sup>. These variations have been reported in several studies<sup>13, 14, 15, 16, 17, 18</sup>.

##### **Number of roots and root fusion**

The maxillary second permanent molars have three roots, one palatal and two buccal while the mandibular ones have two, a distal and a mesial, which are less divergent than in the first molars. However, some studies have reported the occurrence of either less or more roots in these teeth<sup>4, 19, 20, 21, 22, 23</sup>.

A study on root morphology of a Ugandan population reported a prevalence of three separate roots in second permanent maxillary molars to be 86% while fusion of the mesio-buccal and disto-buccal roots was reported to be 6.3%<sup>7</sup>. The prevalence of occurrence of two roots in

mandibular second permanent molars has been documented as 78% in a Sudanese population<sup>8</sup>. The occurrence of a third root has been reported to be below 5% among Caucasians, but up to over 40% among Mongoloids<sup>24</sup>.

Manning evaluated the root canal anatomy of 149 extracted mandibular second permanent molars using clearing technique and found that 22% of the mandibular second permanent molars had single roots, 76% had two roots and 2% had three roots<sup>4</sup>. Another study reported two cases of three rooted mandibular second permanent molars, with one mesial and two distal roots<sup>21</sup>. In another study, where the anatomy of 628 extracted mandibular first and second permanent molars was studied, it was found that 84.1% had two separate roots, 15.9% had fused roots and 1.5% had three roots<sup>19</sup>. A study evaluating racial variations of the mandibular second permanent molar showed that the incidence of three rooted mandibular second permanent molars was 2.8% in Mongoloid patients, 1.8% patients of Negro origin and 1.7% in Caucasian patients<sup>21</sup>. The presence of four roots (three mesial roots and one distal root) in the mandibular second permanent molar is a very rare anatomic variant. However, some cases of four rooted mandibular first molars have been documented in literature<sup>22, 24</sup>. A case report by Peiris et al (2009)<sup>23</sup> showed a case of extracted mandibular second permanent molar with four roots (2 mesial roots and 2 distal roots) using the clearing technique. In a study on Thai mandibular permanent molars it was found that the second permanent molars with two, three, and one root/s were 54%, 19% and 1% respectively<sup>25</sup>. A study of root and canal morphology of mandibular second permanent molars in an Indian population revealed that 87.8% had two separate roots with three canals while c-shaped canals were observed in 7.5%<sup>26</sup>. Other studies have shown different trends in shape and number of roots among different races<sup>4, 27, 28</sup>. These variations appear to be genetically determined<sup>29</sup> and are important in tracing racial origins of populations.

## **Root curvature**

The mesial root of the second permanent mandibular molar is stronger than the distal and may be curved distally while the in the second permanent maxillary molar, the palatal root is reported to incline palatally from the furcation<sup>26, 30</sup>. It also curves buccally and the apparent length on a radiograph is always shorter than its actual length. The buccal roots have been reported to have a distal curvature<sup>26, 30</sup>. The mesio-buccal root curves first to the mesial as it leaves the floor of the chamber and then to the distal, often quite abruptly. The mesial root of second permanent mandibular molars has been found to curve distally in 83% of the teeth while the distal root is straight in 78% of teeth<sup>19</sup>. The disto-buccal root is less frequently curved and straighter than the mesio-buccal one, although generally it exhibits a mesial curvature.

Some studies<sup>19, 26, 30, 29, 30</sup> have measured curvature of roots in various teeth. Using micro-computed tomography on 46 extracted maxillary second permanent molar teeth from Korean adults it was found that the medial buckle root was the most curved, followed by the distobuccal root and lastly the palatal root<sup>30</sup> at frequencies of 28%, 26% and 20% respectively.

In the second permanent mandibular molars, the mesial root curves mesially from the cervical line to the middle third of the root and then angles distally at the apex. The distal root is straight but sometimes exhibits a mesial curvature. The distal - lingual root, if present, often has a sharp apical hook towards the buccal.

Although several studies<sup>19, 26, 29, 30, 31</sup> have confirmed these directions of curvature, very few have explained the factors that could affect the direction and degree of curvature. It has been postulated that contact with the adjacent tooth during root development as well as changes in occlusal plane could be responsible for the direction of curvature of the roots<sup>29</sup>.

## **Tooth lengths**

The average length of maxillary second permanent molars is 20mm while that of the mandibular second permanent molar is 19.8mm<sup>32</sup>. The eruption time of this tooth is 11-12 years and completion of root formation is at 2-3 years post eruption<sup>6, 11</sup>. A study by Alam et al<sup>33</sup> found that tooth length has no significance on the sex of people of same race. Verhoeven et al<sup>34</sup> studied the mean lengths of each type of tooth in the permanent dentition of a Netherlands population and found that it was greater in males than in female. Rocha et al<sup>19</sup> in their study of second permanent molars in a Brazilian population found that the mean root lengths of the mesial and distal roots of second permanent mandibular molars were 20.87mm and 20.00mm. He further reported that, the minimum and maximum lengths of the mesial and distal roots were 16.25mm and 25.83mm respectively and 15.48mm and 25.72mm respectively.

## **Gender**

Few studies have evaluated gender differences in different populations. In a study on a Turkish population, it was reported that 25% of males and 22% of females' second permanent mandibular molars had lateral canals<sup>35</sup>. Lahdesmaki et al (2004)<sup>36</sup> and (2006)<sup>37</sup> reported that the average difference between males and females in permanent teeth length was about 6% in the mandibular canines, premolars and molars. There seems to be clear sexual difference in extreme root lengths, with extremely short roots being associated with females and extremely long roots with males<sup>37</sup>. The effect of the Y chromosome on dental development explains the expression of sexual dimorphism in the size and shape<sup>36, 37</sup>.

### **1.1.2 Internal morphology**

#### **Techniques used to study root canal morphology**

A variety of techniques have been used to study root canal morphology including radiographic examination<sup>38</sup> root sectioning<sup>39</sup>, staining and clearing techniques<sup>40, 41</sup>. It has been reported that fine details of the root canal system can be visualized by staining and clearing<sup>25</sup>.

A number of multi-variant studies have been carried out on root and root canal morphology of mandibular and maxillary molars. However, most of these were *in vitro* and laboratory studies using clearing and staining techniques<sup>41, 42, 43</sup>. These studies could not be applied *in vivo* since the techniques involved resulted in total destruction of the specimens or mutilation of the same.

The clearing technique or transparent root canal makes three-dimensional assessments possible while maintaining the original form of the root canal even to its minute detail. The specimen can also be preserved for a longer period of time. Other methods that have been utilized include the use of scanning electron microscope which is *in vitro*<sup>44</sup>, intra-oral periapical radiographs, surgical operating microscope as well as computerized tomography<sup>43, 45, 46, 47</sup> which, are *in-vivo*. *In-vitro* studies have been more widely conducted and are more accurate when compared with the *in-vivo* ones.

#### **Number of canals and canal configuration.**

The internal root morphology has been widely studied among Caucasian and Mongoloid populations. A wide variation and complexity of root canal systems has been reported in various studies<sup>3, 7, 24, 25, 48, 49</sup>.

The variations include; number, shape and types of canals, canal configuration, presence or absence of accessory canals and intercommunication between canals.

In a study by Visnja B. S et al (1991)<sup>49</sup>, the frequency of curved canals was found to be about 59%, being greater in posterior than anterior teeth. The root canal curvature was frequently localized at the apical one third (53.9%) followed by the cervical (33.3%) and the middle one-third (12.8%). The apical curvature was predominant in the sample of anterior teeth while the cervical curvature occurred in 45.2% of the posterior teeth sampled<sup>49</sup>.

The frequency of occurrence of apical deltas is more in the mesiobuccal root of both the first and second permanent maxillary molars<sup>7</sup>. More variations in the canal system occur in the mesiobuccal root of this tooth which may be attributed to racial differences<sup>7</sup>. A 100% occurrence of three separate roots in maxillary second molars has been reported, with 41.6% of them having a second canal in the mesio-buccal root compared to 67.8% in the first permanent maxillary molars<sup>5</sup>. Other studies have confirmed the presence of a second mesial-buccal canal in both the first and second maxillary molars<sup>3, 7, 24, 25, 50, 51, 52, 53, 54, 55, 56, 57, 58</sup>.

A study of a Sudanese population found that 73% of second permanent mandibular molars had type IV Vertucci canal configuration with 14% having type II<sup>8</sup>. It was also found that intercanal communication was present in 49%, this being more common in mesial roots<sup>8</sup>. Mandibular first and second permanent molars were shown to have one large canal until age 11-15 years, with the canal systems being completely defined at age 30-40 years<sup>59</sup>. Type IV and VIII Vertucci canal configurations were the most often found configurations in the apical 5mm<sup>59</sup>. The prevalence of accessory canals, lateral canals, intercanal communications and apical deltas was reported in 41%, 25%, 27% and 11% respectively. 80% of c-shaped canals had 1-3 apical foramina<sup>60</sup>. The frequency of occurrence of apical deltas is more in the mesiobuccal root of both the first and second permanent maxillary molars<sup>7</sup>.

The prevalence of intercanal communication is low among the young and the old but high during the middle ages<sup>61</sup>. It has been demonstrated that the apical anatomy of C-shaped root canal systems in permanent mandibular second molars is extremely complex with many

anatomical variations<sup>62</sup>. C-shaped canals have a relatively high prevalence in mandibular molars of Lebanese and Chinese populations<sup>4, 28</sup>.

Simon et al found that 36 % of mandibular second permanent molars with c-shaped canal systems had two main apical foramina, one in each albeit fused roots<sup>2</sup>. Of these, 16% had one single canal with a single foramina<sup>2</sup>. In another study done using stereo microscope measurements of mandibular second permanent molars by Choi et al (2006)<sup>30</sup>, it was found that 69% had single foramina and 31% had two foramina in the mesial root and 87% and 13% in the distal root respectively. In another study, it was reported that the incidence of one and two foramina was 61% and 38.8% in the mesial root respectively and 97.4% and 2.6% in the distal root respectively<sup>19</sup>. In addition a study on maxillary second permanent molars, found that the prevalence of those with two, three, four and five canals was 23.3%, 58.3%, 16.75 and 1.7% respectively<sup>25</sup>. This study also found that intercanal communication was present in 53% of second molars, 39.8% of first molars and 19% of third molars<sup>25</sup>. A review of literature shows that the study of root canal anatomy has endodontic<sup>1</sup> and anthropological<sup>63</sup> significance. There is scarcity of information on internal and external root morphology of teeth among the Kenyan population due to the fact that, the studies which have been carried out are on average tooth lengths in permanent dentition by Maina et al (1990)<sup>9</sup>, internal and external root morphology of permanent premolars by Ng'ang'a et al (2001)<sup>10</sup> and internal and external root morphology of first permanent molars by Nyaga et al (2010)<sup>11</sup>. There is no data on second permanent molars in a Kenyan population thus the need for this study.

## 1.2 RESEARCH PROBLEM

While it is widely expected that the current world trends of shifting towards more refined carbohydrate diets and more, easily accessible sugary drinks and snacks will lead to more edentulous people, the opposite is actually the reality with more people remaining dentate. This could be attributed to the universal acceptance of the fact that retention of a natural tooth with good prognosis is a superior choice to loss and replacement and improved levels of oral hygiene awareness, use of fluoride, increased number of dentists, and development of better restorative materials and techniques.

Endodontic and restorative treatments are geared towards restoring the form and function and directly influence the periodontal status which is key to tooth survival. Recent advances in endodontic treatment have resulted in the retention of many teeth which would have been condemned and extracted. The success rate of root canal treatment has greatly improved over the years. A more informed approach to endodontic treatments is required in order to increase the success rate to near 100%. Several studies<sup>20, 45, 52</sup> have reported significant numbers of teeth with apical periodontitis after root canal treatment which is an indication of unfavorable outcome.

There is a strong correlation between success rate of endodontic treatment and the complexity of the morphology of the canal system. While teeth with simple non complicated canal systems can be successfully instrumented and irrigated during non-surgical root canal treatment, this is not the case for those with complicated root canal systems and apical ramifications. In the latter instrumentation and flushing out of microorganisms and pulp tissues is difficult, which may sometimes require surgical endodontic treatment.

Although plain radiographs show the general internal and external morphology of teeth, they are inadequate in demonstrating the internal root morphology owing to the fact that they are two dimensional while the tooth is three dimensional.



Therefore, a thorough knowledge and understanding of the complexity of each tooth's internal and external morphology and the various variations is of absolute importance. Available literature has revealed a wide variation among Caucasian and Mongoloid populations in the external and internal morphology of teeth. It is therefore important to establish if the same exists in a Kenyan population.

### **1.3 STUDY JUSTIFICATION**

A lot of studies have been conducted on the internal and external morphology of all teeth and these have contributed immensely towards the current treatment regimes in dentistry. However majority of these have been conducted among Mongoloid and Caucasian populations and the Kenyan dentist relies heavily on the data obtained from these studies. Given the documented, observed racial differences in shape, size, and number of roots, root canal configuration and chronology of eruption all of which are genetically determined, it is important to study the external and internal root morphology among Africans. Moreover, different researchers have used different methodologies and techniques to study the internal and external root morphology of molars with varying degrees of accuracy and this has led to conflicting data even within a given population.

It is important for endodontists to be aware of the occurrence and frequency of variations in root canal morphology among peoples of different races. This is because world populations are becoming more cosmopolitan especially in the urban setups and Kenya is not an exception. Successful endodontic treatment requires knowledge, visualization of the internal canal morphology and anticipation of variations and complexities before start of treatment. This knowledge helps in location of canals negotiation as well as subsequent management.

Available information on tooth morphology of the Kenyan population is only on root length from studies by Maina et al (1990)<sup>9</sup> and Ng'ang'a et al (2001)<sup>10</sup> and Nyaga et al (2010)<sup>11</sup> who established the mean teeth lengths in permanent dentition, internal and external root

morphology of permanent premolars among Kenyans of African descent and external and internal root morphology of first permanent maxillary and mandibular molars respectively.

These studies have established some variations as compared to those of other studies. These variations and complexities which could either be attributed to different research methodologies or racial variations should be considered when one is performing endodontic procedures among Kenyan patients.

The aim of this study is therefore to determine the internal and external root morphology of the second permanent molars of a Kenyan population. The findings will be used as a reference by endodontists in clinical practice leading to improved quality of treatment and will form a basis for further research.

## **1.4 STUDY OBJECTIVES**

### **1.4.1 Broad objective**

To determine the external and internal root morphology of second permanent molars of a Kenyan population.

### **1.4.2 Specific objectives**

1. To determine the number of roots and the direction of root curvature in the  
Second maxillary and mandibular permanent molars.
2. To determine the pattern of root fusion in second maxillary and mandibular permanent  
molars.
3. To determine the average tooth length of the second maxillary and  
mandibular permanent molars.
4. To determine the number of canals and canal configurations in the  
Second maxillary and mandibular permanent molars.

## **1.5 HYPOTHESIS**

### **1.5.1 Null hypothesis**

There is no variation in the external and internal root morphology of second permanent molars.

## **1.6 STUDY VARIABLES**

### **Independent variables**

- a) Number of roots.
- b) External tooth length.
- c) Root curvature.

### **Dependent variables**

- a) Internal tooth morphology.
- b) Root canal configuration.
- c) Number of root canals.

### **Socio-demographic**

- a) Gender.

## **CHAPTER TWO**

### **MATERIALS AND METHODS**

#### **2.1 Study design**

This was a descriptive cross-sectional study.

#### **2.2 Study areas**

The study was conducted in major dental clinics in the city of Nairobi, Kenya. Being a cosmopolitan city it draws its 3.5 million population from almost and more significantly all Kenyan communities most of whom have migrated from the rural areas. The study sites were dental clinics in the following facilities; School of Dental Sciences-UON, Kenyatta National Hospital, Armed Forces Memorial Hospital, Moi Air Base, St Mary's Hospital, Social Services League and Mbagathi District Hospital.

##### **2.2.1 School of Dental Sciences**

It is situated off Argwing's Kodhek road and offers a Bachelor of Dental Surgery (BDS) degree and Master of Dental Surgery (MDS) degrees in Oral and Maxillofacial Surgery, Pediatrics' Dentistry, Periodontology and Prosthodontics. It also serves as a referral Hospital for patients from all parts of the country. These patients are attended to by both undergraduate and postgraduate students under supervision. It is also an internship training centre for newly qualified dentists.

##### **2.2.2 Kenyatta National Hospital (KNH)**

KNH is the largest Government referral hospital in Kenya and is situated in Upper Hill area of Nairobi off Ngong road. Its dental department has divisions catering for all specialties in dentistry and also serves as an internship centre. All departments are manned by specialists who supervise the Dental officers and interns. The patients attended in this Hospital are drawn from all types of socioeconomic classes.

### **2.2.3 Defence Forces Memorial Hospital (DFMH)**

Situated along Mbagathi road, it serves Kenya's military personnel and their civilian immediate families. Its dental clinic serves both as a referral centre for patients from medical reception stations in all military camps and facilities in the country. It is also an internship training centre for newly qualified Dentists.

### **2.2.4 Mbagathi District Hospital**

Originally known as 'Infectious Disease Hospital' (IDH) under the then King George the VI Hospital, now KNH. It was built in 1950's to offer health care in infectious diseases such as, tuberculosis, measles, meningitis and leprosy. In 1995, it was carved out of KNH and transformed in to an autonomous District Hospital for Nairobi. The Hospital has fully functional dental, eye, pharmacy, laboratory, radiology and inpatient departments.

### **2.2.5 St. Mary's Mission Hospital**

This Catholic Mission hospital was established in year 2000 to offer affordable health care services to the poor. It serves large numbers of patients from the surrounding low income areas of Kibera, Mukuru, Kwa Njenga, Reuben and Kuwinda. The hospital offers services in Dental care, Physiotherapy, Medical Laboratory, Ophthalmology, Radiology, Pediatrics, Surgery and Pharmacy.

### **2.2.6 Social Services League Clinic**

The clinic is situated in the heart of the Nairobi Central Business District along Uyoma Street off Ronald Ngala Street. It offers dental services at subsidized cost and the clinic is manned by Dentists and Community Oral Health officers.

### **2.2.7 Moi Air Base Dental Clinic**

Situated along Juja road in Eastern part of Nairobi, it serves as a referral hospital for Kenya Air Force personnel. It has a fully functional dental clinic, run by a dentist and community oral health officers.

## **2.3 STUDY POPULATION**

Second permanent maxillary and mandibular molars were collected from Kenyan patients aged between 16 and 40 years attended at the above hospitals' dental clinics and after dental examination, investigations and diagnosis and the tooth/teeth treatment prescribed as extraction and consequently performed the extracted tooth/teeth were collected and stored in well labeled containers with the patients' informed consent.

## **2.4 SAMPLE SIZE DETERMINATION**

Betty R. Kirkwood formula<sup>63</sup> was used to calculate the sample size:-

$$n = z^2 xu / e^2$$

Where,

n=Desired sample size,

U=Estimated proportion of an attribute in the target population. In this study, different aspects of tooth morphology were studied. The average length of second permanent maxillary molars is 20 mm. This was used as an estimate of one of the characteristics was studied.

e=Maximum possible error in the measurement. It is set as 0.5mm.

z=standard deviation set at 1.96 (95% confidence level).

$$n = 1.96^2 \times 1.96 \times 20 / 0.5 \times 0.5 = 307$$

=307 teeth.

However a sample size of 310 teeth was used.

## **2.5 DATA COLLECTION INSTRUMENTS AND TECHNIQUES**

### **2.5.1 Specimen collection**

Each collection point was supplied with two containers, one labeled male and the other female. Immediately after extraction, the teeth were washed in tap water, and then immersed in 5.25% sodium hypochlorite solution for 30 minutes to remove adherent soft tissue. They were then stored in 10% formalin. The teeth were then sorted according to the inclusion and exclusion criteria

### **2.5.2 Inclusion criteria**

Second permanent maxillary and mandibular molars:-

- a) From a Kenyan population
- b) From patients aged between 16 and 40 years.
- c) With well defined root and crown morphology.
- d) With fully formed roots and extracted without root fracture.
- e) Extracted without root fracture.

### **2.5.3 Exclusion criteria**

- a) Permanent molars other than second molars.
- b) Permanent second molars from non-Kenyan patients
- c) Permanent second molars from Kenyan patients not aged 16-40 years.
- d) Permanent second molars with roots which are not fully formed.
- e) Permanent second molars with evidence of root resorption.
- f) Permanent second molars with evidence of root fractures.
- g) Permanent molars with gross caries.
- h) Root treated second permanent molars.



## 2.6 DATA COLLECTION AND INSTRUMENTS

### 2.6.1 External morphology


A data collection form was used by the investigator to record the laboratory findings of each specimen (Appendix I).

#### 2.6.1.1 Number of roots

- a) A one rooted tooth showed one root externally.
- b) Two, three, or more rooted teeth were considered so if there was a clear demarcation of all the roots from the furcation.
- c) Roots were considered to be fused if there is calcification in the fusion regardless of whether it happens in the apical, middle or cervical third.

#### 2.6.1.2 Tooth length

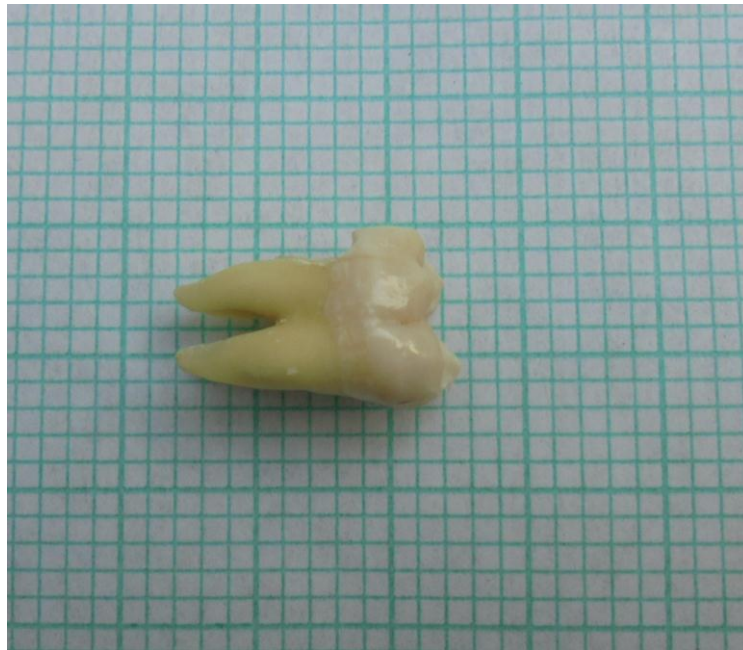
The external tooth lengths were measured using a calibrated electronic digital caliper (Shengya Machine and Tools Co. Ltd) to the nearest 0.05 of a millimeter from the tip of the mesio buccal and mesio lingual cusps of the maxillary and mandibular molars respectively to the tip/tips of the root/roots.



**Figure 1: Measuring tooth length using electronic digital caliper.**

### **2.6.1.3 Root curvature**

The teeth were oriented in their anatomical positions on a calibrated graph paper and the degree of root curvature analyzed with reference to the tooth vertical axis. By visual examination of the root against the grid, it was determined whether the root was straight, curved towards mesial, buccal, lingual, and palatal or had an S curvature. The extent of the curvature was determined by the position of the root apex from the long axis of the root.



**Figure 2: Determination of root curvature using a graph paper.**

### **2.6.1.4 Internal morphology**

The standard clearing technique defined by Vertucci et al (1984)<sup>1</sup> was used to determine the number and types of root canal configurations.

An access cavity was made in each of the teeth and the coronal pulp tissue extirpated until the canal orifices. They were then immersed in 5% sodium hypochlorite solution (Chlorex-5, Syner-chemie, Nairobi, Kenya) and agitated for 24 hours. The teeth were then washed in running water for 2 hours. They were then dried for 12 hours. After drying the teeth, Indian ink (Sanford rotring GmbH, Hamburg, Germany) was injected in the root canal systems

starting coronally using an endodontic irrigating syringe with a 27 gauge needle (BU Kwang Medical Inc, Seoul, Korea). The root apices were then immediately connected to a central suction system, until the ink exited through the apical foramina. After twelve hours of drying, the teeth were decalcified in 10% nitric acid for 5 days. The acid was agitated daily and the process was monitored periodically by radiography to avoid over decalcification. The decalcified teeth were then washed in running tap water for 4 hours and dehydrated in ascending concentrations (70%, 95%, and 100%) of ethyl alcohol (Scharlab S.L. Sentmenat, Spain) for 3 days and then immersed in methyl salicylate (RANKEM RFCL Limited Okhla-India) for 6 hours to render them transparent. They were then observed under a lens with magnification power 3X.

Vertucci's classification (1984)<sup>1</sup> was applied in analyzing the root canal configuration.



**Figure 3: Canal configuration type II in second permanent mandibular molar.**

## **2.7 DATA ANALYSIS AND PRESENTATION**

The findings from each specimen were entered in a coded form and 12.0 Statistical Package for Social Sciences (SPSS) was used for analysis. Analytical tests were carried out to explain the dispersion, central tendencies and frequency of various variables. Pearson Chi-square test was used to assess the relationship between two different sample means.

The data was presented in form of tables, frequency diagrams and charts.

## **2.8 DATA VALIDITY AND RELIABILITY**

To ensure that the data is representative of the general population, the samples were collected from major hospitals with dental clinics within Nairobi. The investigator trained research assistants and participated in the data collection to control external and internal influences. The investigator also ensured that separation of the collected teeth by gender was done at the collection points. Verification of the collected teeth via tooth morphology of the maxillary and mandibular molars was done before analysis.

To ensure data reliability, a repeat analysis was carried out by the investigator and the supervisors on two randomly selected teeth out of every ten teeth analyzed. Any variations that arose were addressed.

## **2.9 CONTROL OF ERRORS AND BIAS**

The study used only teeth which met the inclusion criteria.

The digital caliper used was calibrated by the Kenya Bureau of Standards and all data collection tools were pretested.

## **2.10 ETHICAL CONSIDERATIONS**

Permission to carry out the research was sought from the KNH/UON-Ethics and Research Committee. Approval was granted (appendix IV).

Permission was also sought from the hospitals where data collection was undertaken and from the patients who were at liberty to consent or refuse to their tooth/teeth being included in the study. All teeth collected that met the inclusion criteria had equal chances of being included in the study. Patients' confidentiality was maintained by recording only their gender and omitting the rest of the demographic data. All information collected was treated as confidential and the research findings will lead to better prognosis of endodontically treated teeth.

## **2.11 PERCEIVED BENEFITS**

The results of this study will be used as reference by dental practitioners in their clinical practice and for teaching and training in dentistry. The recorded data will increase the amount of information available on the subject especially among Africans whose available data is scanty. It is hoped that the results of this study will stimulate further research and also serve as a partial fulfillment of Master of Dental Surgery degree in Prosthodontics (MDS-Prosthodontics).

## **2.12 STUDY LIMITATIONS**

- a) The study population was limited to those attended at dental facilities in prominent hospitals in Nairobi city and may not be truly representative of the population.
- b) Tooth surface loss either due to age or any other factors may have influenced tooth length dimensions. This was overcome by using the non-functional cusps (mesio-lingual for the mandibular molars and mesio-buccal for the maxillary molars) as reference points on the crowns. These may also have undergone some degree of tooth surface loss.

## **2.13 ENVIRONMENTAL CONSIDERATIONS**

Disposal of all contaminated materials, chemicals and specimen used in the study was done according to the appropriate guidelines established and practiced at the University of Nairobi, School of Dental Sciences.

## CHAPTER THREE

### RESULTS

#### 3.1 External morphology

A total of 310 second permanent molars were included in the study. Of these, 121 (39.03%) and 189 (60.97%) were maxillary and mandibular respectively. Table 1 shows the gender distribution of the teeth. Slightly over a quarter, (98, 31.61%) of the second permanent molars studied were second left mandibular molars. The gender relationship was statistically significant ( $\chi^2= 4.66$ ,  $df= 1$ ,  $p= 0.03$ ).

**Table 1: Distribution of second permanent molars between males and females.**

Gender.	Second right maxillary molar n (%)	Second left maxillary molar n (%)	Second left mandibular molar n (%)	Second right mandibular molar n (%)	Total	$\chi^2$	df	p
Male	27 (8.71)	23 (7.42)	55 (17.74)	31 (0.10)	136(43.87)	4.66	1	0.03
Female	32 (10.32)	41 (13.23)	43 (13.87)	58 (18.71)	174(56.13)			
Total	59 (19.03)	64 (20.65)	98 (31.61)	89 (28.71)	310 (100)			

### 3.1.1 Number of roots

Tables 2 shows the number of roots in maxillary and mandibular permanent molars. Majority of the maxillary second permanent molars 117 (96.69%) had three roots while majority of mandibular second permanent molars 176 (93.12%) had two roots. All second permanent molars from male participants had three roots while 94.44% of those from female participants had three roots. Three second permanent molars from female participants were found to have two roots while one was found to have five roots. A significant finding was the presence of three roots in 6, (6.82%) and 4, (3.96%) in second mandibular permanent molars from male and female participants respectively and four roots in 3, (4.41%) of those from male participants.

**Table 2: Number of roots in second permanent maxillary and mandibular molars.**

Number of roots	Gender		Total
	Male n (%)	Female n (%)	
Maxillary molars	2	0 (0)	3 (4.17)
	3	49 (94.44)	68 (94.44)
	5	0 (0)	1 (1.39)
Total	49 (100)	72 (100)	121 (100)
Mandibular molars	2	79 (89.77)	97 (96.04)
	3	5 (5.68)	4 (3.96)
	4	4 (4.41)	0 (0)
Total	88 (100)	101 (100)	189 (100)

### 3.1.2 Presence and pattern of root fusion

Majority of second permanent maxillary molars 87 (71.90%) had no root fusion while 35 (18.10%) had their roots fused. There was no root fusion in 166 (87.83%) of second permanent mandibular molars. Relationship between length and pattern of root fusion was significant for both maxillary and mandibular molars,  $F=3.30$ ,  $df=5$ ,  $p=0.01$  and  $F=2.98$ ,  $df=3$ ,  $p=0.01$  respectively.

**Table 3: The root length and frequency of root fusion in second permanent maxillary and mandibular molars.**

Tooth	Length of fused roots mm	Presence and pattern of fusion	n (% Frequency).	ANOVA
Maxillary molars	20.98 ± 65	No fusion	87 (71.90)	$F=3.30$ , $df=5$ , $p=0.01$
	21.52 ± 1.97	MB+DB	18 (14.88)	
	19.75 ± 0.63	MB+P	13 (10.74)	
	19.26 ± 0.01	MB+DB+P	2 (1.65)	
	22.12 ± 1.68	Others	1 (0.83)	
Mandibular molars	22.68± 0.91	No fusion	166 (87.83)	$F=2.98$ , $df=3$ , $p=0.01$
	22.14 ± 1.71	M+D	14 (7.41)	
	22.12 ± 1.68	Others	9 (4.76)	

### 3.1.3 Root curvature

#### Root curvature in maxillary and mandibular second permanent molars

The MB root of second permanent maxillary molars was straight in 47 (38.84%) and curved in 71 (58.68 %). The most frequent curvature of this root was distal with mesial being the least as shown in table 5 below. Two teeth representing 1.65% had a MB root which was curved both mesially and distally.



There was no curvature in 82 (67.77%) of the DB root of second permanent maxillary molars while curvature was evident in 39 (32.23%). Overall, the distribution of, mesial, distal, buccal and other forms of curvatures were 17 (14.05%), 13 (10.74%) and 4 (3.31%) respectively.

The palatal root of second permanent maxillary molars was straight in 75 (62.00%) and curved in 38 (31.40%) and 8 (6.61%) buccally and mesially respectively.

The mesial root of second permanent mandibular molars was straight in 49 (25.93%), curved distally, buccally and mesially in 134 (69.30%) 1,(0.53%) and 1 (0.53%) respectively.

Four second mandibular molars representing 2.12%, had four roots two mesial and two distal with no curvatures.

The distal root was straight in 143 (75.66%) and curved distally, and mesially in 36 (19.05%) and 7 (3.70%) respectively.

**Table 4: Frequency of occurrence and direction of root curvature in second permanent maxillary and mandibular molars.**

Root	Root curvature					
	No curvature	buccal	mesial	distal	others	
Maxillary molars	MB	47 (38.84%)	0 (0%)	1 (0.83%)	71 (58.68%)	2 (1.65%)
	DB	82 (67.77%)	(4.13%)	17 (14.05%)	13 (10.74)	4 (3.31%)
	P	75 (62.00%)	38 (31.40%)	0 (0%)	8 (6.61%)	0 (0%)
Mandibular molars	M	49 (25.92)	1 (0.53%)	1 (0.53%)	130 (68.78)	8 (4.23%)
	D	143 (75.66%)	0 (0%)	7 (3.70%)	36 (19.05%)	3 (1.59%)

### 3.1.4 Root lengths of second permanent Maxillary and mandibular molars

The mean root length of the MB, DB and P roots of second maxillary molars was found to be  $20.65 \pm 1.77\text{mm}$ ,  $21.47 \pm 1.79\text{mm}$  and  $23.18 \pm 1.65\text{mm}$  respectively. The longest of these roots was the palatal at  $27.80 \pm 1.65\text{mm}$  while the shortest was the distal buccal at  $16.76 \pm 1.79\text{mm}$ . The mean root length of the M and D roots of second permanent mandibular molars was  $22.19 \pm 1.71\text{mm}$  and  $23.15 \pm 1.60\text{mm}$  respectively. Students t-test outcome was statistically significant ( $t=2.09$ ,  $p=0.04$ ).

**Table 5: Root lengths of second permanent Maxillary and mandibular molars**

Root	Length $\pm$ SD	t	p
Mesial-buccal root	$21.15 \pm 1.77\text{mm}$		
Distal-buccal root	$21.47 \pm 1.79\text{mm}$		
Palatal root	$23.18 \pm 1.65\text{mm}$	2.09	0.04
Length M root	$22.19 \pm 1.71\text{mm}$		
Length D root	$23.15 \pm 1.60\text{mm}$		

## 3.2 Internal morphology

### 3.2.1 Number of canals per root

Majority of the second permanent maxillary molars studied, 83 (69%) were found to have one canal in the MB root. A second canal (MB2) was found in 38 (31%) (Figure 9). All the DB roots had one canal and 120 (99.20%) of the P root had one canal while 1 (0.80%) had two canals.

The mesial root of second permanent mandibular molars was found to have 2, 1 and 3 canals in 177 (94%), 8 (4%) and 4 (2%) frequency respectively while the distal root had 1 and 2 canals in 162 (85.70%) and 27 (14.30%) respectively.

Where two canals were found, one was located lingually and the other buccally while when one canal occurred, it was located at the center of the root. The three canals found in only two MB roots of second permanent mandibular molars, were located lingually, buccally and the third was in the middle of the former two.

The distal root of the second mandibular permanent molars was found to have one canal, which was centrally located in 162 (85.70%) and two canals, one located lingually and the other buccally in 27 (14.30%).

### **3.2.2 Canal configuration**

Six canal configurations were observed in the MB canal of second permanent maxillary molars. The most frequently occurring canal configuration was Vertucci type I at 97 (80.16%) with types IV, II, III, V and VI occurring in 9 (7.44%), 7 (5.79%), 4 (3.31%), 2 (1.65%) and 2 (1.65%) respectively.

A total of 43 second permanent maxillary molars were found to have a second mesial buccal canal (MB2). Of these, 40 (93.01%), 1 (2.33%), 1 (2.33%) and 1 (2.33%) had Vertucci's types I, II, III and IV respectively.

The MB canal of second permanent mandibular molars was found to be predominantly (88.95%) type I configuration.

The distal root of second permanent mandibular molars was found to have one canal in 162 (85.70%) which was predominantly Vertucci's type I configuration. Other types of canal configurations observed were types II, III, IV and V. Two canals, one located DL and the other DB, were also observed in 27 (14.30%) of distal roots of the second permanent mandibular molars studied.

There were no c-shaped canals found in second permanent maxillary molars. However, 6.35% of the second permanent mandibular molars were found to have c-shaped canals.

**Table 6: Number of canals per root and root canal configuration of second permanent Maxillary and mandibular molars**

No. of canals		n,(%)	Canal configuration (Vertucci's classification (1984))						
			n (%)						
			I	II	III	IV	V	VI	
	1	38 (31.40)	71(85.50)	4 (4.8)	2 (2.4)	3 (3.6)	1 (1.2)	2 (2.4)	
	MB	2	83 (68.60)	26 (64.40)	3 (7.9)	2 (5.3)	6 (15.8)	1 (2.6)	0 (0)
Maxillary molars.	DB	1	121(100)	111(91.7)	2 (1.7)	3 (2.5)	4 (3.3)	0 (0)	1 (0.8)
	P	1	120 (99.2)	71 (85.5)	4 (4.8)	2 (2.4)	3 (3.6)	1 (1.2)	2 (2.4)
		2	1 (0.83)	26 (68.4)	3 (7.9)	2 (5.3)	6 (15.7)	1 (2.6)	0 (0)
	M	1	1 ( 0.55)	1 (100)	0 (0)	0 (0)	0 (0)	0 (0)	0 (0)
		2	176 (97.24)	167 92.27)	6 (3.31)	3 (1.66)	5 (2.76)	0 (0)	0 (0)
		3	4 (2.21)	4 (2.21)	0 (0)	0 (0)	0 (0)	0 (0)	0 (0)
Mandibular molars.	D	1	162 (85.71)	128 (67.72)	14 (8.64)	8 (4.94)	10 (6.17)	2 (1.23)	0 (0)
		2	27 (14.29)	61 (32.28)	21(77.78)	1 (3.7)	1 (3.7)	3(11.11)	1 (3.7)

## CHAPTER 4

### 4.0 DISCUSSION

#### 4.1 External morphology

The second permanent mandibular and maxillary molars analysed in this study were not grouped according to their specific ages hence age variations were not considered in this study. Teeth were collected from patients aged between 16 years and 40 year because the apices close at 16years while at 40 years, variations including canal calcifications, pulp stones and root canal fillings begin to occur.

Majority of second maxillary molars were found to have three roots. Two roots were found in 2.48% of the study sample while one root was found in 0.83%. These findings are similar to those from previous studies<sup>4, 6 24, 25, 27, 28</sup>. There was no variation in the external and internal root morphology of second permanent molars hence the null hypothesis was accepted.

Of the 121 maxillary second permanent molars studied, majority (72) were from female participants. 4.17% of these were found to have two roots while 1.39% had one root. All the second permanent maxillary molars from male participants were found to have three roots. A Pearson chi-square was performed to determine if there was any association between gender and the extracted teeth. This was not statistically significant ( $\chi^2= 4.66$ ,  $df= 1$ ,  $p= 0.03$ ). Though the occurrence of two and five roots in second permanent maxillary molars is a rare occurrence, three second permanent maxillary molars from female participants were found to have two roots while one had five roots. Their occurrence in this study could be attributed to racial variations. All the second permanent maxillary molars from male participants had two roots, a finding which is similar to those in other studies<sup>1, 4, 5, 24, 25, 34, 44</sup>.

There was no root fusion in majority of the teeth studied. Where it occurred, the most frequently fused roots were the mesiobuccal and distobuccal and there was a marginal

association between the root length and presence of root fusion with longer roots fusing more frequently than shorter roots ( $F=3.30$ ,  $df=5$ ,  $p=0.01$ ). The frequency of fusion of the mesiobuccal and distobuccal roots was found to be 14.88% in this study. In a study of second permanent maxillary molars of a Ugandan population Rwenyonyi et. al (2007)<sup>7</sup>, reported that root fusion occurred in 6.3%. The differences in frequencies between the current study and the later can be attributed to sample size since the later used 223 second permanent maxillary molars as compared to the current study, which has used 121 second permanent maxillary molars. Racial variations could also have contributed to the differences in frequencies.

Majority of the second permanent mandibular molars studied were found to have two roots which were not fused. These findings are similar to those of other studies<sup>6, 7, 12, 25, 26, 43, 59, 63</sup>. However, a study of Sudanese mandibular molars reports an incidence of two roots to be 78%. This is lower than the findings of the current study which reports an incidence of 93.12%. Although both studies used the standard clearing technique, this difference could be attributed to racial differences. This is because the current study was done on teeth extracted from a Kenyan population while the previous studies were done on teeth extracted from Caucasian and Mongoloid populations.

Four second mandibular molars were found to have four roots, two distal and two mesial. Case reports of second permanent molars with more than two roots have been published by Peiris et al (2009)<sup>23</sup> and Ferraz et al (1993)<sup>21</sup> who reported rare cases of mandibular second permanent molars with four and three roots respectively. An extra root has a clinical significance in endodontics since it presents with an extra canal which must be identified, cleaned, shaped and obturated. In addition, it may pose challenges during tooth extraction. Where the tooth is being used as an abutment, the roots distribute masticatory forces to jaw bones and also contain the neurovascular bundle. An extra root will therefore increase the root surface area and the crown to root ratio and periodontal surface area which in turn leads

crow to root ratio and more even distribution of masticatory forces making the tooth a more favorable as an abutment.

Majority of the mesiobuccal and distobuccal roots of the second permanent maxillary molars were found to be curved distally and mesially respectively. The palatal root was found to be more frequently straight. Where the curvature of this root occurred it was more frequently towards the buccal. Majority of the mesial roots of the second permanent mandibular molars were curved with the curvature being more frequently distal. The distal root of this tooth was more frequently not curved. Where curvature of this root occurred, it was more frequently distal. These findings concur with those of studies done by Prassana et al (2010)<sup>28</sup> on an Indian population, lee et al (2006)<sup>31</sup> and Visnja et al (1991)<sup>49</sup>. Rocha et al (1996)<sup>19</sup> reported that the mesial root of second permanent mandibular molars curve distally in 83% of the teeth examined. He further reported that the distal root was straight in 78% of the teeth examined. This prevalence is slightly higher than that found in the current study, which reports that 74.07% of the mesial roots are curved while 75.66% of distal roots are not curved. This difference could be attributed to racial differences since the former and current studies used the same technique to study the external morphology but the populations studied were Brazilian and Kenyan respectively.

Root curvature may be visible on a plane radiograph. However, two dimensional radiographs must be interpreted with caution since a straight root in the mesial-distal dimension may be curved in the buccal-lingual direction. Endodontic treatment in curved roots is challenging and has been associated with disastrous consequences such as loss of working length, apical transportation, wedge creation, perforations and instrument separation all of which impact negatively on the prognosis of endodontic treatment.

The root mean lengths of second permanent molars were found to be  $23.18 \pm 1.65\text{mm}$ ,  $20.65 \pm 1.77\text{mm}$  and  $21.47 \pm 1.79 \text{ mm}$  for the palatal, mesiobuccal and distobuccal respectively. This differs with what has been reported by Carrotte P (2004)<sup>32</sup> who gives the average length of the second permanent maxillary molar as an average of 19.8mm. The difference could be due to racial difference, sample size variation or methodology. This is because the author documented an average of root lengths of second permanent maxillary and mandibular molars computed from a combination of earlier studies. The reference points used could also have contributed to the variations. The distal root of second permanent mandibular molars was found to be longer than the mesial one with mean lengths of  $23.15 \pm 1.60 \text{ mm}$  and  $22.19 \pm 1.71\text{mm}$  respectively. This significantly differs from what was reported by Rocha et al (1996)<sup>19</sup> in their study on a Brazilian population. While the current study used the apices of the respective roots and the mesiolingual cusp as the reference points, Rocha et al used the apices of the respective roots and their corresponding cusps as the reference points. This could have led to the increased mean lengths in the current study due to the fact that the non functional cusps which are likely to undergo minimal tooth surface loss were used as the reference points. Racial and sample size variations could also have contributed to the difference in mean root lengths.

The knowledge of average tooth lengths is of great interest and practical value in endodontic treatment. These findings may be useful in determining working lengths accurately with hand files or while using apex locators. Knowledge of root curvature and root lengths in determining post length and post length to crown ratio during restoration of endodontically treated teeth.



### 4.3 Internal morphology

Most of the second permanent maxillary molars were found to have one canal in each of the roots. A second canal was found in the mesiobuccal root in 31.41% of the teeth studied. The palatal root was also found to have a second canal in 0.8% of the teeth studied. The incidence of a second canal in the MB root of the second permanent maxillary molar has been reported by several investigators<sup>3, 7, 42, 43, 44, 51, 52, 59, 64</sup> at varying percentages. The methods used in these studies were, the clearing technique<sup>3, 7, 42, 44, 51, 52, 59, 64</sup>, scanning electron microscope<sup>44</sup>, intra-oral periapical radiographs, surgical operating microscope as well as computerized tomography<sup>43, 45, 46, 47</sup>. Sert S et al (2004)<sup>5</sup>, in their study on a Turkish population, reported the occurrence of the second canal in the MB root of second permanent maxillary molars to be 41.6%. The presence of a second canal in the MB root of maxillary molars is no longer a subject of debate since there is an overwhelming amount of literature in support of this. The findings of the current study concur with those in other studies<sup>3, 7, 42, 43, 58</sup> although incidence is lower than in some studies and higher than in others. The difference could be attributed to variations in race, since the current study was done on second permanent maxillary teeth extracted from a Kenyan population which is predominantly composed of Africans as compared with the other studies whose population was Caucasians and Mongoloids. Although the occurrence of a second canal in the palatal root of second permanent maxillary molars is a rare occurrence, there are several case reports in literature which report the treatment of second maxillary molars with two palatal canals<sup>65, 66, 67, 68, 69, 70</sup>. The current study found one such case. This finding is an awakening call to endodontists to expect the unexpected during their clinical practice.

The incidence of c-shaped canals in the current study was found to be 6.35%. This finding is in tandem with those from previous studies<sup>4, 28 59</sup>. C-shaped canals are difficult to identify and instrument during endodontic treatment. Since the success of endodontic treatment is

dependent on complete chemo mechanical preparation and obturations, their presence, if not detected and cleaned, can greatly influence endodontic treatment outcome. For this reason, knowledge of their existence is of great importance to the endodontist.

The most common type of canal configuration in both the maxillary and mandibular second permanent molars was Vertucci type I. The other types of root canal configurations found in varying frequencies were type II, III, IV, V and VI. Vertucci's. The findings of the current study partly concur with other studies<sup>1, 7, 8, 25, 41, 43</sup>. This is because canal configuration types VII and VIII were not found in the current study. This difference can be attributed to the different populations from whom the teeth included in the different studies were extracted. The knowledge from laboratory studies is essential in providing insight in to the complexity of root canal anatomy. Standard canal instrumentation may not be sufficient enough to clean the root canal system. Consequently, the root filling may leave some spaces with remnant pathogenic micro- organisms which may proliferate and sustain post treatment periradicular disease<sup>62</sup>.

## **4.5 CONCLUSIONS**

### **1. Number of roots and root fusion**

Majority of second permanent maxillary molars had three roots with 2.48% and 0.8% having two and five roots respectively.

Root fusion occurred in 18.1%.

Majority of second permanent mandibular molars had two roots with three and four roots occurring in 5.29% and 1.59% respectively. Root fusion occurred on 29.1%.

### **2. Root curvature**

The palatal root of second permanent maxillary and distal root of the second permanent mandibular molar exhibited the lowest frequency of root curvature.

Of the curved palatal roots, majority curved buccally while the distal root curved distally in most cases.

### **3. Root length**

The mean root lengths of second permanent maxillary molars were  $23.18 \pm 1.65$ mm,  $21.5 \pm 1.77$ mm and  $21.47 \pm 1.79$ mm for palatal, mesiobuccal and distobuccal respectively.

Second permanent mandibular molars had mean root lengths of  $22.19 \pm 1.71$ mm and  $23.15 \pm 1.60$ mm for the mesial and distal roots respectively.

#### **4. Number of canals and canal configuration**

Majority of second permanent maxillary molars were found to have three canals. A fourth canal was found in 31.41%. This fourth canal was in the mesiaobuccal root. An overwhelming majority of second permanent mandibular molars were found to have three canals. The mesial root had one and three canals at a frequency of 4.23% and 2.12% respectively. Vertucci type I canal configuration was predominantly found in all the roots of the teeth studied.

#### **4.6 RECOMENDATIONS**

1. Long and short files should be included in the endodontic armamentarium.
2. Three dimensional diagnostic techniques are essential in identification of anatomical features such as root curvatures and internal root canal morphology.
3. More attention should be directed towards finding the MB2 canal in the mesiobuccal root of the second permanent maxillary molar.

## REFERENCES

1. Vertucci F. J. Root canal anatomy of the human permanent teeth. *Oral Surgery Oral medicine Oral pathology*, 1984; 58: 589-599.
2. Simon J. H. S. The Apex: how critical is it? *General Dentistry*, 1994; 42: 330-334.
3. Vertucci F. J. Root canal morphology and its relationship to endodontic procedures. *Endodontic Topics* 2005; 10: 3-29.
4. Manning S. A. Root canal anatomy of mandibular second molars II; C-shaped canals. *International Endodontic Journal* 1990; 67(1):40-45.
5. Sert S, Bayiri G. S. Evaluation of the root canal configuration of the mandibular and maxillary permanent teeth by gender in a Turkish population. *Journal of Endodontics*, 2004; 30:391-398.
6. Ngassapa D, Hassanali J, Amwayi P and Guthua S. *Essentials of Oral Anatomy* 1996; page 119.
7. Rwenyonyi C. M, Kutesa A. M, Muwazi L. M, Buwembo W. Root and canal morphology of maxillary first and second permanent molar teeth in a Ugandan population. *International Endodontic Journal*, 2007; 4(40):679-683.
8. Ahmed H. A, Abu-bakr N. H, Yhia N. A and Ibrahim Y. E. Root and root canal morphology of permanent mandibular molars in a Sudanese population. *International Endodontic Journal*, 2007; 40:766-712.
9. Maina S. W, Wagaiyu C. K. The average tooth length in a black Kenyan population. *East African medical Journal*, 1990; 67:33-38.
10. Rose N. Ng'ang'a. External and Internal root canal morphology of premolar teeth in Kenyans of African descent, 2001; 78: 200-203.

11. Nyaga J. M, Maina S. W, Okoth J. and Gathece L. Internal Root Morphology in Mandibular First Permanent Molars in A Kenyan Population East African Medical Journal, 2010; 87: 101-106.
12. Berkovitz B. K. B, Holland G. R, Moxham B. J. Oral Anatomy, Histology and Embryology. Mosby Elsevier Science Limited. Third Edition 2002; page 13-33.
13. Carlsen O. Root complex and root canal system: a correlation analysis using one-rooted mandibular second molars. Scandinavian Journal of Dental Research, 1990; 98(4):273–285.
14. Bond J. L, Hartwell G. R, Donnelly J. C, Portell F. R. Clinical management of middle mesial root canals in mandibular molars. Journal of Endodontics, 1988; 14(6):312–314.
15. Weine F. S, Pasiewicz R. A, Rice R. T. Canal configuration of the mandibular second molar using a clinically oriented in vitro-method. Journal of Endodontics, 1988; 14: 207-213.
16. Wells D. W, Bernier W. E. A single mesial canal and two distal canals in a mandibular second molar. Journal of Endodontics, 1984; 10(8):400–403.
17. Rabie G. Mandibular molar with merging mesiobuccal and distal root canals. Endodontic Dentistry Traumatology, 1985; 1(5):191–194.
18. Melton D. C, Krell K. V, Fuller M. W. Anatomical and histological features of C-shaped canals in mandibular second molars. Journal of Endodontics, 1991; 17(8):384–386.
19. Rocha, L. F. C., Sousa Neto, M. D, Fidel S. R, Costa W. F, Pecora J. D. External and Internal Anatomy of mandibular molars. Brazilian Dental Journal, 1996; 1: 33-40.

20. Castellucci A. Access cavity and endodontic anatomy. In: Castellucci A, editor. Endodontics. Vol.12th Edition. Tridente Florence; 2006; 245–329.
21. Ferraz J. A, Pecora J. D. Three-rooted mandibular molars in patients of Mongolian, Caucasian and Negro origin. Brazilian Dentistry Journal, 1993; 3(2):113–117.
22. Friedman S, Moshonov J, Stabholz A. Five root canals in a mandibular first molar. Endodontic Dentistry Traumatology, 1986; 2(5):226–228.
23. Peiris R, Pitakotuwage N, Takahashi M, Ohzeki S, Nakayama M, Sakurai S, et al. Mandibular permanent second molar with four roots and root canals: a case report. Odontology. 2009; 97(1):51–64.
24. Vertucci F. J, Williams R. G: Root canal anatomy of the mandibular first molar. Journal of New Jersey Dental Association 1974; 45, 27-28.
25. Gulabivala K, Opasanon A, Ng Y-L, Alavi A. Root and canal morphology of Thai mandibular molars. International Endodontic Journal, 2002; 35, 56-62.
26. Cooke H. G, Cot F. L. C-shaped canals in mandibular molars. Journal of American Dental Association 1979; 99:836-839.
27. Prasanna N, Chandana S, Chandragin V.S and Mitbun R. Root and canal morphology of mandibular second permanent molars in an Indian population. Journal of Endodontics, 2010; 36 (8): 1319-1322.
28. 28. Yang, Z. P, Yang, S. F, Lin, Y. C, Chi C. Y. C-shaped roots canals in mandibular second molars in Chinese population. Endodontics and Dental Traumatology; 1988; 4: 160-163.
29. Pineda F. and Kuttler Y. Mesiodistal and buccolingual roentgenographic investigation of 7,275 root canals Oral Surgery, 1972; 33: 101 – 110.

30. Choi, H. M, Yi W. J, Choi, S. C, Park T. W. Factors affecting root curvature of mandibular first molar. *Korean Journal of Oral Maxillofacial Radiology*, 2006; 36, (1): 55-62.
31. Lee J. K, Ha B. H, Choi, J. H, Heo S. M, Perinpanayagam, H. Quantitative three-dimensional analysis of root canal curvature in maxillary first molars using micro-computed tomography. *Journal of Endodontic*, 2006; 32: 941-945.
32. Carrotte P. Part 4. Morphology of the root canal system. *British Dental Journal*, 2004; 197:379-383.
33. Alam M. S, Aziz-us-salam, Prajapati K, Rai P, Molla A. A. Study of tooth length and working length of first permanent molar in Bangladeshi people. *Bangladesh Medical Resource Council Bulletin*, 2004; 30(1): 36-42.
34. Verhoeven J.W, van Aken J, Van Der Weerd G.P. The length of teeth. A statistical analysis of the differences in length of human teeth for radiologic purposes. *Oral Surgery Oral Medicine Oral Pathology*, 1979; 47:193-199.
35. Semih Sert and Gundaz S. B. Evaluation of the root canal configuration of the mandibular and maxillary permanent teeth by gender in the Turkish population. *Journal of Endodontics*, 2008; 30:40.
36. Lahdesmaki R, Alvesalo L. Root growth in the permanent teeth in 47, XYY males' permanent teeth. *Journal of Dental Research*, 2004; 83: 771 – 775.
37. Lahdesmaki R, Alvesalo L. Root growth in the permanent teeth of 45, X/46, XX females. *European Journal of Orthodontics*, 2006; 28: 339 – 344.



38. Kaffe I, Kaufman A, Littner MM, Lazarson A. Radiographic study of root canal system of mandibular anterior teeth. *International Endodontic Journal*, 1985; 18:253-259.
39. Mauger M. J, Schindler W. G, Walker W. A. An evaluation of canal morphology at different levels of root resection in mandibular incisors. *Journal of Endodontics*, 1998; 24:607-609.
40. Robertson D, Leeb J, McKee M, Brewer E. A clearing technique for the study of root canal systems. *Journal of Endodontics*, 1980; 6:421-624.
41. Sert S, Bayiri G. S. Evaluation of the root canal configuration of the mandibular and maxillary permanent teeth by gender in a Turkish population. *Journal of Endodontics*, 2004; 30:391-398.
42. Al- Shalabi R. M, Omer, O. E, Glennon J, Jennings S. M, Claffey N. M. Root canal anatomy of maxillary first and second permanent molars. *International Endodontic Journal*, 2000; 33: 405-414.
43. Alavi A. M, Opananon A, Ng Y. L, Gulabivala K. Root and canal morphology of Thai maxillary molars. *International Endodontic Journal*, 2002; 35: 475-485.
44. Buhrley L. J, Barrow M. J, Begole E. A, Wenckus C. S. Effect of magnification on location of the MB2 canal in maxillary molars. *Journal of Endodontics*, 2002; 28: 324-327.
45. Sperr W, Schedle A, Eder A, Kantor M. Root canal system in the mesiobuccal root of the maxillary first molar: An in vitro comparison study of computed tomography and histology. *Dentomaxillofacial Radiology*, 2006; 35:175-177.

46. Tam A, Yu W. Location of canal isthmus and accessory canals in the mesiobuccal root of maxillary first permanent molars. *Journal of Canadian Dental Association*, 2002; 68: 28-33.
47. Zaatari E. I, Al-Kandari A. M, Alhomaidah S, Al-yasin I. M. Frequency of endodontic treatment in Kuwait: Radiographic evaluation of 846 endodontically treated teeth. *Journal of Endodontics*, 1997; 23: 453-456.
48. Melton D. C, Krell K. V, Fuller M. W. Anatomical and histological features of c-shaped canals in mandibular second molars. *Journal of Endodontics*, 1991; 17:384-396.
49. Visnja B. S. Frequency and most common localization of root canal curvature. *Acta stomatologica croatica*, 1991; 25:109-115.
50. Vertucci F. J. Root canal morphology and its relationship to endodontic procedures. *Endodontic Topics*, 2005; 10:3-29.
51. Walcott J. Ishley D, Kennedy W, Johnson S, Minnich S. Clinical investigation of second mesiobuccal canals in endodontically treated and retreated maxillary molars. *Journal of Endodontics*, 2002; 28:477-479.
52. Vasudev S. K, Goel B. R. Endodontic miscellany: Negotiation and management of MB2 canal in a maxillary second molar. *Endodontology*, 2003; 15: 33-36.
53. Thomas R. P, Moule A. J, Bryant R. Root canal morphology of maxillary permanent first molar teeth at various ages. *International Endodontic Journal*, 1993; 26: 257-267.

54. Tam A, Yu. W. Location of canal isthmus and accessory canals in the mesiobuccal root of maxillary first permanent molars. *Journal of Canadian Dental Association*, 2002; 68: 28-33.
55. Sperr W, Schedle A, Eder A, Kantor M. Root canal system in the mesiobuccal root of the maxillary first molar: An in vitro comparison study of computed tomography and histology. *Dentomaxillofacial Radiology*, 2006; 35:175-177.
56. Skidmore A. E, Bjorndal A. M Root canal morphology of the human mandibular first molar. *Oral Surgery, Oral Medicine, Oral Pathology, Oral radiology Endodontics*, 1971; 32 (5): 778 –7 84.
57. Sempira H. N, Hartwell G. R. (2000). Frequency of second mesiobuccal canal in maxillary molars as determined by use of an operating microscope. A clinical study. *Journal of Endodontics*, 2000; 26: 673-674.
58. Kulild J. C, Peters D. D. Configuration of canal systems in the mesiobuccal root of maxillary first and second molars. *Journal of Endodontics*, 1990; 16:311-317.
59. Cheung G. S. P, Yang J, Fan B. Morphometric study of the apical anatomy of C-shaped root canal systems in mandibular second molars. *International Endodontic Journal*, 2007; 40: 239-246.
60. Peiris H. R. D, Pitakotuwage T. N, Takahashi K, Sasaki K, Kanazawa E. Root canal morphology of mandibular permanent molars at different ages. *International Endodontic Journal*, 2008; 41: 828-835.
61. Walker R. T. Root form and canal anatomy of mandibular second molars in a Southern Chinese population. *Journal of Endodontics*, 1996; 14:325-329.

62. Marcus T. The management of periapical lesions in endodontically treated teeth. Australian Endodontic Journal, 2006; 32: 2-15.
63. Betty K, Jonathan A. C. S. Essential Medical Statistics, Second Edition, 2003 page 413-428.
64. Vasudev S. K, Goel B. R. Endodontic miscellany: Negotiation and management of MB2 canal in maxillary second molar, Endodontology, 2003 15: 33-36.
65. Shin S. J, Park J. W, Lee J. K, Hwang S. W. Unusual root canal anatomy in maxillary second molars: two case reports. Oral Surgery Oral Medicine Oral Pathology Oral Radiology Endodontics, 2007; 104(6): 211-223.
66. Baratto-Filho F, Fariniuk L. F, Ferreira E. L, Pecora J. D, Cruz-Filho A. M, Sousa-Neto M. D. Clinical and macroscopic study of maxillary molars with two palatal roots. International Endodontic Journal, 2002; 35(9):796–801.
67. De Almeida-Gomes F, Maniglia-Ferreira C, dos Santos R. A. Two palatal root canals in a maxillary second molar. Australian Endodontic Journal, 2007; 33(2):82–83.
68. Barbizam J. V, Ribeiro R. G, Tanomaru Filho M. Unusual anatomy of permanent maxillary molars. Journal of Endodontics, 2004; 30(9):668–671.
69. Qun L, Longing N, Qing Y, Yuan L, Jun W, Qingyue D. A case of asymmetric maxillary second molar with double palatal roots. Quintessence International, 2009; 40(4):275–276.
70. Prashanth M. B, Jain P, Patni P. Maxillary right second molar with two palatal root canals. Journal of Conservative Dentistry, 2010; 13(2):94–96.

**APPENDIX 1: Consent form**

I am a master’s student at the University of Nairobi Dental Hospital. Currently, I am carrying out a research study on extracted permanent second molars with an aim of understanding their morphology in our population. If your dentist recommends the extraction of tooth/teeth after examination, investigations and diagnosis, I wish to request for your permission to include your extracted tooth/teeth in my study. By donating your tooth/teeth, you will contribute greatly to my research study whose findings will improve the quality of dental treatment to the general population.

**Informed consent**

I, the patient/parent/guardian, after reading and being explained to the purpose of the tooth/teeth collection do consent to the inclusion of my/my patient’s tooth/teeth to the study.

Patient -----

Age                      Signature                      Date

Parent -----

Signature                      Date

Guardian-----

Signature                      Date



**8. Curved root**

Root	Direction of curvature					
	Straight	Lingual	Buccal	Mesial	Distal	Others
MB						
DB						
P						
M						
D						
Others						

**9. Number of canals per root**

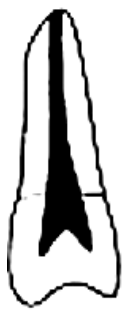Root	Number of canals
Mb	
DB	
P	
M	
D	
Others	

**10. Canal configuration according to Vertucci's classification (1984) per root**

Canal	Vertucci's classification								
	I	II	III	IV	V	VI	VII	VIII	Other
MB									
MB2									
DB									
P									
ML									
DL									
DB									
C-shaped canals									
Others									



**APPENDIX III: Vertucci's classification of root canal system (1984)**



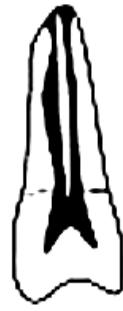**Type I**



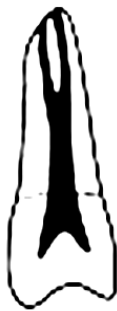**Type II**



**Type III**



**Type IV**



**Type V**



**Type VI**



**Type VII**



**Type VIII**

## APPENDIX IV: Letter of approval



Ref: KNH-ERC/ A/527

Dr. Katoto A.M.  
Dept. of Conservative and Prosthetic Dentistry  
School of Dental Sciences  
University of Nairobi

Dear Dr. Katoto

**RESEARCH PROPOSAL: "EXTERNAL AND INTERNAL ROOT MORPHOLOGY OF PERMANENT SECOND MOLARS OF A KENYAN POPULATION"**  
(P202/06/2010)

This is to inform you that the KNH/UON-Ethics & Research Committee has reviewed and approved your above cited research proposal for the period 15<sup>th</sup> July 2010 to 14<sup>th</sup> July 2011.

You will be required to request for a renewal of the approval if you intend to continue with the study beyond the deadline given. Clearance for export of biological specimens must also be obtained from KNH/UON-Ethics & Research Committee for each batch.

On behalf of the Committee, I wish you a fruitful research and look forward to receiving a summary of the research findings upon completion of the study.

This information will form part of the data base that will be consulted in future when processing related research study so as to minimize chances of study duplication.

Yours sincerely

**PROF A N GUANTAI**  
**SECRETARY, KNH/UON-ERC**

c.c. Prof. K. M. Bhatt, Chairperson, KNH/UON-ERC  
The Deputy Director CS, KNH  
The Dean, School of Dental Sciences, UON  
The HOD, Records, KNH  
Supervisors: Dr. Susan Maina, Dept. of Conservative and Prosthetic Dentistry, UON  
Dr. Fred Otieno, Dept. of Conservative and Prosthetic Dentistry, UON  
Dr. Anne Njiru, Dept. of Oral & Maxillofacial Surgery, UON

**KENYATTA NATIONAL HOSPITAL**  
Hospital Rd. along, Ngong Rd.  
P.O. Box 20723, Nairobi.  
Tel: 726300-9  
Fax: 725272  
Telegrams: MEDSUP, Nairobi.  
Email: [KNHplan@Ken.Healthnet.org](mailto:KNHplan@Ken.Healthnet.org)  
15<sup>th</sup> July 2010