



Pan African Urological Surgeons' Association

African Journal of Urology

www.ees.elsevier.com/afju
www.sciencedirect.com



Case report

Large aneurysm in renal angiomyolipoma causing life-threatening retroperitoneal hemorrhage



P.C. Magabe^{a,*}, W. Otele^b, L.M. Mugambi^c

^a Department of Radiology, Interventional Radiology Section, University of Nairobi, Kenyatta National Hospital, Kenya

^b Department of Urological Surgery, Kenyatta National Hospital, Kenya

^c Department of Radiology, Kenyatta National Hospital, Kenya

Received 8 March 2014; received in revised form 1st May 2014; accepted 17 May 2014

KEYWORDS

Aneurysm;
Angiomyolipoma;
Retroperitoneal
hemorrhage

Abstract

Large aneurysms occurring in renal angiomyolipomas (AML) may be encountered. When present, they have a higher propensity to hemorrhage and cause catastrophic intratumoral and perirenal hemorrhages. They also tend to occur more in tuberous sclerosis-associated AML rather than in the sporadic form. A 22-year-old female presented with sudden onset of acute right abdominal pain, hematuria and fainting. At evaluation in the emergency department, the patient was found to be in hemorrhagic shock with hemoglobin of 4 g/dl and low blood pressure of 60/40 mmHg. Fullness and tenderness of the right abdominal flank was also noted. Contrast enhanced CT scan of the abdomen showed a large fatty mass of the right kidney with a surrounding perirenal hematoma. A 4.0 cm wide focus of contrast was seen within the mass highly suspicious of an aneurysm. A subsequent DSA angiogram of the right kidney confirmed the presence of the aneurysm within the mass as the cause of the hemorrhage. The patient underwent successful emergency coil and particle embolization of the aneurysm and mass with control of the bleeding. The patient was diagnosed with tuberous sclerosis syndrome with further clinical findings of cutaneous adenoma sebaceum and lung cystic changes.

© 2014 Pan African Urological Surgeons' Association. Production and hosting by Elsevier B.V. All rights reserved.

Case report

A 22-year-old female presented to the emergency department with sudden onset of acute right abdominal pain associated with hematuria and fainting. At initial evaluation, the patient was found to be pale with a hemoglobin reading of 4 g/dl and a low blood pressure of 60/40 mmhg. There was also fullness and tenderness of the right abdominal flank. Emergency resuscitation for hemorrhagic shock

* Corresponding author.

E-mail addresses: cmagabe@yahoo.co.uk, pcmagabe@gmail.com (P.C. Magabe).

Peer review under responsibility of Pan African Urological Surgeons' Association.

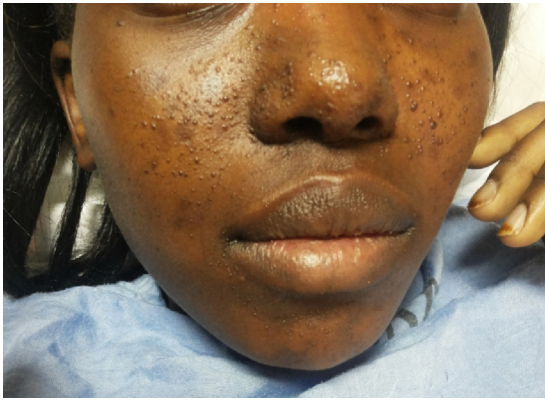

Figure 1 Close-up photograph of the patient's face showing multiple small cutaneous nodules with a predominantly malar distribution confirmed to be facial angiofibromas.

was commenced with IV fluids and transfusion of four units of whole blood. Once stable, the patient on further clinical evaluation was found to have multiple painless facial cutaneous nodules with malar distribution consistent with angiofibromas (Fig. 1). Pregnancy was excluded with negative results on a serum B HCG test. Contrast enhanced CT scan of the abdomen and chest showed a large fatty mass (–50 to –70 HU) arising from the upper and middle poles of

the right kidney. There was an associated large hyper dense perirenal hematoma (Fig. 2). A 4.0 cm lobulated focus of contrast was seen within the mass highly suspicious of an aneurysm (Fig. 3). Cystic lung changes were also noted. A subsequent DSA angiogram of the right kidney confirmed the presence of the aneurysm within the mass (Fig. 4), which was the cause of the hemorrhage.

She underwent emergency embolization of the aneurysm and right kidney AML mass with coils and poly vinyl alcohol (PVA) particles respectively, with successful obliteration of the aneurysmal sac and devascularization of the mass. She had an uneventful recovery in the ward and was discharged as stable for outpatient follow-up. She was diagnosed with tuberous sclerosis in view of the above-described findings of renal AML, cystic lung changes and cutaneous facial angiofibromas. Four months post-treatment the patient was readmitted with a large perirenal abscess as a complication of the embolization. This was surgically drained with good recovery post-operation.

Discussion

Renal angiomyolipoma (AML) is a benign renal neoplasm composed of variable amounts of fat, blood vessels and smooth muscle tissues originating from perivascular epithelial cells. The blood vessels in these tumors are angiomatous with abnormal thick walls and have a characteristic absence of elastic tissue. These features

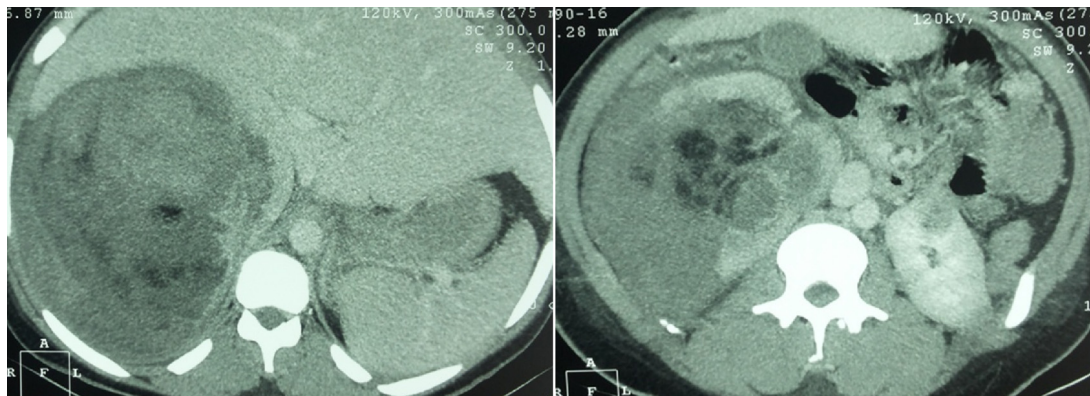


Figure 2 Contrast enhanced CT scan abdomen through the lower pole of the left kidney. An intrarenal mass with fatty hypo-attenuating components is seen. Sections through the upper pole (not shown) showed the larger extrarenal component of the mass.

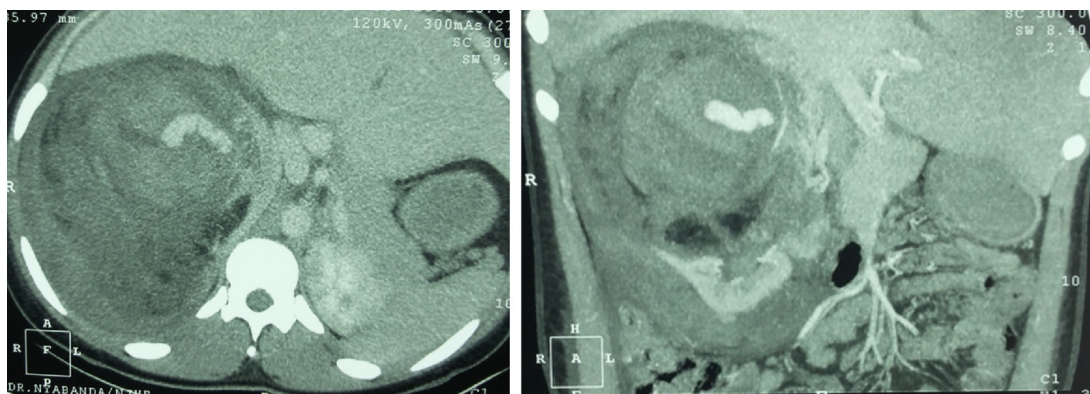


Figure 3 Coronal contrast CT abdomen shows a lobulated focus of hyper-attenuating contrast within the mass representing the pseudoaneurysm. Surrounding hyper-dense perirenal hematoma is also noted.

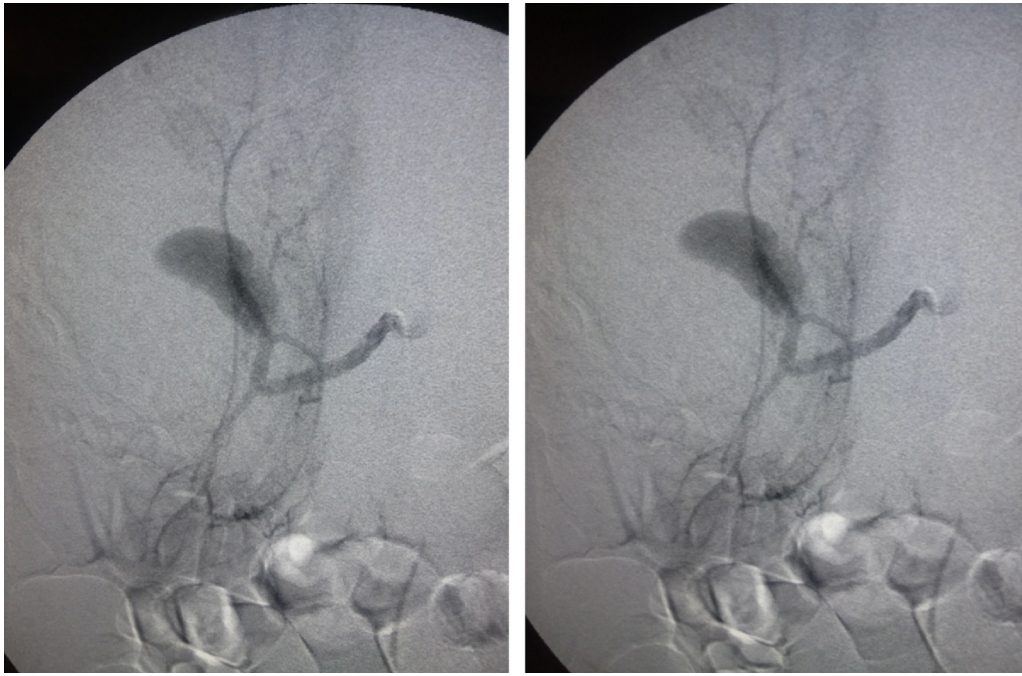


Figure 4 Conventional DSA angiogram of the right renal artery demonstrates the large 4.0 cm lobulated pseudoaneurysm arising from the middle pole segmental artery. The resultant hematoma compresses and splays the upper and lower pole renal arterial segmental branches.

increase the risk of aneurysms forming and these have higher rates of spontaneous hemorrhages.

The incidence of renal AML is approximately 0.3–3% [1]. Isolated sporadic renal AMLs are seen in 80% of cases and multiple AML lesions associated with tuberous sclerosis are seen in 20% of cases [2,3]. Approximately 50% of patients with tuberous sclerosis have AMLs that tend to be multiple and bilateral. These also grow faster and are more frequently associated with bleeding [4,5]. The female to male ratio of tuberous sclerosis-related AML is 2:1. The sporadic type AML ratio is higher at 4:1.

The clinical presentation of patients with renal AML is variable and is dependent on size, vascularity and presence of aneurysms within the mass lesion. Aneurysm formation appears to be related to tumor size [1]. The sizes of aneurysms reported in literature, however, have been largely less than 2 cm. In a series of 23 patients by Yamakado [6], the largest size was 1.33 cm. The presence of a larger aneurysm is a strong predictor of a potential life-threatening hemorrhage such as the patient presented and is recommended that immediate treatment be instituted once this is seen [7]. Previously, the main predictor for bleeding was the size of the AML with the risk of hemorrhage being significantly greater in AMLs larger than 4 cm [8]. Occasionally, the first clinical presentation of renal AML may be spontaneous non-traumatic renal hemorrhage confined to the sub-capsular and surrounding perirenal adipose tissue. This has been termed Wunderlich's syndrome, although many other causes exist for this syndrome [9].

Due to the tumor's fat components, a CT is useful for diagnosis and may in addition show the underlying cause of bleeding. Renal AML appears as a circumscribed hypo-attenuating fatty mass (–30 HU to –70 HU) in non-contrast CT images. Associated perirenal hemorrhage is usually hyper dense with an attenuation of up to 60–70 HU (Fig. 2). The aneurysm, if large, can be demonstrated in the contrast

images as a focus of hyper-attenuating contrast within the mass surrounded by the hematoma and hypo-attenuating fatty components (Fig. 3). Color Doppler US is, however, the best in demonstrating the aneurysm.

Management of renal AML is aimed at minimizing risks of hemorrhage while preserving the nephrons. Selective angiographic embolization (SAE) has been accepted as an alternative, minimally invasive, therapeutic approach with a similar long-term outcome [10–12]. This obviates the need for a radical or partial nephrectomy in patients with lesions less than 4 cm in stable AMLs. Excision in lesions larger than 4 cm, however, remains the definitive mode of treatment after initial embolization, especially in tuberous sclerosis-related AML. SAE alone was sufficient enough to obliterate the bleeding AML in the patient presented, who remained symptom free for the intermediate follow-up period thereafter. Patients with asymptomatic lesions require no treatment, although close follow-up is required for tuberous sclerosis-related AMLs.

In conclusion, spontaneous hemorrhage from an aneurysm in renal AML is potentially a life-threatening event. A quick assessment to verify vascularity of the mass and presence of an aneurysm is important for preventive treatment against catastrophic bleeding.

Conflict of interest

No conflict of interest noted by me or any of the authors. There are also no financial disclosures to make by any of the authors.

References

- [1] Zhang JQ, Fielding JR, Zou KH. Etiology of spontaneous perirenal hemorrhage: a meta-analysis. *Journal of Urology* 2002;167:1593–6.

- [2] Casper KA, Donnelly LF, Chen B, Bissler JJ. Tuberous sclerosis complex: renal imaging findings. *Radiology* 2002;225:451–6.
- [3] Rakowski SK, Winterkorn EB, Paul E, Steele DJ, Halpern EF, Thiele EA. Renal manifestations of tuberous sclerosis complex: incidence, prognosis, and predictive factors. *Kidney International* 2002;70:1777–82.
- [4] Nelson CP, Sanda MG. Contemporary diagnosis and management of renal angiomyolipoma. *Journal of Urology* 2002;168:1315–25.
- [5] Künzi T, Walther F, Marti HP, Frey FJ, Vogt B. Intrarenal arterial aneurysms with haematuria in a patient with tuberous sclerosis complex. *Nephrology Dialysis Transplantation* 2005;20:2268–70.
- [6] Yamakado K, Tanaka N, Nakagawa T, Kobayashi S, Yanagawa M, Takeda K. Renal angiomyolipoma: relationships between tumor size, aneurysm formation, and rupture. *Radiology* 2002;225(October (1)):78–82.
- [7] Koh KB, George J. Radiological parameters of bleeding renal angiomyolipoma. *Scandinavian Journal of Urology and Nephrology* 1996;30:26520.
- [8] Steiner MS, Goldman SM, Fishman EK, Marshall FF. The natural history of renal angiomyolipoma. *Journal of Urology* 1993;150:1782–8624.
- [9] Albi G, del Campo L, Tagarro D. Wunderlich's syndrome: causes, diagnosis and radiological management. *Clinical Radiology* 2002;57:840–5.
- [10] De Luca S, Terrone C, Rossetti SR. Management of renal angiomyolipoma: a report of 53 cases. *BJU International* 1999;83:215–8.
- [11] Rimon U, Duvdevani M, Garniek A, Golan G, Bensaid P, Ramon J, et al. Large renal angiomyolipomas: digital subtraction angiographic grading and presentation with bleeding. *Clinical Radiology* 2006;61:520–6.
- [12] Ramon J, Rimon U, Garniek A, Golan G, Bensaid P, Kitrey ND, et al. Renal angiomyolipoma: long-term results following selective arterial embolization. *European Urology* 2009;55:1155–61.