

Ocular findings in patients with head injury

Masila F¹, Kiboi J², Marco S³, Njuguna M³

¹PCEA Kikuyu Hospital, Kiambu, Kenya

²Department of Surgery-Neurosurgery, College of Health Sciences, University of Nairobi, Kenya

³Department of Ophthalmology, College of Health Sciences, University of Nairobi, Kenya

Corresponding author: Dr. F. Masila. Email: faithvata@yahoo.com

ABSTRACT

Objective: To describe the ocular and visual findings in patients with head injury.

Methods: A cross-sectional study of 147 patients with head injury was carried out at Kenyatta National Hospital, Nairobi, Kenya. Participants were recruited consecutively into the study and underwent a thorough ophthalmic and neurosurgical examination. Analysis was done for the age, sex, cause of head injury, in addition to visual and ocular findings. Analysis was done to determine if there was any correlation between ocular findings and the severity of head injury using the Glasgow Coma Scale (GCS), brain CT scan findings and fractures of the skull, orbit and face.

Results: The leading causes of head injury were road traffic accidents (44.9%) and assaults (42.2%). The patients comprised 136 males and 11 females. The age ranged from 18 to 77 years (mean=33.7 years). Ocular findings were observed in 101(68.7%) cases of head injury. These included lid laceration (8.9%), ecchymosis (36.1%), subconjunctival haemorrhage (13.9%), corneal epithelial defects (16.7%), corneal laceration (0.6%), scleral laceration (0.6%), traumatic cataract (1.1%), vitreous haemorrhage (1.1%), papilloedema (4.4%), optic atrophy (10.6%), retinal haemorrhage (5.6%), pupillary abnormalities (21.7%) and oculomotor nerve palsy (1.1%). Orbital fractures were found in nine patients. Visual impairment occurred in 52(29.2%) eyes. A positive correlation was seen between severe head injury (GCS <8) and occurrence of ocular signs. There was no correlation observed between ocular findings and intracranial haemorrhage, pneumocephalus, brain oedema and infarctions seen on brain CT scan. There was no correlation seen between ocular findings and fractures of the skull and facial bones.

Conclusion: Various forms of injury occur to the ocular and visual system in patients with head injury.

Key words: Ocular and visual findings, Head injury

INTRODUCTION

Head injury is a common cause of death and major disabilities in trauma patients. After moderate to severe injury the disability is frequently characterized by a combination of physical and cognitive defects¹. The visual system is one of the systems involved in Traumatic Brain Injury (TBI). The eye is frequently involved in head trauma due to proximity of the eye to the head as well as due to the neural connections between the eye and the brain. Many theories have been proposed of how the eye is injured in traumatic brain injury. In penetrating brain injury, there may be physical damage to the visual pathway, visual cortex, and/or other vision-related structures of the brain. In non-penetrating or closed-head injury, displacement, stretching, and shearing forces may damage areas of the brain, including those associated with vision². Direct ocular trauma also contributes to the visual dysfunction in patients with head injury.

There has been scanty documentation regarding the ophthalmic manifestations of head injury

in many trauma centres. There are several services (neurosurgery, otolaryngology, plastic surgery, general surgery and ophthalmology) with varied ophthalmologic interest and training, assessing these cases. A number of potential eye injuries may be escaping ophthalmologic assessment³. Early diagnosis of visual problems following traumatic brain injury is essential to maximize the overall rehabilitation potential⁴. The aim of this study is to describe the spectrum of ocular and visual defects seen in patients with head injury.

MATERIALS AND METHODS

A cross-sectional study of 147 patients admitted with head injury at Kenyatta National Hospital, Nairobi, Kenya, a national teaching and referral hospital was carried out in April 2012. Patients were recruited consecutively with a diagnosis of head injury by the neurosurgical team on basis of history, neurological findings, admission Glasgow Coma Scale (GCS) and brain CT scan findings. Inclusion criteria consisted of adult patients (18 years and above) admitted with

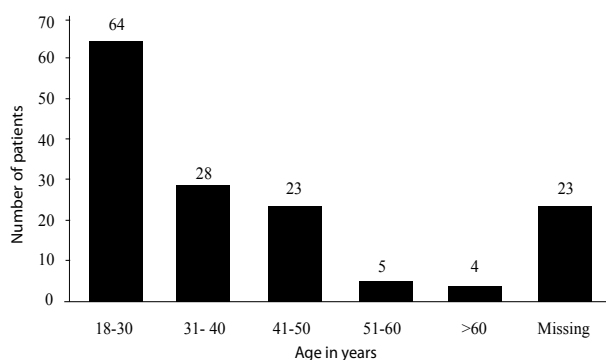
a diagnosis of head injury within 1 week of injury. Exclusion criteria included patients with head injury less than 18 years of age and those presenting with head injury more than 1 week after the injury. Ophthalmic assessment was carried out in all patients within 1 week of admission into the hospital by the ophthalmologist. Visual acuity was assessed using the LogMAR chart at 3m. A detailed ophthalmic examination was carried out. All ophthalmic and neurological findings were transferred into a questionnaire including the patients' demographic data and cause of head injury. Analysis was done using Statistical Package for Social Scientists (SPSS) version 17.0 software. Ocular findings were associated with neurological findings of the patients using Chi square test of associations. Patients were managed according to their respective diagnoses by the neurosurgical and ophthalmologic units.

RESULTS

One hundred and sixty-three patients were recruited into the study. Sixteen patients were excluded; seven patients were excluded as they had head injury for more than 1 week and had been admitted to the surgical ward after transfer from the Intensive Care Unit and nine patients were excluded as they had coma resulting from medical illness initially thought to be due to head injury. One hundred and forty seven patients were included in the analysis.

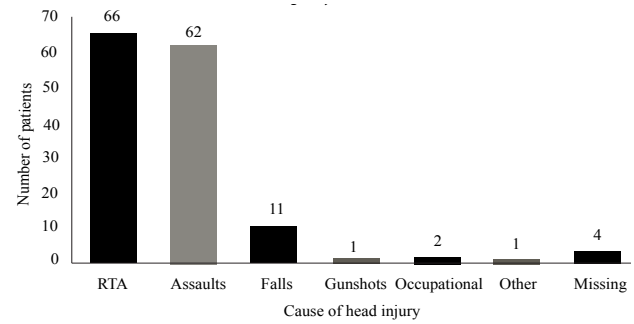
There were 136(92.5%) males and 11(7.5%) females giving a male to female ratio of 12:1. The mean age of the patients was 33.7 years, standard deviation 12.1. Majority of the patients were young adults, 64 (43.5%) in the age group 18-30 years (Figure 1).

Figure 1: Distribution of patients by age (n=147)



The causes of head injury are shown in Figure 2. The commonest causes of head injury were road traffic accidents 66(44.9%) and assaults 62(42.2%). Majority of the assaults occurred in males. In this study only one female patient had head injury due to assault. The rest of the causes of head injury included occupational injury 2(1.4%), gunshot injury 1(0.7%) and others 1(0.7%).

Figure 2: Causes of head injury (n=147)



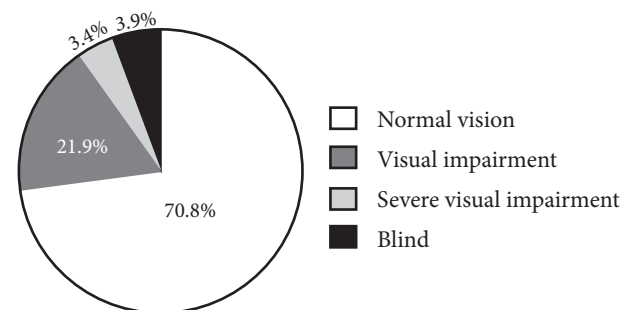
Ophthalmic complaints were reported in 24(27%) patients out of 89 patients who were conscious (Table 1). The most common complaint was eye pain. Other complaints reported were itching, tearing and foreign body sensation.

Table 1: History of ophthalmic complaints (n=89)

Major ophthalmic complaint	Frequency	(%)
Pain	11	12.4
Reduced or loss of vision	7	7.9
Swelling	3	3.4
Other	4	4.5
None	65	73.0
Total	89	100

Visual acuity was taken in 89 patients (178 eyes) who were conscious. Majority of the eyes, 126 (70.8%) had normal vision. A total of 52 eyes (29.2%) had impaired vision (Figure 3).

Figure 3: Visual acuity (LogMAR) per eye (n=178 eyes)



Ocular findings were present in 101(68.7%) patients with head injury. Ocular findings were present in 101 patients (202 eyes examined) of whom 180 eyes had findings (Table 2). The commonest findings were in the ocular adnexae with ecchymosis occurring most frequently, in 65(36.1%) eyes. In the anterior segment, corneal epithelial defects (superficial punctate erosions and epithelial defects) were the most frequent finding and occurred in 30(16.7%) eyes. In the posterior segment, the most common findings were optic atrophy and retinal haemorrhages in 19 and 10 eyes respectively.

Table 2: Ocular findings per eye (n=180 eyes)

Ocular diagnosis	Frequency	(%)
Ocular adnexae		
Ecchymosis	65	36.1
Lid laceration	16	8.9
Subconjunctival haemorrhage	25	13.9
Chemosis	13	7.2
Infectious conjunctivitis	20	11.1
Anterior segment		
Corneal epithelial defects	30	16.7
Corneal laceration	1	0.6
Scleral laceration	1	0.6
Iris sphincter tears	3	1.7
Traumatic cataract	2	1.1
Posterior segment		
Vitreous haemorrhage	2	1.1
Papilloedema	8	4.4
Optic atrophy	19	10.6
Retinal haemorrhage	10	5.6
Retinal detachment	1	0.6
Comotio retinae	2	1.1
Choroidal rupture	2	1.1
Macula hole/scar	2	1.1
Neuro-ophthalmic		
Pupillary abnormalities	39	21.7
3 rd nerve palsy	2	1.1
Orbital fractures	9	5

Among the neuro-ophthalmic complications, pupillary abnormalities were found in 39 eyes. Two patients had oculomotor nerve palsy with restriction of extraocular motility and strabismus. The patients had other features of 3rd nerve palsy- ptosis and pupillary dilatation. Orbital fractures were seen in nine patients. In our study none of the orbital fractures were associated with enophthalmos or extraocular muscle entrapment. From our study there is a positive correlation between severe head injury (GCS <8) and occurrence of ocular signs (p value 0.05) (Table 3).

Table 3: Correlation of ocular signs with the severity of head injury(Glasgow Coma Scale)

Surgical diagnosis	Presence of ocular findings		OR (95% CI)	P value
	Yes	No		
GCS 13-15 (Mild)	40 (41.2%)	28 (57.1%)	1.0	
GCS 9-12 (Moderate)	22 (22.7%)	10 (20.4%)	1.5 (0.6-3.8)	0.342
GCS <8 (Severe)	35 (36.1%)	11 (22.4%)	2.2 (1.0-5.1)	0.05

There was no statistically significant association between ocular findings with the findings on brain CT scan and fractures of the skull, orbit and face (Table 4).

Table 4: Correlation of ocular signs with brain CT scan findings and fractures

CT scan findings	Presence of ocular findings		OR (95% CI)	P value
	Yes	No		
Intracranial haemorrhage	43 (46.2%)	17(38.6%)	1.4 (0.7-2.8)	0.402
Brain oedema	29 (31.5%)	9 (20.9%)	1.7 (0.8-4.1)	0.202
Brain infarctions	3 (3.3%)	1 (2.3%)	1.4 (0.1-14.2)	1.000
Pneumocephalus	8 (8.8%)	2 (4.5%)	2.0 (0.4-10.0)	0.498
Fractures				
Skull base fracture	9 (9.5%)	2 (4.7%)	2.1 (0.4-10.4)	0.502
Calvarial fracture	36 (37.9%)	12 (27.3%)	1.6 (0.7-3.6)	0.221
Facial fracture	10 (10.6%)	1 (2.3%)	5.8 (0.7-46.4)	0.097

DISCUSSION

Head injury is an important public health problem⁵. It is defined as trauma leading to brain injury, skull fractures and scalp injury. It includes open or closed head injuries resulting in impairments in cognition, language, memory, attention, reasoning, abstract thinking, judgement, problem-solving, sensory, perceptual and motor abilities and behaviour, but it does not include brain injuries that are congenital, degenerative or induced by birth trauma^{6,7}. The incidence of head injury in the US is 403 per 100 000 population^{8,9}. In Germany it was 332 cases of Traumatic Brain Injury (TBI) per 100 000 head of population per year and in children (younger than 16 years) the incidence was 581 cases of TBI per 100 000 inhabitants¹⁰. In South Africa, the prevalence of traumatic brain injury was 316 cases per 100 000 per head of population per year¹¹.

The most common causes of head injury in our study were road traffic accidents and assaults, followed by falls from a height. Other studies have shown road traffic accidents to be a leading cause of head injury. Severity of head injury has been correlated directly to lack of proper seatbelt or helmet use⁴.

In our study, majority of the head injury patients (92.5%) were males. Pelletier *et al*³ and Kulkarni *et al*¹² found 97% males and 3% females and 81% males and 19% females, respectively. The higher incidence in males seen in our study and various studies indicate men are more likely to engage in risk taking behaviors and which put them at a higher risk of head injury. Alcohol is a significant contributing factor in men^{13,14}. Since more

males operate motor vehicles, road traffic accidents lead to more head injury in this population.

Ophthalmic complaints were reported in 24(27%) patients in our study. In a study by Brahm *et al*¹³ in the USA, 75.4% of all inpatients (with moderate to severe head injury) had subjective complaints. Among the outpatients (with mild head injury) subjective visual complaints were reported in 75.8%. Other visual complaints that may occur in the patient with head trauma include difficulty reading, photophobia, visual hallucinations, phosphenes, visual field defects, visual cognition deficits, visual inattention and visual perceptual-motor dysfunction (such as impaired spatial relationships and right-left discrimination problems)¹⁴. Visual abnormalities that follow head trauma occur commonly and can involve any part of the visual pathway¹⁴. They may be monocular or binocular. In our study majority of the eyes, 126(70.8%) had normal vision (LogMAR 0.0-0.5). Brahm *et al*¹³ found that of the inpatients (with moderate to severe head injury), 77.8% had a visual acuity of 20/60 or better, 6.3% had visual acuity of 20/70-20/100, 12.7% had a visual acuity of worse than 20/100 and 3.2% had no light perception in both eyes. Of the outpatients (with mild head injury), 98.4% had a visual acuity of 20/60 or better, 1.6% had a visual acuity worse than 20/100, no patient had a visual acuity between 20/70-20/100 and no light perception¹³. This showed a majority of patients in both the inpatient and outpatient populations had normal to near-normal acuities similar to our study.

The prevalence of ocular findings in our study was 68%. Kulkarni *et al*¹² found a higher prevalence of ocular involvement of 83.5% in closed head injury patients. Kowal¹⁴ found a lower estimate in the range of 30-50% of closed head injury patients who had visual signs and symptoms. Studies show that higher incidences of ocular findings are found when ophthalmologists participate in the examination of head injury patients¹⁵. This implies that there are certain ocular defects which may be missed by other medical personnel who examine the eye in head injury patients. Pelletier *et al*³ showed that data lacking in the visual assessment of head and neck trauma patients were visual acuity, pupillary reaction, motility assessment, lid function, integrity of the globe and funduscopy. Jabaley *et al*¹⁵ reported the incidence of ocular injury in patients with facial fractures through a retrospective study and a prospective one. In the retrospective study, ophthalmology consultation was decided upon

by the admitting plastic surgeon. The results showed 11% had an ocular injury. In the prospective study, all patients with fracture diagnosis were seen by an ophthalmologist, 29% had signs of ocular injury.

Physical ocular trauma is a common finding in head injured patients¹⁶. It is due to direct trauma to the ocular contents and involves injury to the ocular adnexae, anterior and posterior segments of the globe. Ecchymosis and subconjunctival haemorrhage are the commonest findings seen in the ocular adnexae. Corneal and scleral lacerations, traumatic cataract are seen frequently in the anterior segment. Posterior segment manifestations include vitreous haemorrhage, retinal haemorrhage, retinal detachment, macular hole, optic atrophy all of which were seen in our study.

Among the neuro-ophthalmic complications, pupillary abnormalities were a common finding. Causes of fixed and dilated pupils in the head injury patient include transtentorial/uncal herniation (Hutchinson's pupillary signs), traumatic 3rd nerve palsy (which occurred in two patients in our study), traumatic mydriasis and orbital blow-out fracture (the latter two were not found in our study). In head injury patients causes of pin-point pupils include Horner's syndrome, traumatic miosis, pontine hemorrhage and Hutchinson's pupil (early stages of transtentorial herniation)¹⁴.

Papilloedema is a common neuro-ophthalmic complication. Papilloedema occurring within 48 hours indicates extra or intracerebral haemorrhage and is an indication for immediate surgical measures. Papilloedema occurring after 1 week of head injury is usually due to cerebral oedema¹⁶.

There was restriction of extraocular motility and strabismus in two patients in our study. Both were due to 3rd nerve palsy and the patients had other features of 3rd nerve palsy- ptosis and pupillary dilatation. Ocular motor cranial nerve palsy leading to motility disorders is a frequently encountered neuro-ophthalmic complication. The cranial nerves are susceptible to injury because of their long course at the base of the skull¹⁴. In a study by Kowal¹⁴ 70 of 164 patients with head injury had cranial nerve palsies, 16 of these had third nerve palsy, 38 had fourth nerve palsy and 16 had sixth nerve palsy. Accurate ocular motility assessment within the first few hours of head injury is not possible with patients in coma. Many signs and symptoms like third nerve misdirection arise a few months after trauma¹⁷. Lagophthalmos may occur in the head injury patient due to facial nerve palsy. In fractures of the

base of the skull the most common cranial nerve palsy is ipsilateral facial nerve paralysis of the lower motor neuron type¹⁶. We did not find any patient with facial nerve paralysis in our study.

Strabismus occurs in head injury due to ocular motor cranial nerve palsies or injury to extraocular muscles eg muscle entrapment in orbital fractures. Ciuffreda *et al*¹⁸ found strabismus in 25%. In a study by Kowal¹⁴, 10 patients had exotropia and 3 had esotropia. Esophoria and exotropia are a common sequelae of head trauma. Binocular single vision may be lost after a head injury, with the breakdown of a latent phoria or loss of the normal physiological fusion of the image presented to each eye.

There was no patient who had diplopia, proptosis or nystagmus in our study. Diplopia is a finding frequently encountered in head injury patients¹⁴. Patients may complain of double vision after discharge from hospital as seen in other studies and it is possible that the head injury patients seen in this study may present later with diplopia after discharge from hospital. In a study by Odebode *et al*¹⁹, four patients complained of double vision, shortly after discharge from the hospital. In a study by Kulkarni *et al*¹², seven patients sought ophthalmic opinion for diplopia within a month of being discharged after their head injury. Most cases of diplopia resolve spontaneously in 6-12 months after the head trauma⁵.

Oscillopsia is a symptom that may occur in the head injury patient. Nystagmus in head injury may occur as a result of internuclear ophthalmoplegia. It may also result from trauma to the optic chiasm which simulates a pituitary region tumor with see-saw nystagmus⁵.

Optic atrophy was seen in 19 eyes in our study, which is an indicator of optic neuropathy. It is likely that the optic atrophy was pre-existing prior to the head trauma. Kowal¹⁴ reported severe optic atrophy in nine patients (who had visual acuities of 6/60 to no light perception with marked disc pallor) and mild optic atrophy in 33 patients (who had acuities better than 6/12). Moster *et al*²⁰ reported traumatic optic neuropathy in 18%. Traumatic optic nerve damage may result from direct trauma to the nerve as a result of mechanical compression from a fracture fragment or indirect damage from oedema or ischaemia. Spontaneous improvement occurs in 15-33%. If due to mechanical compression from fracture fragment, CT scan is good for diagnosis as it reveals bony fragments and surgical decompression may be undertaken via intranasal or

trans-ethmoidal or trans-sphenoidal approach. If due to indirect damage from edema or ischemia, MRI is better for diagnosis. High dose steroids have been advocated due to their antioxidant effect and to maintain perfusion in indirect damage¹⁹. In our study, there was no patient with cerebral (cortical) blindness unlike Banks *et al*²¹ who reported cortical blindness in 0.4-0.6%.

Orbital fractures were seen in nine patients. In our study none of the orbital fractures were associated with enophthalmos or extraocular muscle entrapment. There was no orbital blow out fracture seen in our study. None of the orbital fractures were associated with globe rupture. Odebode *et al*¹⁹ reported globe ruptures in two patients with concomitant comminuted fracture of the orbit. Optic canal fracture often associated with basilar skull fracture can produce an optic neuropathy.

From our study there is a positive correlation between severe head injury (GCS <8) and occurrence of ocular signs (p value 0.05). A study by Odebode *et al*¹⁹ showed nearly half of the ocular and visual injuries occurred in mildly head-injured patients with GCS of 13–15. Severe ocular injury was associated with severe head injury whose GCS was less than or equal to 8 on admission.

There was no statistically significant association between ocular findings with the findings of intracranial haemorrhage, pneumocephalus, brain oedema and infarctions seen on brain CT scan. There was no statistically significant association between fractures of the skull and facial bones with the ocular findings. A study with a larger sample size could possibly show an association between ocular findings and neurological findings.

Comprehensive examination of the patients with head trauma was limited due to the patients' consciousness level. In patients with markedly reduced levels of consciousness, some aspects of the ocular examination were not carried out such as visual acuity, assessment of strabismus, nystagmus and diplopia test. There was difficulty or inability to obtain ophthalmic history in some moderate to severe head injury patients.

The visual system impacts all aspects of life. Rehabilitation of the head injury patient is much more difficult if the visual system is not efficient. Head injury patients may be difficult to examine because of cognitive and communication disorders. Multiple examinations may be needed to assess fully a brain-injured patient. A complete assessment may include evaluation of the eye, refraction, and examination

of ocular motility, accommodation, vergence, stereopsis, visual perception, and visual fields²². Vision examinations and treatment may facilitate TBI patient rehabilitation including reading, speech and language deficits, vestibular function, mobility, driving, and other activities in which the visual system plays a role¹³.

CONCLUSION

Various forms of injury can occur to the ocular and visual system in patients with head injury, some leading to various degrees of visual impairment including blindness.

RECOMMENDATION

There should be a detailed early ophthalmological assessment in all patients with head injury to prevent the sequelae of injury to the eye which may lead to loss of vision.

ACKNOWLEDGMENTS

Special thanks to Kenyatta National Hospital for approval to carry out the study and staff at the hospital for their assistance, Faculty members, MMed ophthalmology residents and other staff at the University of Nairobi, Department of Ophthalmology for their various contributions. Further appreciation to Light For The World (LFTW) for providing funding to carry out the study.

REFERENCES

- Margaret C. Stratton, Robert J. Gregory. After traumatic brain injury: a discussion of consequences. *Brain Injury*. 1994; **8**(7): 631-645.
- Taber KH, Warden DL, Hurley RA. Blast-related traumatic brain injury: what is known? *J Neuropsychiatry Clin Neurosci*. 2006; **18**: 141-145.
- Pelletier, Conrad R. MD. Assessment of ocular trauma associated with head and neck injuries. *J Trauma*. 1998; **44**(2):350-354.
- Sabates N.R., Gonce M.A., Farris B.K. Neuro-ophthalmological findings in closed head trauma. *J Clin Neuro-Ophthalmol*. 1991; **11**:273-277.
- Yanoff Myron, Jay S Duker. *Yanoff & Duker: Ophthalmology* 3rd Edition.
- Brain resource information network. *About traumatic brain injury*. Available online at: <http://www.tndisability.org/brain/> About-traumatic-brain-injury.php, accessed 15 May 2011.
- Individuals with Disabilities Education Act: *Special education lawyers protecting your child educational right. Disabilities under I.D.E.A.* Available online at: <http://www.specialeducationlawyers.info/disabilities.htm>, accessed 15 May 2011.
- Langlois JA, Rutland-Brown W, Thomas KE. The incidence of traumatic brain injury among children in the United States: differences by race. *J Head Trauma Rehab*. 2005; **20**(3):229-238.
- Keris V, Lavendelsi E, Macane I. Association between implementation of clinical practice guidelines and outcome for traumatic brain injury. *World J Surg*. 2007; **31**: 1354-1357.
- Eckhard Rickels, Klaus von wild, Paul Wenzlaff. Head injury in Germany: A population-based prospective study on epidemiology, causes, treatment and outcome of all degrees of head-injury severity in two distinct areas. *Brain Injury*. 2010; **24**(12): 1491-1504.
- Nell V, Ormond-Brown S. Epidemiology of traumatic brain injury in Johannesburg – II morbidity, mortality and etiology. *Social Sci Med*. 1991; **33**(3):289 – 296.
- Kulkarni AR, Aggarwal SP. Ocular manifestations of head injury: A clinical study. *Eye (London)*. 2005; **19**(12):1257-1263.
- Karen D. Brahm. Visual impairment and dysfunction in combat-injured service members with traumatic brain injury. *Optometry Vision Sci*. 2009; **86**(7PP): 817-825.
- Kowal L. Ophthalmic manifestations of head injury: *Austra New Zealand J Ophthalmol*. 1992; **20**: 35-40.
- Jabaley ME, Lerman M, Sanders HJ. Ocular injuries in orbital fractures: a review of 119 cases. *Plast Reconstr Surg*. 1975; **56**: 410-417.
- Khurana AK. *Comprehensive Ophthalmology* 4th Edition.
- Smith JL. Some neuro-ophthalmological aspects of head trauma. *Clin Neurosurg*. 1966; **13**: 181- 196.

18. Ciuffreda KJ, Kapoor N, Rutner D, Suchoff IB, Han ME, Craig S. Occurrence of oculomotor dysfunctions in acquired brain injury: a retrospective analysis. *Optometry*. 2007; **78**: 155–161.
19. Odebode TO, Ademola-Popoola DS, Ojo TA, Ayanniyi AA. Ocular and visual complications of head injury. *Eye*. 2005; **19**: 561–566.
20. Moster ML, Volpe NJ, Kresloff MS. Neuro-ophthalmic findings in head injury. *Neurol*. 1999; **52**(2): A23.
21. Banks M, Lessell, Simmons MD. Neuro-ophthalmology and trauma. *Int Ophthalmol Clin Ocular Trauma*. 2002; **42**(3): 1–12.
22. Falk NS, Aksionoff EB. The primary care optometric evaluation of the traumatic brain injury patient. *J Am Optom Assoc*. 1992; **63**:547-553.