

**OUTCOME OF MACULAR HOLE SURGERY
AT KIKUYU EYE UNIT**

A dissertation submitted in part fulfillment for the degree of
Master of Medicine (Ophthalmology), University of Nairobi 2014.

DR MUFADDAL FAKHRUDDIN KUDRATI

M.B.Ch.B (UON)

DECLARATION

This dissertation proposal is my original work and has not been presented for a degree at any other university.

Signed:

Date:

Dr. Mufaddal Fakhruddin Kudrati

MBChB (UON)

SUPERVISORS APPROVAL

This dissertation proposal has been submitted with our approval as supervisors.

Dr. KARIUKI M.M.

MBChB, MMed Ophthalmology (Nairobi), FEACO (E.A)

Senior lecturer, Department of Ophthalmology,

University of Nairobi.

Signed:

Date:

Dr. KIMANI K.

MBChB, MMed Ophthalmology (Nairobi), MSc CEH (London), FEACO (E.A)

Senior lecturer, Department of Ophthalmology,

University of Nairobi.

Signed:

Date:

Dr. JAFFERJI S.S.

MBChB, MMed Ophthalmology (Nairobi),

Consultant Ophthalmologist / Vitreoretinal Surgeon

Kikuyu Eye Unit.

Signed:

Date:

TABLE OF CONTENTS

TITLE PAGE

DECLARATION.....	i
SUPERVISORS APPROVAL	ii
TABLE OF CONTENTS.....	iii
DEDICATION.....	iv
ACKNOWLEDGEMENT.....	v
ABBREVIATIONS	vi
LIST OF TABLES AND FIGURES	viii
ABSTRACT	ix
1.0 LITERATURE REVIEW	1
1.1 INTRODUCTION	1
1.2 MANAGEMENT: MACULAR HOLE SURGERY	6
1.3 OUTCOME OF MACULAR HOLE SURGERY	8
2.0 STUDY RATIONALE	12
3.0 OBJECTIVES	13
3.1 MAIN OBJECTIVE	13
3.2 SPECIFIC OBJECTIVES	13
4.0 METHODOLOGY	14
4.1 STUDY DESIGN	14
4.2 STUDY LOCATION	14
4.3 STUDY POPULATION	15
4.4 EXCLUSION CRITERIA	15
4.5 STUDY PERIOD	15
4.6 STUDY MATERIALS	16
4.7 DATA COLLECTION AND ANALYSIS	16
4.8 STUDY LIMITATIONS.....	17
4.9 ETHICAL CONSIDERATIONS	17
5.0 RESULTS	18
6.0 DISCUSSION	33
7.0 CONCLUSION	38
8.0 RECOMMENDATIONS	39
REFERENCES	40
APPENDIX.....	44
I.QUESTIONNAIRE.....	44
II.MACULAR HOLE SURGERY: PROCEDURE AS DONE AT KEU	49

DEDICATION.

To my father who spent his life guiding me at every step, leading by example and helping me become the person I am today.

To my mum and my wife who have stood by me through everything; for their love, prayers, undying support and numerous sacrifices for my success.

To my son who has been a source of unending joy and inspiration for me to go on in spite of all the challenges.

To my brother, sister and all my family members for their constant encouragement and support.

ACKNOWLEDGEMENT.

I wish to acknowledge the following persons for their invaluable support and guidance towards my dissertation.

My supervisors, Dr.Kariuki.M., Dr.Kimani.K. and Dr.Jafferji S.S. for their unparalleled assistance and tireless guidance throughout this dissertation.

P.C.E.A. Kikuyu Hospital, through Dr.Mbongo for allowing me to carry out this study.

Dr.Gichuhi S and Dr.Gachago M for their valuable input.

Mr.Gabriel Otieno for his help in the statistical analysis.

I also wish to thank Light For The World (LFTW) through the Department of Ophthalmology, University of Nairobi for providing sponsorship for my dissertation.

ABBREVIATIONS

AAO	American Academy of Ophthalmology
ARMD	Age Related Macular Degeneration
BBG	Brilliant Blue G
BCVA	Best Corrected Visual Acuity
C ₂ F ₆	Hexafluoroethane
C ₃ F ₈	Perfluoropropane
CME	Cystoid Macular Edema
CNV	Choroidal Neovascularisation
CRAO	Central Retinal Artery Occlusion
CSME	Clinically Significant Macular Edema
ERC	Ethics and Research Committee
ERM	Epiretinal Membrane
FA	Fluorescein Angiography
FGE	Fluid Gas Exchange
FTMH	Full Thickness Macular Hole
HST	Horse Shoe Tear
ICG	Indocyanine Green
ILM	Internal Limiting Membrane
IMH	Idiopathic Macular Hole
IOP	Intraocular Pressure
KEU	Kikuyu Eye Unit
KNH	Kenyatta National Hospital
LASIK	Laser Assisted in situ Keratomileusis
OCT	Optical Coherence Tomography
PCEA	Presbyterian Church of East Africa
PDR	Proliferative Diabetic Retinopathy

PPV	Pars Plana Vitrectomy
PVD	Posterior Vitreous Detachment
RD	Retinal Detachment
RPE	Retinal Pigment Epithelium
SF ₆	Sulfur Hexafluoride
Sio	Silicone Oil
TA	Triamcinolone Acetonide
UON	University of Nairobi
VH	Vitreous Hemorrhage
VMA	Vitreomacular Adhesion
VMI	Vitreomacular Interface
VMT	Vitreomacular Traction
VMHS	Vitrectomy for Macular Hole Study

LIST OF TABLES AND FIGURES

TABLES

Table 1: Staging of Macular Holes	3
Table 2: Other co-existing ocular findings.....	23
Table 3: Surgical technique	24
Table 4: Intra-operative complications	24
Table 5: Outcome of surgery depending on cause of macular hole.....	28
Table 6: Association between symptoms duration and outcome of macular hole surgery	29
Table 7: Association between hole size and outcome of macular hole surgery	30
Table 8: Outcome of macular hole surgery dependant on Type of surgical technique: For large macular holes ($\geq 400\mu\text{m}$)	31
Table 9: Outcome of macular hole surgery dependant on Type of surgical technique: For old macular holes (≥ 6 months duration)	31
Table 10: Further interventions required	32

LIST OF FIGURES

Figure 1: Location of KEU, it's environ and route from Nairobi.....	14
Figure 2: Outline of stages in preparation of dissertation.....	15
Figure 3: Study flow chart.....	18
Figure 4: Age of presentation	19
Figure 5: Laterality	20
Figure 6: Cause of macular hole	20
Figure 7: Duration of symptoms	21
Figure 8: Pre operative BCVA in affected eye.....	21
Figure 9: Size of macular holes	22
Figure 10: Macular hole assessment method used.....	22
Figure 11: Delay between diagnosis and surgery.....	23
Figure 12: Follow up period	25
Figure 13: Anatomic outcome	26
Figure 14: Type of hole closure	26
Figure 15: Visual outcome at different periods post operatively.....	27
Figure 16: Visual outcome at last follow up visit.....	28
Figure 17: Post-operative complications	32

ABSTRACT

Purpose: To determine the outcome for Macular Hole surgery at Kikuyu Eye Unit (KEU).

Method: This was a retrospective hospital based case series conducted at Kikuyu Eye Unit. Records of all patients who underwent macular hole surgery at KEU between January 2008 and July 2013 were accessed and data related to demography, pre-operative evaluation, surgical details, post-operative follow up and complications was retrieved. The main outcome measures were hole closure rates, visual outcome after surgery and complications of macular hole surgery.

Results: A total of 57 eyes of 54 patients who had macular hole surgery were included. The median age of the patients was 62 years (range 13-82 years) and the female to male ratio was 1.1: 1. Most of the holes were idiopathic (87.7%) while the rest were traumatic. The patients had a mean duration of symptoms of 13.7 months, SD 15.79 (range 1 week-5 years) and the average delay between diagnosis and surgery was 2.4 months, SD 2.15 (range 1 week-3 months). The mean hole size was 578 μ m, SD 230.14 (range 200-1100 μ m).

46 eyes (80.7%) underwent standard ILM (internal limiting membrane) peeling while 11 eyes (19.3%) underwent ILM peel with inverted flap technique. All the eyes were followed up for at least 1 month post operatively with 93% follow up rate at 3 months, 63% at 6 months and 36% at 1 year.

94.7% of eyes had anatomical closure, 83% of which were type 1 closures. 68.42% of the eyes had visual improvement of ≥ 2 Snellen lines, 15.8% had their pre-op vision preserved while vision deteriorated in 3 eyes.

All the holes which failed to close were $> 400\mu$ m in size and of > 6 months duration.

Inverted flap technique had better visual outcome for holes $\geq 400\mu$ m ($p=0.007$) and ≥ 6 months duration ($p=0.0045$) compared to standard ILM peel alone.

Cataract occurred in 44.68% of phakic eyes at a mean of 16 weeks post macular hole surgery. Increase in IOP was seen in 12.28% of eyes at a mean of 1.2 weeks after surgery. Other complications included retinal break, localized retinal detachment.

Conclusion: Macular hole surgery was associated with very successful outcomes in a majority of patients including traumatic holes. The anatomic outcome was better than the visual outcome with 94.7% achieving anatomic closure compared to 68.42% having visual improvement.

ILM peel with inverted flap technique was associated with better outcomes in older and larger holes compared to standard ILM peel alone.

The commonest complication post macular hole surgery was cataract followed by increased IOP.

1.0 LITERATURE REVIEW

1.1 INTRODUCTION

1.1.1 DEFINITION

A macular hole is a defect at the fovea with interruption of all retinal layers (except stage 1A and 1B) from the internal limiting membrane (ILM) up to the Retinal Pigment Epithelium (RPE).¹

1.1.2 EPIDEMIOLOGY

Idiopathic macular hole (IMH) is a disease usually presenting in the 6th – 7th decade of life more commonly in women^{2,3} with a reported prevalence of between 0.14% - 0.3% in different populations.^{4,5,6}

Data gathered over 8years in the United Kingdom National Ophthalmology Database study of vitreoretinal surgery, reported a Female to Male ratio of 2.2:1 with a median age of patients of 70.3 years.²

A study by Sen P *et al* found the prevalence of IMH in an Indian population to be 0.17% with a mean age of 67years,⁵ while a population based study in the USA found a prevalence of 3.3 per 1000 in persons over 55 years.⁶

1.1.3 CAUSES OF MACULAR HOLES

Vast majority of macular holes are idiopathic⁷ occurring in previously normal eyes. Occasionally, they have been reported secondary to other ocular conditions like high myopia, ocular trauma, proliferative sickle cell retinopathy, proliferative diabetic retinopathy (PDR) and retinitis pigmentosa .^{7,8,9}

Case reports also exist of macular hole in patients with macular haemorrhage associated with rupture of retinal arterial macroaneurysm , atrophic stage of choroidal neovascularisation (CNV) and secondary to sclopetaria.¹⁰⁻¹²

Macular holes may also occur following interventions like, vitrectomy, Laser assisted in situ Keratomileusis(LASIK) and as a rare complication of cataract surgery.¹³⁻¹⁵

1.1.4 PATHOGENESIS AND STAGING.

The pathogenesis and classification of macular hole was first described by Gass J.D and has been refined over the years.^{7, 16, 17}

The pathogenesis of IMH is still not completely understood but with emergence of technology like Optical Coherence Tomography (OCT) which enable images of precursor lesions and their progression, possible mechanisms and underlying intraocular processes leading to macular hole formation are being put forward.

Gass hypothesized that IMHs begin with tangential traction of the prefoveal vitreous cortex, which results in a foveal dehiscence that progresses from foveolar detachment to a full-thickness IMH.

However, more recent research (using OCT) has allowed better understanding and visualization of the vitreomacular interface (VMI) and has elucidated that IMHs are initiated during perifoveal posterior vitreous detachment (PVD) as a consequence of anteroposterior and dynamic vitreomacular traction (VMT).

The anterior tractional forces acting at the foveola firstly produce an intrafoveal split, which evolves into a foveal pseudocyst . The pseudocyst may then become extended, disrupting and separating the outer and inner retinal layer. Degeneration of the retinal tissue secondary to these tractional forces at the foveola may facilitate this process. Dehiscence of the foveal cyst creates a full-thickness defect. Complete detachment of the cyst roof can be observed by the appearance of an operculum within the vitreous gel, which consists of glial tissue and hyperplastic Muller cells from the inner retinal surface, as well as components of the outer retina including cone cells in up to 65% of cases.

Recently the International vitreomacular traction study group have described the pathogenesis based on OCT as a progression from vitreomacular adhesion (VMA) to VMT eventually leading to a full thickness macular hole (Table 1).

Trauma related macular holes are suggested to be related to the transmission of concussive forces in a coup contracoup manner, which results in contusion necrosis and immediate rupture of the macula which is very thin.

It can form due to vitreous traction over the macula secondary to mechanical energy created by vitreous fluid waves after blunt trauma (whiplash separation of the vitreous from the retina).Holes may be noted immediately after blunt trauma that causes Berlin's edema, after a subretinal haemorrhage or after severe cystoids macular edema (CME).

Usually there is no retinal operculum over the macula in traumatic holes, which implies that there is no loss of neurosensory foveal retina. The lowering of vision in traumatic macular holes may depend on degree of associated damage like post contusion retinal necrosis, retinal pigment atrophy, choroidal rupture or subretinal haemorrhage at the macular area.

Table 1: STAGING OF MACULAR HOLE ^{1, 4, 16, 17}

	STAGE 1 a. (Impending Macular Hole)	STAGE 1 b. (Occult Macular Hole)	STAGE 2 (Small/early FTMH)	STAGE 3 (FTMH without PVD)	STAGE 4 (FTMH with PVD)
SLIT LAMP EXAM	Flattening of foveal depression associated with a yellow spot at the fovea.	Yellow ring seen around the fovea.	-Central or eccentric full thickness hole <400µm in diameter. -Can be round, oval, crescentic or horse-shoe shaped. -Posterior vitreous attached.	-Full thickness hole > 400µm in diameter. -Yellow dots may be seen on base of the hole. -Surrounding sub-retinal fluid and overlying operculum may be visible.	Full size (>400µm) macular hole with complete PVD as evidenced by a Weiss Ring.
OCT	Foveal pseudocyst or horizontal splitting (schisis) associated with a vitreous detachment from the perifoveal retina but NOT from the foveal centre.	Progression of pseudocyst to include a break in the outer foveal layer.	-Tractional break in the roof of the pseudocyst. - Posterior hyaloid remains attached to foveal centre. - Pseudooperculum (condensed vitreous) may overlie the hole.	-Full thickness defect at fovea. -Perifoveal subretinal fluid and cystic changes. -Operculum may be seen. -Vitreofoveal separation not complete.	Full thickness defect at fovea from the ILM till RPE.
VISUAL ACUITY	20/20 – 20/60	20/25 – 20/80	20/50 – 20/400	20/200 – 20/800	20/200 – 20/800
NEW (INTL CLASSIFICATION)	VMT		FTMH – VMA present, small or medium	FTMH – VMA present, medium or large	FTMH – VMA release, small, medium, large

NB: as per the International Vitreomacular Traction Study Group classification¹:

VMA: - Partial vitreous detachment as indicated by elevation of cortical vitreous above the retinal surface in the perifoveal area.

- Persistent vitreous attachment to the macular within a 3mm radius from the centre of the fovea.
- Acute angle between posterior hyaloid and inner retinal surface.
- Absence of changes in foveal contour or retinal morphology.

VMT : - Partial vitreous detachment as indicated by elevation of cortical vitreous above the retinal surface in the perifoveal area.

- Persistent vitreous attachment to the macular within a 3-mm radius from the centre of the fovea.
- Acute angle between posterior hyaloid and inner retinal surface.
- Presence of changes in foveal contour or retinal morphology (distortion of foveal surface, intraretinal structural changes such as pseudocyst formation, elevation of fovea from the RPE, or a combination of any of these three features).
- Absence of full thickness interruption of all retinal layers.

FTMH (full thickness macular hole):

- Small - < 250µ,
- Medium - 251- 400µ,
- Large - > 400µ

1.1.5 NATURAL HISTORY

Visual acuity in a patient with macular hole usually deteriorates over weeks to months and stabilizes around 6/60 – 6/240 (20/200 – 20/800), without any intervention.

Up to 50% of stage 1 holes may close spontaneously but in more advanced full thickness holes, closure and visual improvement without any intervention occurs in a significantly lower proportion.

In a randomized clinical trial to evaluate anatomic and visual benefit of surgery for full thickness macular holes (FTMH) as compared to observation, Ezra E *et al* found that 11.5% of holes closed spontaneously with little or no change in visual acuity in 24months. In contrast, the surgical group had a 80.6% closure rate with 45% of eyes achieving visual acuity of 20/40 or better.¹⁸

In the Clinical Course of macular holes: Eye Disease Case Control Study, Chew EY *et al* found 34.4% of all eyes with a macular hole had an increase in size of the hole without any intervention and 45% of eyes had a decrease in visual acuity of two or more Snellen lines. They also reported the rate of spontaneous regression of the macular holes as 8.6% over a 6year follow up period.¹⁹

Kim *et al* reported a progression rate to stage 3 or 4 of 71% for stage 2 macular holes without any intervention with 12months of follow up.²⁰

1.1.6 DIAGNOSIS AND INVESTIGATIONS

Diagnosis of macular hole is mainly clinical through history and fundus examination, with patients presenting with loss of central vision and metamorphopsia.

Clinical tests which can be employed in the diagnosis include the Watzke–Allen test (patients report a split or thinning of the beam) and the Amsler Grid (may show a central pin–cushion distortion).

Imaging Tests

OCT (Optical Coherence Tomography)

- It allows visualization of the hole in cross–section and 3D and to assess attachment of the vitreous to the fovea.
- OCT is also useful in detecting very early macular holes, guide prognosis for the fellow-eye and in staging of macular holes.
- It can also guide management for example if the macular hole is seen associated with Epiretinal membranes (ERM) - which can be difficult to determine clinically.
- It also helps monitor progress and recovery after surgery.

Fluorescein Angiography (FA)

- It is rarely used in the diagnosis of macular holes since the advent of OCT, although it can help rule out other conditions that may mimic macular holes.

1.2 MANAGEMENT: MACULAR HOLE SURGERY

Macular holes were for a long time considered to be an untreatable condition with very little chance of spontaneous recovery.

Kelly and Wendel first described and reported macular hole surgery about two decades ago and showed it was possible to achieve both anatomic closure and improve visual function.²¹ Since then vitrectomy for macular holes has become a widely performed and one of the most successful vitreoretinal surgeries.

The Vitrectomy for Macular Hole Study (VMHS), which was conducted early in the development of macular hole surgery, demonstrated that surgery for stage 3 and 4 holes was very effective in closing the defect and modestly improving visual function, while stage 2 holes which underwent surgery were less likely to progress as compared to those without any intervention.^{20,22}

Other clinical trials and studies have also shown surgery for macular holes is safe with significantly high anatomic closure rates of between 80% - 95% for stage 2 or worse holes, with eyes even achieving Snellen acuity of 20/40 or greater, as opposed to spontaneous closure rates of only about 5% - 11% in the observation only group.^{18,23,24}

Surgical management is indicated for stage 2 or worse holes but is not recommended for stage 1 macular holes which are best managed conservatively.^{20, 24}

With a few variations in some aspects of the surgery, the basic surgical technique for macular hole surgery is the same. It includes:

- Standard 3 port pars plana vitrectomy
- Removal of perimacular traction which may include ILM peeling with or without assistance of a dye - ILM peeling has been advocated lately as a major determinant of outcome of macular hole surgery.^{25,26}

The dyes which can be used to stain the ILM include Indocyanine Green (ICG), Trypan Blue, Triamcinolone acetate (TA), and Brilliant Blue G (BBG).

- Fluid gas exchange (FGE)
- Internal tamponade with air, gas or oil - The gases which can be used are C₂F₆, C₃F₈ (Perfluoropropane) and SF₆ (Sulfurhexafluoride).

1.2.1 Modified Techniques for Macular Hole Surgery.

Although overall macular hole closure rates at present are more than 90%, larger holes have less favorable outcomes after one surgery and have higher re-opening rates compared to smaller holes. Therefore modified techniques of hole closure surgeries for larger holes are being developed.

- i. **Inverted ILM flap technique** – this is a technique whereby instead of completely removing the ILM, a remnant which is attached to the margins of the macula hole is left in place. This ILM remnant is then inverted to cover the macula hole.

This method has shown to improve both the anatomic and functional outcomes of macular hole surgery especially for holes larger than 400µm in size and holes in highly myopic eyes.^{27, 28}

In a study by Michalewska Z *et al*, this technique was found to give closure rates of 98% and better post-operative visual acuity than the standard vitrectomy technique (closure rates of 88%) for holes larger than 400µm.²⁷

- ii. **Perifoveal radial relaxing incisions** – this technique done in stage IV macular holes that had remained open after ILM peeling vitrectomy, produced closure rates in all cases with the second procedure while also improving functional outcome in a study by Reis R *et al*.²⁹

- iii. Alpatov S *et al* reported a technique whereby PPV was combined with mechanically joining the hole edges with forceps and gently pressing them together followed by tamponade. This method was used for stage 3 and 4 macular holes and gave comparable functional and anatomic results, but had a higher incidence of retinal pigment epitheliopathy.³⁰

1.3 OUTCOMES OF MACULAR HOLE SURGERY

1.3.1 Anatomic Outcome.

Successful anatomic outcome post macular hole surgery can be defined and assessed either clinically or with the use of OCT.

Clinically successful anatomic outcome is defined as disappearance of the defect at the macula and also the cuff of subretinal fluid that surrounds it.

Using OCT, it is defined as re-approximation of retinal tissue at the fovea covering the full thickness defect.

Anatomic closure can be determined at about 3 – 4 weeks post surgery (when the gas bubble resolves fully).¹⁷ Kelly and Wendel were the first to demonstrate successful macular hole closure and reported a 58% closure rate.²¹ In their subsequent series they achieved a closure rate of 73%.³¹ Since then advances in surgical techniques has led to more successful anatomic outcomes and studies have shown closure rates of between 80% - 100%.^{4, 32,33}

In the Morfields Macular Hole Study Group Report of a randomized clinical trial over 2years, they showed a 80.6% rate of macula hole closure in patients undergoing surgery, compared with only 11.5% spontaneous closures in the observation group.¹⁸

A meta-analysis on 1654 eyes treated for full thickness macular hole using different techniques by Mester V *et al*, reported that 87.5% of eyes achieved anatomical closure.²⁶

In a large study, Hager A *et al* also showed that surgery was able to successfully close 92.2% of macular holes.³⁴

The anatomic closure rate depends on a number of factors like hole duration, pre-operative hole size and surgical technique used.

1.3.1.1 Types of Hole Closures.

The most commonly used classification of successful macular hole closure type was described by Kang SW *et al*.³⁵ They described 2 patterns of hole closure based on OCT:

- i. Type 1 closure – closed without any foveal neurosensory defect (complete sealing of the macular hole without bare RPE).
- ii. Type 2 closure – closed with a persisting foveal neurosensory retinal defect, although the whole rim of the macula hole is attached to the underlying RPE with flattening of the cuff of subretinal fluid (incomplete sealing of the macular hole with bare RPE).

61.3% of patients were noted to have type 1 closure while 38.7% had type 2 closures in their study.

They also found that larger pre-operative macular hole size and longer duration of symptoms was associated with type 2 closure.

Recurrence of macular hole also occurred more commonly in the type 2 closure group.

Visual improvement was more marked in the type 1 closure group than type 2.

Other authors have also described hole closure types based on ophthalmoscopic, biomicroscopic or OCT examination.

Tomambe *et al*³⁶ classified the anatomical hole closure based on ophthalmoscopic or biomicroscopic examination into 3 types:

- Elevated / open
- Flat / open
- Flat / closed

Flat / closed holes had better visual prognosis than the other types.

Imai *et al*³⁷ also categorized successfully repaired macular holes using OCT in to 3 types:

- U type (normal foveal contour)
- V type (steep foveal contour)
- W type (foveal defect of neurosensory retina)

The U and V pattern may be equated to type 1 and W pattern to type 2 closure type in Kang's classification.

1.3.2 Functional (Visual) Outcome.

Most literature define successful visual outcome as improvement in post- operative visual acuity of at least 2 or more Snellen lines (≥ 0.3 log MAR) over the pre-operative visual acuity.

Kelly and Wendel reported a 42% visual acuity improvement of 2 or more Snellen lines in their pilot study.²¹

Subsequent studies and refinements in surgical techniques have reported significant improvement in visual acuity with a large percentage of patients achieving Snellen acuity of 20/40 or greater, although anatomic success has been noted to be even better than visual outcome in most studies.^{18, 31-34}

The VMHS in a prospective randomized controlled series showed significant visual improvement in surgically treated eyes compared to observed eyes.^{20, 22}

A review of over 400 citations of macular hole surgeries by the American Academy of Ophthalmology (AAO) showed that post- operative vision of 20/40 or better was achieved in 22% - 49% of patients.²⁴

Data extracted over 8years for eyes undergoing macular hole surgery in participating centers in the United Kingdom National Ophthalmology Database Study of macular hole, which included 1078 eyes showed that 57.8% of eyes improved by 2 or more Snellen lines. They also reported better improvement in eyes undergoing ILM peel and eyes with worse presenting visual acuity.²

A number of factors affect post operative visual outcome in macular hole surgery just as they affect the anatomic outcomes. These include the pre-operative hole size, surgical technique used, pre – operative visual acuity and occurrence of post-operative complications.^{35, 38, 39}

The improvement in vision after successful macular hole surgery has been reported to be continuous and a long-standing process, with improvement reported from 6months to even 2years thereafter.⁴⁰

Even with modest improvements in vision post macular hole surgery, patients report marked improvement in a number of daily life activities and quality of life.^{41, 42}

1.3.3 Outcome Related to Pre-Operative Hole Size.

The pre-operative diameter of the macular hole may be a prognostic factor for post-operative visual and anatomical outcomes of macular hole surgery.

Studies have shown that macular holes smaller than 400µm have a higher surgical success rate,^{33, 38} although some authors have found that hole diameter is not a predictive factor in outcome of macular hole surgery.^{23, 43}

Pre-operative hole diameters of more than 400µm have also been shown to have reduced first surgery closure and have higher rates of late re-opening and other complications.^{33, 38}

In a study by Ullrich S *et al* the diameter of macular hole pre-operatively was not related to the duration of symptoms, therefore larger hole were not necessarily older than smaller holes.³⁸

The surgical technique used may also be influenced by the pre- operative hole size. ILM peeling does not seem to be as useful in macular holes < 400µm as in holes larger than 400µm diameter.⁴⁴ Also, face-down positioning may improve the closure rate of macular holes larger than 400µm.⁴⁵

The inverted ILM flap technique has been seen to improve both functional and anatomic outcomes for macular holes with diameter more than 400µm.²⁷

In the study by Kang SW *et al*, the type of hole closure was influenced by pre- operative hole diameter. Type 2 closure was more commonly seen in larger holes.³⁵

1.3.4 Outcome Related to Symptom Duration.

Surgery for macular hole has been shown to have a better prognosis in holes with symptom duration of less than 6 months,^{31, 43, 46} although some studies have demonstrated no relation between symptom duration and outcome of macular hole surgery.^{23, 47}

Jaycock PD *et al* found a closure rate of 94% in patients undergoing surgery within 1 year of onset of symptoms and 47.4% in patients who waited 1 year or longer.⁴⁸

1.3.5 Complications of Macular Hole Surgery.

Like any other surgery, macular hole surgery is not without complications.

A frequent complication of macular hole surgery is cataract formation.^{2, 24} It has been reported in as many as 75% of patients undergoing macular hole surgery.²⁴

Progression of cataract post macular hole surgery is faster in non prone positioning after surgery. Authors therefore advocate for combined phacovitrectomy for phakic patients to allow less stringent positioning requirements.⁴⁸

The VMHS reported 41% patients had posterior segment complications.⁴⁹ Hotta K *et al* found posterior segment complications in 38% of patients who underwent vitrectomy for stage III or IV IMH.⁵⁰ Data extracted over 8years for eyes undergoing macula hole surgery in the United Kingdom National Ophthalmology Database Study of vitreoretinal surgery reported one or more intra operative complications occurring in 12.4% of patients.²

Posterior segment complications which occur post macular hole surgery include:

- RPE changes (most frequently due to ICG toxicity, intra operative light toxicity or excessive drying secondary to air infusion). It has been reported in up to 33% of patients undergoing IMH surgery.^{49,50}
- Retinal tears and retinal detachments (RD).⁴⁹⁻⁵¹
- Peripheral visual field loss^{50, 52} – mostly due to ICG toxicity or mechanical iatrogenic injury to the nerve fibre layer.
- Intra operative hole enlargement.⁵¹
- Late re-opening of a successfully closed macular hole.⁴⁹⁻⁵¹ This was seen to occur only in macular holes that were 400µm or larger pre-operatively in a study by Ip MS *et al*.⁵³ Bhatnagar P *et al* also found that cataract extraction after successful surgery for macular hole , especially when complicated by CMO increases the risk of macular hole re-opening.⁵⁴
- Endophthalmitis – reported in about 1% of patients.^{24,49,51}

Other less common complications which have been observed in macular hole surgery patients include CMO, CNV.⁴⁹

Glaucoma and increased intra ocular pressure (IOP) is another significant complication of macular hole surgery. In most cases it is transient and was seen to occur mostly within the 1st post-operative week by Chen CJ in about 52% of patients undergoing macular hole surgery.⁵⁵

2.0 STUDY RATIONALE

Macular hole surgery has been carried out in Kenya for over a decade now. No study has yet been done in Kenya to evaluate the outcome of macular hole surgeries.

This study will therefore form a baseline for comparison with future audits.

It will also help to determine whether macular hole surgery has beneficial outcome in our setup. This is important because macular hole surgery is expensive and we still have limited specialists and centers carrying out this procedure.

3.0 OBJECTIVES

3.1 MAIN OBJECTIVE

To determine the outcome of surgery for macular holes at KEU.

3.2 SPECIFIC OBJECTIVES

1. To determine the anatomical outcome of macular hole surgery.
2. To determine the functional (visual) outcome of macular hole surgery.
3. To determine the factors influencing outcome of macular hole surgery.
4. To describe the complications of macular hole surgery.

4.0 METHODOLOGY

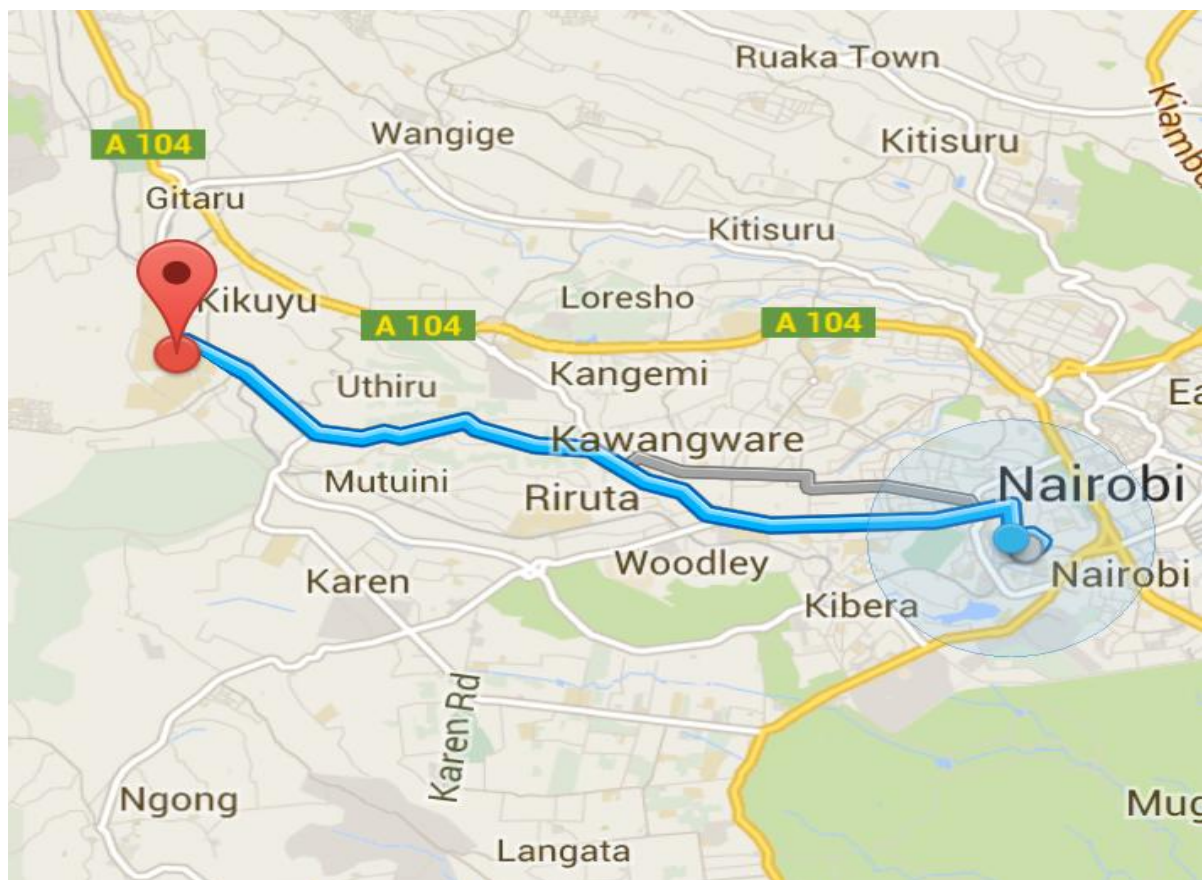
4.1 STUDY DESIGN

A retrospective hospital based case series.

4.2 STUDY LOCATION

Kikuyu Eye Unit which is a part of a larger Presbyterian Church of East Africa (P.C.E.A) Kikuyu Hospital located about 30km from Nairobi city. It is a busy eye unit catering for about 3000-4000 patients in a month mainly from central Kenya and Nairobi. It also serves as one of the few referral centres in the country for vitreoretinal surgeries.

Figure 1: LOCATION OF KEU, ITS ENVIRON AND ROUTE FROM NAIROBI.



4.3 STUDY POPULATION


All patients with macular holes who underwent macular hole surgery at KEU between January 2004 and July 2013.

4.4 EXCLUSION CRITERIA

- Missing or incomplete records
- Less than 1 month follow up
- Macular hole secondary to or associated with retinal detachment.
- Macular hole surgery done together with cataract surgery.
- Any other ocular disease affecting the macula – ARMD, CMO, clinically significant macular edema (CSME), Angioid streaks with foveal involvement, Central serous chorioretinopathy, hypotony maculopathy.

4.5 STUDY PERIOD

Figure 2: OUTLINE OF STAGES IN PREPARATION OF DISSERTATION.



4.6 STUDY MATERIALS

- Theatre lists from KEU.
- Patients files from the records department at KEU.
- Self structured questionnaire.
- Excel data entry sheet.

PERSONNEL.

- Principal investigator.
- Theatre records in-charge at KEU.
- Records clerk at KEU.
- Statistician

4.7 DATA COLLECTION AND ANALYSIS

All theatre lists between January 2004 and July 2013 were retrieved from the theatre records. The In-Patient number (I.P.NO.), Name of patient, age, diagnosis and date of surgery of all patients who had macular hole surgery were compiled and their files retrieved from the records department with the help of the hospital records clerk.

Data from the files including demographic details, pre-op evaluation, surgical details and post-op findings of patients who had at least 1 month follow-up was entered into a structured questionnaire (Appendix II) by the principal investigator.

Data was then entered in Microsoft Access Database and cleaned for errors, missing entries and duplicate entries to ensure high quality data. The data was analyzed using SPSS version 17.0 and the findings summarized and presented in form of graphs and tables. The confidence level was taken as 95% ($P < 0.05$).

4.8 STUDY LIMITATIONS

- This being a study with a small sample size, even the few missing records may have been significant in the final analysis.
- OCT was used only in a small percentage of patients to assess macular holes and also outcome of surgery. Clinical assessment which was employed in most of the cases is unfortunately a subjective method and is dependent on the clinicians evaluation.

4.9 ETHICAL CONSIDERATIONS

Ethical approval was obtained from the KNH/UON Ethics and Research Committee (KNH/UON-ERC). Permission was also obtained from P.C.E.A Kikuyu Hospital to undertake the study.

Patients' confidentiality was strictly observed by coding patient's names and using these codes instead of names for reference, analysis and presentation of the findings of this study.

The information and the questionnaire was only accessible to the investigators and the statisticians.

9.0 RESULTS

Figure 3: Study flowchart

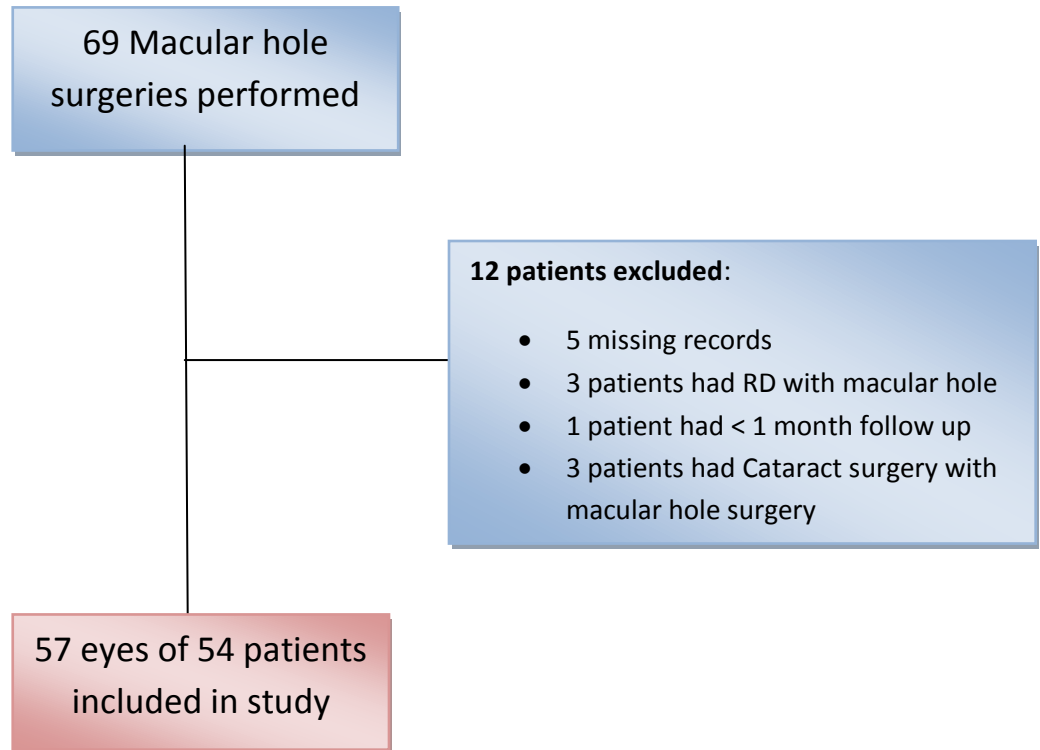
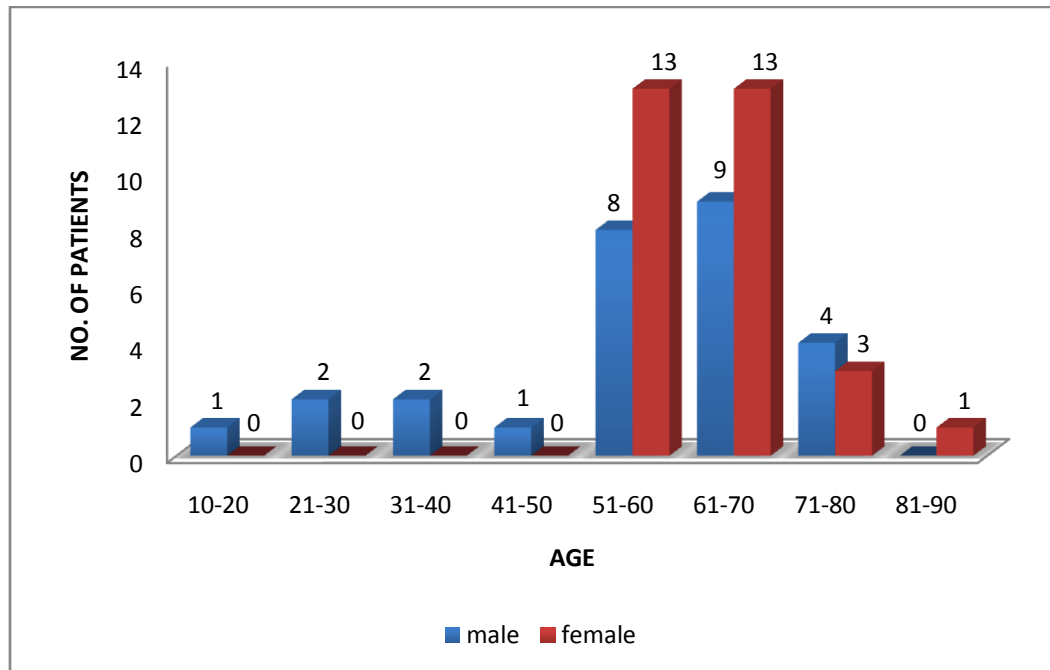


Figure 4: AGE OF PRESENTATION n= 57



Female (n= 30) to male (n=27) ratio was **1.1: 1.0** and there was no statistical difference in sex (p-value=0.6917)

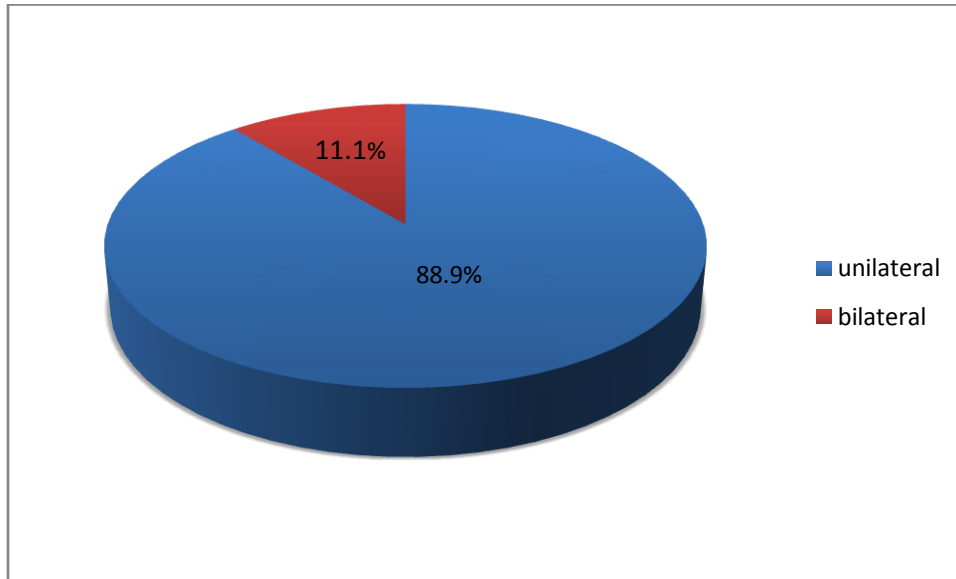
Median age of presentation was 62 years, range 13-82 years, mean age: 59.63 years, SD: 12.60.

Mean age for male was 56.44 years, SD: 16.33.

Mean age for female was 62.5 years, SD: 7.04.

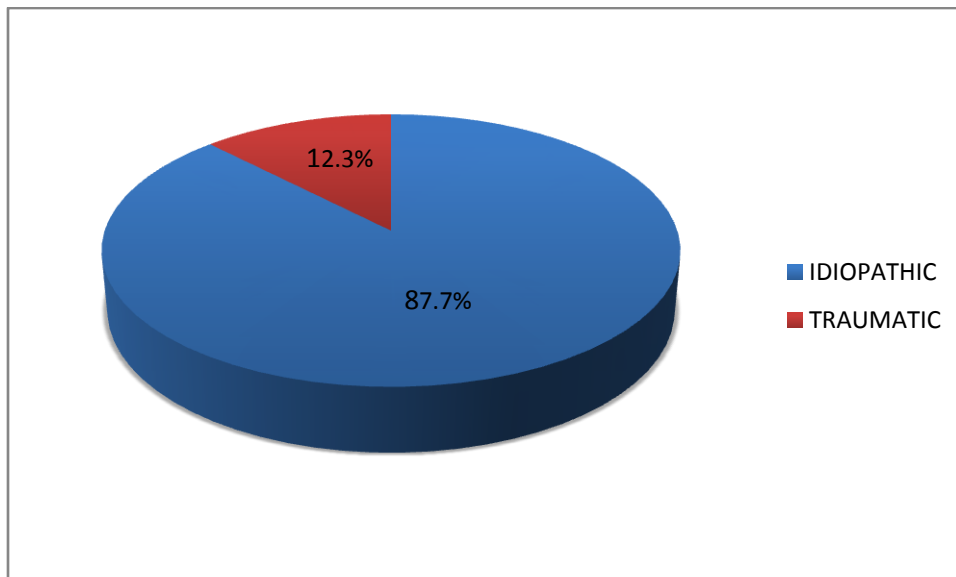
The difference in the mean age for males and females was not statistically significant, p= 0.0697.

Figure 5: LATERALITY n=54



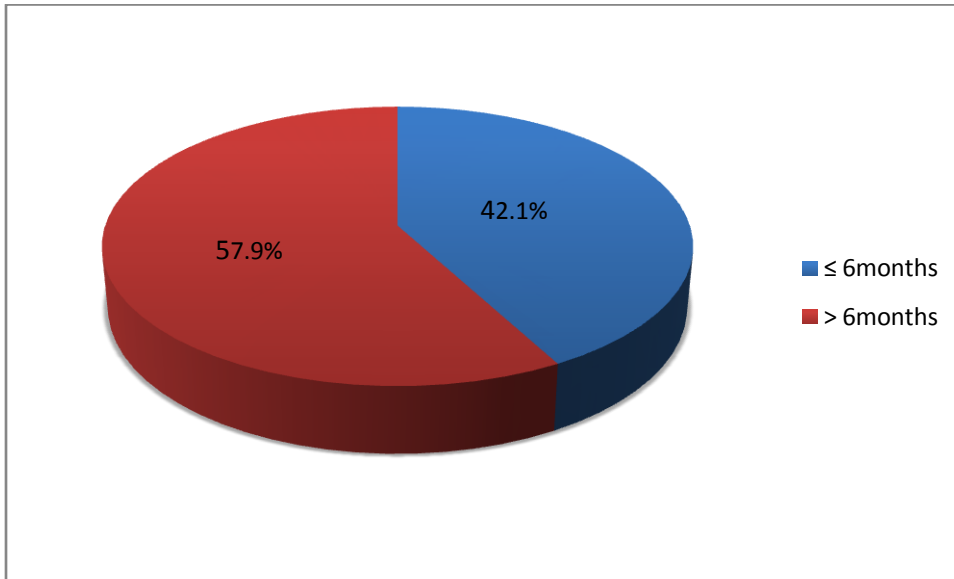
6 patients had bilateral macular holes.

Figure 6: CAUSE OF MACULAR HOLE n=57



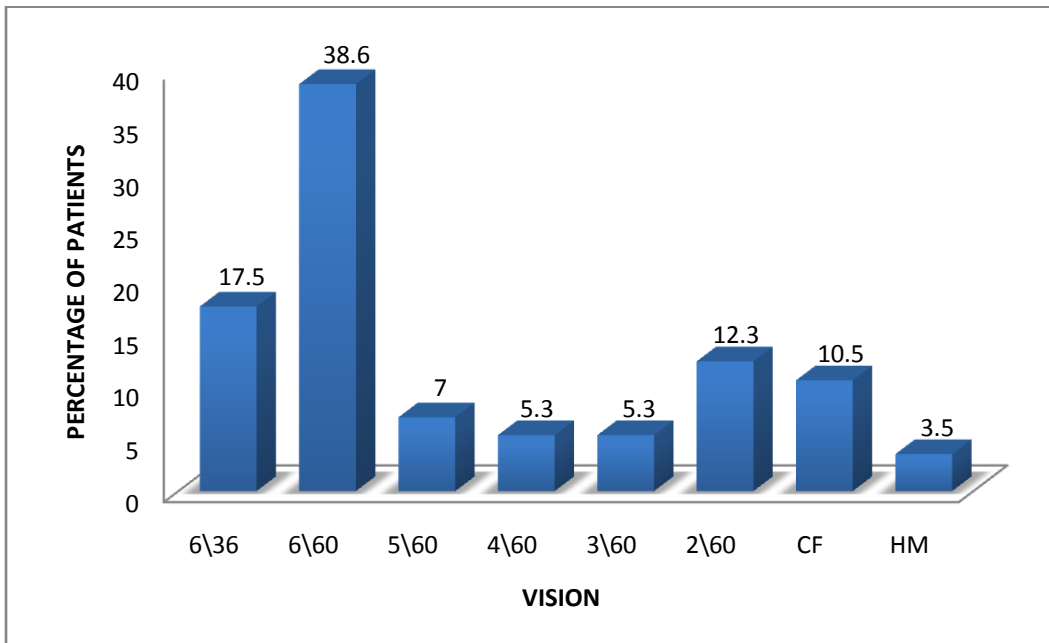
Majority of the holes were idiopathic in nature.

Figure 7: DURATION OF SYMPTOMS



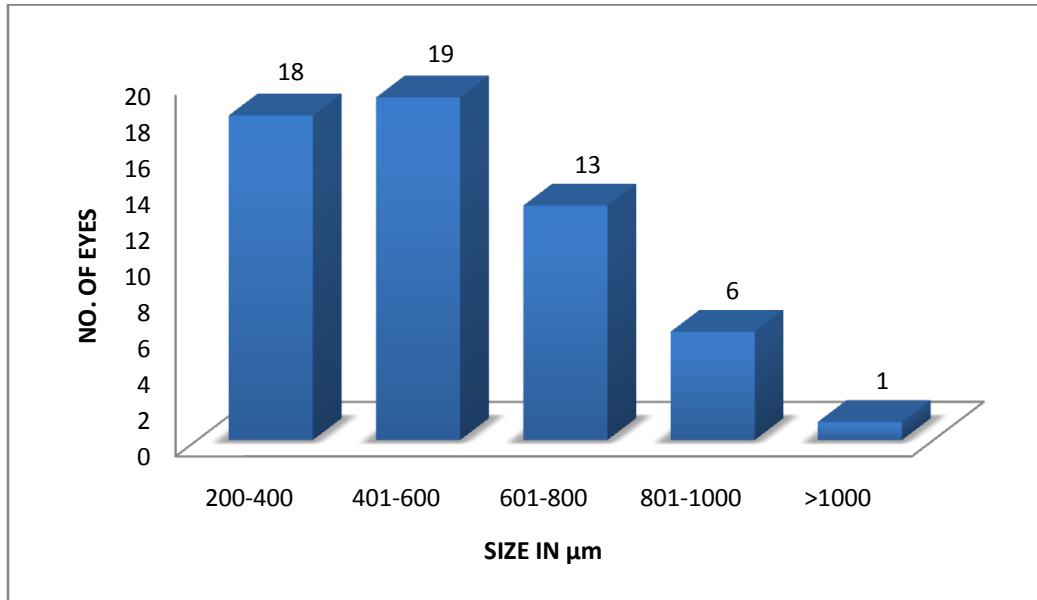
Mean duration of symptoms was 13.7 months, SD:15.79, median:9 months, range 1 week - 5 years.

Figure 8: PRE-OP BCVA IN AFFECTED EYE n=57



All the eyes had pre-operative vision worse than 6/36 with majority between 6/36 and 6/60

Figure 9: SIZE OF MACULAR HOLE n=57



Mean size was 578.44μm, SD: 230.14, median: 500 μm, range (200-1100) μm

Figure 10: MACULAR HOLE ASSESSMENT METHOD USED n=57

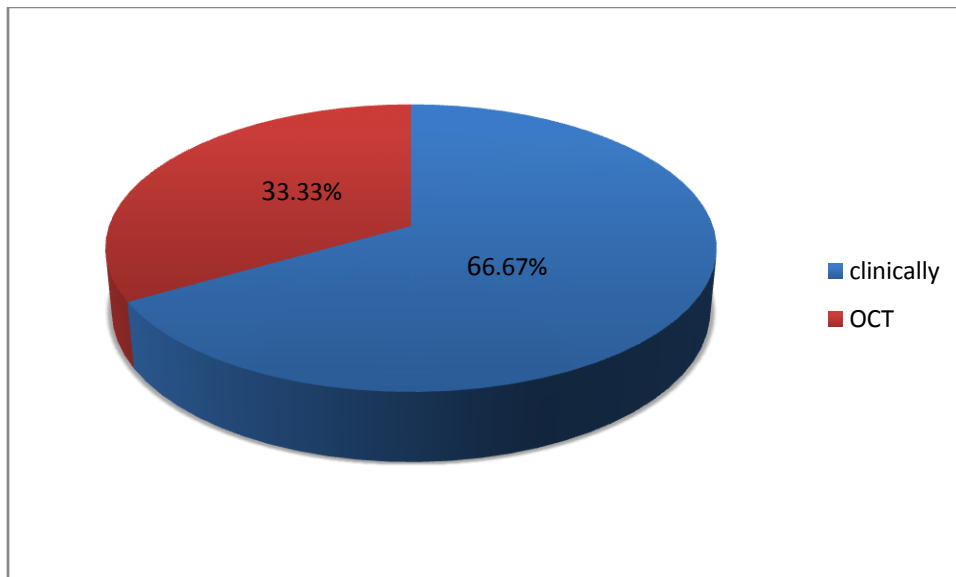
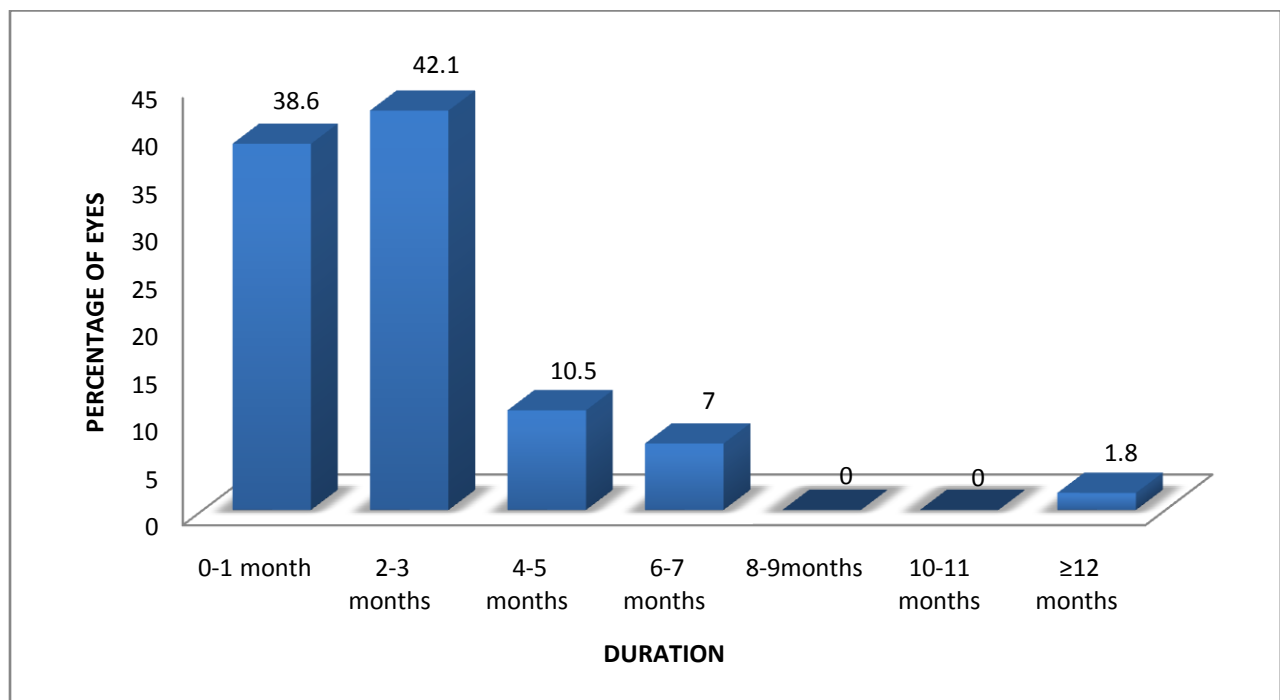


Table 2: OTHER CO-EXISTING OCULAR FINDINGS (n = 57)

OCULAR FINDING	NO. OF EYES	%
Diabetic Retinopathy	3	5.3
Glaucoma	2	3.5
Pseudophakia	9	15.8
Optic Atrophy	1	1.8
Lattice Degeneration	1	1.8
Corneal Scar	1	1.8
Aphakia	1	1.8
None	43	75.4

NB: some patients had multiple co-existing ocular findings.

Figure 11: DELAY BETWEEN DIAGNOSIS AND SURGERY n=57



The mean time between diagnosis and surgery was **2.36 months**, SD:2.15, median:2 months, range 1 week-1 year.

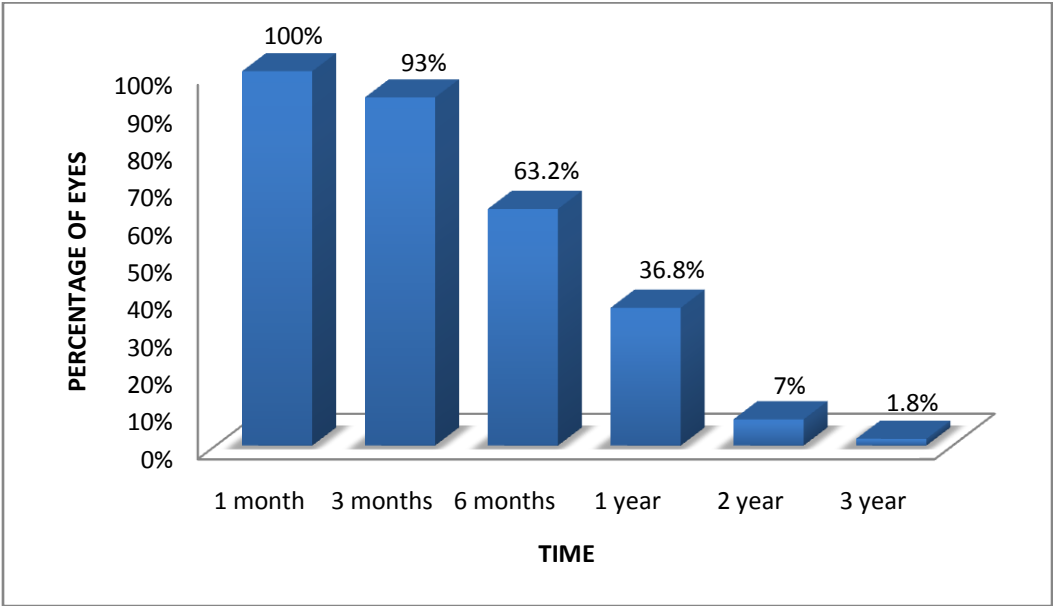
Table 3: SURGICAL TECHNIQUE

	NO. OF PATIENTS	%
TYPE OF SURGERY (n = 57)		
• ILM Peel only	46	80.7
• ILM peel with inverted flap	11	19.3
TAMPONADE AGENT (n = 57)		
• SF ₆	50	87.7
• C ₃ F ₈	07	12.3
OTHER INTRA OP PROCEDURES (n = 57)		
• Endolaser	05	8.8
• Cryopexy	02	3.5
• None	50	87.7

Table 4: INTRA –OP COMPLICATIONS n=57

COMPLICATION	NO. OF EYES(%)
• Small retinal break / Horse shoe tear	4(7.0)
• Retinal detachment	1(1.8)
• Lens touch	1(1.8)
• None	51(89.4)

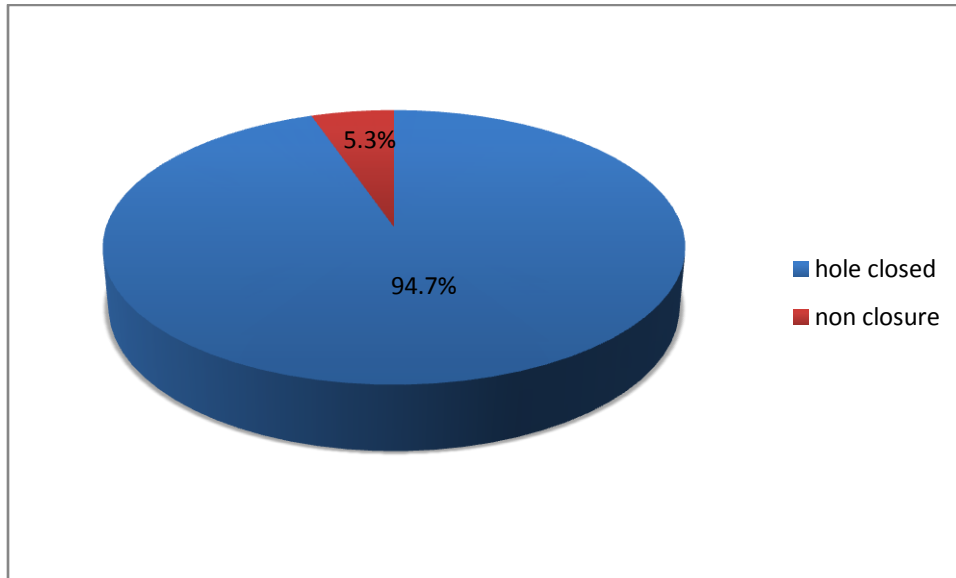
Figure 12: FOLLOW UP PERIOD n=57



All the eyes had at least 1 month post operative follow up and 93% were also seen at 3 months after which the follow up reduced to 63% at 6 months and 36% at 1 year. Only 4 patients had a follow up of more than 2 years.

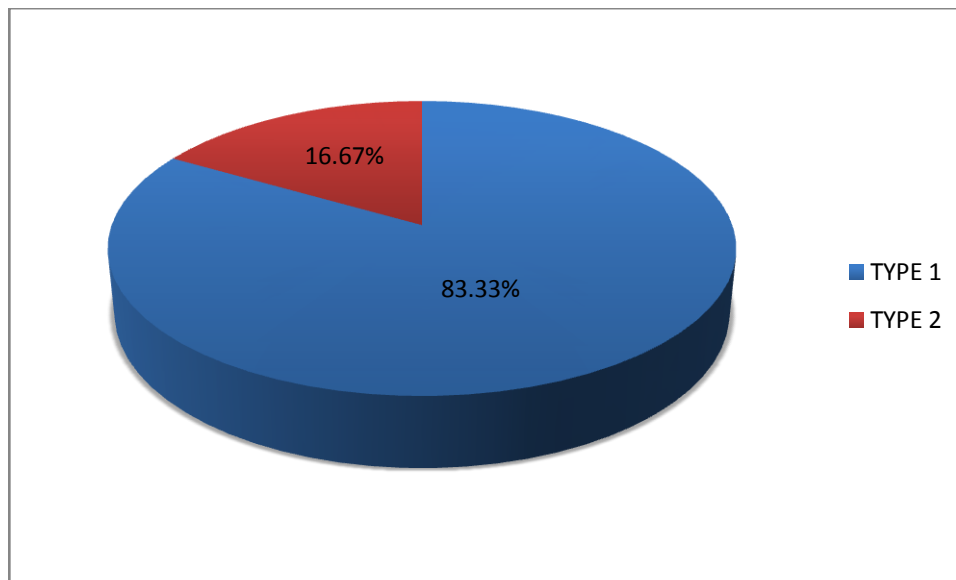
ANATOMIC OUTCOME

Figure 13: Anatomic Outcome n=57



Majority of the holes operated on closed successfully (hole closure was assessed using OCT in 1/3 of the eyes, the rest had clinical assessment).

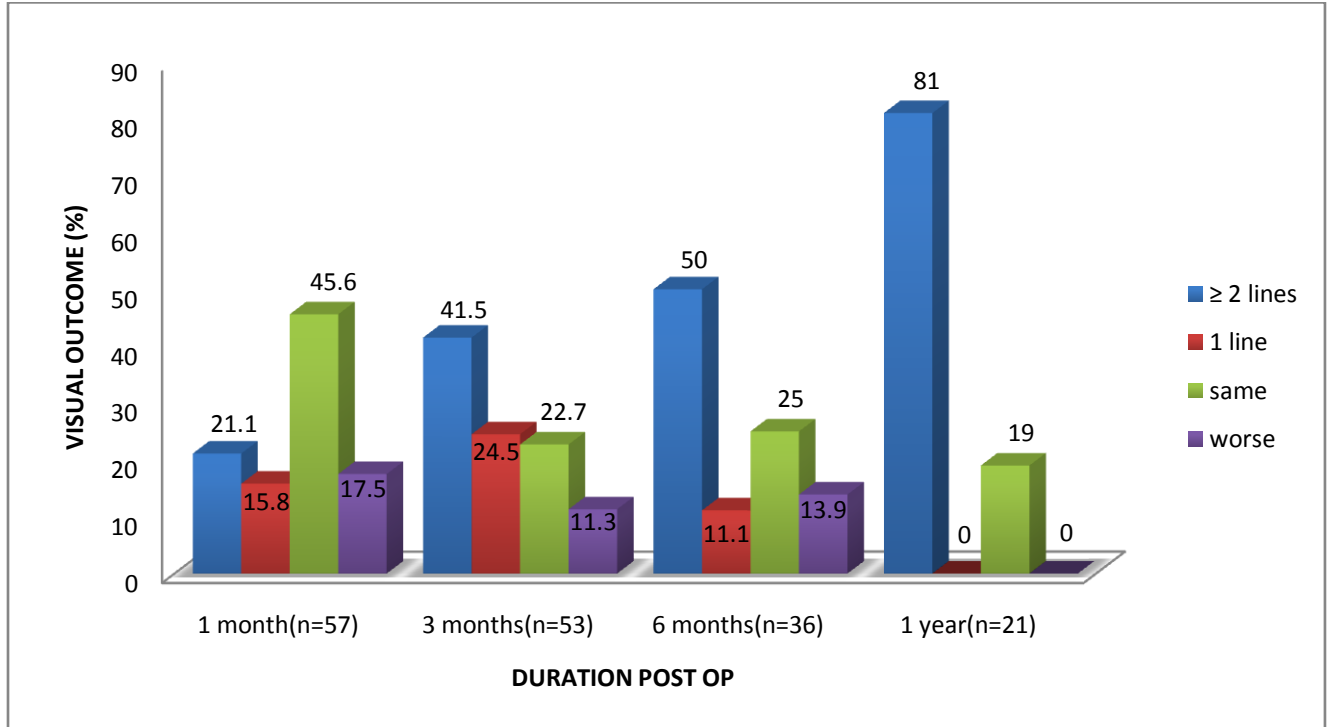
Figure 14: TYPE OF HOLE CLOSURE n=54



Most holes with anatomic closure had Type 1 closure.

VISUAL OUTCOME

Figure 15: VISUAL OUTCOME AT DIFFERENT PERIODS POST OP.



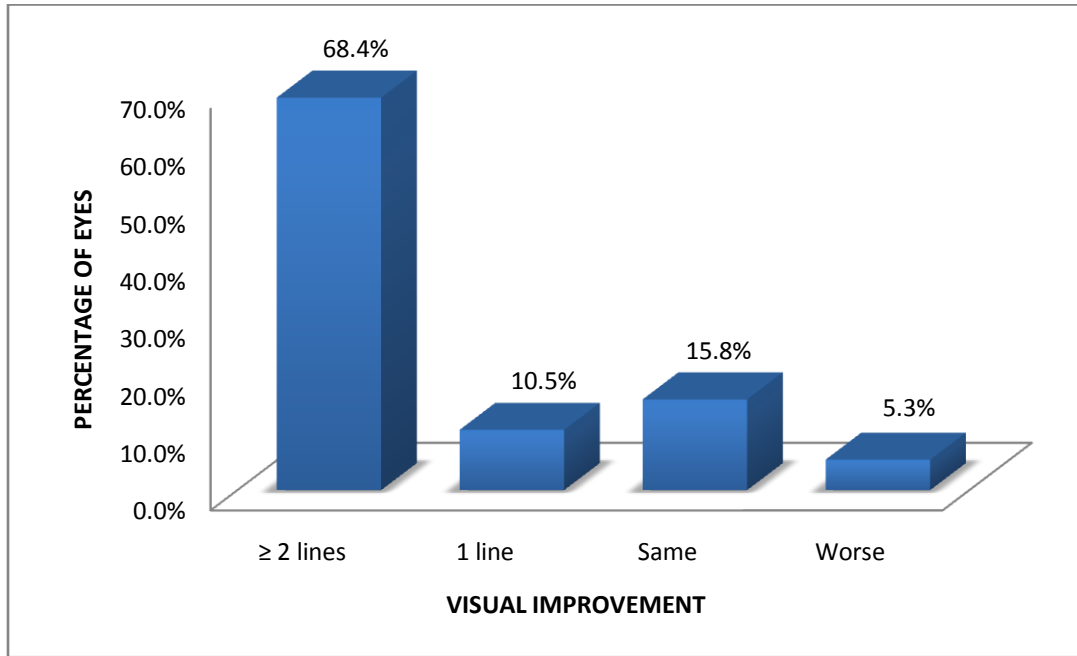
Most patients had the same vision at 1 month as pre-operatively, though 36% already had improvement at 1 month. At 3 months majority had improvement in vision.

Vision at 6 months was slightly lower in patients compared to at 3 months.

Only 21 eyes (36.8%) were followed up at 1 year and majority had vision improvement ≥ 2 lines. None of the eyes which were followed up for 1 year had worsened vision.

Only 4 patients were on follow up at 2 years, 3 of whom had vision improvement ≥ 2 lines and 1 had the same vision as preoperatively

Figure 16: VISUAL OUTCOME AT LAST FOLLOW UP VISIT n=57



Mean follow up of patients was **8.12 months** and **78.9%** of the eyes had some improvement in vision with **68.4%** having improvement of ≥ 2 lines.

Table 5: OUTCOME OF SURGERY DEPENDING ON CAUSE OF THE MACULA HOLE

Outcome	Idiopathic n=50	Traumatic n=7
Visual Outcome		
Improvement	39 (78%)	6 (85.7%)
No improvement	11 (22%)	1 (14.3%)
Hole closure (n=57)		
Closed	48 (96%)	6 (85.7%)
Non closure	2 (4%)	1 (14.3%)
Type of hole closure*		
Type 1	40 (83.3%)	5 (83.3%)
Type 2	8 (16.7%)	1 (16.7%)

*two of the idiopathic holes and one of the traumatic holes did not close so N for type of closure for idiopathic holes was n=48 and for traumatic holes was n=6.

Table 6: ASSOCIATION BETWEEN SYMPTOM DURATION AND OUTCOME OF MACULAR HOLE SURGERY.

Variable	≤6months n=26	>6months n=31	OR (95% CI)
Visual Outcome (n=57)			
Improvement (45)	22	23	1.91 (0.50 – 7.24)
No improvement (12)	4	8	
Hole closure (n=57)			
Closed (54)	25	29	1.72 (0.15-20.17)
Non closure (3)	1	2	
Type of hole closure (n=54)*			
Type 1 (45)	21	24	1.09 (0.26 - 4.68)
Type 2 (9)	4	5	

*n=54 for type of hole closure as 3 holes did not close.

The OR suggests visual improvement, hole closure and type 1 closure was more likely in eyes with symptom duration of ≤6months than in eyes with symptoms of > 6 months, but the CI is very wide and includes 1, therefore there may not be a statistically significant association.

Table 7: ASSOCIATION BETWEEN HOLE SIZE AND OUTCOME OF MACULAR HOLE SURGERY.

Variable	≤400 μm n=20	>400 μm n=37	OR (95% CI)
Visual Outcome (n=57)			
Improvement (45)	17	28	1.82 (0.43-7.67)
No improvement (12)	3	9	
Hole closure (n=57)			
Closed (54)	20	34	-
Non closure (3)	0	3	
Type of hole closure (n=54)*			
Type 1 (45)	18	27	2.33 (0.42 - 12.94)
Type 2 (9)	2	7	

*n=54 for type of hole closure as 3 holes did not close.

The OR suggests visual improvement and type 1 closure was more likely in eyes with hole size of ≤ 400 μm than in eyes with holes of > 400μm, but the CI is very wide and includes 1, therefore there may not be a statistically significant association.

All the 3 eyes which had non closure had holes larger than 400μm; although OR could not be calculated to determine association between pre-operative hole size and anatomic outcome as 0 eyes ≤ 400 μm had non - closure.

OUTCOME OF MACULAR HOLE SURGERY vs TYPE OF SURGICAL TECHNIQUE

Table 8: For LARGE macular holes ($\geq 400\mu\text{m}$) n=37

SURGICAL TECHNIQUE	HOLE CLOSED	VISION IMPROVED
ILM PEEL	25/28 (89.3%)	14/28 (50%)
INVERTED FLAP	9/9 (100%)	9/9 (100%)
	p = 0.306	p = 0.0071

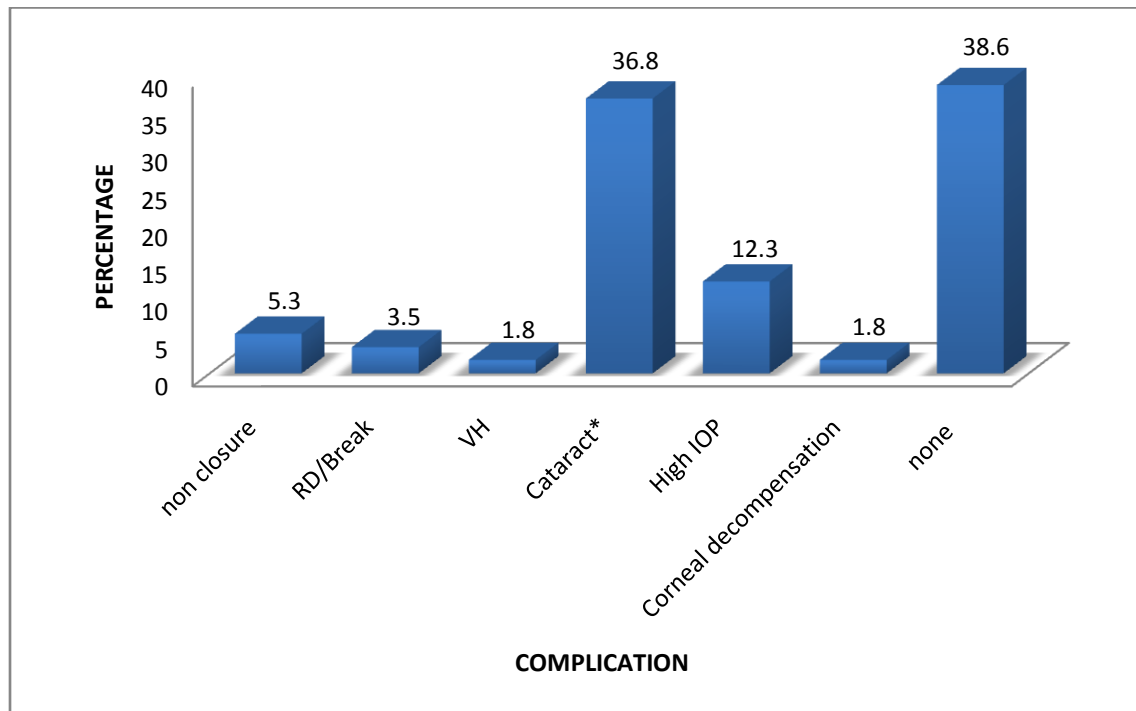
Inverted flap technique had better visual outcome for holes $\geq 400\mu\text{m}$ ($p=0.007$), but there was no statistically significant difference in the hole closure between the 2 surgical techniques ($p=0.306$).

Table 9: For OLDER Macular Holes (≥ 6 months duration) n=33

SURGICAL TECHNIQUE	HOLE CLOSED	VISION IMPROVED
ILM PEEL	22/24 (91.7%)	11/24 (45.8%)
INVERTED FLAP	9/9 (100%)	9/9 (100%)
	p = 0.3252	p = 0.0045

Inverted flap technique had better visual outcome for holes of ≥ 6 months duration ($p=0.0045$), but there was no statistically significant difference in the hole closure between the 2 surgical techniques ($p=0.3252$).

Figure 17: POST OPERATIVE COMPLICATIONS.



*The cataract rate was actually much higher as 9 eyes out of 57 were already pseudophakic pre-op and 1 eye was aphakic. Therefore 21/47 (44.7%) developed cataract post-operatively.

Mean time post-op when these complications occurred:

Cataract (n=21) – Mean: 16 weeks, SD: 10.93, Median: 12 weeks, range (4 -52) weeks

High IOP (n=7) – Mean: 1.2 weeks, SD: 1.31, Median: 1 week, range 1day-4weeks

RD (n=2) – Mean: 10 weeks, SD: 2.83, Median: 10weeks, range 8-12 weeks

Table 10: FURTHER INTERVENTIONS REQUIRED.

INTERVENTION	NO.OF EYES (%)
Cataract Surgery (n=47)	15 (31.9)
Medical management of High IOP. (n=57)	7 (12.3)
Gas Tapping (n=57)	2 (3.5)
Laser (n=57)	2 (3.5)

6.0 DISCUSSION

Demographics.

Most of the macular holes in our study were idiopathic (87.7%) while the rest were traumatic (12.3%). Aabery TM found that the most common cause of macular holes was idiopathic.⁷ One of the reasons why macular holes secondary to other causes were not found in this study may be because only eyes which are expected to have a positive outcome are operated on and patients with other severe ocular diseases leading to macular holes may have been advised against surgery. Also patients who had other ocular pathologies like retinal detachment with macular holes which required a different type of surgery as opposed to the conventional macular hole surgery were excluded in this study.

The mean age of presentation of the patients with idiopathic macular holes was 63.14 years, while the patients with traumatic holes presented at a much younger age (mean of 34.57 years). The overall female to male ratio was 1.1:1, but if the traumatic holes (which all occurred in males) are excluded, then the female to male ratio increases to 1.5:1. This was in keeping with studies which have shown that idiopathic macular holes usually present in the 6th – 7th decade of life and are more common in women.^{2,3} The female to male ratio was lower than other studies like the United Kingdom National Ophthalmology Database Study of vitreoretinal surgery, which reported a female to male ratio of 2.2:1.² This may be due to the fact that in this study only the patients who underwent surgery were considered and this may be affected by the different health seeking behaviors between males and females in the region. This may also have been due to the small sample size in our study. The United Kingdom National Ophthalmology Database Study of Vitreoretinal Surgery included 1078 eyes.

Few patients were found to have other co-existing ocular conditions. Out of 57 eyes included in this study, 3 had Diabetic retinopathy (1 mild NPDR, 2 stable PDR), 2 had glaucoma (both had well controlled IOP pre-operatively) while 1 each had disc pallour, lattice degeneration and corneal scar pre operatively. 9 eyes (15.8%) were pseudophakic prior to the macular hole surgery while 1 was aphakic secondary to trauma.

The patients presented with a mean duration of symptoms of 13.7 months (median 9 months) with almost 60% of the patients presenting more than 6 months after onset of symptoms. The mean duration of symptoms was even higher for idiopathic holes considering the traumatic holes presented much earlier. This was quite a long duration as it has been seen in several studies that holes of more than 6 months duration have poorer prognosis.⁴³ Also most patients had a delay between the time of diagnosis to date of surgery, the mean time being 2.4 months (range 1 week - 3 months). This further increased the duration of the symptoms. However, many patients with idiopathic macular holes may not remember exactly the onset of symptoms, especially in elderly patients with a healthy contralateral eye.

The average size of the macular holes was found to be 578µm (range 200 - 1100) .Only 1/3 of the holes were assessed using OCT and most of the patients who had an OCT were seen between 2011 and 2013. This is due to the fact that OCT was not common and therefore not affordable to most of the patients, but has over the years become more readily available and cheaper and therefore more patients are now being more objectively assessed using OCT.

Surgical Technique

Most of the eyes in our study underwent PPV with conventional ILM peeling, while Inverted ILM flap technique was mainly considered for eyes with large, old holes.

The tamponade agent used in majority of the eyes was SF₆. SF₆ was preferred in our cases as it has a faster reabsorption rate than C₃F₈ .Therefore, patients would have faster visual recovery post surgery and would require fewer days of post operative face down positioning. C₃F₈ was used mainly for patients who needed longer tamponade due to other co-existing problems like diabetic retinopathy with traction on the macular hole.

Kim SS *et al* found that using SF₆ and C₃F₈ for IMH surgery yielded similar anatomic, visual outcomes and rates of cataract formation at 6 months, but C₃F₈ caused a larger myopic shift⁵⁶ while Jackson TL *et al* in the United Kingdom National Ophthalmology Database Study of vitreoretinal surgery reported no difference in the visual outcomes whether C₂F₆, C₃F₈, SF₆ or air was used.²

Silicone Oil can also be used for tamponade in macular hole surgery but studies have found that the final visual outcomes with silicone oil may not be as good as with gas tamponade^{57,58}. This may be related to toxicity of the oil to the RPE. Also it requires a second operation to remove the oil. However, it has the advantage that it does not require face–down positioning post–operatively and this is very important in patients with diseases like arthritis or in patients with altitude restrictions.

Also in our cases, a lower concentration of SF₆ was used (18-20%) and yet the majority of the eyes had very good anatomic and visual outcome. Using higher concentrations may therefore be unnecessary and have no added benefit in terms of final outcome of surgery.

Intra operative endolaser and cryopexy was done for four eyes which developed intra operative retinal tears and one which developed a localized retinal detachment.

Anatomic Outcome.

Out of the 57 eyes which were operated, 54 (94.7%) had anatomical closure with 83% of these being Type1 closures. This was comparable to a study by Hager A et al³⁴ in which they found a 92.2% closure rate and also other studies which have shown successful anatomic closures of between 80% - 100%.^{4, 32, 33}

All the eyes which had non closure had symptoms of more than 6months and were more than 400µm in size. Ullrich S et al who looked at macular hole size as a prognostic factor found that preoperative hole diameters of more than 400µm have shown reduced first surgery closure.³⁸ Ip MS et al also reported a higher success rate with holes less than 400µm³³ although Mester et al reported that the hole size had no influence on the outcome of macular hole surgery.⁴³ Studies have also shown better prognosis in holes of less than 6months duration.^{31, 46}

Both idiopathic and traumatic holes had statistically similar closure rates although the traumatic holes in our study were very few. Two of the holes which failed to close were idiopathic while one was traumatic.

There was a trend towards association between Type1 closure and symptoms duration of less than 6months and hole size <400µm, but this did not reach statistical significance. This may have been due to the small number of patients in our study. Kang SW et al³⁵ described Type1 and Type2 closures and found that smaller pre-operative hole size and shorter duration of symptoms was associated with Type1 closure.

Functional (Visual) Outcome.

39 eyes (68.42%) had a visual improvement of ≥ 2 Snellen lines at the last follow up visit. 9 eyes (15.8%) had their vision preserved (no change from the pre-operative vision), while 3eyes had worse vision than the pre-operative BCVA.

At 1 month post – op, only 21% (12/57) of eyes had improvement of ≥ 2 lines, this increased to 41.5% (22/57) at 3months, 50% (18/36) at 6months and 80.9% (17/21) at 1 year follow up. This could be explained by the fact that at 1 month some of the patients may still have had some unabsorbed gas in their eyes and also improvement in vision after successful macular hole surgery has been reported to be continuous and a long-standing process with improvement reported from 6months to even 2years after surgery.⁴⁰

The steep increases in percentage with improvement between 6months and 1year could also be contributed to the fact that most patients who developed cataract post macular hole surgery had cataract surgery during this period and also may be due to the low number of patients who had follow up beyond 6months.

There was a trend towards association between symptoms of ≤ 6 months and hole size $\leq 400\mu\text{m}$ and visual improvement as suggested by the OR (3.03 and 2.43 respectively) but this did not reach statistical significance. This was most likely due to the small sample size in our study. Studies have shown that shorter duration of symptoms and smaller pre – operative hole size are a good prognostic factor for improvement in vision post macular hole surgery^{33,31,46} though some authors have reported the hole diameter and duration of symptoms did not correlate significantly with post operative visual outcome.^{23,59}

In our study we also found that traumatic macular holes (which traditionally were not operated on because it was thought there would be no visual improvement) had significant improvement in vision with 86% of the eyes with traumatic holes achieving improvement in vision with 71% having improvement more than 3 Snellen lines. The improvement in vision in traumatic holes may be related to the pathogenesis of traumatic holes which involves concussive forces in a coup contracoup manner causing immediate rupture at the thin foveola. Therefore there is usually no retinal opercula over the macula hole as seen in idiopathic holes which implies that there is minimal loss of neurosensory foveal retina. Thus, release of the tangential traction exerted by the posterior hyaloids allows good approximation of the hole edges with restoration of the foveal retina near its original position with no or a small residual defect allowing the glial tissue to connect the hole edges completely.

It was also noted that in our study, patients with traumatic holes presented much earlier than those with idiopathic holes and therefore the hole could be closed before significant degeneration of photoreceptors occurs. This early presentation of patients with traumatic holes is usually because the patient notices an abrupt loss of visual acuity after the trauma or because of other concurrent injuries. Also the mean age of patients with traumatic holes was much younger (34.6 years) which may allow better healing processes.

Outcome Related To Surgical Technique.

For holes larger than $400\mu\text{m}$, inverted flap had a 100% closure compared to 89.3% closure rate for ILM peel only and visual improvement of ≥ 2 lines was noted for all large holes which underwent inverted flap compared to only 50% in ILM peel only.

Inverted flap technique was also seen to be more beneficial than ILM peel alone for older holes (holes older than 6 months duration). 100% had vision improvement with inverted flap compared to only 45.8% with ILM peel alone. While anatomic hole closure was statistically similar with both methods it was achieved in 100% of eyes with old holes undergoing inverted flap technique compared to 91.7% with ILM peel alone.

These findings were similar to a study done by Michalewska Z et al, in which they showed that inverted flap technique gave closure rates of 98% and better post operative visual acuity than standard ILM peel for holes larger than $400\mu\text{m}$.²⁷

The success of inverted flap technique has been described by histopathologic findings which have shown that the ILM serves as a scaffold for gliosis, it enables glial cell proliferation which fills up the macular hole defect and the photoreceptor cells follow this gliosis and reapproximate over the foveal defect over time. This leads to normalization of the foveal contour and visual improvement.

Complications.

Overall 36 eyes (63.16%) developed post – operative complications, the most common complication being cataract formation, which occurred in 21 out of 47 patients (44.68%). 9 eyes out of the 57 operated were pseudophakic by the time they underwent macular hole surgery while 1 eye was aphakic secondary to trauma. Cataract formation has been seen as a frequent complication of macular hole surgery in many studies,^{2,24} even as much as 75% of patients in a review of over 400 citations on macular hole surgery by Benson WE et al.²⁴ In our study 15 eyes out of 21 (76%) who developed cataract underwent cataract surgery by the time of their last follow up visit.

The next common complication was high IOP (12.28%). The mean duration at which the patients developed high IOP was 1.2 weeks post surgery (range 1day – 4weeks). In a study done by Chen CJ, they found increased intra ocular pressure post macular hole surgery was transient in most cases and was seen to occur mostly within the 1st post – operative week.⁵⁵ All the spikes in IOP (except 2) in our study were transient and successfully controlled by medical management. Two patients had developed high IOP due to expansion of the gas in the eye secondary to travelling to high altitude areas immediately after the operation. Both of these underwent gas tapping to decrease the IOP but unfortunately vision could not be salvaged in both these eyes. Ferrini W et al⁶⁰ reported 2 cases of patients who underwent PPV and SF₆ tamponade for retinal detachments and developed expansion of gas in the eye on travelling to an area 600m higher than where they were operated on within the first post operative week. Fang et al⁶¹ have also reported a case of a patient who underwent PPV with gas tamponade for a retinal detachment and then travelled to an altitude of 6210 feet and developed expansion of the gas in the eye leading to central retinal artery occlusion (CRAO).

Few complications like retinal detachment and breaks were seen in this study and this may be attributed to the surgical technique whereby PVD was induced only upto or just beyond the arcades, the rest of the vitreous detachment was natural or by hydrodissection . Inducing a PVD all the way beyond the equator actually leads to higher frequency of retinal breaks and detachments.

We did not have any eyes develop RPE alterations. This may be attributed to lower dye exposure time during surgery (less than one minute) and actively removing the dye from the macula hole. Interestingly, we did not even see dye toxicity in patients undergoing inverted flap technique whereby the ILM with the stain is left in the macula hole. Therefore dye toxicity may not be a significant factor affecting outcome of macular hole surgery, although this needs to be confirmed by larger studies employing electroretinograms (ERG).

7.0 CONCLUSIONS

1. Most patients had successful anatomical closure post macular hole surgery and majority of these had Type 1 closure.
2. More than two-thirds of the eyes achieved improvement in vision of ≥ 2 lines post macular hole surgery.
3. All the holes which failed to close were $>400 \mu\text{m}$ in size.
4. Inverted flap technique compared to conventional ILM peel alone was associated with better outcome especially in terms of vision improvement in older and larger holes.
5. The most common complication post macular hole surgery was cataract formation, followed by high IOP.
6. Good outcomes were achieved even for traumatic macular holes.

8.0 RECOMMENDATION

1. Consider surgery for all macular holes regardless of size, duration and cause as good anatomic and functional outcomes occur in most patients including large, old and traumatic holes; although there was a trend towards better outcomes with holes $< 400\mu\text{m}$ in size and < 6 month symptom duration.
2. Consider inverted flap technique for larger and older holes as this technique was associated with better outcomes compared to standard ILM peel alone for these holes.
3. Inform patients not to travel to high altitude areas when gas is inserted in the eye as this will cause expansion and may cause complete loss of vision due to absolute glaucoma.
4. Carry out a study on risks versus benefit of combined cataract and macular hole surgery in our setup as many patients in our study developed cataract post macular hole surgery within a few months.
5. We also recommend a much larger study preferably prospective and with use of OCT for objective assessment of all the holes and outcomes of surgery.

REFERENCES

1. Duker JS, Kaiser PK, Binder S, de Smet MD, Gaudric A, Reichel E *et al.* The International Vitreomacular Traction Study Group classification of vitreomacular adhesion, traction and macular hole. *Ophthalmology* 2013 Dec; 120(12):2611-9.
2. Jackson TL, Donachie PH, Sparrow JM, Johnston RL. United Kingdom National Ophthalmology Database study of vitreoretinal surgery: Report 2, macular hole. *Ophthalmology* 2013 Mar; 120(3):629 – 34.
3. Risk factors for idiopathic macular holes. The Eye Disease Case-Control Study Group. *Am. J. Ophthalmology* 1994 Dec; 118(6):754 – 61.
4. la Cour M, Friis J. Macular Holes: Classification, Epidemiology, Natural history and Treatment. *Acta Ophthalmologica Scand.* 2002 Dec; 80(6):579 – 87.
5. Sen P, Bhargava A, Vijaya L, George R. Prevalence of idiopathic macular hole in adult rural and urban south Indian population. *Clin. Exp. Ophthalmol* 2008 Apr; 36(3):257 – 60.
6. Oh KT, Hughes BM, Atebara HN, Drouilhet JH, Phillpotts BA, Law SK *et al* Macular Hole . *Medscape* 2011 Jul.
7. Aaberg TM. Macular holes: a review. *Surv. Ophthalmol* 1970; 15:139 – 62.
8. Rajagopal R, Apte RS. Full-thickness macular hole in a patient with proliferative sickle cell retinopathy. *Retina (Philadelphia, Pa.)* 2010 May; 30(5):838 – 9.
9. Jin ZB, Gan DK, Xu GZ, Nao-IN. Macular hole formation in patients with Retinitis Pigmentosa and prognosis of pars plana vitrectomy . *Retina (Philadelphia, Pa.)* 2008 Apr; 28(4):610 – 4.
10. Sagara N, Kawaji T, Koshiyama Y, Inomata Y, Fukushima M, Tanihara H. Macular hole formation after macular haemorrhage associated with rupture of retinal arterial macroaneurysm. *Br J. Ophthalmol* 2009 Oct; 93(10):1337 – 40.
11. Shimada N, Ohno-Matsui K, Yoshida T, Futagami S, Tokoro T, Mochizuki M. Development of macular hole and macular retinoschisis in eyes with myopic choroidal neovascularisation. *Am. J. Ophthalmol.* 2008 Jan; 145(1):155 – 61.
12. Kunjukunju N, Navarro A, Oliver S, Olson J, Patel C, Garcia G *et al.* Bilateral macular hole formation secondary to scleroperetaria caused by shockwaves transmitted by a posterior vector: Case Report. *BMC Ophthalmol* 2010:6.
13. Fabian ID, Moisseiev E, Moisseiev J, Moroz I, Barak A, Alhalel A. Macular hole after vitrectomy for primary rhegmatogenous retinal detachment. *Retina (Philadelphia, Pa.)* 2012 Mar; 32(3):511–9.
14. Arevalo JF, Mendoza AJ, Velez-Vazquez W, Rodriguez FJ, Rodriguez A, Rosales-Meneses JL *et al.* Full thickness macular hole after LASIK for the correction of myopia. *Ophthalmology* 2005 Jul; 112(7):1207 – 12.
15. Papathanassiou M, Alonistiotis D, Petrou P, Theodossiadis P, Vergados I. Macular hole formation following phacoemulsification cataract surgery. *Clin Exp Optom* 2011 Jan; 94(1):112-4.
16. American Academy of Ophthalmology, Diseases of the Vitreous and Vitreoretinal interface, Retina and Vitreous. Basic and clinical science course, 2012-2013. San Francisco, American Academy of Ophthalmology 2012; 304-306.

17. Yanoff M, Duker J.S. Macular hole. *Ophthalmology* 3rd edition. Elsevier 2009; section 6.30.
18. Ezra E, Gregor ZJ. Surgery for idiopathic full-thickness macular hole: two-year results of a randomized clinical trial comparing natural history, vitrectomy and vitrectomy plus autologous serum: Morfields Macular Hole Study Group Report No. 1. *Arch. Ophthalmol.* 2004 Feb; 122(2):224 – 36.
19. Chew EY, Sperduto RD, Hiller R, Nowroozi L, Seigel D, Yanuzzi LA *et al.* Clinical course of Macular Holes: The Eye Disease Case–Control Study. *Arch. Ophthalmol.* 1999; 117(2):242 – 46.
20. Kim JW, Freeman WR, Azen SP, el-Haig W, Klein DJ, Bailey IL. Prospective randomized trial of vitrectomy or observation for stage 2 macular holes. Vitrectomy for Macula Hole Study Group. *Am. J. Ophthalmol.* 1996 Jun; 121(6):605 – 14.
21. Kelly NE, Wendel RT. Vitreous surgery for idiopathic macular holes. Results of a pilot study. *Arch. Ophthalmol.* 1991 May; 109(5):654 – 9.
22. Freeman WR, Azen SP, Kim JW, el – Haig W, Mishell DR , Bailey I. Vitrectomy for the treatment of full thickness stage 3 or 4 macular holes. Results of a multicentered randomized clinical trial. The Vitrectomy for Treatment of Macular Hole Study Group. *Arch. Ophthalmol* 1997 Jan; 115(1):11 – 21.
23. Haritoglou C, Reiniger IW, Schaumberger M, Gass CA, Priglinger SG, Kampik A . Five-year follow up of macular hole surgery with peeling of the internal limiting membrane: Update of a prospective study .*Retina* 2006Jul; 26(6):618 – 22.
24. Benson WE, Cruickshanks KC, Fong DS, Williams GA, Bloome MA, Frambach DA *et al.* Surgical management of macular holes: A report by the American Academy of Ophthalmology. *Ophthalmology* 2001 Jul; 108(7):1328 – 35.
25. Spiteri Cornish K, Lois N, Scott N, Burr J, Cook J, Boachie C *et al.* Vitrectomy with ILM peeling versus vitrectomy with no peeling for idiopathic full thickness macular holes. *Cochrane Database Syst Rev.* 2013: CD009306.
26. Mester V, Kuhn F. Internal limiting membrane removal in the management of full thickness macular holes. *Am. J. Ophthalmology.* 2000 Jun; 129(6):769 – 77.
27. Michalewska Z, Michalewski J, Adelman RA, Nawrocki J. Inverted internal limiting membrane flap technique for large macular holes. *Ophthalmology* 2010 Oct; 117(10):2018 – 25.
28. Kuriyama S, Hayashi H, Jingami Y, Kuramoto N, Akita J, Matsumoto M. Efficacy of inverted internal limiting membrane flap technique for the treatment of macular hole in high myopia. *Am. J. Ophthalmol* 2013Jul; 156(1):125 – 131.
29. Reis R, Ferreira N, Meireles A. Management of stage 4 macular holes: When standard surgery fails. *Case report Ophthalmology* 2012 May; 3(2):240 – 50.
30. Alpatov S, Shchuko A, Malyshev V. A new method of treating macular holes. *Eur J. Ophthalmol* 2007 Mar; 17(2):246 – 52.
31. Wendel RT, Patel AC, Kelly NE, Salzano TC, Wells JW, Novack GD. Vitreous surgery for macular holes. *Ophthalmology* 1993 Nov; 100(11):1671 – 76.
32. Hirneiss C, Neubauer AS, Gass CA, Reiniger IW, Priglinger SG, Kampik A, Haritoglou C. Visual quality of life after macular hole surgery: outcome and predictive factors. *Br J. Ophthalmol* 2007 Apr; 91(4):481 – 4.

33. Ip MS, Baker BJ, Duker JS, Reichel E, Baurnal CR, Gangnon R, Puliafito CA. Anatomical outcomes of surgery for idiopathic macular hole as determined by optical coherence tomography. *Arch. Ophthalmol* 2002 Jan; 120(1):29 – 35.
34. Hager A, Ehrich S, Wiegand W. Anatomical and functional results after elective macular surgery. *Ophthalmologe* 2005 Jun; 102(6):597 – 602.
35. Kang SW, Ahn K, Ham DI. Types of macular hole closure and their clinical implications. *Br. J. Ophthalmol.* 2003 Aug; 87(8):1015 – 9.
36. Tornambe PE, Poliner LS, Cohen RG. Definition of macular hole surgery end points: elevated/open, flat/open, flat/closed. *Retina* 1998; 18(3):286 – 7.
37. Imai M, Iijima H, Gotoh T, Tsukahara S. Optical coherence tomography of successfully repaired idiopathic macular holes. *Am. J. Ophthalmol* 1999 Nov; 128(5):621 – 7.
38. Ullrich S, Haritoglou C, Gass c, Schaumberger M, Ulbig MW, Kampik A. Macular hole size as a prognostic factor in macular hole surgery. *Br. J. Ophthalmology* 2002 April; 86(4):390-93.
39. Larsson J, Holm K, Lövestam – Adrian M. The presence of an opeculum verified by optical coherence tomography and other prognostic factors in macular hole surgery. *Acta Ophthalmol Scand* 2006 Jun; 84(3):301 – 4.
40. Leonard RE, Smiddy WE, Flynn HW, Feuer W. Long term visual outcomes in patients with successful macular hole surgery. *Ophthalmology* 1997 Oct; 104(10):1648 – 52.
41. Rayat J, Almeida DR, Belliveau M, Wong J, Gale J. Visual function and vision-related quality of life after macular hole surgery with short duration, 3- day face-down positioning. *Can. J. Ophthalmol.* 2011 Oct; 46(5):399 – 402.
42. Pearce IA, Branley M, Groenewald C, McGalliard J, Wong D. Visual function and patient satisfaction after macular hole surgery. *Eye (Lond.)* 1998;651 – 8.
43. Mester U, Becker M. Prognostic factors in surgery of macular holes. *Ophthalmologe* 1998 Mar; 95(3):158 – 62.
44. Tadayoni R, Gaudric A, Haouchine B, Massin P. Relationship between macular hole size and the potential benefit of internal limiting membrane peeling. *Br J. Ophthalmol.* 2006 Oct; 90(10):1239 – 41.
45. Solebo AL, Lange CA, Bunce C, Bainbridge JW. Face down positioning or posturing after macular hole surgery. *Cochrane Database Syst Rev* 2011;(12): CD008228.
46. Ryan EH, Gilbert HD. Results of surgical treatment of recent-onset full-thickness idiopathic macular holes. *Arch. Ophthalmol.* 1994 Dec; 112(12):1545 – 53.
47. Salter AB, Folgar FA, Weissbrot J, Wald KJ. Macular hole surgery prognostic success rates based on macular hole size. *Ophthalmic Surg Lasers Imaging* 2012 May; 43(3):184 – 9.
48. Jaycock PD, Bunce C, Xing W, Thomas D, Poon W, Gazzard G et al. Outcomes of macular hole surgery: implications for surgical management and clinical governance. *Eye (Lond.)* 2005 Aug; 19(8):879-84.
49. Banker AS, Freeman WR, Kim JW, Munguia D, Azen SP. Vision threatening complications of surgery for full thickness macular holes. Vitrectomy for Macular Hole Study Group. *Ophthalmology* 1997 Sep; 104(9):1442 – 52.

50. Hotta K, Hirakata A, Shinoda K, Miki D, Hida T. Posterior segment complications after macular hole surgery. *Nippon Ganka Gakkai Zasshi* 1997 Oct; 101(10):808 – 13.
51. Park SS, Marcus DM, Duker JS, Pesavento RD, Topping TM, Frederick AR, D'Amico DJ. Posterior segment complications after vitrectomy for macular hole. *Ophthalmology* 1995; 102(5):775 –81.
52. Pendergast SD, McCuen BW. Visual field loss after macular hole surgery. *Ophthalmology* 1996; 103(7):1069 – 77.
53. Thapa R, Paudyal G. Anatomical and visual outcome following macular hole surgery at a tertiary eye care centre in Nepal. *JNMA J Nepal Med Assoc* 2011 Jul – Sep; 51(183):122 – 7.
54. Bhatnagar P, Kaiser PK, Smith SD, Meisler DM, Lewis H, Sears JE. Reopening of previously closed macular holes after cataract extraction. *Am. J. Ophthalmol.* 2007 Aug; 144(2): 252-9.
55. Chen CJ. Glaucoma after macular hole surgery. *Ophthalmology* 1998 Jan; 105(1):94-9.
56. Kim SS, Smiddy WE, Feuer WJ, Shi W. Outcomes of SF₆ versus C₃F₈ gas tamponade for macular hole surgery. *Retina (Philadelphia, Pa.)* 2008Nov; 28(10):1408 – 15.
57. Tafoya ME, Lambert HM, Vu L, Ding M. Visual outcomes of silicone oil versus gas tamponade for macular hole surgery. *Semin Ophthalmol* 2003 Sep; 18(3):127 – 31.
58. Lai JC, Stinnett SS, McCuen BW. Comparison of silicone oil versus gas tamponade in the treatment of idiopathic full-thickness macular hole. *Ophthalmology* 2003 Jun; 110(6):1170 – 4.
59. Amari F, Ohta K, Kojima H, Yoshimura N. Predicting visual outcome after macular hole surgery using scanning laser ophthalmoscope microperimetry . *Br J Ophthalmol* 2001 Jan; 85(1):96-8
60. Ferrini W, Pournaras JA, Wolfensberger TJ. Expansion of intraocular gas bubbles due to altitude: do meteorological factors play a role? *Klin Monbl Augenheilkd* 2010 Apr; 227(4):312-4.
61. Fang IM, Huang JS. Central retinal artery occlusion caused by expansion of intraocular gas at high altitude. *Am. J. Ophthalmol.* 2002 Oct; 134(4): 603-5.

APPENDIX I

QUESTIONNAIRE

PART A: PRE – OP

I. DEMOGRAPHICS

- 1. Patients Number:
- 2. Age:
- 3. Gender: MALE FEMALE

II. HISTORY

- 1. Symptoms duration:
- 2. Eye Affected: OD OS OU
- 3. Any other ocular disease/s:
- 4. Any other co-morbid condition/s:
- 5. Macular hole: PRIMARY RECURRENT
- 6. Cause of Macular Hole:

III. EXAMINATION

- 1. Size of macular hole: Clinically: OCT:
- 2. Cuff of subretinal fluid: Present Absent

IV. DATE OF DIAGNOSIS:

V. DATE OF SURGERY:

PART B: INTRA – OP

I. TYPE (TECHNIQUE) OF SURGERY DONE:

- | | | | | |
|-----------------------------|-------|--------------------------|-----|--------------------------|
| 1. Vitrectomy: | YES | <input type="checkbox"/> | NO | <input type="checkbox"/> |
| 2. Fluid gas exchange: | YES | <input type="checkbox"/> | NO | <input type="checkbox"/> |
| 3. Tamponade Agent: | AIR | <input type="checkbox"/> | GAS | <input type="checkbox"/> |
| 4. Endolaser: | YES | <input type="checkbox"/> | NO | <input type="checkbox"/> |
| 5. Cryopexy: | YES | <input type="checkbox"/> | NO | <input type="checkbox"/> |
| 6. ILM Peeling: | YES | <input type="checkbox"/> | NO | <input type="checkbox"/> |
| 7. Inverted Flap technique: | YES | <input type="checkbox"/> | NO | <input type="checkbox"/> |
| 8. Type of Anesthesia: | LOCAL | <input type="checkbox"/> | G/A | <input type="checkbox"/> |
| 9. ERM peeling: | YES | <input type="checkbox"/> | NO | <input type="checkbox"/> |

SILICONE OIL

10. Any other procedure/s

II. INTRA – OP COMPLICATIONS

Lens touch

Vitreous Hemorrhage (VH)

Retinal breaks / RD

Hole enlargement

Others

PART C: POST – OP

I. Post-op face down positioning: YES NO

II. Hole closed:

On Day 1:	YES <input type="checkbox"/>	NO <input type="checkbox"/>
At week 1:	YES <input type="checkbox"/>	NO <input type="checkbox"/>
At 1month:	YES <input type="checkbox"/>	NO <input type="checkbox"/>
At 3months:	YES <input type="checkbox"/>	NO <input type="checkbox"/>
At 6months:	YES <input type="checkbox"/>	NO <input type="checkbox"/>
At 1year:	YES <input type="checkbox"/>	NO <input type="checkbox"/>
At 2years:	YES <input type="checkbox"/>	NO <input type="checkbox"/>
At 3years:	YES <input type="checkbox"/>	NO <input type="checkbox"/>
At 4years:	YES <input type="checkbox"/>	NO <input type="checkbox"/>
At 5years:	YES <input type="checkbox"/>	NO <input type="checkbox"/>
At 6years:	YES <input type="checkbox"/>	NO <input type="checkbox"/>
At 7years:	YES <input type="checkbox"/>	NO <input type="checkbox"/>
At 8years:	YES <input type="checkbox"/>	NO <input type="checkbox"/>
At 9years:	YES <input type="checkbox"/>	NO <input type="checkbox"/>
At 10years:	YES <input type="checkbox"/>	NO <input type="checkbox"/>

III. How was Hole Closure assessed: CLINICALLY OCT

IV. Type of hole closure: TYPE 1 TYPE 2

V. Date of last follow-up:

VI. Post-op complications:

When Occurred (A,B or C):

- | | | |
|---------------------------|--------------------------|--------------------------|
| ▪ Failure of hole closure | <input type="checkbox"/> | <input type="checkbox"/> |
| ▪ Reopening of hole | <input type="checkbox"/> | <input type="checkbox"/> |
| ▪ RD/tears | <input type="checkbox"/> | <input type="checkbox"/> |
| ▪ VH | <input type="checkbox"/> | <input type="checkbox"/> |
| ▪ Cataract | <input type="checkbox"/> | <input type="checkbox"/> |
| ▪ CMO | <input type="checkbox"/> | <input type="checkbox"/> |
| ▪ Visual Field Defects | <input type="checkbox"/> | <input type="checkbox"/> |
| ▪ Corneal decompensation | <input type="checkbox"/> | <input type="checkbox"/> |
| ▪ Endophthalmitis | <input type="checkbox"/> | <input type="checkbox"/> |
| ▪ RPE Changes | <input type="checkbox"/> | <input type="checkbox"/> |
| ▪ CNV | <input type="checkbox"/> | <input type="checkbox"/> |
| ▪ Other/s | <input type="checkbox"/> | <input type="checkbox"/> |

NB: When did above complication occur?

A = Immediate post-op (within 1 week)

B = Early post-op (between 1 week and 1 month)

C = Late post op (beyond 1 month)

VII. IOP

Pre Op OD:

OS:

Post Op (operated eye)

On Day 1:

At 1 Week:

At 1 Month:

VIII. Visual Acuity (BCVA)

Pre Op (uncorrected) OD:..... OS:

Pre Op (BCVA) Snellen OD: OS:

Post Op (BCVA)

At 1week: OD: OS:

At 1month: OD: OS:

At 3months: OD: OS:

At 6months: OD: OS:

At 1year: OD: OS:

At 2years: OD: OS:

At 3years: OD: OS:

At 4years: OD: OS:

At 5years: OD: OS:

At 6years: OD: OS:

At 7years: OD: OS:

At 8years: OD: OS:

At 9years: OD: OS:

At 10years: OD: OS:

IX. Any further intervention/s needed? YES NO

X. If YES, what intervention/s was/were needed?

XI. Date of further intervention if any:

Duration of further intervention after primary surgery :

APPENDIX II

MACULA HOLE SURGERY: PROCEDURE AS DONE AT PCEA KIKUYU EYE UNIT

Pre op assessment

1. Symptomatology is assessed
2. BCVA
3. Slit lamp & indirect ophthalmoscopy examination to evaluate the macula hole, sizing and determine the type of surgery required
4. Informing the patient of the surgery, possible outcomes and complications
5. Booking the patient for the surgery

Surgical Procedure

1. Dilation with topical Tropicamide and Phenylephrine. Topical anesthesia to assist dilation and introduce patient comfort.
2. Topical NSAID drops.
3. Cleaning with 5% Povidone Iodine solution
4. Administration of local anesthesia (combination of lignocaine and Marcaine)
5. Patient is cleaned and sterile draped.
6. The choice of PPV is either 20G or 23G set up. Earlier procedures were predominantly 20G based on availability.
7. The Vitrectomy is done using either the DORC associate Dual 6000 or Alcon Accurus Vitrectomy machines.
8. Core Vitrectomy is done followed by PVD induction at the posterior pole. The PVD is not force induced to the periphery. Vitreous is trimmed to extent possible.
9. The ILM is stained using Infracyanine Green a vital dye for less than one minute.
10. The peeling is initiated using a DDMS (diamond dusted membrane spatula) and the peeling is done with a DORC ILM forceps. The peeling is done upto the arcades, the disc nasally and approximately 2DD temporally. Depending upon the hole size, an inverted flap may be done.
11. The eye is fully examined with depression of the periphery to ensure no pathology is left unaddressed.
12. Fluid gas exchange is done, followed by either SF6 or C3F8 gas insertion.
13. Eye is closed and finger tension is done to ensure correct eye pressure.
14. Instillation of Povidone Iodine 1% drops, Atropine followed by Maxitrol ointment

Post Operative Management

1. Patient is advised face down position immediately after surgery for a period of 7 to 10 days
2. Instillation of moxifloxacin eye drops for one week, tapering schedule of topical prednisolone acetate 1% over a period of 5 weeks.
3. Patient is seen on post op day 1, week 1, one month and 3 months when visual assessment is done. IOP is checked and retinal assessment is done along with hole closure evaluation.
4. Where indicated and as per the patients financial ability, OCT is done pre op and post op to evaluate the macula hole.