

**LATENT ASSOCIATED NUCLEAR ANTIGEN-1 EXPRESSION IN TUMOURS
DIAGNOSED AS KAPOSI SARCOMA AND IN TUMOURS THAT
MORPHOLOGICALLY MIMIC KAPOSI SARCOMA AT KENYATTA NATIONAL
HOSPITAL**

DR BENJAMIN ESIABA NDIBILE (H58/64347/10)

MB.Ch,B (UNIVERSITY OF NAIROBI)

A dissertation submitted in partial fulfilment of the requirement for the award of Master of
Medicine in Human Pathology by the University of Nairobi

November, 2015

DECLARATION

I hereby declare that this dissertation is my original work and has not been presented to any other academic institution for evaluation for research and examination to the best of my knowledge.

NDIBILE, BENJAMIN ESIABA, MB.Ch,B. (H58/64347/2010)

Signature _____ Date _____

Supervisors' Approval

This dissertation has been submitted for the evaluation for research and examination with our approval as university supervisors.

1. PROF E.A ROGENA, MB.Ch,B(UoN),M.Med(Path),Msc(Forensic Path)
Department of Human pathology (Thematic unit of anatomic pathology) University of Nairobi

Signature _____ Date _____

2. Dr Zuriel Daniel MB.Ch,B (UoN), M.MED(Path), Dermopath(Frankfurt)

Department of Human pathology (Thematic unit of anatomic pathology) University of Nairobi

Signature _____ Date _____

UNIVERSITY OF NAIROBI DECLARATION FORM OF ORIGINALITY

<p>Name of Student: Benjamin Esiaba Ndibile</p> <p>Registration number: H58/64347/2010</p> <p>College: College of Health Science</p> <p>Faculty/School/Institute: School of Medicine</p> <p>Department: Department of Human Pathology</p> <p>Course Name: Master of Medicine in Human Pathology</p> <p>Title of the work: Latent Associated Nuclear Antigen-1 Expression in tumours Diagnosed as Kaposi sarcoma and in tumours that morphologically mimic Kaposi sarcoma at Kenyatta National Hospital</p>

1. I understand what Plagarism is and I am aware of the University’s policy in this regard.
2. I declare that this dissertation is my original work and has not been submitted elsewhere for examination, award of degree or publication. Where other people’s work or my own work has been used, this has properly been acknowledged and referenced in accordance with the University of Nairobi’s requirement.
3. I have not sought or used the services of any professional agencies to produce this work.
4. I have not allowed, and shall not allow anyone to copy my work with the intention of passing it off as his/her own work.
5. I understand that any false claim in respect of this work shall result in disciplinary action, in accordance with University Plagarism Policy.

Signature..... Date

DEDICATION

This work is dedicated to the Almighty God, my parents, siblings, wife; Dr. Caroline Esiaba and to our children Tracy, Lindsey and my late son Elvis for always believing in me.

ACKNOWLEDGEMENT

I thank my supervisors; Professor Emily A. Rogena and Dr. Zuriel Daniel who despite their busy schedule were always available to read through my work and make the necessary corrections.

I am particularly grateful to Mr. Kairu and Mr. Ochieng from the University of Nairobi; Histopathology laboratory, for the technical assistance I received from them.

I thank my professional colleagues, without whose support this work would not have been possible.

I thank my wife (Dr. Caroline N. Esiaba) and children (Tracy and Lindsey) for walking with me each step of the way and above all my gratitude goes to the Almighty God for having brought me this far.

LIST OF ABBREVIATIONS

AIDS	Acquired Immunodeficiency Syndrome
ART	Antiretroviral therapy
CD8	Cluster of differentiation 8
CDC	Center of Disease control
CT	Computed tomography
DAB	Diamino-Benzidine
DNA	Deoxyribonucleic acid
DPX	Distyrene Plasticizer Xylene
EDTA	Ethylenediaminetetraacetic acid
ERC	Ethics Research Committee
GI	Gastrointestinal
HAART	Highly active antiretroviral therapy
H&E	Haematoxylin and Eosin
HHV 8	Human herpes virus 8
HIV	Human immunodeficiency virus
IHC	Immuno-histochemistry
IL-6	Interleukin-6
IRF-3	Interferon regulatory factor-3
KAIS	Kenya Aids Indicator Survey

KNH	Kenyatta National Hospital
KS	Kaposi sarcoma
LANA-1	Latent associated nuclear antigen 1
LLKS	Lymphangioma Like Kaposi sarcoma
MCD	Multicentric castlemans disease
MSM	Males having sex with males
NNRTI	Nonnucleoside reverse transcriptase inhibitor
ORF 25	Open reading frame 25
ORF 50	Open reading frame 50
ORF 57	Open reading frame 57
PEL	Primary effusion lymphoma
PG	Pyogenic granuloma
SPSS	Statistical Package for Social Sciences
STD	Sexually transmitted disease.
VEGF	Vascular endothelial growth factor
v FLIP	Viral Fas-ligand interleukin.

TABLE OF CONTENTS

DECLARATION	ii
UNIVERSITY OF NAIROBI DECLARATION FORM OF ORIGINALITY	iii
DEDICATION	iv
ACKNOWLEDGEMENT	v
LIST OF ABBREVIATIONS	vi
TABLE OF CONTENTS	viii
LIST OF FIGURES	x
LIST OF TABLES	xi
ABSTRACT	xii
1. BACKGROUND AND INTRODUCTION	1
2. REVIEW OF LITERATURE.....	3
2.1 Pathogenesis of Kaposi Sarcoma.	3
2.2 Epidemiology	5
2.3 Laboratory diagnosis	8
2.3.1 Histomorphology	8
2.3.2 Immunohistochemistry:	8
3. STUDY JUSTIFICATION AND RATIONALE	10
4. RESEARCH QUESTION	10
4.1 Broad objective	10
4.2 Specific objectives.....	10
5. STUDY DESIGN, MATERIALS AND METHODS	11
5.1 Study design	11
5.2 Study setting.....	11
5.3 Study subjects.....	11
5.4 Study duration	11
5.5.1 Inclusion criteria.....	11
5.5.2 Exclusion criteria.....	12
5.6 Sample size determination	12
5.7 Sampling method.....	13

5.9 Materials	13
5.9.1 Equipment	13
5.9.2 Reagents and other consumables	13
5.10 Methods	13
5.10.1 Paraffin embedded block retrieval	13
5.10.2 Histological preparation-Haematoxylin & Eosin for light microscopy	13
5.10.3 Immunohistochemistry controls	14
5.10.4 Quality assurance.....	14
5.10.6 Data management and analysis	14
6. RESULTS.....	16
7. DISCUSSION	25
7.1 CONCLUSIONS	27
7.2 RECOMMENDATIONS	27
7.3 STUDY LIMITATION	27
REFERENCES	28
APPENDIX I: DATA CAPTURE SHEET.....	31
APPENDIX II: LATENT ASSOCIATED NUCLEAR ANTIGEN-1 IMMUNOHISTOCHEMICAL STAINING PROCEDURE	32
APPENDIX III: HARRIS HAEMATOXYLIN AND EOSIN STAINING PROCEDURE	34
APPENDIX IV: ETHICS AND RESEARCH COMMITTEE APPROVAL LETTER	35

LIST OF FIGURES

Figure 1: Distribution of cases by gender-----	18
Figure 2: Patient HIV status-----	19
Figure 3: Site of the lesion-----	19
Figure 4: Histomorphological diagnosis before review-----	20
Figure 5: Histomorphological diagnosis after review-----	20
Figure 6: Stratification of Kaposi sarcoma by stage of progression-----	21
Figure 7: Histomorphological and immunohistochemical findings of some of the cases in the study-----	24-25

LIST OF TABLES

Table 1: Association of LANA-1 expression with different variables-----	22
Table 2: Concordance rate-----	23

ABSTRACT

Background: Kaposi sarcoma(KS) mimics a variety of non-KS lesions histomorphologically like bacillary angiomatosis and pyogenic granuloma; therefore posing a diagnostic challenge to many histopathologists. Latent anti-nuclear antigen-1 (LANA-1) is expressed in all cells infected by the virus, therefore immunohistochemical identification of HHV8 LANA-1 is the gold standard in the diagnosis of KS.

Study objective: The main objective of this study was to evaluate LANA-1 expression in KS and its histomorphological mimics at KNH.

Study design: The study design was a laboratory based descriptive retrospective study.

Study setting: The study was carried out at KNH and UoN histopathology laboratories.

Study duration: The study was done on cases reported between 1st January 2012 to 31st December 2013 at Kenyatta National Hospital and the study was done between January 2015 and March 2015.

Study population: Cases previously reported as Kaposi sarcoma and those that morphologically mimic KS.

Materials and methods: Fifty one cases previously diagnosed as Kaposi sarcoma and those that morphologically mimic Kaposi sarcoma were analyzed for the expression of LANA-1 by immunohistochemistry on paraffin embedded blocks. Latent associated nuclear antigen-1 expression was correlated with age, sex, HIV status, site of the lesion and stage of progression of the lesion.

Results: The males were 27(52.9%) while the females were 24(47.1%). M:F was 1.1:1. Mean age was 36.9 years while the median was 34.0 years. Sixteen cases (31%) had HIV status indicated whereas 35 cases (69%) did not. There was a positive correlation between KS and HIV status with a p-value of <0.001. Thirty two cases (62.7%) were skin lesions, 13 cases were from oral cavity (25.5%), two were lymph nodes (3.9%) and 4(7.8%) of the cases were from other sites. There was no correlation between KS and site of the lesion (p-value of 0.343). Thirty five cases (68.6%) had previously been diagnosed as KS and 16 cases as mimics. Thirteen cases of the mimics were pyogenic granuloma, two dermatofibromas and

one cavernous haemangiomas. The KS cases after review (n=33) were stratified according to the stage of progression and the outcome was as follows; twenty seven(81.8%) of the cases were in nodular stage, one case(3%) was in plaque stage and five cases (15.2%) were in patch stage. There was no correlation between KS and the stage of progression (p-value of 1.000). LANA-1 expression was 97% in cases which had previously been diagnosed as KS while none of the mimics was positive for LANA-1 (p-value <0.001).

Conclusion: Early patch stage KS lesions pose a diagnostic challenge and therefore HHV-8 LANA-1 immunohistochemistry aids in definitive diagnosis.

Recommendations: Latent associated nuclear antigen-1 immunohistochemistry should be recommended for early patch stage KS lesions to differentiate early KS from its mimics.

1. BACKGROUND AND INTRODUCTION

Kaposi sarcoma (KS) was first described by a Hungarian dermatologist Moritz Kaposi in 1872 as an idiopathic multiple pigmented sarcoma of the skin(1).It is an angioproliferative tumour that usually develops in the skin and eventually disseminates to multiple cutaneous sites, viscera and lymph nodes (1).

Previously rare , KS is now a global health care problem because of its association with the HIV pandemic and other immunosuppressed states (2). In Kenya, the HIV prevalence has reduced from 14% in the mid-90s to 5.6% as at 2012 (36). According to the Cancer incidence report of 2011 from the Nairobi Cancer Registry, the incidence of KS in Nairobi Kenya is 3.8/100,000 in male adults and 2.0/100,000 in female adults (3).

Kaposi sarcoma mimics a variety of non-KS lesions histomorphologically like bacillary angiomatosis, pyogenic granuloma, microvenular hemangioma and tumours with a spindle cell component like spindle cell haemangioma, spindle cell angiosarcoma and dermatofibroma (4) therefore posing a diagnostic difficulties to many histopathologists hence the need for this study. In KS lesions, HHV-8 is the causative virus and is found in the tumour spindle cells but also in lymphocytes, monocytes and keratinocytes. The Latent associated nuclear antigen-1(LANA-1) of HHV-8 is expressed in all cells infected by the virus (5).

The immunohistochemical identification of HHV-8 LANA-1 is the gold standard in the diagnosis of KS and helps in differentiating it from its mimics. It has a specificity, sensitivity and predictive value of 98.6%, 100% and 99% respectively according to a previous study done (6).

This study sought to assess the utility of LANA-1 immunohistochemistry in the diagnosis of KS and differentiating it from its morphological mimics and thereafter recommend its adoption at Kenyatta National Hospital. Studies have been done worldwide to assess the utility of LANA-1 in differentiating KS from its mimics. In a study done in South Korea by Wah Cheuk et al in 2004, all KS cases showed nuclear staining for HHV-8 LANA-1 whereas all the KS mimics negatively stained for HHV-8 LANA-1 (6).

In a study done in South Africa by Louis-Jacques Van Bogaert et al, (2012) in Limpopo Province, there was a 9.2% histopathological discordance between the pre and post immunohistochemical diagnosis of Kaposi sarcoma (31).

2. REVIEW OF LITERATURE.

2.1 Pathogenesis of Kaposi Sarcoma.

Human herpes virus-8(HHV-8) is a gamma virus belonging to the herpes virus family and is etiologically associated with all forms of Kaposi sarcoma. In addition to KS, HHV-8 is also implicated in primary effusion lymphoma (PEL) and multicentric Castleman's disease (MCD) (8,9). HHV-8 virus is acquired through sexual transmission, by mother to child transmission during pregnancy or delivery, or by close non-sexual contacts. Three important facts implicate HHV-8 in the pathogenesis of KS.

First, the DNA sequences of all KS variants contain HHV-8 DNA, secondly anti-HHV-8 antibodies are present in individuals at high risk of developing KS, and lastly the development of KS is preceded by the seroconversion of HHV-8 (10, 11). Human herpes virus-8 is vital for the development of KS. And the pathogenesis of KS is associated with several HHV-8 genes which are oncogenic (12). In immunocompetent individuals, HHV-8 establishes latent infection following an acute infection. During latent infection, HHV-8 evades the host immune surveillance and establishes persistent infection.

Latent infection has an important role in the development of HHV-8 associated malignancies because most tumor cells in KS, PEL and MCD are latently infected by HHV-8. In immunocompromised hosts, HHV-8 latently infected cells can be reactivated expressing all viral lytic genes and producing infectious virions. The first lytic gene to be expressed is an immediate early gene ORF50 followed by ORF57 and late genes such as major capsid protein ORF25. Viral DNA replication capsid packaging and virion maturation also follow the expression of viral lytic genes, leading to the completion of viral replication cycle (13).

For herpesviruses, lytic replication not only produces infectious virions for spreading but causes their associated diseases. For HHV-8, viral lytic products and denovo infection promotes cell proliferation, angiogenesis and local inflammation, leading to the initiation and progression of KS tumours (14,15,16). In KS tumours, a small subset of cells also undergoes spontaneous lytic replication. Inhibition of HHV-8 lytic replication with antiherpesviral drugs that block lytic replication causes KS tumour regression (17,18).

The host immune surveillance plays a significant role in eliminating the virus during an acute infection and stabilizing viral load levels during an acute infection and throughout lifelong persistent infection. However, it is unknown whether host immune responses directly suppress HHV-8 lytic replication or the target cells triggers a rapid secretion of interferon-beta (IFN- β) and activates interferon regulatory factor 3(IRF-3) to induce the expression of host IFN-stimulated antiviral genes. Interferon alpha (IFN- α) blocks the initiation of lytic replication while interferon-gamma inhibits the late steps of lytic replication. Latent associated nuclear antigen (LANA), v FLIP and vCyclin are located in the latency locus and are expressed during latency(19).

LANA-1 inhibits the functions of p53, subsequently blocking apoptosis. Viral cyclin (vCyclin) inhibits cell cycle arrest and aviral Fas-ligand interleukin (v FLIP) protects virally infected cells from apoptosis (19). The HHV-8 lytic genes also produces a homologue of IL-6 which directly promotes proliferation of HHV-8 infected cells and indirectly induces the expression of vascular endothelial growth factor (VEGF) and cellular IL-6 resulting in proliferation of uninfected cells and angiogenesis (20).

Human immunodeficiency virus (HIV) co-infection is also an important factor in the pathogenesis of KS. During primary infection, HIV replicates rapidly in lymphoid tissue resulting in a surge in viraemia (21). The virus escapes immune mediated clearance despite an immune response being mounted following primary infection. A state of chronic infection is then established characterised by variable degree of viral replication and a chronically activated immune system (21).

Human immune deficiency virus Tat protein, a transcriptional activator of HIV gene expression is plays an important role in the pathogenesis of KS by directly promoting HHV-8 replication and is released by HIV infected T-cells into the extracellular matrix where it synergises with upregulated cytokines and growth factors to promote angiogenesis and the progression of KS(21).

2.2 Epidemiology

Before the discovery of Human immunodeficiency virus (HIV), Kaposi sarcoma(KS) was rare, being mostly isolated in elderly men of Mediterranean, Jewish or African descent (22). Patients on immunosuppressants following organ transplantation also accounted for a small number of cases. During the 1980s, the increased number of cases of Acquired immune deficiency syndrome(AIDS) was associated with an increased incidence of KS. Fortunately, the widespread use of highly active antiretroviral therapy has reduced the number of patients who develop KS. However, KS remains the most frequently reported cancer in areas where the underlying rate of HHV-8 seropositivity is high (23).

The incidence of KS in HIV infected individuals is increasing in Sub-Saharan Africa, where there is limited access to Anti-retroviral therapy. Although KS was endemic in Central and East Africa before AIDS, AIDS related KS has become the most frequently diagnosed tumor in several African countries (24,25).

All forms of KS are more common in men than women. In the absence of immunosuppression, KS is currently estimated to be 3 to 4 times more common in men but even higher male to female ratios have been reported for the classic and African endemic forms of the disease (25).

The risk of KS varies in different HIV risk groups and has changed over time. Multistate AIDS-Cancer Match Registry data through 1990 showed a relative risk of 106,000 fold in MSM and 13,000 fold in people exposed to HIV through injection drug use or heterosexual activity as compared with the general population (7). At the beginning of the epidemic, 40-50% of MSM with AIDS developed KS whereas the proportion had fallen to <15% by the late 1980s. By contrast only 10% of injection drug users, 4% of haemophiliacs and 3% of children with AIDS had KS as a presenting diagnosis (28).

In Nairobi Kenya, the Cancer incidence report of 2011 from the Nairobi Cancer Registry reported KS incidence of 3.8/100,000 in male adults and 2.0/100,000 in female adults (3). No studies have been done nationally to determine the national incidence and prevalence of Kaposi sarcoma.

Histomorphological variants related to progression

Patch stage KS represents the earliest phase in the progression of cutaneous KS and is the histologic variant that is likely to cause diagnostic difficulties. The initial low-power impressions are those of a mild inflammatory dermatosis. On closer examination there are signs of a subtle vasoformative process composed of newly formed slit-like or jagged vascular spaces which are more conspicuous in the immediate vicinity of native dermal vessels and skin appendages. The protrusion of these microscopic vascular structures into the lumens of more ectatic neoplastic channels results in the characteristic promontory sign. The intervening dermis frequently reveals dissection of its collagen bundles by slit-like vascular spaces lined by a monolayer of flattened endothelial cells with a variable degree of erythrocyte extravasation. The newly formed channels often contain red blood cells. There is also a mild background inflammatory cell infiltrate comprising lymphocytes and plasma cells often accompanied by hemosiderin-laden macrophages (26,27).

In plaque stage lesions of KS, the histologic picture is characterized by a more diffuse dermal vascular infiltrate, accompanied by greater cellularity and occasional extension of this process into the subcutaneous adipose tissue. The lesional cells tend to be more spindled and arranged in short fascicles. Mitotic figures are sparse and there is insignificant nuclear or cytological pleomorphism. Intra- and extracellular hyaline globules representing erythrocytes are often seen. Numerous dissecting vascular channels containing erythrocytes occupy the intervening dermis, and there is background plasma cell-rich contingent of chronic inflammatory cells with admixed siderophages and free-lying hemosiderin pigment. The promontory sign may also be encountered (26,27).

The nodular form of KS usually poses no diagnostic difficulties. However, a small ulcerated nodular KS lesion may be mistaken for a pyogenic granuloma. Nodular KS exhibits dermal expansion by a circumscribed variable cellular proliferation of neoplastic spindled cells arranged in fascicles. Erythrocytes are contained within slit-like channels between the individual spindled cells. Although careful inspection may reveal mitoses, the lesional cells are relatively monomorphic. The periphery of some nodular KS lesions may show more dilated vascular spaces imparting a pattern that is similar to that of a cavernous hemangioma. These larger congested channels are a vital part of the lesion as confirmed by positive immunohistochemical staining of the lining endothelial nuclei for HHV-8 latent nuclear antigen 1 (LANA-1). Large cutaneous nodules may frequently undergo ulceration. Superficial

shave biopsies of such lesions may be diagnostically challenging to the histopathologist as most of the specimen may contain only an inflammatory exudate with underlying granulation tissue which may be misinterpreted as pyogenic granuloma. Distinguishing between spindle cells from granulation tissue and lesional KS cells from the upper portion of an underlying KS nodule can be difficult without immunohistochemistry (26,27).

Mimics of Kaposi Sarcoma

The mimics of Kaposi sarcoma and its variants are broad. Clinical history such as HIV infection or history of organ transplant may strongly support the diagnosis of KS. Even with these clinical history, patch-stage cutaneous KS lesions may need to be differentiated from targetoid hemosiderotic hemangioma, fibrous histiocytoma, and interstitial granuloma annulare. The histologic mimics of plaque-stage KS include tufted angioma, targetoid hemosiderotic hemangioma, microvenular hemangioma and acroangiokeratitis. Lesions that may be confused with nodular KS include bacillary angiomatosis and other vascular tumors like spindle cell hemangioma and Kaposiform hemangioendothelioma, fibrohistiocytic tumors like cellular angiomatoid and atypical variants of fibrous histiocytoma and dermatofibrosarcoma protuberans, resolving dermal fasciitis, spindle cell melanoma, and other spindle cell mesenchymal neoplasms like cutaneous leiomyosarcoma (26, 27).

Advanced and more aggressive forms of KS need to be differentiated from angiosarcoma. Paucivascular anaplastic KS needs to be distinguished from other high-grade sarcomas like leiomyosarcoma, spindle cell rhabdomyosarcoma, malignant peripheral nerve sheath tumor, fibrosarcoma and amelanotic spindle cell melanoma. Lymphangioma-like KS may mimic other benign lymphatic tumors such as lymphangioma circumscriptum or acquired progressive lymphangioma. The architectural arrangement of telangiectatic KS may mimic a sinusoidal hemangioma which is an uncommon acquired variant of cavernous hemangioma (26, 27).

Pyogenic granuloma-like KS may be misdiagnosed as a true PG especially if the surface is ulcerated. The mimics of intravascular KS includes intravascular papillary endothelial hyperplasia, intravenous PG, intravascular fasciitis, papillary intralymphatic angioendothelioma and intravascular myopericytoma (26,27).

2.3 Laboratory diagnosis

2.3.1 Histomorphology

The histopathology of KS is identical in the different epidemiologic KS types. However, some studies have documented minor histopathologic differences between AIDS-KS and non-HIV-associated KS cases namely that mitoses and cellular anaplasia are more common in HIV-negative patients whereas AIDS-KS lesions tend to display more extensive dissecting vessels. Early patch-stage KS is characterized by abnormal vessels lined by thin endothelial cells dissecting the dermis (29).

Proliferating vessels often surround larger ectatic vessels and skin adnexa producing the promontory sign. This sign is not pathognomonic for KS as it has also been described in other vascular lesions including benign vascular tumors and angiosarcoma. Sparse chronic inflammatory cells extravasated red blood cells and hemosiderin-laden macrophages are frequently present in patch KS lesions. These early histologic changes may be inconspicuous and for that reason can be easily missed on biopsy (29).

Plaque-stage KS lesions are characterized by a proliferation of both spindle cells and vessels which in the skin involve most of the dermis and sometimes even the subcutis. Well-developed KS tumors consist of several fascicles of these spindle-shaped tumor cells often admixed with a chronic inflammatory infiltrate composed of lymphocytes, plasma cells and haemosiderin-laden macrophages (29,30).

2.3.2 Immunohistochemistry:

HHV-8 LANA -I

HHV-8 LANA-1 is a 1,162 amino acid protein encoded by viral gene ORF73 that is found in all cells latently infected by HHV-8. It has been postulated to have a vital role in the pathogenesis of KS by targeting the p53 and retinoblastoma-E2F pathways. Latent antinuclear antigen-1(LANA-1) can be detected by immunohistochemical staining in all different morphological forms of KS. The advantages of this method of HHV-8 detection over molecular studies include the relative simplicity of the technique and the opportunity to interpret the results on the context of the morphologic features. Human Herpesvirus type 8 Novocastra lyophilized mouse monoclonal antibody is used to stain for LANA-1. Human

Herpes virus type 8 LANA-1 staining is localised in the nuclei of infected endothelial and spindle cells and is usually diffuse with superimposed granular pattern. Latent associated nuclear antigen-1 immunostaining has a sensitivity of 99% and specificity of 100% according to a study by Robin YM et al (2004) in France (33). Immunostaining results are reported as positive if the cells stain for LANA-1 or negative if they fail to stain for LANA-1 as was done in previous studies (6,31).

3. STUDY JUSTIFICATION AND RATIONALE.

Previously the main role of immunohistochemical analysis in KS has been to establish the vascular or presumably lymphatic nature of the lesion and it did not contribute much towards differentiating reactive from neoplastic vascular lesions. KS mimics a variety of non-KS lesions for example bacillary angiomatosis, pyogenic granuloma and spindle cell angiosarcoma therefore causing confusion to many histopathologists which leads to patients missing on the correct therapy for KS.

At KNH, KS diagnosis is done by histomorphology alone rather than combining histomorphological diagnosis with immunohistochemical diagnosis. This could lead to a situation where KS cases are misdiagnosed as non-KS lesions due to their histomorphological similarities. Immunohistochemical evaluation of these cases is therefore essential in characterizing these cases to find out whether there is any discordance between histomorphological and immunohistochemical diagnosis of KS.

Given the high sensitivity and specificity of HHV-8 LANA-1 immunostaining for KS, immunohistochemical analysis plays an important role in the diagnosis of KS and could be helpful in the diagnosis of KS.

This study therefore aimed to assess the utility of LANA-1 immunohistochemistry in the definitive diagnosis of KS and in differentiating it from its morphological mimics.

4. RESEARCH QUESTION

What is the pattern of LANA-1 expression in tumours diagnosed as Kaposi sarcoma and in tumours that morphologically mimic Kaposi sarcoma at Kenyatta National Hospital?

4.1 Broad objective

To describe the pattern of LANA-1 expression in tumours diagnosed as Kaposi sarcoma and in tumours that morphologically mimic Kaposi sarcoma at Kenyatta National Hospital.

4.2 Specific objectives

1. To describe the histomorphology of all cases diagnosed as KS and cases that morphologically mimic KS on light microscopy.

2. To describe the pattern of expression of LANA-1 in cases diagnosed as Kaposi sarcoma and cases that morphologically mimic Kaposi sarcoma.
3. To correlate LANA-1 expression with histomorphology in cases diagnosed as Kaposi sarcoma and in cases that morphologically mimic Kaposi sarcoma.

5. STUDY DESIGN, MATERIALS AND METHODS

5.1 Study design

This was a laboratory based descriptive retrospective study.

5.2 Study setting.

The study was done at the Kenyatta National Hospital and University of Nairobi histopathology laboratories.

5.3 Study subjects

Cases previously reported as Kaposi sarcoma and cases that morphologically mimic KS at Kenyatta National Hospital.

5.4 Study duration

The study was done on cases reported between 1st January 2012 to 31st December 2013 at Kenyatta National Hospital and the study was performed between January and February 2015.

5.5 Study eligibility criteria

5.5.1 Inclusion criteria

1. Cases previously diagnosed as Kaposi sarcoma on histomorphology at Kenyatta National Hospital histopathology laboratory.
2. Cases previously diagnosed as mimics of Kaposi sarcoma on histomorphology at Kenyatta National Hospital histopathology laboratory.

5.5.2 Exclusion criteria

1. Cases whose laboratory reports could not be retrieved from the archives.
2. Laboratory reports of which the tissue blocks cannot be retrieved or are damaged or lack sufficient tissues for evaluation.
3. Poorly processed tissues.

5.6 Sample size determination

An estimated number of 59 specimens of KS and KS mimics were identified in KNH within a retrospective period between 1st January 2012 to 31st August 2014. Therefore, out of this population a representative sample was drawn and the sample size calculation was obtained using a formula for finite population (less than 10,000). The calculation was as follows:

$$n' = \frac{NZ^2P(1-P)}{d^2(N-1) + Z^2P(1-P)} \quad (31)$$

Where

n' = sample size with finite population correction,

N = size of the target population = 59

Z = Z statistic for 95% level of confidence = 1.96

P = Estimated proportion of KS and KS mimics with positive expression of LANA-1 = 53% (Bogaert, 2012).

d = margin of error = 5%

$$= \frac{59 \times 1.96^2 \times 0.53 \times 0.47}{0.05^2 (59-1) + 1.96^2 \times 0.53 \times 0.47}$$

$n = \mathbf{51}$

A minimum of 51 KS and KS mimics were sampled for LANA-1 expression tests.

5.7 Sampling method

Consecutive sampling method was used to select the sample for this study. Sampling frame was created from the list of all the KS and KS mimics collected between 1st January 2012 to 31st December 2013.

5.8 Identification of cases

The files containing histology reports at the Kenyatta National Hospital were perused to identify all the cases that met the inclusion criteria. The name, sex, ward, patients hospital number, hospital name and laboratory number were noted from the histology report as the cases were identified. This information was used to retrieve the archived specimen.

5.9 Materials

5.9.1 Equipment

A semi-automated Rotary microtome and an Olympus microscope was provided by the University of Nairobi department of Human Pathology.

5.9.2 Reagents and other consumables

Gloves, cassettes, microtome blades, staining racks, slides, slide holder, labels, and reagents were purchased by the Principal investigator.

5.10 Methods

5.10.1 Paraffin embedded block retrieval

Paraffin wax embedded blocks were retrieved from histopathology archives at the study site using the laboratory numbers on the retrieved pathology reports.

5.10.2 Histological preparation-Haematoxylin & Eosin for light microscopy

A 5 micron section was cut from each of the blocks and stained with Haematoxylin & Eosin (Appendix 3). This procedure was performed by the University of Nairobi histopathology laboratory technologists. The slides were reported by the investigator then reviewed together with the two supervisors who are qualified pathologists.

Immunohistochemistry was then performed on all cases diagnosed as Kaposi sarcoma and cases that morphologically mimic Kaposi sarcoma(Appendix 2).

5.10.3 Immunohistochemistry controls

Previously positive LANA-1 immunohistochemistry KS cases were used as positive control whereas slides of normal skeletal muscles were used as negative control.

5.10.4 Quality assurance

All reagents were prepared according to the manufacturer's instructions. Standard operating procedures were adhered to during all the procedures. The reagents were checked for expiry date, turbidity, odour and precipitates. The recommended storage for all reagents were observed. Positive controls were used while doing immunohistochemistry staining and interpretation. The slides were well labelled before mounting the sections and then arranged in order to avoid mix up of slides. Slides that had morphological discrepancies after review by the two supervisors were reviewed by a third pathologist who acted as a tie breaker.

5.10.5 Ethical considerations

Permission for records and specimen retrieval and use in this study was obtained from the Ethics and Research Committee of KNH/UoN. All patient identifiers were protected to maintain confidentiality by use of study numbers. The histomorphological and immunohistochemistry results will be submitted to the patient's primary clinicians as an addendum report to aid in patient management. The findings of this research will be disseminated to the clinicians at KNH for use in the management of KS patients in future. A manuscript paper will also be submitted to scientific journals for publication without patient identifiers after which the raw data from this study will be destroyed.

5.10.6 Data management and analysis

Data on gender, age and HIV status was abstracted from patient's file using a coded data capture sheet by the investigator. Laboratory information was recorded in the data capture sheet by the investigator after the tests were carried out. The data capture sheet was reviewed by the investigator to ensure they were completed appropriately. Data collected

was entered into an Excel spreadsheet by the investigator in a password protected computer. Back-up copies were stored in an external hard drive and compact disc which was in sole custody of investigator. The filled data capture sheet was in the safe custody of the investigator who filed and stored them in a locked cabinet for verification during analysis. Data cleaning was conducted after data entry before analysis. Statistical analysis was done in SPSS version 21.0. The study population was described by summarizing demographic and clinical data into proportions for categorical variables and means/ medians for continuous data.

Histomorphological findings were analyzed and presented as proportions. Latent associated nuclear antigen-1 expression was presented as proportions of patients with positive and negative results. In addition, final diagnosis was presented as proportions of cases with concordance or discordance between LANA-1 immunohistochemistry with histomorphology. Ninety five (95%) confidence interval was presented with the proportions. LANA-1 expression was stratified with histomorphology findings. The degree of agreement was presented using Kappa statistics. Statistical significance was interpreted at a p value of 0.05. The findings of this study were presented in tables and graphs.

6. RESULTS

This study was carried out between January and March 2015. The total number of cases recruited for this study was 51 out of which 35 cases were KS cases and 16 cases were KS mimics. The mean age in this study was 36.9 years and the median age was 34.0 years. The youngest case was 3 months whereas the oldest case was 82 years. Among the cases recruited, 27(52.9%) were males and 24(47.1%) were females. The male to female ratio was 1.1:1 with a slight male preponderance (Figure 1).

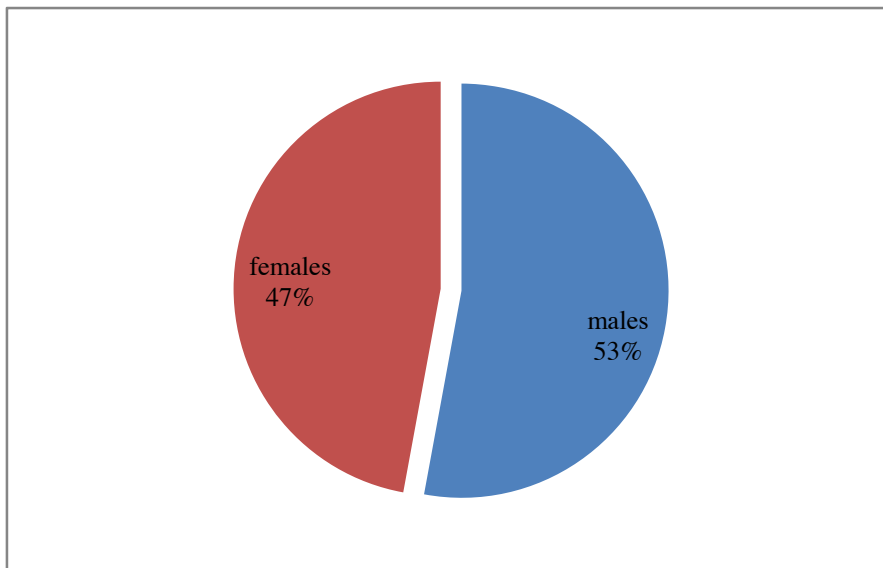


Figure 1: Distribution of cases by sex (n=51)

Of the 51 cases analysed, 16 cases (31%) had HIV status indicated on the request form whereas 35 cases (69%) did not (Figure 2).

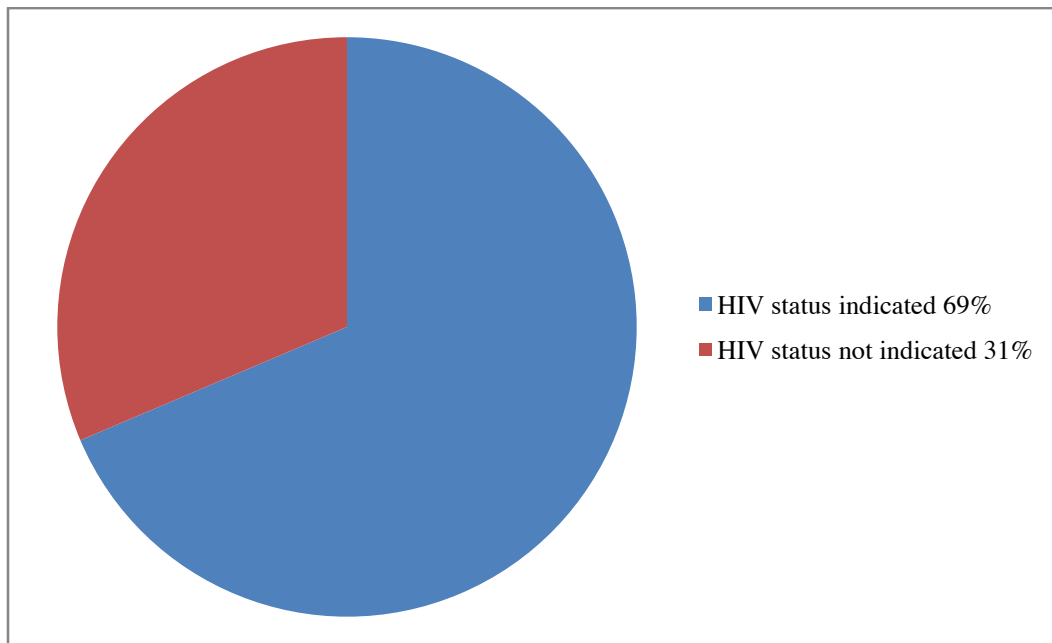


Figure 2: Patients HIV status (n=51)

Of the cases analysed, 32 (62.7%) were skin lesions, 13 (25.5%) were from the oral cavity, 2 (3.9%) were lymph nodes and 4 (7.8%) were from other sites of the body (Figure 3).

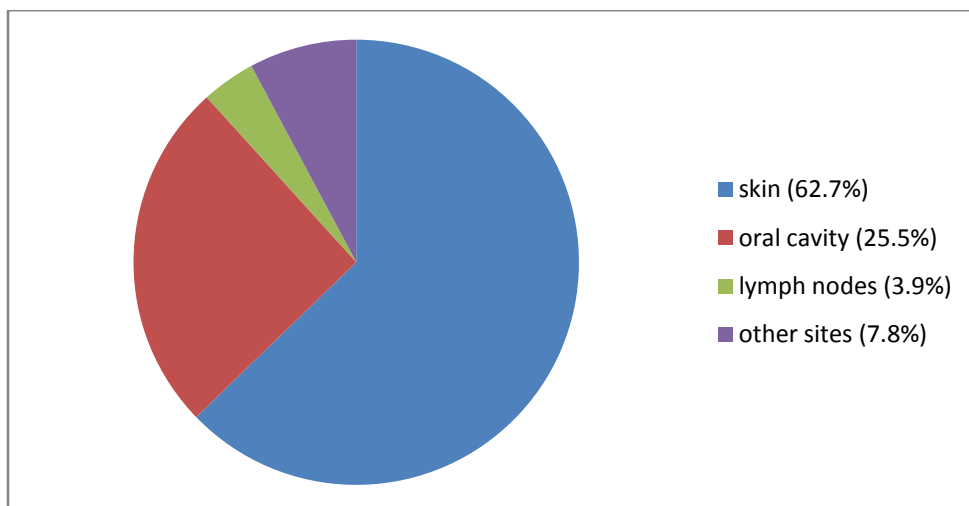


Figure 3: Site of the lesion (n=51)

The histomorphological diagnosis of the cases before review was as follows: 35 (68.6%) cases had been diagnosed as KS whereas 16 (31.4%) cases had been diagnosed as KS mimics (Figure 4). Thirteen of the mimics were pyogenic granuloma, two cases were dermatofibroma and one case was carvenous haemangioma.

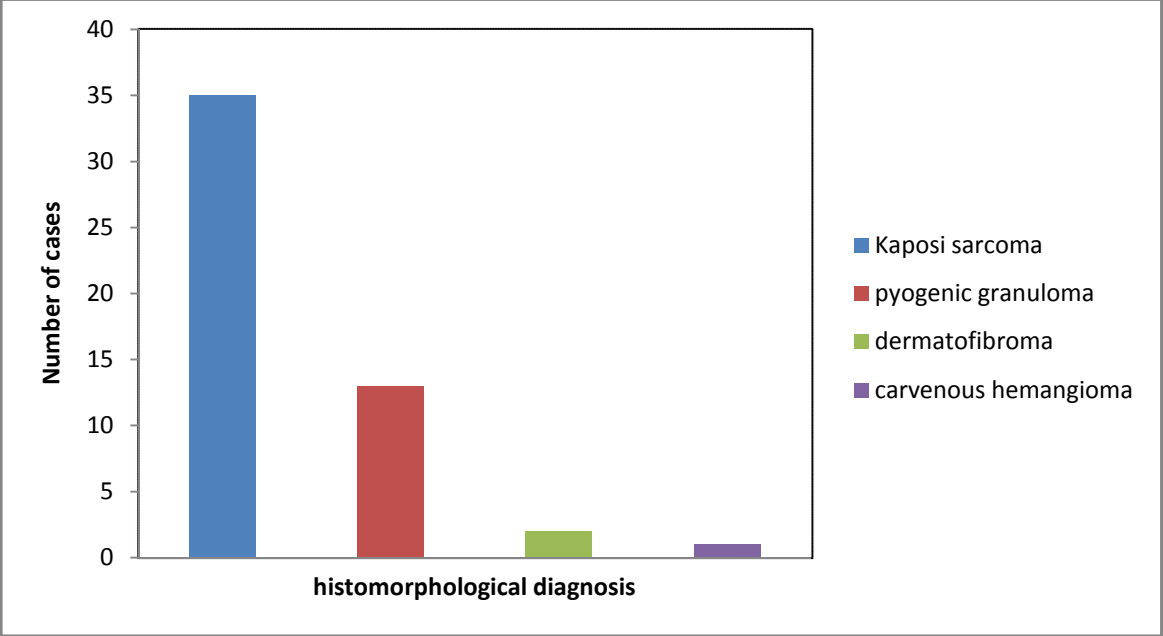


Figure 4: Histomorphological diagnosis before review (n=51)

After histomorphological review, 33 (64.7%) cases were KS and 18 (35.3%) were KS mimics. Of the KS mimics, 12 (66.7%) cases were pyogenic granuloma, 2 (11.1%) cases were dermatofibroma, one (5.6%) case was clear cell acanthoma and one (5.6%) case was an endometrial polyp.

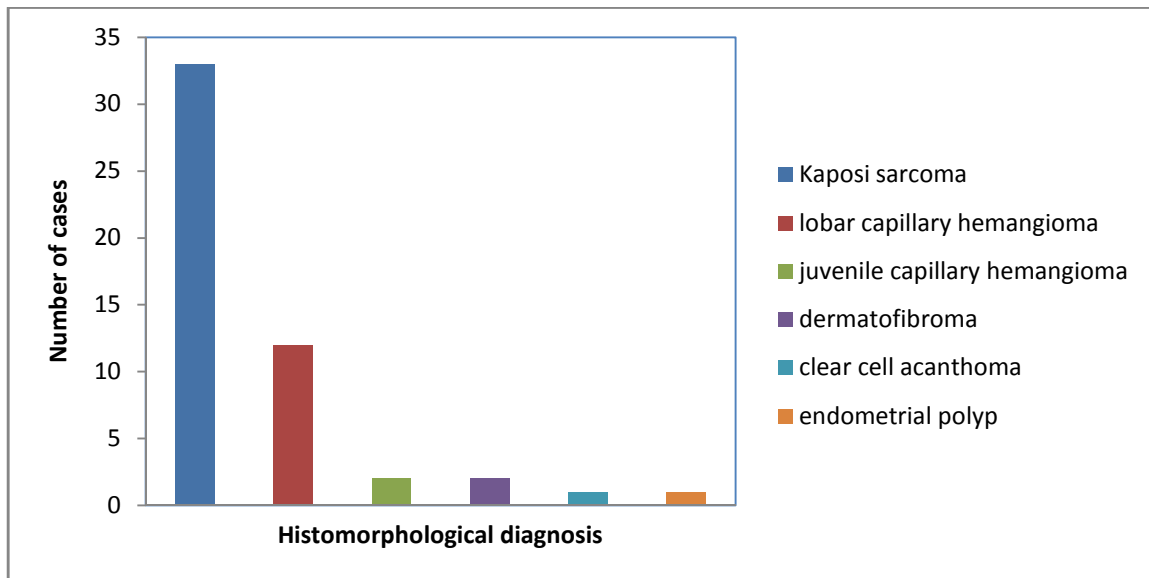


Figure 5: Histomorphological diagnosis after review (n=51).

The KS cases (n=33) were stratified according to the stage of progression and the results were as follows;27(81.8%) cases were of nodular stage,one(3.0%) case was in plaque stage and 5(15.2%) cases were in patch stage (Figure 6).

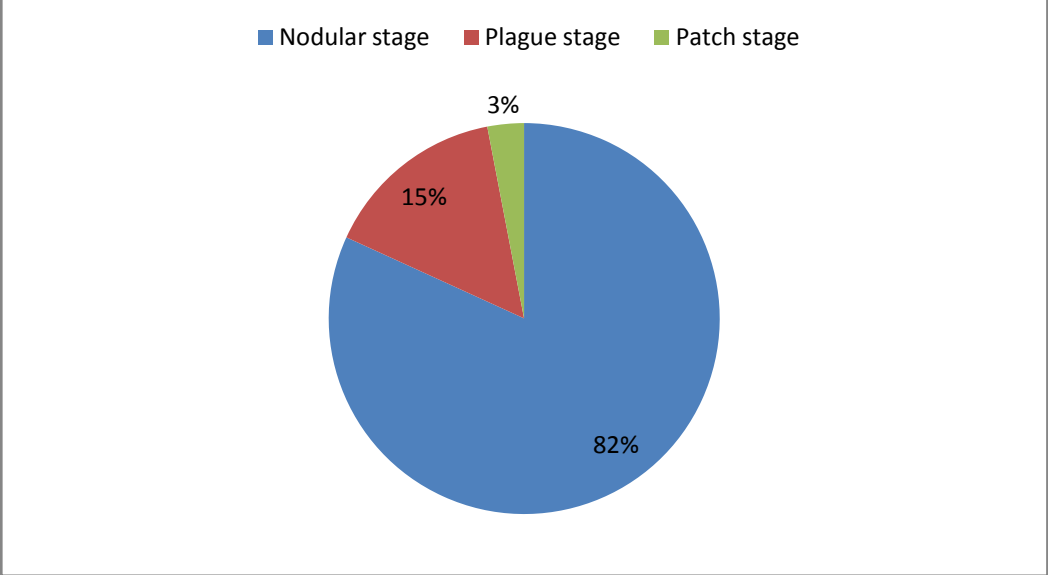


Figure 6: Stratification of Kaposi sarcoma cases by stage of progression (n=33)

Association of LANA-1 expression with different variables.

All specimens from HIV positive patients (Table 1) expressed LANA-1 compared to 45.7% of those with unknown HIV status ($p < 0.001$). LANA-1 expression was not significantly associated with age, gender, site of the lesion and stage of progression of KS ($p > 0.05$).

All the specimens from patients identified as HIV positive were Kaposi sarcoma. Of the specimens whose HIV status were unknown, 48.6% were Kaposi sarcoma (Table 1).

There was no statistical significance between LANA-1 expression and the stage of progression as shown in Table 1.

Table 1: Association of LANA-1 expression with different variables.

	LANA-1 expression		P-Value
	Positive (%)	Negative (%)	
Age, mean (SD)	39.8 (12.7)	32.1 (20.9)	0.108
Sex			
Male	17 (63.0%)	10 (37.0%)	0.973
Female	15 (62.5%)	9 (37.5%)	
Site of the lesion			
Skin	20 (62.5%)	12 (37.5%)	0.343
Oral cavity	9 (69.2%)	4 (30.8%)	
Lymph nodes	2 (100.0%)	0 (0.0%)	
Other	1 (25.0%)	3 (75.0%)	
HIV status			
Positive	16 (100.0%)	0 (0.0%)	< 0.001
Not indicated	17 (48.6%)	18 (51.4%)	
Kaposi sarcoma stage of progression			
Patch	5 (100)	0 (0)	1.000
Plague	1 (100)	0 (0)	
nodular	27 (100)	0 (0)	

Histomorphology and immunohistochemistry concordance rate.

There was a high rate of concordance (96%) between histomorphology and immunohistochemistry with a Kappa of 0.912, p-value of <0.001 as shown in Table 2. In determining the concordance rate, the histomorphological diagnosis before review and immunohistochemical diagnosis was correlated.

Table 2: Concordance rate

histomorphological diagnosis before review	Immunohistochemistry LANA-1 expression		Total	Concordance rate	Kappa,p value
	Positive	Negative			
Kaposi Sarcoma	33	2	35	96%	0.912 <0.001
Mimic	0	16	16		
Total	33	18	51		

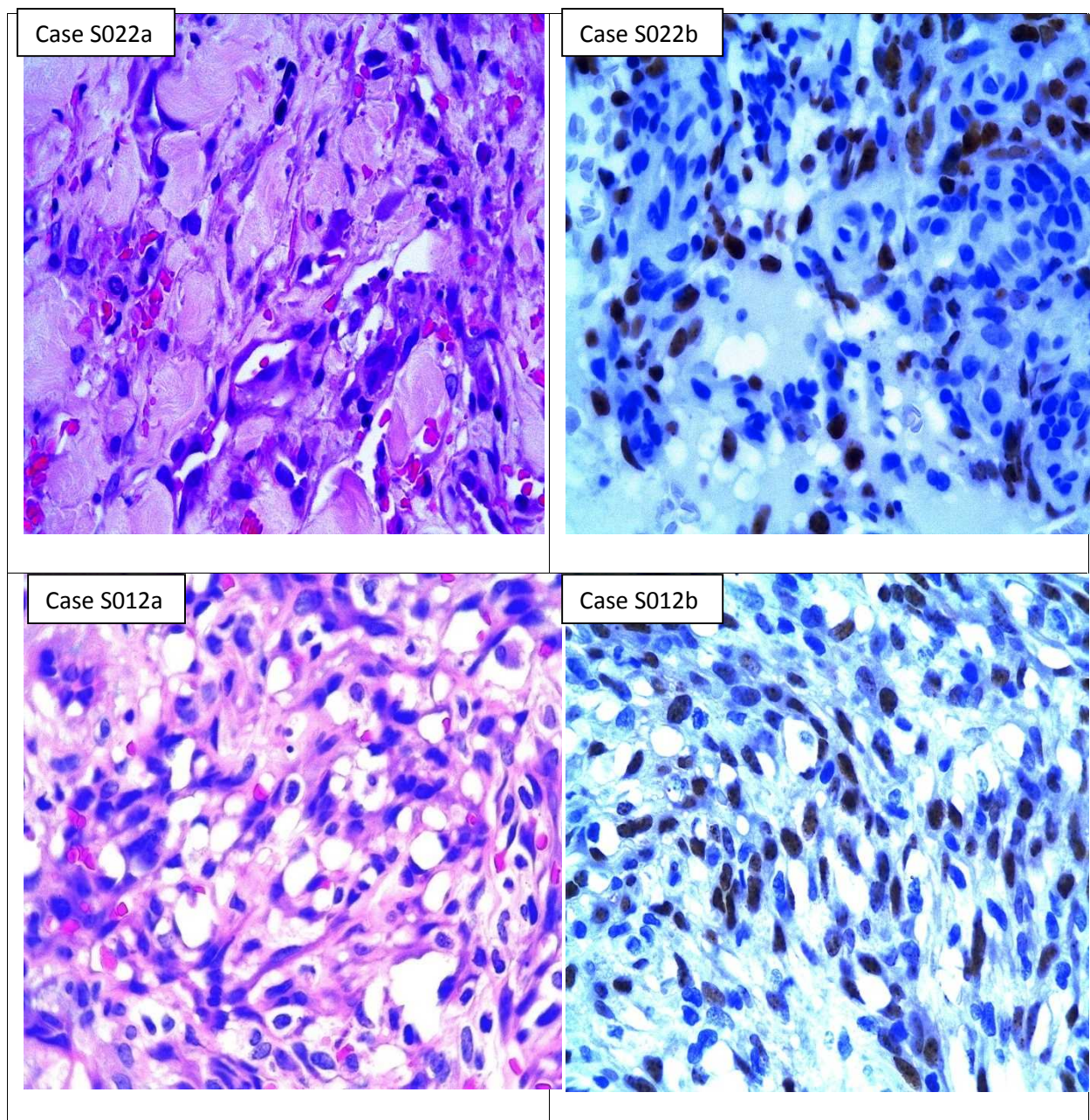


Figure 7: Histomorphological and immunohistochemical findings of some of the cases in the study.

Case S022a: ^ x63, H/E stained section of the skin exhibiting features of patch stage of Kaposi sarcoma characterised by vascular proliferation, plasma cell infiltrate in the dermis and dermal splitting. **Case S022b:** ^ x63, Positive LANA-1 immunohistochemistry. **Case S012a:** ^ x63, H/E stained section of the skin exhibiting features of lymphangiectatic KS comprising of dilated lymphatic channels with areas of red blood cell extravasation. **Case S012b:** ^ x63, Positive LANA-1 immunohistochemistry.

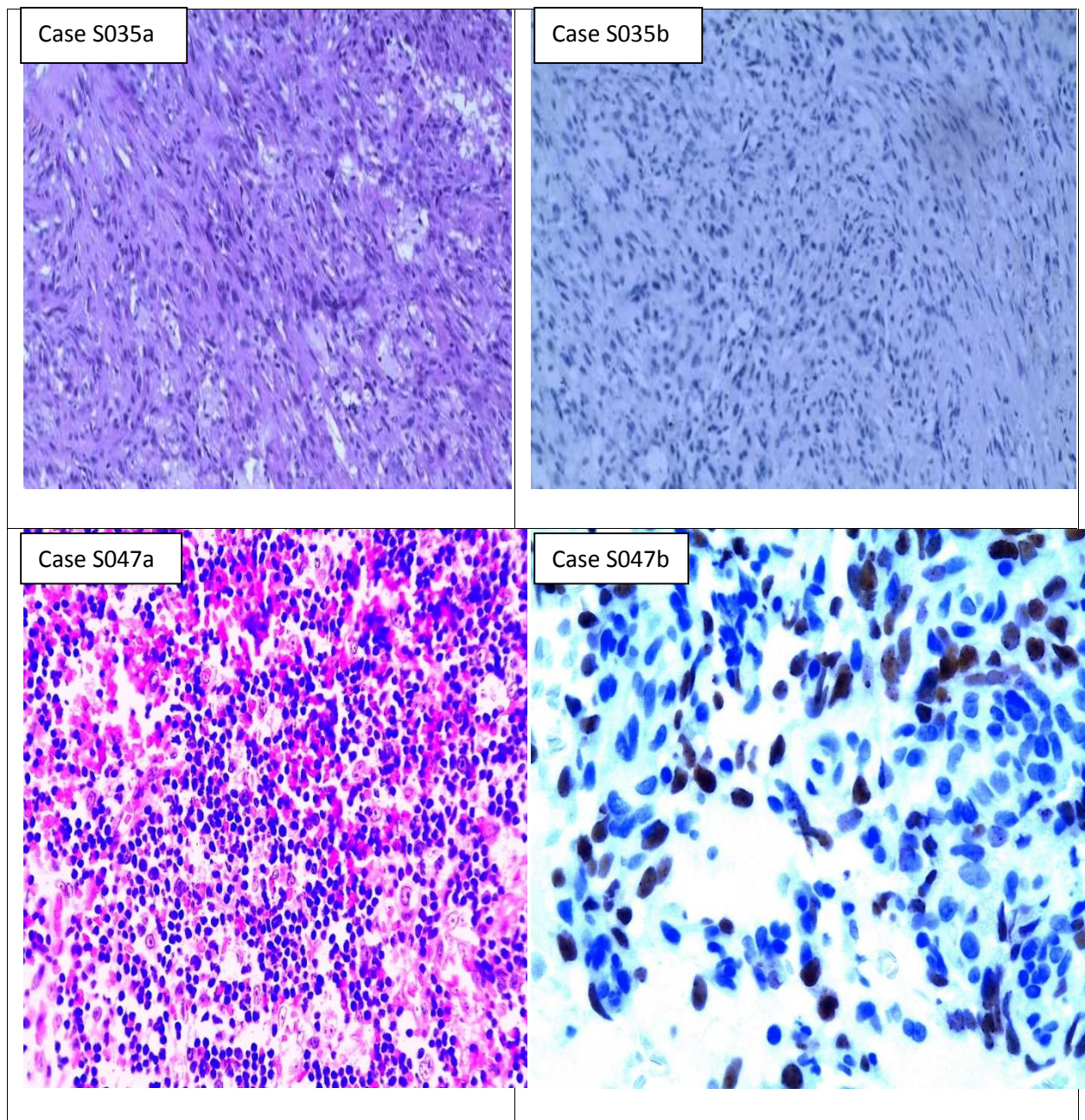


Figure 7 continued: Histomorphological and immunohistochemical findings of some of the cases in the study.

Case S035a: ^ x20, H/E stained section of the skin bearing a nodular benign tumour in the dermis comprising of bland spindle shaped cells; **Case S035b:** ^ x20, Negative LANA-1 immunohistochemistry. **Case S047a:** ^ x63, H/E stained section of the lymph node exhibiting features of lymph node Kaposi sarcoma characterised by architecture effacement and marked red blood cell extravasation. **Case S047b:** ^ x63, Positive LANA-1 Immunohistochemistry.

7. DISCUSSION

Kaposi sarcoma mimics a variety of non-Kaposi sarcoma lesions on histomorphology like bacillary angiomatosis, pyogenic granuloma and dermatofibroma therefore posing a diagnostic challenge to many histopathologists. Kaposi sarcoma lesions express latent associated nuclear antigen-1 which can be detected by the Human herpes virus-8 antibody hence aiding in the accurate diagnosis of Kaposi sarcoma and therefore, differentiating it from its mimics which do not express LANA-1. The use of the monoclonal anti-HHV-8 LANA-1 antibody to identify the HHV-8 in fixed tissues is an efficient and low cost way to differentiate KS from its mimics compared to molecular methods such as fluorescence insitu hybridization (32).

Previous studies have shown that there is no statistical significant association between age and KS. This was observed in this study where the youngest case was 3 months and the oldest 82 years. However, the mean age was 36.9 years. In this study cases of KS were fewer in the very young and the elderly compared to the adolescents and the middle-aged. This could be attributed to the low prevalence of HIV/AIDS in the very young and elderly which is a predisposing factor to KS development as per the KAIS report of 2012 (35). Further comparison of age and LANA-1 expression in this study, revealed no statistical significance (p -value=0.108). These results are comparable to a study done by Louis JVB et al, (2012) in South Africa (31).

Similar to other studies, there was a male preponderance (52.9%) but with no statistical significant association with LANA-1 expression with a p -value of 0.978 (31, 32). This is contrary to the expectation that there should be a female preponderance of KS due to the high HIV/AIDS prevalence amongst the female population as per KAIS report of 2012. This is because HIV/AIDS is a risk factor for KS development (35). Instead studies have shown that the high male preponderance of KS is due to the high androgen levels in KS patients which affects the immune system by inducing an abnormal cytokine profile or by increasing the CD8 lymphocyte proliferation and activation or both (34). Studies have previously shown a positive significant association between immunosuppression associated with HIV and KS (35). The findings in this study showed a statistically significant association between HIV and LANA-1 expression with a p -value of <0.001 .

All the cases that had their positive HIV status indicated on the request form (31.3%) were reported as Kaposi sarcoma on histomorphology. Of the cases that did not have their HIV

status indicated, 48.6% of them were reported as Kaposi sarcoma. Failure to indicate the HIV status in this study, made it difficult to ascertain with confidence the HIV status of the Kaposi sarcoma mimics. A similar study done by Louis JVB et al, (2012) also encountered similar challenges in which 61% of the cases had HIV status known whereas 39% were unknown (31). This study therefore, had poor documentation for HIV status on the request forms compared with that of Louis JVB et al done in 2012.

Kaposi sarcoma has three stages of progression which includes; patch, plaque and nodular stages. The diagnosis of KS is usually difficult in the early patch stages but becomes less confusing as Kaposi sarcoma progresses towards the nodular stage (26, 27). This has been shown in this study where majority of the cases (81.8%) were in nodular stage, 5% were in patch stage whereas 1% of the cases were in plaque stage. These findings slightly differed from those of Louis JVB et al, (2012) and Wah Cheuk et al, (2004) in which the majority of KS were in patch stage (6,31,). However, there was no statistically significant association between the stage of KS progression and LANA-1 expression (p-value of 1.000).

Two cases (0.1%) out of 35 that had initially been diagnosed as early patch KS were negative for LANA-1 immunohistochemistry and after review of their histomorphological features diagnosed as clear cell acanthoma and endometrial polyp respectively. The patch stage of KS is the histological variant with the greatest propensity to cause diagnostic difficulties because in very early stages it has features as subtle as a mild inflammatory infiltrate in the dermis and dermal splitting (27).

Nodular stage of Kaposi sarcoma is the last stage in the progression of KS. This study had more cases in nodular stage than the studies by Louis Bogaert et al, (2012) in South Africa and Wah cheuk et al, (2004) in South Korea which have advanced health care systems than Kenya, therefore it is possible to postulate that patients in these countries seek for health care early, hence cases being diagnosed early in patch stage.

Three cases (0.1%) in this study were diagnosed as ulcerated nodular KS and stained positive for LANA-1 immunohistochemistry. Pyogenic granuloma which is a mimic of KS can be confused with ulcerated nodular KS due to the morphological similarities with pyogenic granuloma-like KS which include epidermal ulceration and vascular proliferation causing diagnostic challenges on morphology (27).

This study had a high concordance rate between LANA-1 immunohistochemistry and histomorphology (Concordance rate of 96% with a Kappa of 0.912, p-value of <0.001) compared to a study done by Louis JVB et al, (2012) in South Africa which had a 90.8% concordance rate. A similar study done by Wah Cheuk et al, (2004) had a concordance rate of 100% which was attributed to the antigen retrieval method that was used (pressure cooking in an alkaline method) compared to this study where EDTA was used for antigen retrieval. This study therefore shows that histomorphology is still a dependable method in the diagnosis of KS.

Kaposi sarcoma mimics do not express LANA-1 on immunohistochemistry. This has been shown in this study in which all the KS mimics were negative for LANA-1 immunohistochemistry. Studies done in South Africa and South Korea showed similar results (6,31).

7.1 CONCLUSIONS

The following conclusions were drawn from the results of this study.

1. Histomorphological diagnosis is a dependable method in the diagnosis of Kaposi sarcoma and differentiating it from its mimics.
2. Nodular stage of KS can be diagnosed on histomorphology alone with a high level of accuracy.
3. Early patch stage KS lesions pose a diagnostic challenge and therefore HHV-8 LANA-1 immunohistochemistry is indicated for a definitive diagnosis.

7.2 RECOMMENDATIONS

1. Latent associated nuclear antigen-1 immunohistochemistry should be recommended for early patch stage of Kaposi sarcoma to differentiate early KS from its mimics.
2. Latent associated nuclear antigen-1 immunohistochemistry should be recommended for ulcerated nodular KS to differentiate these lesions from ulcerated pyogenic granuloma.

7.3 STUDY LIMITATION

There was difficulty in retrieval of the tissue blocks due to poor archival system at the KNH histopathology laboratory.

REFERENCES

1. Kaposi M: Idiopathisches multiples pigment sarcoma de-Hut. Archives Dermatology Syphilis 1872,4(265).
2. Parkin DM, "The global health burden of infection-associated cancers in the year 2002," International Journal of Cancer 2006; 118: 3030–3044.
3. Nairobi Cancer Registry report 2011
4. Schwartz J, Dorfman RF and Kohler S, "Human herpes virus-8 latent nuclear antigen-1 expression in endemic Kaposi sarcoma: an immunohistochemical study of 16 cases," The American Journal of Surgical Pathology 2003; 27: 1546–1550.
5. Patel M, Goldblum JR, and Hsi ED, "Immunohistochemical detection of human herpes virus-8 latent nuclear antigen-1 is useful in the diagnosis of Kaposi sarcoma," Modern Pathology 2004; 17: 456–460.
6. Cheuk W, Wong KO, Wong CS et al "Immunostaining for human herpesvirus 8 latent nuclear antigen-1 helps distinguish kaposi sarcoma from its mimickers," American Journal of Clinical Pathology 2009; 121: 335–342.
7. Biggar RJ, Rosenberg PS, Cota T et al. Kaposi sarcoma and non-Hodgkins lymphoma following the diagnosis of AIDS, Multistate AIDS-Cancer Match Study group. International Journal of Cancer 1996;68:754-8
8. Cesarman E, Nador RG, Aozasa K et al, "Kaposi's sarcoma-associated herpes virus in non-AIDS related lymphomas occurring in body cavities," American Journal of Pathology 1996;149: 53-57.
9. Soulier J, Grollet L, Oksenhendler E et al, "Kaposi's sarcoma-associated Herpes virus-like DNA sequences in multicentric Castleman's disease," 1995; 86: 1276-1280.
10. Schwartz RA. Kaposi's sarcoma: an update of Journal of surgical oncology 2004;87:146-152
11. Fauci AS and Lane HC. Human immunodeficiency virus. AIDS and related disorders. In Harrison's principles of internal medicine 16th edition; 2006.
12. Massod R, Cesarman E, Smith DL et al. Human herpes virus-8-transformed endothelial cells have functionally activated vascular endothelial growth factor/vascular endothelial growth factor receptor. American Journal of Pathology 2002;160:23-29
13. Boshoff and Chang Y, "Kaposi's sarcoma-associated herpesvirus: a new DNA tumor virus," Annual Review of Medicine 2000; 52: 453-470.

14. Ciufu DM, Cannon JS, Poole LJ et al., "Spindle cell conversion by Kaposi's sarcoma-associated herpesvirus: formation of colonies and plaques with mixed lytic and latent gene expression in infected primary dermal microvascular endothelial cell cultures," *Journal of Virology* 2001;75: 5614-5626.
15. Gao SJ, Deng JH and Zhou FC, "Productive lytic replication of a recombinant Kaposi's sarcoma-associated herpesvirus in efficient primary infection of primary human endothelial cells," *Journal of Virology* 2003; 77: 9738-9749.
16. Pan H, Zhou F and Gao SJ, "Kaposi's sarcoma-associated herpes virus induction of chromosome instability in primary human endothelial cells," *Cancer Research* 2004; 64: 4064-4068.
17. Jones JL, Hanson DL, Chu SY, et al, "AIDS associated Kaposi's sarcoma 1995; 267: 1078-1079.
18. Mocroft A, Youle M, Gazzard B et al., "Anti-herpesvirus treatment and risk of Kaposi's sarcoma in HIV infection. Royal Free/Chelsea and Westminster Hospitals Collaborative Group," *AIDS* 1996; 10: 1101-1105.
19. Monini P, Carlini F, Sturzl M et al., "Alpha interferon inhibits human herpesvirus 8 (HHV-8) reactivation in primary effusion lymphoma cells and reduces HHV-8 load in cultured peripheral blood mononuclear cells," *Journal of Virology* 1999; 73: 4029-4041.
20. Massod R, Cesorman E, Smith DL et al. Human herpes virus-8-transformed endothelial cells have functionally activated vascular endothelial growth factor/vascular endothelial growth factor receptor. *American Journal of Pathology* 2002;160:23-29
21. Fauci AS and Lane HC. Human immunodeficiency virus. AIDS and related disorders. In *Harrison's Principles of Internal Medicine* 16th edition. 2006
22. Coogan MM, Greenspan J, Challacombe SJ, Oral lesions in infection with human immunodeficiency virus. *Bull World Health Organisation* 2005, September, 83(9):700-6.
23. Iscovich J, Boffetta P, Franceschi S et al. Classic Kaposi sarcoma: epidemiology and risk factors. *Cancer* 2000;88:500-17.
24. Karima C, Bray F, Wabinga HR et al. Kaposi sarcoma trends in Uganda and Zimbabwe: A sustained decline in incidence. *International Journal of Cancer* 2013;133:1197-1203.
25. Wabinga HR, Parkin DM, Wabwire MF et al. Trends in cancer incidence in Kyagondo county, Uganda, 1960-1997. *British Journal of cancer* 2000;82:1585-92)
26. Ackerman AB. *Histologic features of Kaposi's sarcoma and simulators of it.* Spectrum Publications, New York; 1985. 71-79.
27. Ackerman AB and Gottlieb GJ. *Atlas of the gross and microscopic features.* 1988. 29-72.

28. Beral V, Peterman TA, Berkelman RL et al. Kaposi sarcoma among persons with AIDS: a sexually transmitted infection? *Lancet* 1990;335:123-8)
29. Borroni G, Brazzelli V, Vignoli GP et al. Bullous lesions of Kaposi's sarcoma: case report. *American Journal of Dermatology*. 1997;19:379–383.
30. Connick E, Kane MA, White IE et al. Immune reconstitution inflammatory syndrome associated with Kaposi's sarcoma during potent antiretroviral therapy. *Clinical infectious disease* 2004;39:1852-5
31. Bogaert LJ, Gee K, Gray L et al. Clinicopathological Proficiency in diagnosis of Kaposi Sarcoma, *International Scholarly Research Notices*; 2012; 1-8
32. Patricia Fonsera, Tullia Cuzzi, Maria Clara et al. Immunohistochemical detection of the latent antigen-1 of the human herpes type 8 to differentiate cutaneous epidemic Kaposi sarcoma and its histological simulators. *Brazilian Journal of Dermatology*; 2012; 1-4
33. Robin YM, Guillou L, Michelles JJ et al. Human herpes 8 immunostaining. a sensitive and specific method for diagnosing Kaposi sarcoma in paraffin embedded sections. *American Journal of Clinical Pathology* 2004;121:330-4.
34. Christeff N, Winter C, Gharakhanian S et al. Differences in androgens of HIV positive patients with and without Kaposi sarcoma. *Journal of Clinical Pathology*; 1995; 48:513-518
35. Kenya Aids Indicator Survey 2012.

APPENDIX I: DATA CAPTURE SHEET.

PROJECT TITLE: LATENT ASSOCIATED NUCLEAR ANTIGEN- 1 EXPRESSION IN TUMOURS DIAGNOSED AS KAPOSI SARCOMA AND IN TUMOURS THAT MORPHOLOGICALLY MIMIC KAPOSI SARCOMA AT KENYATTA NATIONAL HOSPITAL.

Date-----

PATIENTS BIODATA

1. **Study/serialnumber** _____

2. **Age** (specify in completed years)_____

3. **Sex:** M F

4. **HIV status (as indicated on the request form)**

positive negative not indicated

5. **On HAART (if indicated on request form)**

yes no not indicated

6. **Site of the lesion**

Skin Oral Cavity Lymph Node Other Sites

7. **Previous histomorphological diagnosis**

Kaposi Sarcoma Mimic

8. **If mimic specify**_____

9. **Current histomorphological diagnosis (after review)**

Kaposi Sarcoma Mimic

10. **If Kaposi sarcoma, specify stage of progression**

Patch Plague Nodular

11. **If mimic, specify**_____

12. **Immunohistochemistry**

LANA-1 expression

Positive

Negative

APPENDIX II: LATENT ASSOCIATED NUCLEAR ANTIGEN-1 IMMUNOHISTOCHEMICAL STAINING PROCEDURE

Leica Bond-Max immunostainer Machine was used. After mounting the sections on negatively charged slides and loading them into the machine, IHC staining for LANA-1 consisting of a series of the following steps was carried out.

1. Rinse slide twice with Bond wash solution and twice with tris EDTA buffer.
2. Incubate with tris EDTA buffer for 20 minutes at 100 0C.
3. Incubate further with the tris EDTA buffer for another 12 minutes at room temperature. Steps 2&3 are also referred to as heat induced epitope retrieval (HIER). HIER describes a process of heating formalin-fixed paraffin-embedded tissue sections for improved immunoreactivity of tissue antigens with their specific antibodies.

Following antigen retrieval;

4. Rinse three times with bond wash solution.
5. Wash with bond wash solution for three minutes.
6. Block with peroxide for 5 minute
7. Rinse three times using bond wash solution at 350C.
8. Incubate with LANA-1 as appropriate for 15 minutes.
9. Rinse once with bond wash solution.
10. Apply post primary antibody for 8 minutes and wash with bond wash solution thrice each wash taking 2 minutes.
11. Apply Polymer for 8 minutes and wash with bond wash solution twice each wash taking 2 minutes.
12. Rinse with deionized water.
13. Rinse with mixed DAB refine then incubate the sections with mixed DAB refine for 10

minutes; DAB acts as the chromogen.

14. Rinse with deionized water.

15 Stain with hematoxylin for 5 minutes.

16. Rinse with deionized water,

17 Rinse with bond wash solution,

18. Rinse with deionized water

19. Air-dry the slide.

20. Visualize LANA-1 expression with a light microscope.

21. Document LANA-1 expression on the data sheet

APPENDIX III: HARRIS HAEMATOXYLIN AND EOSIN STAINING PROCEDURE

Principle of the stain

The mordant forms a lake on the tissue. It is on the lake that the stain gets attached thus coloring the cell nuclei. The nuclei having an affinity for the basic radical in the dye retains the color even after treatment with 1% acid alcohol. Eosin stains the cytoplasm as a counter stain.

Staining technique.

1. Bring section to water
2. Stain in Harris haematoxylin for 5 minutes
3. Rinse in tap water
4. Differentiate in 1% acid alcohol, 3dips
5. Rinse in tap water
6. Place in Scotts tap water for 30 seconds or in running tap water for 10 minutes
7. Counter stain in Eosin for 5 minutes
8. Rinse in tap water to remove excess eosin followed by 70% ethanol to obtain the desired shades of red and pink.
9. Dehydrate in the 3 changes of absolute alcohol
10. Clear in 3 changes of Xylene
11. Mount with D.P.X